



REVIEW

Open Access

Optical endomicroscopy and the road to real-time, in vivo pathology: present and future

Charles S Carignan^{1*} and Yukako Yagi²

Abstract

Epithelial cancers account for substantial mortality and are an important public health concern. With the need for earlier detection and treatment of these malignancies, the ability to accurately detect precancerous lesions has an increasingly important role in controlling cancer incidence and mortality. New optical technologies are capable of identifying early pathology in tissues or organs in which cancer is known to develop through stages of dysplasia, including the esophagus, colon, pancreas, liver, bladder, and cervix. These diagnostic imaging advances, together as a field known as optical endomicroscopy, are based on confocal microscopy, spectroscopy-based imaging, and optical coherence tomography (OCT), and function as "optical biopsies," enabling tissue pathology to be imaged in situ and in real time without the need to excise and process specimens as in conventional biopsy and histopathology. Optical biopsy techniques can acquire high-resolution, cross-sectional images of tissue structure on the micron scale through the use of endoscopes, catheters, laparoscopes, and needles. Since the inception of these technologies, dramatic technological advances in accuracy, speed, and functionality have been realized. The current paradigm of optical biopsy, or single-area, point-based images, is slowly shifting to more comprehensive microscopy of larger tracts of mucosa. With the development of Fourier-domain OCT, also known as optical frequency domain imaging or, more recently, volumetric laser endomicroscopy, comprehensive surveillance of the entire distal esophagus is now achievable at speeds that were not possible with conventional OCT technologies. Optical diagnostic technologies are emerging as clinically useful tools with the potential to set a new standard for real-time diagnosis. New imaging techniques enable visualization of high-resolution, cross-sectional images and offer the opportunity to guide biopsy, allowing maximal diagnostic yields and appropriate staging without the limitations and risks inherent with current random biopsy protocols. However, the ability of these techniques to achieve widespread adoption in clinical practice depends on future research designed to improve accuracy and allow real-time data transmission and storage, thereby linking pathology to the treating physician. These imaging advances are expected to eventually offer a see-and-treat paradigm, leading to improved patient care and potential cost reduction.

Virtual Slides: The virtual slide(s) for this article can be found here: <http://www.diagnosticpathology.diagnomx.eu/vs/5372548637202968>

Keywords: Barrett's esophagus, Cancer, Confocal microscopy, Dysplasia, Endoscopy, In vivo imaging, Neoplasia, Optical coherence tomography, Optical imaging

Introduction

Cancers affecting the mucosal tracts are a substantial public health concern. Indeed, the incidence of esophageal adenocarcinoma (EAC) has increased dramatically in the United States [1,2] as well as most other Western developed societies [1]. The increased incidence is particularly alarming among US white men, which jumped 463% between 1975 and 2004 [2]; increases have also

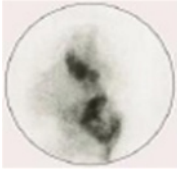
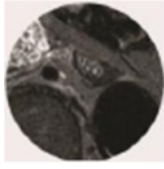

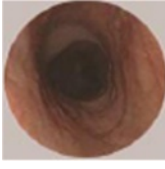
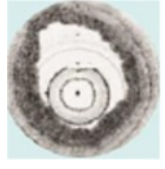

been observed in Europe, Australia, and New Zealand [3]. Age-standardized rates of EAC have increased up to 40% every 5 years in England and Wales [4], while annual increases in incidence rates of up to 5%, 5%, 6%, and 12% have been observed in Scotland, Scandinavia, France, and Switzerland, respectively [1,3,5,6]. EAC has a substantial impact on mortality, with a low 5-year survival rate (16.8%) [7]; overall, esophageal cancer has become the eighth most common cause of cancer death worldwide [1,3]. In contrast to esophageal cancer, the overall incidence rates of colorectal [8] and cervical

* Correspondence: CCarignan@ninepointmedical.com

¹NinePoint Medical, One Kendall Square B7501, Cambridge, MA 02139, USA
Full list of author information is available at the end of the article

Table 1 Comparison of current and investigational imaging technologies

	Radiology			Endoscopy	Endomicroscopy	
Resolution	1 cm	1 mm	100 μm	~100 μm	10 μm	1 μm
Field of view	50+ cm	30+ cm	2–5 cm	140°	3 mm	0.3 mm
Technology	Radio nucleotide, DOT, PET	MRI, CT, US	EUS, IVMRI, X-ray	Standard and high-definition video endoscopes	OFDI, OCT	SECM, Micro OCT, FFOCM

					
Organ Thallium	Organ MRI	Organ US	Tissue surface White light	Architectural OCT*	Cellular CM

*Volumetric.

CM = confocal microscopy; CT = computed tomography; EUS = endoscopic ultrasound; IV = intravenous; FFOCM = full-field optical coherence microscopy; MRI = magnetic resonance imaging; OCT = optical coherence tomography; OFDI = optical frequency domain imaging; PET = positive emission tomography; SECM = spectrally encoded confocal microscopy; US = ultrasound.

cancers [9] have declined in the past several decades, but rates of gastric adenocarcinoma have remained relatively stable [10]. Despite these trends, colorectal cancer is still the third most common cancer worldwide, with the highest age-standardized incidence rates in Australia/New Zealand (45.7 per 100,000 men) and Western and Southern Europe (41.2 and 39.3 per 100,000 men, respectively) [11]. Colorectal cancer is the third leading cause of cancer mortality in men and women in the United States and accounts for 8% of all cancer deaths worldwide, with the highest mortality rates in Central and Eastern Europe [11]. Cervical cancer is the third most common cancer in women, with an estimated 530,000 new cases worldwide in 2008; incidence and mortality are lower in more developed areas such as Europe and North America than in developing countries in Africa and South America [11]. Gastric cancer is the fourth most common malignancy in the world (989,000 new cases occurring in 2008) and the second leading cause of cancer death (738,000 deaths worldwide), with the highest mortality rates in Eastern Asia and Central and Eastern Europe [11].

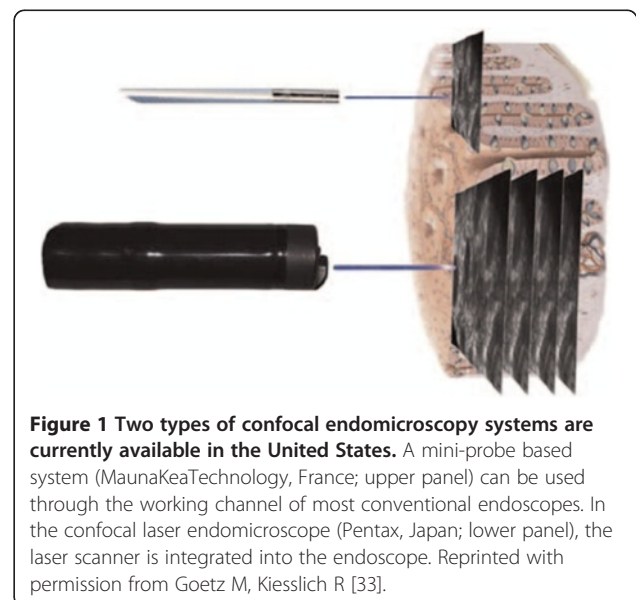Given the incidence and mortality associated with epithelial cancers, effective strategies for early detection and treatment of premalignant lesions are essential. The benefits of early detection have been clearly demonstrated in cervical cancer, with population-based and cohort studies indicating that regular Pap screenings have decreased cervical cancer incidence and mortality by at least 80% [12]. Similarly, Barrett's esophagus (BE) has been recognized as the premalignant lesion of EAC [13,14]. A growing number of studies have shown that regular endoscopic BE surveillance identifies patients with earlier stage cancer [15-17], leading to higher survival

rates than more advanced disease [16]. Several retrospective studies have indicated that survival is prolonged if esophageal cancers are detected by endoscopic surveillance rather than by presenting symptoms [13,15,18].

This review discusses the substantial progress under way in endoscopic imaging, including the present state of technology, current approaches to imaging research, and the potential impact of these techniques on daily clinical practice in the near future.

Paradigms in endoscopic biopsy: applications and limitations

Current approaches to endoscopic biopsy use external imaging, such as computed tomography (CT), magnetic



resonance (MR), or white light endoscopy, to image suspect tissue. Despite advances in the field of endoscopic imaging, technical limitations of these modalities exist. These limitations may have important clinical implications, especially in optimizing cancer screening, diagnosis, and surveillance in the detection and histological assessment of premalignant lesions. For example, treatment guidelines for recognizing EAC and preventing mortality are largely based on endoscopic surveillance of patients with chronic, symptomatic gastroesophageal reflux disease and those with BE as well as use of histopathological assessment to evaluate the risk of BE progression to EAC [13,14,19]. Although currently considered the gold standard for surveillance [19], white light endoscopy is limited to the surface of the mucosa and depends on clinical changes to signify underlying disease. External sources (CT/MR) typically lack sufficient resolution to provide accurate guidance for biopsy location determination.

When BE is identified, targeted biopsies and four-quadrant, random biopsies are obtained to detect invisible neoplasias [14,19,20], but these strategies may be unreliable [21] because of sampling error and other practical limitations. When performed appropriately, a random sampling technique reduces the area of tissue surveyed, covering as little as 5% of the surface area of BE tissue [22]. Mucosal irregularities of early neoplasias are often discrete and easily missed during standard BE surveillance endoscopy [20]. In surgical resection specimens, up to 43% of patients with confirmed high-grade dysplasia had adenocarcinomas that were missed before surgery, despite the use of endoscopic biopsy [23]. Given the small amounts of histologically ambiguous tissue retrieved, the potential for diagnostic misinterpretation and variability among pathologists is considerable, a problem that has been demonstrated in several studies [22,24-26]. The time delay between endoscopy and diagnosis is another limitation, with separate procedures required for the detection and treatment of dysplasia [26]. The current biopsy approach is uncomfortable and time consuming for patients, often requiring a lengthy period of sedation and posing risks of bleeding and perforation [20,27]. The limitations of current imaging and biopsy methods represent an unmet need in the early detection of mucosal dysplasias.

Current and investigational technologies for in vivo imaging

Unlike current techniques, newly developed in vivo imaging technologies offer the potential to guide biopsy and to move toward real-time pathology. These tools may enable immediate optical histology of the mucosal layer during ongoing endoscopy, or *virtual histology*, allowing visualization of living cells and cellular structure at and below the

mucosal surface [28]. Compared with conventional radiologic and endoscopic techniques, these newer technologies achieve higher-resolution microscopic images with wider-ranging visualization of the target tissue (Table 1).

Confocal laser endomicroscopy

Confocal laser endomicroscopy (CLE), a recent endoscopic advance, allows real-time high-resolution histologic analysis

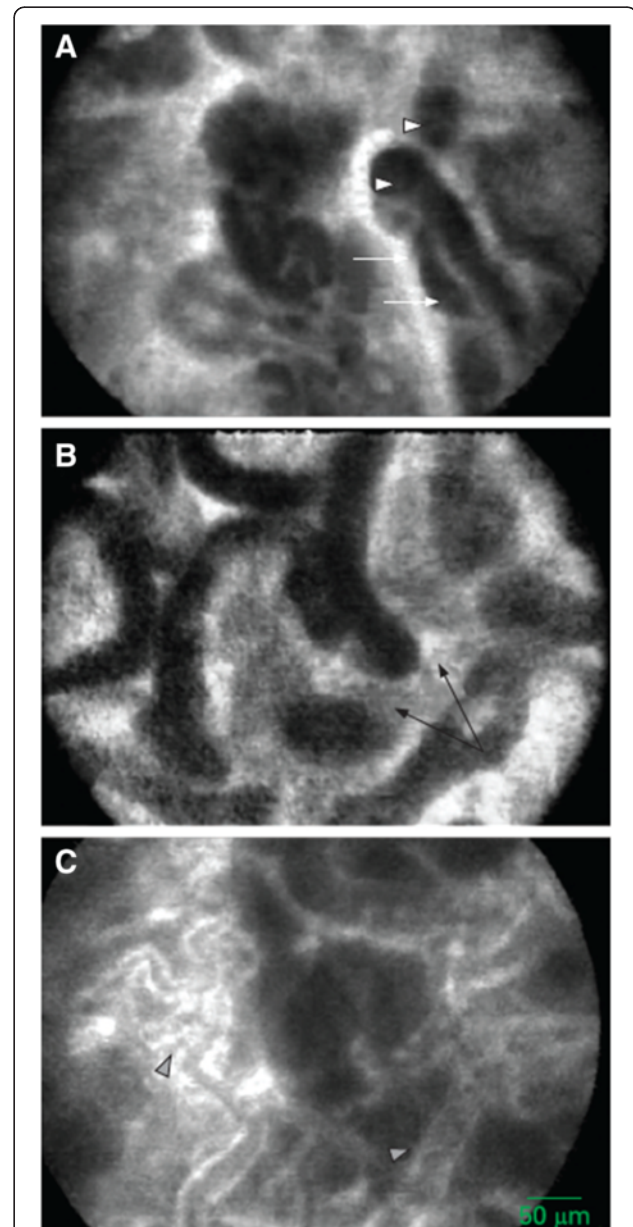


Figure 2 Barrett's mucosa with early mucosal adenocarcinoma recorded with in vivo miniprobe confocal laser microscopy.

Neoplastic characteristics include irregular epithelial lining with variable width (white arrows), increased cell density seen as dark areas with variable fluorescein uptake (white triangle), fusion of glands (black arrow), and irregular dilated blood vessels (arrowheads). Reprinted with permission from Pohl H, et al. [37].

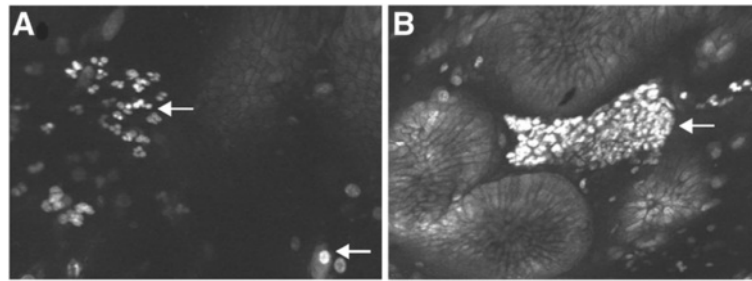


Figure 3 Neutrophils and microabscesses of *H. pylori*-positive gastric mucosa. (A) Neutrophils were identified by their nuclear features. White arrow shows the mononuclear cell. (B) Microabscesses appeared in superficial epithelium and foveola. Reprinted with permission from Ji R, et al. [43].

of targeted tissue during endoscopy [29]. The CLE illuminates tissue with a low-powered laser focused by an objective lens into a single point within a fluorescent specimen [30,31]. A confocal microscope is used to exclude light above and below a plane of interest, thus allowing for an optical section to be observed, similar to a histologic tissue section [29]. The generated gray scale image represents one focal plane within the examined specimen [31]. The mucosa typically can be imaged to a depth of 100 to 150 μm with this technique [22].

Currently, two devices are available and have received the CE Mark for use for CLE [29,32] (Figure 1 [33]), and a third is under development. The endoscope-based CLE (eCLE; Cellvizio[®], Pentax Corporation, Montvale, NJ, USA, and Tokyo, Japan) uses a confocal fluorescence microscope integrated into the distal tip of a conventional upper endoscope or colonoscope [29,30]. The probe-based CLE (pCLE; Mauna Kea Technologies, Newtown,

PA, USA, and Paris, France) uses a fiber-optic probe bundle with a laser microscope inserted through the accessory channel of a standard endoscope [29,30]. Although lateral and axial resolution is better with eCLE than with pCLE, the eCLE is considerably bulkier [29]. The pCLE is more useful in smaller spaces [29]; recent data demonstrated the feasibility of using pCLE for visualization of intra-abdominal organs, including liver, pancreas, spleen, and lymph nodes in a porcine model [34]. Development of a probe-based volumetric CLE device is under way.

Since 2004 when confocal endomicroscopy was first used for diagnosing colorectal pathology [35], CLE has shown promise in a number of clinical applications. Indeed, CLE potentially may be used in the same manner as endoscopic biopsy [36]. Both eCLE and pCLE have had high accuracy ($\geq 90\%$) in diagnosing BE and Barrett's-associated neoplastic changes (Figure 2) [37,38]. CLE also can detect lymphocytic and collagenous colitis in chronic

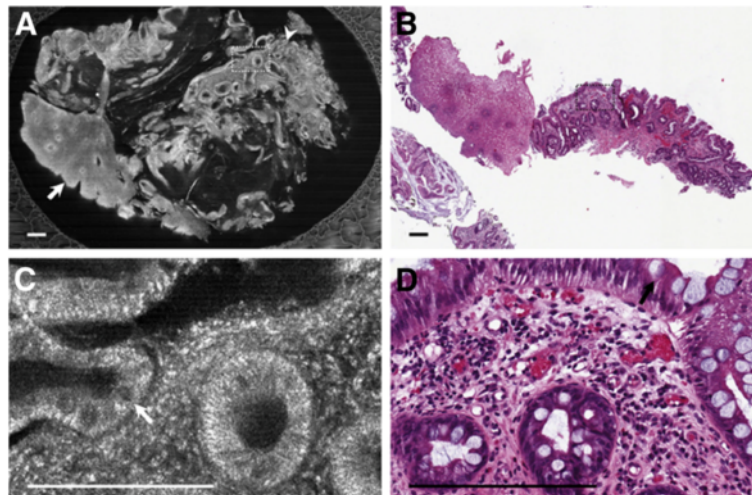


Figure 4 SECM and histopathological images of BE stained with 0.6% acetic acid. (A) Large-area SECM image shows columnar epithelium (arrowhead) and squamous epithelium (arrow). (B) Histopathologic image demonstrates squamoglandular junctional mucosa. (C) High-magnification SECM image shows the presence of goblet cells (arrow). (D) High-magnification histopathologic image shows BE with the presence of goblet cells (arrow). Scale bars represent 250 μm . Reprinted with permission from Kang D, et al. [50].

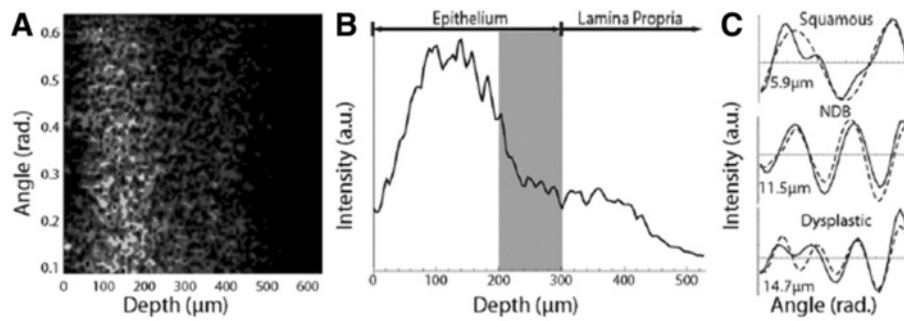


Figure 5 Comparison of depth, area, and images achieved with a/LCI and confocal microscopy. Typical a/LCI data. **(A)** Angle-resolved depth scan of light scattered from tissue. Lighter shades of gray indicate increased amount of scattered light. **(B)** Amplitude scan indicating depth increments used for processing. Tissue layers are labeled, and *gray bar* indicates basal layer (optical coherence tomography). Example angular scans for 3 tissue types pictured (solid line) with best-fit Mie theory solutions (dashed line) and size indicated. Reprinted with permission from Terry NG, et al. [26].

diarrhea [39,40], identify the microarchitecture of early gastric cancer [41,42], detect *Helicobacter pylori* infection with high accuracy (Figure 3) [43], and detect villous atrophy in celiac disease [44]. Preliminary data have shown that CLE can detect malignant changes in pancreatic tissue [45] and premalignant changes in peripheral lung nodules [46], urothelium [47], and cervical epithelium [48].

Although commercially available, the place of CLE in current diagnostic paradigms versus a conventional histopathological examination is still evolving [30]. With appropriate contrast agents, CLE has the potential for subcellular resolution, reducing the number of biopsies required [29], as well as for molecular characterization [49]. However, available CLE devices have a narrow field of view and cannot penetrate beyond the mucosa, allowing visualization of only superficial mucosal layers [29,30]. Moreover, CLE does not provide an archive of tissue for full molecular characterization [29], and contrast agents can limit the procedure duration and ability to obtain repeat images [22].

Spectrally encoded confocal microscopy

Spectrally encoded confocal microscopy (SECM) is a high-speed technique based on reflectance imaging technology [50]. This method couples broadband or wavelength-swept narrowband light into a single optical fiber, which then illuminates a transmission grating and objective lens at the end of the confocal probe to encode one-dimensional spatial information reflected from a sample [50-52]. Because SECM detects spatial information externally to the probe, it can obtain highly detailed images at very high speeds (up to 10 times faster than the video rate), while the size of the optics is small enough to be incorporated into a small-diameter catheter or endoscope [50,51]. The SECM allows for large field confocal images without the need for contrast agent and may permit the imaging of extended areas of tissue [50,51,53]. Given that SECM can achieve, in

principle, comprehensive confocal endomicroscopy of the entire distal esophagus, this technology is being investigated for imaging upper gastrointestinal (GI) tissues [50]. Preliminary assessment indicates that SECM can reveal the architectural and cellular features of gastroesophageal tissues, including the presence of goblet cells, columnar epithelium, and squamous epithelium in BE (Figure 4) [50,52]. A recent study in eosinophilic esophagitis showed that SECM of biopsy samples was functional in accurately providing eosinophil counts, as

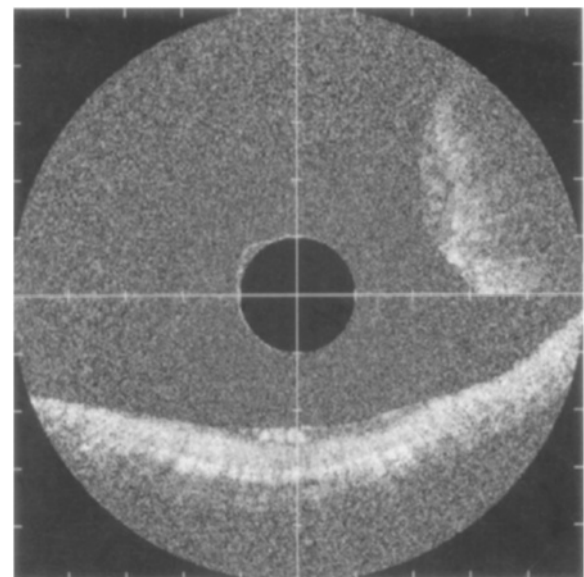


Figure 6 OCT image of colon adenoma (2-o'clock position). A well-organized linear crypt pattern is not present and image is darker because of altered light scattering compared with the nondysplastic mucosa as seen in the normal mucosa running horizontally in the 6-o'clock position. The marks of the vertical and horizontal axes are 1 mm apart. Reprinted with permission from Pfau PR, et al. [74].

well as in identifying microscopic abnormalities such as abscess, degranulation, and basal cell hyperplasia [54].

Spectroscopy-based imaging

Angle-resolved low coherence interferometry (a/LCI), a light-scattering technique, identifies early dysplasia based on nuclear diameter differences [22,26,55]. This method measures the angular distribution of scattered light as a function of depth beneath the tissue surface [26] and achieves depth resolution through a process similar to that used in optical coherence tomography (OCT) [22,26]. The a/LCI device can assess nuclear size at multiple depths [22], with deeper penetration than confocal microscopy approaches (up to 200–300 μm of the epithelial tissue layer compared with the surface and uppermost 100 μm of tissue with endoscopic confocal microscopy) [26,55]. The a/LCI data are analyzed and reported according to a best-fit analysis (Figure 5), with nuclear measurements in cell and tissue types reported with an accuracy of 0.2 to 0.3 μm [22]. The a/LCI device can provide instant high-resolution images non-invasively without the need for image interpretation by an endoscopist or administration of contrast agents [26].

Recent clinical studies have explored a/LCI in the assessment of dysplasia in esophageal [26] and intestinal [55] tissues. In the first in vivo clinical study of a/LCI, 46 patients undergoing routine endoscopic surveillance for BE were scanned with the a/LCI system and the results correlated with an endoscopic biopsy specimen [26]. The nuclear size measurements generated for deep epithelial tissue (200–300 μm beneath the surface) separated dysplastic from non-dysplastic tissue with an accuracy of 86%, using a cutoff of 11.84 μm to separate the two types [26]. Using this same cutoff, a/LCI distinguished dysplastic BE specimens from indeterminate and non-dysplastic BE with a sensitivity of 100% (13/13; 95% confidence interval [CI], 0.75–100) and a specificity of 85% (76/89; 95% CI, 0.76–0.92) [26]. Similarly, a pilot ex vivo study of 27 patients undergoing partial colonic resection demonstrated high diagnostic value of this method at a depth 200 to 300 μm beneath the mucosal surface, with a/LCI separating dysplastic from healthy intestinal tissues with a sensitivity of 92.9%, a specificity of 83.6%, and an overall accuracy of 85.2% [55].

Several other spectroscopy-based imaging techniques are under investigation in various clinical applications. Laser-induced fluorescence is a technique based on the principle that certain compounds exhibit a characteristic fluorescence emission when excited by light [56]. This technology has been shown to detect malignant colonic tissue [57] and to distinguish malignant tissue from metaplastic and normal tissue in BE [56,58]. Multimodal hyperspectroscopy is based on tissue fluorescence and reflected light measurements, which are analyzed with computer-based algorithms to differentiate between abnormal and

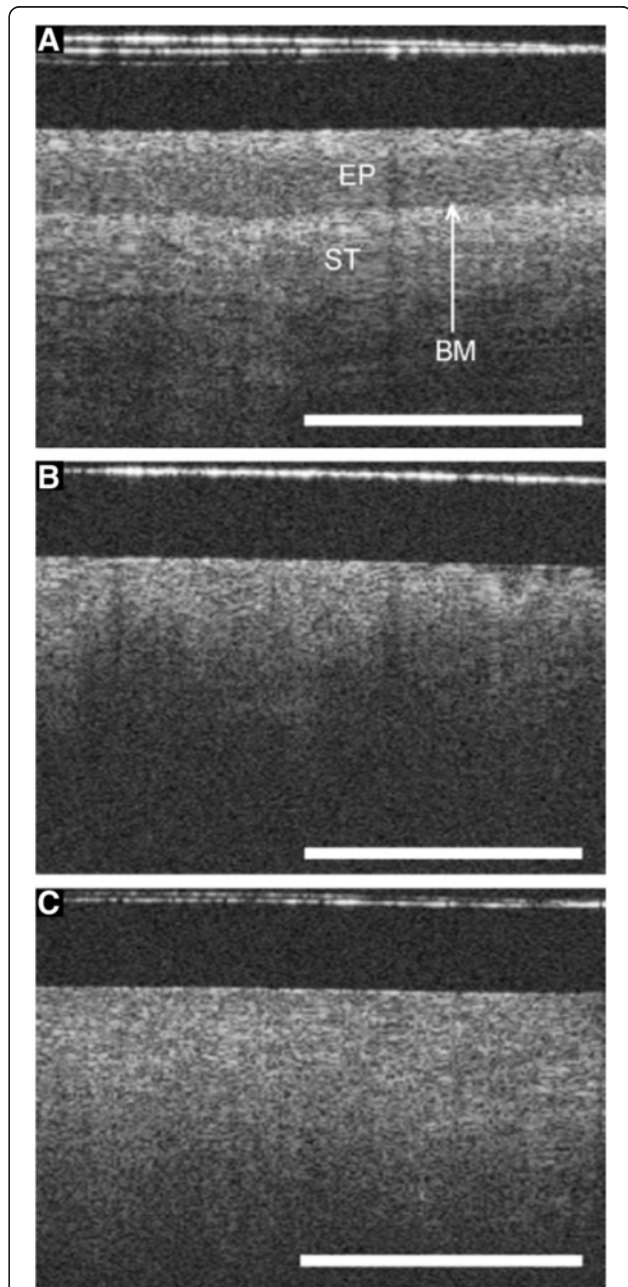


Figure 7 Optical coherence tomography (OCT) images. (A) OCT image of normal cervical tissue, showing a well-organized, three-layer architecture (optical structure) with sharp borders. The thin basement membrane (BM) could not be resolved by OCT. However, because the basement membrane separates the epithelium (EP) from stroma (ST), a sharp interface could be visualized (length of the white bar: 1 mm). (B) OCT image showing a cervical intraepithelial neoplasia (CIN-3) lesion. The intensity of the stromal layer increases with less-organized layer architecture. The stroma seemed to push its way towards the surface as vertical columns. (C) OCT image showing invasive carcinoma. The tissue surface is an unstructured homogeneous highly backscattering region with a complete lack of layer architecture (optical structure). The basement membrane is no longer intact or defined and the tissue microstructure is no longer organized. Reprinted with permission from Gallwas J, et al. [76].

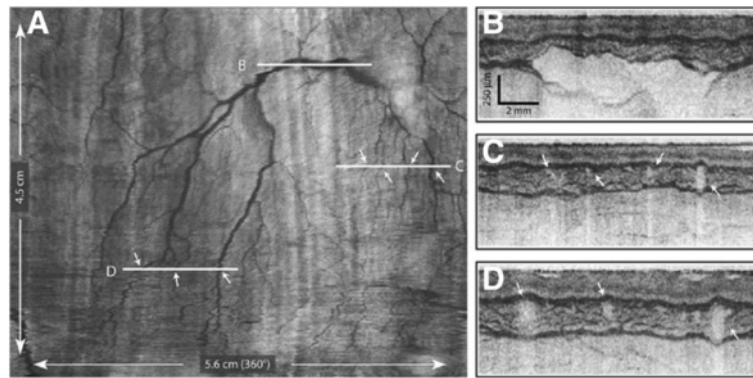


Figure 8 High-resolution images from VLE. (A) A comprehensive vascular map derived from the structural image set. (B–D) Cross-sectional images at the indicated locations. Arrows indicate corresponding vessels in the vascular map and cross-sectional images. Reprinted with permission from Vakoc BJ, et al. [70].

normal tissues [59]. Although more extensively explored for use in detecting cervical cancer [59,60], clinical studies in BE patients are under way [61].

Optical coherence tomography

OCT is an imaging technique first introduced for use in biological tissues in 1991 [62] that generates high-resolution, cross-sectional, subsurface images by using low-coherence interferometry to measure the echo time delay and intensity of back-scattered light [63]. OCT is analogous to ultrasonography, except that OCT measures the intensity of infrared light rather than sound waves [64]. With OCT, depth intensity is measured by time-domain measurements, allowing for image construction for all three dimensions.

Since its use was first described in ophthalmology to image the transparent structures of the anterior eye and retina [65], OCT has evolved to include a wide spectrum of clinical applications. The successful use of OCT imaging techniques has been described in many biologic tissues, including human coronary arteries [66,67]; esophageal [68-71], gastric [72,73], and intestinal [74] tissues (Figure 6); pancreatic and biliary tissues [75]; cervical epithelium (Figure 7) [76]; and urologic tissues [77]. Extensively studied in GI applications [72,74,78], OCT has shown accuracy in diagnosing specialized intestinal metaplasia in BE with a sensitivity of 81% [71,79].

Several OCT systems are currently in use or under investigation. The original OCT technology, now called time-domain OCT (Niris[®], Imalux Corporation, Cleveland, OH, USA) [80,81], has been described in detail elsewhere [64,78]. Interferometric synthetic aperture microscopy uses computed imaging and synthetic aperture techniques to modify OCT signals to achieve three-dimensional, spatially invariant resolution for all depths in a cross-sectional scan [82-84]. The feasibility of using this

technology to image human breast tissue has recently been demonstrated [83,84].

Despite the diagnostic potential of time-domain OCT, its relatively slow imaging speed has precluded its ability to survey large areas of the GI tract, limiting its use to point-sampling with a field of view comparable to that of conventional biopsy [70,85]. However, a new technological approach to OCT allows dramatic increases in imaging speed without compromising image resolution or

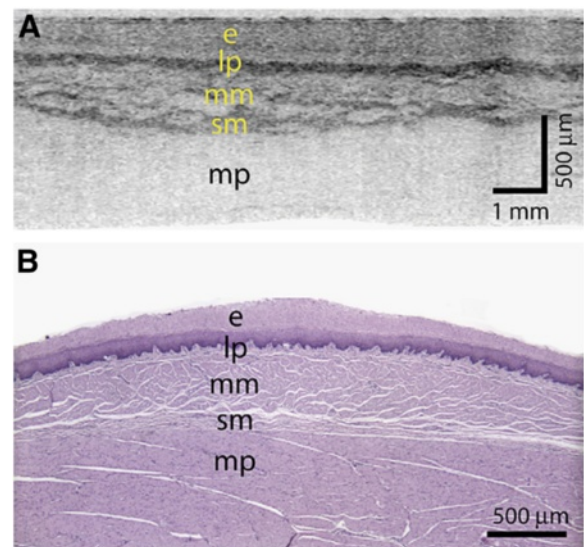


Figure 9 High-resolution images from VLE. (A) A transverse cross-sectional image showing all architectural layers of the squamous mucosa, including the epithelium (e), lamina propria (lp), muscularis mucosa (mm), submucosa (sm), and muscularis propria (mp); because of the large change in esophageal circumference during imaging (56 mm) and after resection (~22 mm), the cross-sectional image is displayed over a proportionately larger width. (B) Representative histology from the same swine (H&E, orig. mag. x2). Reprinted with permission from Vakoc BJ, et al. [70].

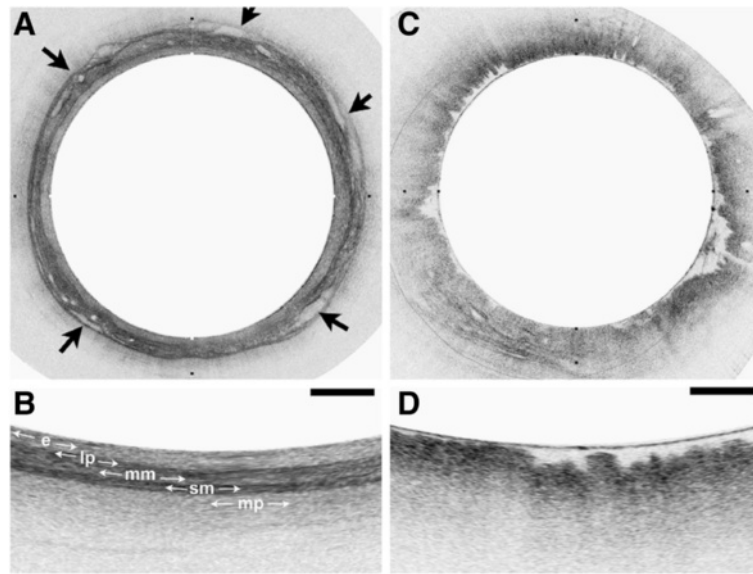


Figure 10 OFDI images obtained from patients with a normal-appearing stomach and esophagus by endoscopy. **(A)** OFDI image of squamous mucosa. **(B)** Expanded view of A demonstrates a layered appearance, including the epithelium (e), lamina propria (lp), muscularis mucosa (mm), submucosa (sm), and muscularis propria (mp). Vessels are clearly identified in the submucosa (arrows). **(C)** OFDI image of gastric cardia. **(D)** Expanded view of C demonstrates vertical pit and crypts, regular, broad architecture, high surface backscattering, and diminished image penetration. Tick marks in **A** and **C** and scale bars in **B** and **D** represent 1 mm. Reprinted with permission from Suter MJ, et al. [68].

quality [70,86-88]. This technology, referred to as Fourier-domain OCT [81] or optical frequency domain imaging [70], is also called volumetric laser endomicroscopy (VLE). VLE acquires cross-sectional images by using a focused, narrow-diameter beam to repeatedly

measure the delay of reflections from within the tissue sample [70]. Interferometry is used to measure the delay intervals, while Fourier transformation is used to compute traditional A-lines, or depth scans, which comprise the tissue reflectivity as a function of depth along the

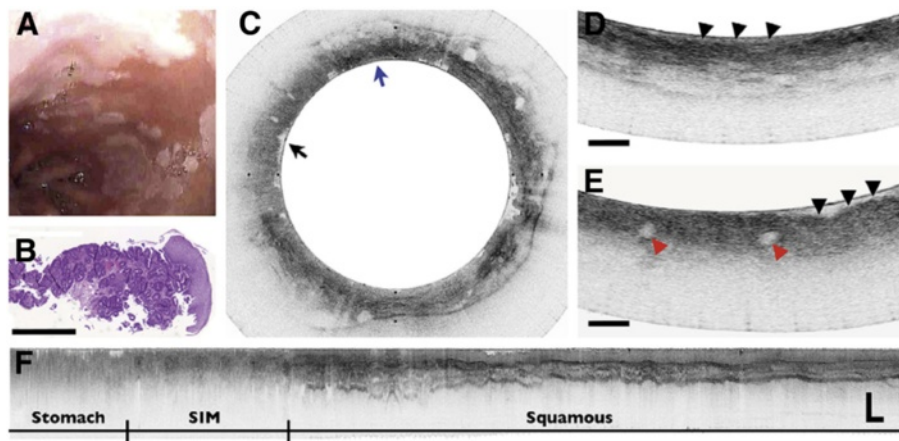


Figure 11 Barrett's esophagus with dysplasia. **(A)** Videoendoscopic image reveals a patchy mucosa consistent with SIM. **(B)** Histopathologic image of the biopsy specimen taken from the SCJ demonstrates intestinal metaplasia and low-grade dysplasia (H&E, orig. mag. $\times 2$). **(C)** Cross-sectional OFDI image demonstrating regions consistent with SIM without dysplasia (blue arrow) and specialized intestinal metaplasia with high grade dysplasia (black arrow). **(D)** Expanded view of **C** taken from the region denoted by the blue arrow in **C**, demonstrating good surface maturation (arrowheads), which is consistent with SIM without dysplasia. **(E)** Expanded view of **C** taken from the region denoted by the black arrow in **C**, demonstrating features consistent with high grade dysplasia, including poor surface maturation (black arrowheads) and the presence of dilated glands (red arrowheads) in the mucosa. **(F)** A longitudinal slice highlights the transition from gastric cardia, through a 9-mm segment of specialized intestinal metaplasia and finally into squamous mucosa. Scale bars and tick marks represent 1 mm. Reprinted with permission from Suter MJ, et al. [68].

beam. Unlike time-domain OCT, VLE uses a fixed wavelength or swept-source technology in which the wavelength of a monochromatic light source is rapidly scanned to measure the interference signal as a function of wavelength [70,87].

The use of a balloon-based VLE system with helically scanning optics for esophageal imaging has been described [68-70,85]. With this system, the optical components of the catheter are positioned with the esophageal lumen via a balloon-centered probe [70,85]. After the balloon is inflated, the distal esophagus is dilated and the imaging optics become centered. Optics are slowly pulled back during the imaging procedure while the imaging optics are rotated by a probe scanner; thus, the entire portion of the esophageal lumen that was in contact with the balloon is scanned in a helical or circumferential fashion [70]. Real-time, volumetric images are obtained by scanning the imaging beam over the tissue surface in two dimensions [69].

Preliminary data for the VLE system have shown its ability to image the entire distal esophagus at a higher speed and greater sensitivity compared with time-domain OCT [70,85]. VLE enables full-length surveillance of target areas with a combination of resolution and depth of surface penetration (3-mm penetration, <10- μ m resolution depth) [52]. When used in swine models, VLE provided high-resolution images of the anatomic layers and vasculature from the distal esophagus and gastroesophageal junction (Figures 8 and 9) [70]. In the first clinical experience with this technique, VLE successfully imaged the microscopic architecture of the distal esophagus in 10 of 12 patients undergoing routine esophagoduodenostomy for BE screening and surveillance (Figures 10 and 11), with volumetric images acquired in less than 2 minutes [68]. Most recently, the feasibility of VLE-guided biopsy with laser marking was demonstrated in swine esophagus, a strategy with the potential to increase the diagnostic accuracy of current surveillance protocols and to guide interventional treatments [69].

Roles and impact of the advances in optical biopsy

In vivo pathology imaging devices and the rapid evolution of the technology have the potential to make real-time diagnosis the new standard, with immediate diagnosis and management during endoscopy. The new optical biopsy technologies provide better quality, detailed, high-resolution images and allow visualization of living cells and cellular structures at and below the mucosal surface during ongoing endoscopy [28,35]. The convergence of imaging and pathology may provide distinct advantages in cancer detection and diagnosis without the limitations and risks inherent with biopsy procedures. With these technologies, maximal diagnostic yields may be obtained, leading to appropriate

staging through guided biopsy while minimizing the frequency and error potential of random biopsy protocols. In vivo cellular information can be delivered before biopsies are performed, or imaging files may be transmitted with biopsies, potentially improving the efficiency and accuracy of diagnosis.

Despite the potential these techniques may offer to standard clinical practice, barriers remain. Optical biopsy techniques can identify neoplastic changes in a variety of biologic tissues, but prospective studies in large cohorts are needed to establish concrete sensitivity and specificity of the respective technologies, in each target organ, versus the need for biopsy. To achieve widespread clinical adoption, these technologies must be accurate, efficient for use in the endoscopic setting, reliable, user-friendly, patient-friendly, and cost-effective [22,89]. Wide acceptance and interpretation capabilities, which require comprehensive physician education and training, are also necessary to establish appropriate comfort with use. Investigators are currently working to improve the accuracy, speed, and ease of interpretation of these technologies [89]. In addition, research is under way to allow real-time data transmission and storage, thereby linking pathology results to the treating physician.

Conclusion

As epithelial malignancies move toward earlier detection and treatment, the ability to accurately detect precancerous lesions has an increasingly important role in controlling cancer incidence and mortality. With new optical techniques, high-resolution images of early neoplastic changes in various tissues and organs can now be captured in real time through endoscopes, catheters, laparoscopes, and needles [78]. Although the diagnostic potential of these technologies is rapidly expanding, their clinical adoption will depend on present and future research demonstrating improved imaging performance and functionality, and the development and acceptance of new guidelines for imaging [78]. Novel optical imaging technology offers the opportunity to utilize a see-and-treat paradigm, potentially leading to improved patient care and cost reduction.

Abbreviations

a/LCI: Angle-resolved low-coherence interferometry; BE: Barrett's esophagus; CI: Confidence interval; CLE: Confocal laser endomicroscopy; CT: Computed tomography; EAC: Esophageal adenocarcinoma; eCLE: Endoscope-based confocal laser endomicroscopy; GI: Gastrointestinal; MR: Magnetic resonance; OCT: Optical coherence tomography; pCLE: Probe-based confocal laser endomicroscopy; SECM: Spectrally encoded confocal microscopy; VLE: Volumetric laser endomicroscopy.

Competing interests

CSC is an employee of NinePoint Medical. YY has no competing interests to declare.

Authors' contributions

CSC and YY made substantial contributions to the conception and design of this review and were involved in drafting the manuscript or revising it critically for important intellectual content. Both authors have given final approval of the version to be published.

Acknowledgements

We thank Albert Balkiewicz, MSc, who provided medical writing services through Peloton Advantage, LLC, on behalf of the authors and NinePoint Medical. The authors were fully responsible for the content, editorial decisions, and opinions expressed in the current article. Neither author received an honorarium related to the development of this manuscript.

Author details

¹NinePoint Medical, One Kendall Square B7501, Cambridge, MA 02139, USA.

²Massachusetts General Hospital and Harvard Medical School, 101 Merrimac St. Suite 820, Boston, MA 02114, USA.

Received: 25 April 2012 Accepted: 19 July 2012

Published: 13 August 2012

References

1. Vizcaino AP, Moreno V, Lambert R, Parkin DM: **Time trends incidence of both major histologic types of esophageal carcinomas in selected countries, 1973–1995.** *Int J Canc* 2002, **99**(6):860–868.
2. Brown LM, Devesa SS, Chow WH: **Incidence of adenocarcinoma of the esophagus among white Americans by sex, stage, and age.** *J Natl Cancer Inst* 2008, **100**(16):1184–1187.
3. Melhado RE, Alderson D, Tucker O: **The changing face of esophageal cancer.** *Cancers* 2010, **2**:1379–1404.
4. Lepage C, Rachet B, Jooste V, Faivre J, Coleman MP: **Continuing rapid increase in esophageal adenocarcinoma in England and Wales.** *Am J Gastroenterol* 2008, **103**(11):2694–2699.
5. Botterweck AA, Schouten LJ, Volovics A, Dorant E, van Den Brandt PA: **Trends in incidence of adenocarcinoma of the oesophagus and gastric cardia in ten European countries.** *Int J Epidemiol* 2000, **29**(4):645–654.
6. Falk J, Carstens H, Lundell L, Albertsson M: **Incidence of carcinoma of the oesophagus and gastric cardia. Changes over time and geographical differences.** *Acta Oncol* 2007, **46**(8):1070–1074.
7. SEER Stat Fact Sheets: *Esophagus Cancer. National Cancer Institute Surveillance Epidemiology and End Results.* 2011. <http://seer.cancer.gov/statfacts/html/esoph.html>. Accessed December 5.
8. Vital signs: **colorectal cancer screening, incidence, and mortality—United States, 2002–2010.** *MMWR Morb Mortal Wkly Rep* 2011, **60**(26):884–889.
9. Trends in age-adjusted SEER incidence rates by cancer site all ages, all races, female 1992–2008 (SEER 13) Cervix Uteri: *Trends in age-adjusted SEER incidence rates by cancer site all ages, all races, female 1992–2008 (SEER 13) Cervix Uteri. National Cancer Institute Surveillance Epidemiology and End Results.* 2011. <http://seer.cancer.gov/faststats/selections.php?#Output>. Accessed November 29, 2011.
10. Schlansky B, Sonnenberg A: **Epidemiology of noncardia gastric adenocarcinoma in the United States.** *Am J Gastroenterol* 2011, **106**(11):1978–1985.
11. Ferlay J, Shin HR, Bray F, Forman D, Mathers C, Parkin DM: **Estimates of worldwide burden of cancer in 2008: GLOBOCAN 2008.** *Int J Cancer* 2010, **127**(12):2893–2917.
12. National Cancer Institute: *Cervical cancer screening (PDQ).* 2011. <http://www.cancer.gov/cancertopics/pdq/screening/cervical/HealthProfessional>. Accessed December 5, 2011.
13. Wang KK, Sampliner RE: **Updated guidelines 2008 for the diagnosis, surveillance and therapy of Barrett's esophagus.** *Am J Gastroenterol* 2008, **103**(3):788–797.
14. Hirota WK, Zuckerman MJ, Adler DG, Davila RE, Egan J, Leighton JA, Qureshi WA, Rajan E, Fanelli R, Wheeler-Harbaugh J, Baron TH, Faigel DO: **ASGE guideline: the role of endoscopy in the surveillance of premalignant conditions of the upper GI tract.** *Gastrointest Endosc* 2006, **63**(4):570–580.
15. Wong T, Tian J, Nagar AB: **Barrett's surveillance identifies patients with early esophageal adenocarcinoma.** *Am J Med* 2010, **123**(5):462–467.
16. Portale G, Hagen JA, Peters JH, Chan LS, DeMeester SR, Gandamihardja TA, DeMeester TR: **Modern 5-year survival of resectable esophageal adenocarcinoma: single institution experience with 263 patients.** *J Am Coll Surg* 2006, **202**(4):588–596.
17. Rubenstein JH, Sonnenberg A, Davis J, McMahon L, Inadomi JM: **Effect of a prior endoscopy on outcomes of esophageal adenocarcinoma among United States veterans.** *Gastrointest Endosc* 2008, **68**(5):849–855.
18. van Sandick JW, van Lanschot JJ, Kuiken BW, Tytgat GN, Offerhaus GJ, Obertop H: **Impact of endoscopic biopsy surveillance of Barrett's oesophagus on pathological stage and clinical outcome of Barrett's carcinoma.** *Gut* 1998, **43**(2):216–222.
19. Spechler SJ, Sharma P, Souza RF, Inadomi JM, Shaheen NJ: **American Gastroenterological Association medical position statement on the management of Barrett's esophagus.** *Gastroenterology* 2011, **140**(3):1084–1091.
20. Pohl J, Pech O, May A, Manner H, Fissler-Eckhoff A, Ell C: **Incidence of macroscopically occult neoplasias in Barrett's esophagus: are random biopsies dispensable in the era of advanced endoscopic imaging?** *Am J Gastroenterol* 2010, **105**(11):2350–2356.
21. Canto MI, Kalloo A: **Chromoendoscopy for Barrett's esophagus in the twenty-first century: to stain or not to stain?** *Gastrointest Endosc* 2006, **64**(2):200–205.
22. Wax A, Terry NG, Dellon ES, Shaheen NJ: **Angle-resolved low coherence interferometry for detection of dysplasia in Barrett's esophagus.** *Gastroenterology* 2011, **141**(2):443–447.
23. Heitmiller RF, Redmond M, Hamilton SR: **Barrett's esophagus with high-grade dysplasia. An indication for prophylactic esophagectomy.** *Ann Surg* 1996, **224**(1):66–71.
24. Montgomery E, Bronner MP, Goldblum JR, Greenson JK, Haber MM, Hart J, Lamps LW, Lauwers GY, Lazenby AJ, Lewin DN, Robert ME, Toledano AY, Shyr Y, Washington K: **Reproducibility of the diagnosis of dysplasia in Barrett esophagus: a reaffirmation.** *Hum Pathol* 2001, **32**(4):368–378.
25. Reid BJ, Li X, Galipeau PC, Vaughan TL: **Barrett's oesophagus and oesophageal adenocarcinoma: time for a new synthesis.** *Nat Rev Cancer* 2010, **10**(2):87–101.
26. Terry NG, Zhu Y, Rinehart MT, Brown WJ, Gebhart SC, Bright S, Carretta E, Ziefle CG, Panjehpour M, Galanko J, Madanick RD, Dellon ES, Trembath D, Bennett A, Goldblum JR, Overholt BF, Woosley JT, Shaheen NJ, Wax A: **Detection of dysplasia in Barrett's esophagus with in vivo depth-resolved nuclear morphology measurements.** *Gastroenterology* 2011, **140**(1):42–50.
27. Bergman JJ, Tytgat GN: **New developments in the endoscopic surveillance of Barrett's oesophagus.** *Gut* 2005, **54**(Suppl 1):i38–i42.
28. Kiesslich R, Goetz M, Neurath MF: **Virtual histology.** *Best Pract Res Clin Gastroenterol* 2008, **22**(5):883–897.
29. Paull PE, Hyatt BJ, Wassef W, Fischer AH: **Confocal laser endomicroscopy: a primer for pathologists.** *Arch Pathol Lab Med* 2011, **135**(10):1343–1348.
30. Kantsevov SV, Adler DG, Conway JD, Diehl DL, Farraye FA, Kaul V, Kethu SR, Kwon RS, Mamula P, Rodriguez SA, Tierney WM: **Confocal laser endomicroscopy.** *Gastrointest Endosc* 2009, **70**(2):197–200.
31. De Palma GD: **Confocal laser endomicroscopy in the "in vivo" histological diagnosis of the gastrointestinal tract.** *World J Gastroenterol* 2009, **15**(46):5770–5775.
32. Wallace MB, Fockens P: **Probe-based confocal laser endomicroscopy.** *Gastroenterology* 2009, **136**(5):1509–1513.
33. Goetz M, Kiesslich R: **Advanced imaging of the gastrointestinal tract: research vs. clinical tools?** *Curr Opin Gastroenterol* 2009, **25**(5):412–421.
34. Becker V, Wallace MB, Fockens P, von Delius S, Woodward TA, Raimondo M, Voermans RP, Meining A: **Needle-based confocal endomicroscopy for in vivo histology of intra-abdominal organs: first results in a porcine model (with videos).** *Gastrointest Endosc* 2010, **71**(7):1260–1266.
35. Kiesslich R, Burg J, Vieth M, Gnaendiger J, Enders M, Delaney P, Polglase A, McLaren W, Janell D, Thomas S, Nafe B, Galle PR, Neurath MF: **Confocal laser endoscopy for diagnosing intraepithelial neoplasias and colorectal cancer in vivo.** *Gastroenterology* 2004, **127**(3):706–713.
36. De Palma GD: **Confocal laser endomicroscopy in the "in vivo" histological diagnosis of the gastrointestinal tract.** *World J Gastroenterol* 2009, **15**(46):5770–5775.
37. Pohl H, Rosch T, Vieth M, Koch M, Becker V, Anders M, Khalifa AC, Meining A: **Miniprobe confocal laser microscopy for the detection of invisible neoplasia in patients with Barrett's oesophagus.** *Gut* 2008, **57**(12):1648–1653.
38. Kiesslich R, Gossner L, Goetz M, Dahlmann A, Vieth M, Stolte M, Hoffman A, Jung M, Nafe B, Galle PR, Neurath MF: **In vivo histology of Barrett's**

- esophagus and associated neoplasia by confocal laser endomicroscopy. *Clin Gastroenterol Hepatol* 2006, **4**(8):979–987.
39. Meining A, Schwendy S, Becker V, Schmid RM, Prinz C: **In vivo histopathology of lymphocytic colitis.** *Gastrointest Endosc* 2007, **66**(2):398–399.
40. Kiesslich R, Hoffman A, Goetz M, Biesterfeld S, Vieth M, Galle PR, Neurath MF: **In vivo diagnosis of collagenous colitis by confocal endomicroscopy.** *Gut* 2006, **55**(4):591–592.
41. Kitabatake S, Niwa Y, Miyahara R, Ohashi A, Matsuura T, Iguchi Y, Shimoyama Y, Nagasaka T, Maeda O, Ando T, Ohmiya N, Itoh A, Hirooka Y, Goto H: **Confocal endomicroscopy for the diagnosis of gastric cancer in vivo.** *Endoscopy* 2006, **38**(11):1110–1114.
42. Liu H, Li YQ, Yu T, Zhao YA, Zhang JP, Zhang JN, Guo YT, Xie XJ, Zhang TG, Desmond PV: **Confocal endomicroscopy for in vivo detection of microvascular architecture in normal and malignant lesions of upper gastrointestinal tract.** *J Gastroenterol Hepatol* 2008, **23**(1):56–61.
43. Ji R, Li YQ, Gu XM, Yu T, Zuo XL, Zhou CJ: **Confocal laser endomicroscopy for diagnosis of Helicobacter pylori infection: a prospective study.** *J Gastroenterol Hepatol* 2010, **25**(4):700–705.
44. Venkatesh K, Abou-Taleb A, Cohen M, Evans C, Thomas S, Oliver P, Taylor C, Thomson M: **Role of confocal endomicroscopy in the diagnosis of celiac disease.** *J Pediatr Gastroenterol Nutr* 2010, **51**(3):274–279.
45. Meining A, Phillip V, Gaa J, Prinz C, Schmid RM: **Pancreaticoscopy with miniprobe-based confocal laser-scanning microscopy of an intraductal papillary mucinous neoplasm (with video).** *Gastrointest Endosc* 2009, **69**(6):1178–1180.
46. Thiberville L, Salaun M, Lachkar S, Dominique S, Moreno-Swiric S, Vever-Bizet C, Bourg-Heckly G: **Human in vivo fluorescence microimaging of the alveolar ducts and sacs during bronchoscopy.** *Eur Respir J* 2009, **33**(5):974–985.
47. Sonn GA, Jones SN, Tarin TV, Du CB, Mach KE, Jensen KC, Liao JC: **Optical biopsy of human bladder neoplasia with in vivo confocal laser endomicroscopy.** *J Urol* 2009, **182**(4):1299–1305.
48. Tan J, Quinn MA, Pyman JM, Delaney PM, McLaren WJ: **Detection of cervical intraepithelial neoplasia in vivo using confocal endomicroscopy.** *BJOG* 2009, **116**(12):1663–1670.
49. Goetz M, Kiesslich R: **Advances of endomicroscopy for gastrointestinal physiology and diseases.** *Am J Physiol Gastrointest Liver Physiol* 2010, **298**(6):G797–G806.
50. Kang D, Suter MJ, Boudoux C, Yoo H, Yachimski PS, Puricelli WP, Nishioka NS, Mino-Kenudson M, Lauwers GY, Bouma BE, Tearney GJ: **Comprehensive imaging of gastroesophageal biopsy samples by spectrally encoded confocal microscopy.** *Gastrointest Endosc* 2010, **71**(1):35–43.
51. Tearney GJ, Webb RH, Bouma BE: **Spectrally encoded confocal microscopy.** *Opt Lett* 1998, **23**(15):1152–1154.
52. Kang DK, Suter MJ, Boudoux C, Yachimski PS, Puricelli WP, Nishioka NS, Mino-Kenudson M, Lauwers GY, Bouma BE, Tearney GJ: **Co-registered spectrally encoded confocal microscopy and optical frequency domain imaging system.** *J Microsc* 2010, **239**(2):87–91.
53. Boudoux C, Yun S, Oh W, White W, Ifimia N, Shishkov M, Bouma B, Tearney G: **Rapid wavelength-swept spectrally encoded confocal microscopy.** *Opt Express* 2005, **13**(20):8214–8221.
54. Yoo H, Kang D, Katz AJ, Lauwers GY, Nishioka NS, Yagi Y, Tanpowpong P, Namati J, Bouma BE, Tearney GJ: **Reflectance confocal microscopy for the diagnosis of eosinophilic esophagitis: a pilot study conducted on biopsy specimens.** *Gastrointest Endosc* 2011, **74**(5):992–1000.
55. Terry N, Zhu Y, Thacker JK, Migaly J, Guy C, Mantyh CR, Wax A: **Detection of intestinal dysplasia using angle-resolved low coherence interferometry.** *J Biomed Opt* 2011, **16**(10):106002.
56. Panjehpour M, Overholt BF, Schmidhammer JL, Farris C, Buckley PF, Vo-Dinh T: **Spectroscopic diagnosis of esophageal cancer: new classification model, improved measurement system.** *Gastrointest Endosc* 1995, **41**(6):577–581.
57. Schomacker KT, Frisoli JK, Compton CC, Flotte TJ, Richter JM, Nishioka NS, Deutsch TF: **Ultraviolet laser-induced fluorescence of colonic tissue: basic biology and diagnostic potential.** *Lasers Surg Med* 1992, **12**(1):63–78.
58. von Holstein CS, Nilsson AM, Andersson-Engels S, Willen R, Walther B, Svanberg K: **Detection of adenocarcinoma in Barrett's oesophagus by means of laser induced fluorescence.** *Gut* 1996, **39**(5):711–716.
59. Ferris DG, Lawhead RA, Dickman ED, Holtzapple N, Miller JA, Grogan S, Bambot S, Agrawal A, Faupel ML: **Multimodal hyperspectral imaging for the noninvasive diagnosis of cervical neoplasia.** *J Low Genit Tract Dis* 2001, **5**(2):65–72.
60. Ferris DG, Litaker MS, Dickman ED, Allmond LM, Smith KM, Arrington TL: **Women's responses to cervical interrogation by fluorescent and reflective spectroscopy.** *J Low Genit Tract Dis* 2003, **7**(4):299–303.
61. Guided Therapeutics: *Guided Therapeutics begins human feasibility clinical study for light-based Barrett's esophagus technology jointly developed with Konica Minolta Opto.* 2011. Accessed December 5, 2011.
62. Huang D, Swanson EA, Lin CP, Schuman JS, Stinson WG, Chang W, Hee MR, Flotte T, Gregory K, Puliafito CA: **Optical coherence tomography.** *Science* 1991, **254**(5035):1178–1181.
63. Testoni PA: **Optical coherence tomography.** *Sci World J* 2007, **7**:87–108.
64. Tearney GJ, Brezinski ME, Bouma BE, Boppart SA, Pitris C, Southern JF, Fujimoto JG: **In vivo endoscopic optical biopsy with optical coherence tomography.** *Science* 1997, **276**(5321):2037–2039.
65. Hee MR, Puliafito CA, Wong C, Duker JS, Reichel E, Rutledge B, Schuman JS, Swanson EA, Fujimoto JG: **Quantitative assessment of macular edema with optical coherence tomography.** *Arch Ophthalmol* 1995, **113**(8):1019–1029.
66. Gogas BD, Farooq V, Onuma Y, Magro M, Radu MD, van Geuns RJ, Regar E, Serruys PW: **3-Dimensional optical frequency domain imaging for the evaluation of primary percutaneous coronary intervention in ST-segment elevation myocardial infarction.** *Int J Cardiol* 2011, **151**(1):103–105.
67. Okamura T, Onuma Y, Garcia-Garcia HM, van Geuns RJ, Wykrzykowska JJ, Schultz C, van der Giessen WJ, Ligthart J, Regar E, Serruys PW: **First-in-man evaluation of intravascular optical frequency domain imaging (OFDI) of Terumo: a comparison with intravascular ultrasound and quantitative coronary angiography.** *Euro Intervention* 2011, **6**(9):1037–1045.
68. Suter MJ, Vakoc BJ, Yachimski PS, Shishkov M, Lauwers GY, Mino-Kenudson M, Bouma BE, Nishioka NS, Tearney GJ: **Comprehensive microscopy of the esophagus in human patients with optical frequency domain imaging.** *Gastrointest Endosc* 2008, **68**(4):745–753.
69. Suter MJ, Jillella PA, Vakoc BJ, Halpern EF, Mino-Kenudson M, Lauwers GY, Bouma BE, Nishioka NS, Tearney GJ: **Image-guided biopsy in the esophagus through comprehensive optical frequency domain imaging and laser marking: a study in living swine.** *Gastrointest Endosc* 2010, **71**(2):346–353.
70. Vakoc BJ, Shishko M, Yun SH, Oh WY, Suter MJ, Desjardins AE, Evans JA, Nishioka NS, Tearney GJ, Bouma BE: **Comprehensive esophageal microscopy by using optical frequency-domain imaging (with video).** *Gastrointest Endosc* 2007, **65**(6):898–905.
71. Evans JA, Bouma BE, Bressner J, Shishkov M, Lauwers GY, Mino-Kenudson M, Nishioka NS, Tearney GJ: **Identifying intestinal metaplasia at the squamocolumnar junction by using optical coherence tomography.** *Gastrointest Endosc* 2007, **65**(1):50–56.
72. Sivak MV Jr, Kobayashi K, Izatt JA, Rollins AM, Ung-Runyawee R, Chak A, Wong RC, Isenberg GA, Willis J: **High-resolution endoscopic imaging of the GI tract using optical coherence tomography.** *Gastrointest Endosc* 2000, **51**(4 Pt 1):474–479.
73. Poneros JM, Brand S, Bouma BE, Tearney GJ, Compton CC, Nishioka NS: **Diagnosis of specialized intestinal metaplasia by optical coherence tomography.** *Gastroenterology* 2001, **120**(1):7–12.
74. Pfau PR, Sivak MV Jr, Chak A, Kinnard M, Wong RC, Isenberg GA, Izatt JA, Rollins A, Westphal V: **Criteria for the diagnosis of dysplasia by endoscopic optical coherence tomography.** *Gastrointest Endosc* 2003, **58**(2):196–202.
75. Testoni PA, Mangiavillano B: **Optical coherence tomography in detection of dysplasia and cancer of the gastrointestinal tract and bilio-pancreatic ductal system.** *World J Gastroenterol* 2008, **14**(42):6444–6452.
76. Gallwas J, Turk L, Frieze K, Dannecker C: **Optical coherence tomography as a non-invasive imaging technique for preinvasive and invasive neoplasia of the uterine cervix.** *Ultrasound Obstet Gynecol* 2010, **36**(5):624–629.
77. Tearney GJ, Brezinski ME, Southern JF, Bouma BE, Boppart SA, Fujimoto JG: **Optical biopsy in human urologic tissue using optical coherence tomography.** *J Urol* 1997, **157**(5):1915–1919.
78. Fujimoto JG: **Optical coherence tomography for ultrahigh resolution in vivo imaging.** *Nat Biotechnol* 2003, **21**(11):1361–1367.
79. Eloubeidi MA, Provenzale D: **Does this patient have Barrett's esophagus? The utility of predicting Barrett's esophagus at the index endoscopy.** *Am J Gastroenterol* 1999, **94**(4):937–943.

80. Imalux Corporation: *Niris principles of operation*. 2011. <http://www.imalux.com/principles.htm>. Accessed December 5, 2011.
81. Bouma BE, Yun SH, Vakoc BJ, Suter MJ, Tearney GJ: **Fourier-domain optical coherence tomography: recent advances toward clinical utility**. *Curr Opin Biotechnol* 2009, **20**(1):111–118.
82. Davis BJ, Marks DL, Ralston TS, Carney PS, Boppart SA: **Interferometric synthetic aperture microscopy: computed imaging for scanned coherent microscopy**. *Sensors Basel Sensors* 2008, **8**(6):3903–3931.
83. Ralston TS, Marks DL, Carney PS, Boppart SA: **Real-time interferometric synthetic aperture microscopy**. *Opt Express* 2008, **16**(4):2555–2569.
84. Ralston TS, Marks DL, Carney PS, Boppart SA: **Interferometric synthetic aperture microscopy**. *Nat Phys* 2007, **3**:129–134.
85. Yun SH, Tearney GJ, Vakoc BJ, Shishkov M, Oh WY, Desjardins AE, Suter MJ, Chan RC, Evans JA, Jang IK, Nishioka NS, de Boer JF, Bouma BE: **Comprehensive volumetric optical microscopy in vivo**. *Nat Med* 2006, **12**(12):1429–1433.
86. de Boer JF, Cense B, Park BH, Pierce MC, Tearney GJ, Bouma BE: **Improved signal-to-noise ratio in spectral-domain compared with time-domain optical coherence tomography**. *Opt Lett* 2003, **28**(21):2067–2069.
87. Choma M, Sarunic M, Yang C, Izatt J: **Sensitivity advantage of swept source and Fourier domain optical coherence tomography**. *Opt Express* 2003, **11**(18):2183–2189.
88. Yun S, Tearney G, Bouma B, Park B, de Boer J: **High-speed spectral-domain optical coherence tomography at 1.3 μm wavelength**. *Opt Express* 2003, **11**(26):3598–3604.
89. Peery AF, Shaheen NJ: **Optical coherence tomography in Barrett's esophagus: the road to clinical utility**. *Gastrointest Endosc* 2010, **71**(2):231–234.

doi:10.1186/1746-1596-7-98

Cite this article as: Carignan and Yagi: Optical endomicroscopy and the road to real-time, in vivo pathology: present and future. *Diagnostic Pathology* 2012 **7**:98.

Submit your next manuscript to BioMed Central and take full advantage of:

- Convenient online submission
- Thorough peer review
- No space constraints or color figure charges
- Immediate publication on acceptance
- Inclusion in PubMed, CAS, Scopus and Google Scholar
- Research which is freely available for redistribution

Submit your manuscript at
www.biomedcentral.com/submit

