

Nivolumab and interferon- γ rescue therapy to control mixed mould and bacterial superinfection after necrotizing fasciitis and septic shock

Anne-Claire Lukaszewicz^{a,b,*}, Fabienne Venet^{b,c,d}, André Boibieux^e, Mathilde Lherm^{f,g}, Bertrand Devigne^a, Guillaume Monneret^{b,c}

^a Hospices Civils de Lyon, Hôpital Edouard Herriot, Service d'anesthésie-réanimation, Lyon, 69437, France

^b EA 7426 « Pathophysiology of Injury-Induced Immunosuppression » (Université Claude Bernard Lyon 1 -Hospices Civils de Lyon – bioMérieux), Hôpital Edouard Herriot, Lyon, 69437, France

^c Hospices Civils de Lyon, Hôpital Edouard Herriot, Laboratoire d'Immunologie, Lyon, 69437, France

^d Centre International de Recherche en Infectiologie (CIRI), Inserm U1111, CNRS, UMR5308, Ecole Normale Supérieure de Lyon, Université Claude Bernard-Lyon 1, Lyon, 69437, France

^e Hospices Civils de Lyon, Hôpital Edouard Herriot, Service de Maladies infectieuses et tropicales, Lyon, 69437, France

^f Hospices Civils de Lyon, Hôpital Edouard Herriot, Centre de Traitement des Brûlés, Lyon, 69437, France

^g Hospices Civils de Lyon, Hôpital Edouard Herriot, Service de Chirurgie des Brûlés, Plastique, Reconstructrice et Esthétique, Lyon, 69437, France

ABSTRACT

Immunosuppression is a major feature of septic shock and patients are at increased risk for opportunistic infections. We describe a successful use of immunostimulation to treat mixed mould and bacterial superinfection in a previously healthy 38-year-old female patient admitted for severe extensive fasciitis. Interferon gamma associated with nivolumab reversed successfully deactivation of immune cells assessed by altered expressions of monocyte human leukocyte antigen-DR (HLA-DR) and lymphocyte programmed death receptor-1 (PD-1). Immunosuppressed patients in ICU with invasive bacterial and fungal infections may benefit from immunostimulation.

1. Introduction

A recent publication has described interleukin-7 (IL-7) immunotherapy in a non-immunocompromised trauma patient with intractable fungal wound sepsis [1]. As in trauma, acquired immunosuppression (mainly characterised by decreased monocyte human leukocyte antigen-DR (mHLA-DR) expression and severe lymphopenia) is a major feature of septic shock [2]. Such patients are at increased risk for secondary infections, especially from opportunistic pathogens [3]. We would therefore like to describe a successful use of immunostimulation to treat intractable fungal infection. Among stimulating drugs, the most available are interferon gamma (IFN- γ) and nivolumab (antibody anti programmed death receptor-1 (PD-1)). IFN- γ has been shown to restore monocyte immune functions, and nivolumab to reverse the inhibition of lymphocytes. Nivolumab causes immune checkpoint blockade by diminishing inhibitory signalling through the PD-1 pathway.

Here, we report a case of invasive bacterial and fungal superinfection associated with mucormycosis in a previously healthy 38-year-old female patient recently admitted for septic shock secondary to extensive streptococcal fasciitis. Due to the rapid spread of fungal infection despite

adequate antibiotics and antifungal treatments, interferon gamma (IFN- γ) associated with nivolumab (anti-PD1 antibody) and hyperbaric oxygen therapy (HBOT) was successfully initiated. The patient's written consent was obtained.

2. Case presentation

The patient was admitted (day 0) to a general hospital intensive care unit (ICU) for shock associated with streptococcal necrotising fasciitis of the left chest wall, initially treated with the association of amoxicilline, clindamycine and linezolid. The fasciitis has developed secondary to a minor thoracic trauma while she was playing sport 2 days before. The infection spread rapidly to the surface and then to the pleura, leading to a pneumothorax (Figs. 1 and 2). Tissue cultures confirmed polymicrobial infection, including *Stenotrophomonas maltophilia*, *Citrobacter* spp., *Aspergillus* spp., and *Mucor* spp. (MALDI-TOF, VitekMS-bioMérieux), which remained refractory after 9 days of intensive treatment combining antibiotics and repeated surgeries. The liposomal amphotericin B (10 mg/kg/day) was initiated, and the patient was transferred to our institution for initiating HBOT therapy in a rescue

* Corresponding author. Hospices Civils de Lyon, Hôpital Edouard Herriot, Service d'anesthésie-réanimation, Lyon, 69437, France.

E-mail address: anne-claire.lukaszewicz@chu-lyon.fr (A.-C. Lukaszewicz).

<https://doi.org/10.1016/j.mmcr.2022.06.003>

Received 12 March 2022; Received in revised form 8 May 2022; Accepted 8 June 2022

Available online 13 June 2022

2211-7539/© 2022 The Author(s). Published by Elsevier B.V. on behalf of International Society for Human and Animal Mycology. This is an open access article under the CC BY-NC-ND license (<http://creativecommons.org/licenses/by-nc-nd/4.0/>).

attempt to better control the course of infection [4].

Upon arrival, repeated tissue cultures showed several bacteria (*Enterococcus faecium*, *Enterobacter gallinarum*, *Pseudomonas aeruginosa*, *Citrobacter sedlakii*, *Stenotrophomonas maltophilia*) and fungi (*Candida albicans*, *Aspergillus fumigatus* and *Aspergillus terreus*). On day 11, mucormycosis (*Lichtheimia ramosa*, *Rhizopus arrhizus*) was confirmed by positive blood polymerase chain reaction (PCR sequencing of the regions ITS1/ITS2 and 18S rRNA). Intravenous antibiotherapy was associated with cefepime, ciprofloxacin, sulfamethoxazole-trimethoprim, linezolid, metronidazole, liposomal amphotericin B (for 10 mg/kg/day for 67 days), and posaconazole (from 400 mg/12h to 400 mg/8h, and for 75 days) and then replaced with isavuconazole. This antibiotic therapy was controlled by repeated measurements of drug plasma concentrations (Table 1).

For 5 days, the patient was aggressively treated with daily debridement surgery and HBOT sessions. This slowed down the clinical degradation and reduced the frequency of surgeries, with a shift towards vacuum therapy associated with fungizone administered to the wound until day 25. During this period, the infection course was monitored by repeated tissue and blood samples (Fig. 3A). Organ failures were stabilised with the weaning of vasopressors, although acute kidney injury under continuous renal replacement therapy (RRT), coagulopathy, and thrombocytopenia persisted.

In parallel, as early as day 11, we observed severe monocyte deactivation (mHLA-DR < 5000 antibody per cell (AB/C), laboratory reference values > 13500 AB/C) without lymphopenia. Considering the severity of the situation, we initiated immunostimulation by IFN-γ (100 mcg subcutaneously daily from day 11 to day 21). This resulted in increased mHLA-DR from 4146 to 19112 AB/C (Fig. 3A). Unfortunately, tissue cultures and blood PCR for fungi (*Lichtheimia ramosa*, *Rhizopus arrhizus*) were still positive. Additional investigations revealed high T lymphocyte PD-1 expression. We subsequently decided to administer one dose of nivolumab (280 mg, anti-PD1) on day 27 with three additional administrations of IFN-γ on days 27, 28, and 31 to support immune function (Fig. 3A). T lymphocyte PD-1 expression became negative the day after nivolumab administration and for 32 days (Fig. 3B). Tissue culture became negative for fungi on day 28 and PCR on day 34. The patient’s clinical status then improved rapidly, which allowed RRT weaning on day 39 and extubation on day 43. Reconstructive surgery and skin grafting began on day 52, and the patient left hospital five and a half months after admission.

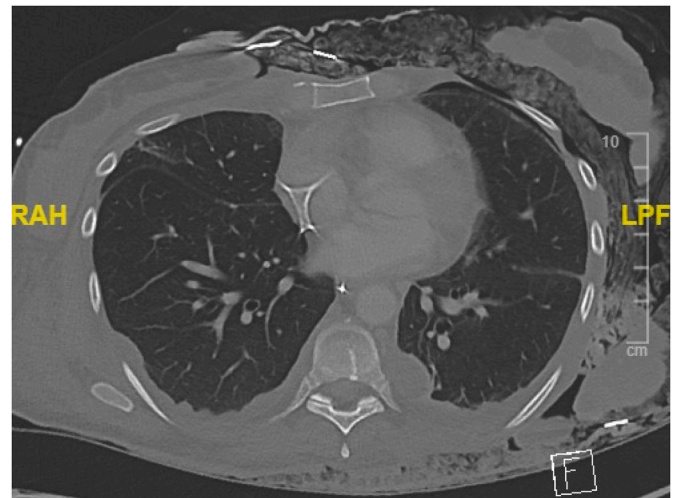


Fig. 2. Chest CT scan showing the extension of the tissue lesion and the pneumothorax.

Table 1

The repeated measurements of drug plasma concentrations according to antibiotics regimen.

	Day 12	Day 17	Day 19	Day 31	Day 40	Day 63	Day 79
Amphotericin B doses/day	500 mg	500 mg	500 mg	500 mg			
Amphotericin B plasma values (mg/L)	2.12	2.24	12.45	3.24	8.3		
Posaconazole doses/day		400 mgx2	400 mgx3	400 mgx3	400 mgx3	400 mgx3	400 mgx3
Posaconazole plasma values (mg/L)		0.39		1.35	0.57	0.59	0.68

3. Discussion

Here we described the course of mixed mould and bacterial superinfection in a previously healthy young patient. Initial severe fasciitis and septic shock might have elicited the severe immunosuppression status and likely favoured mould infection [1]. Because of the rapid spread of infection, we decided early on to combine adjuvant

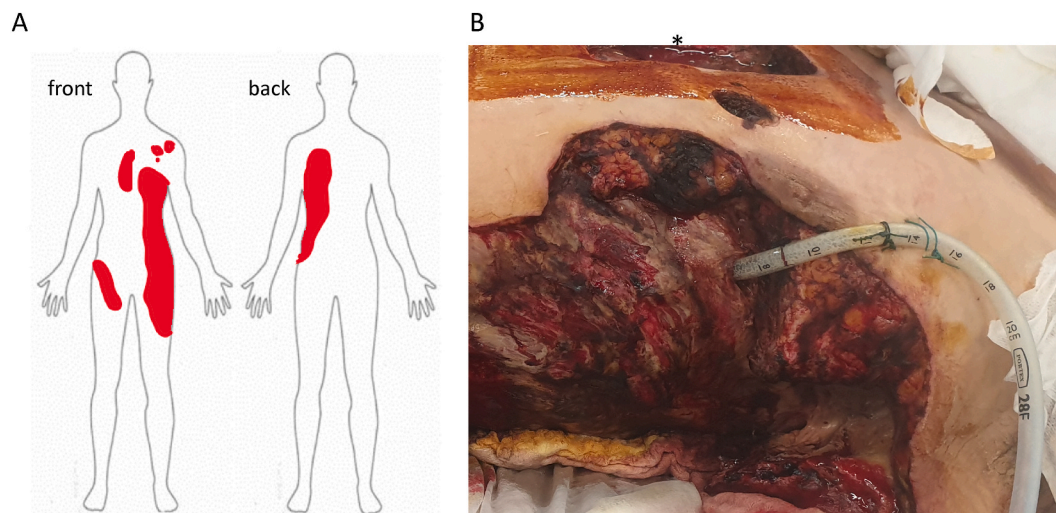


Fig. 1. Clinical presentation of the patient with invasive mucormycosis. (A) Lesions at the body surface. (B) Lesions extending into the chest wall (*: chest tube).

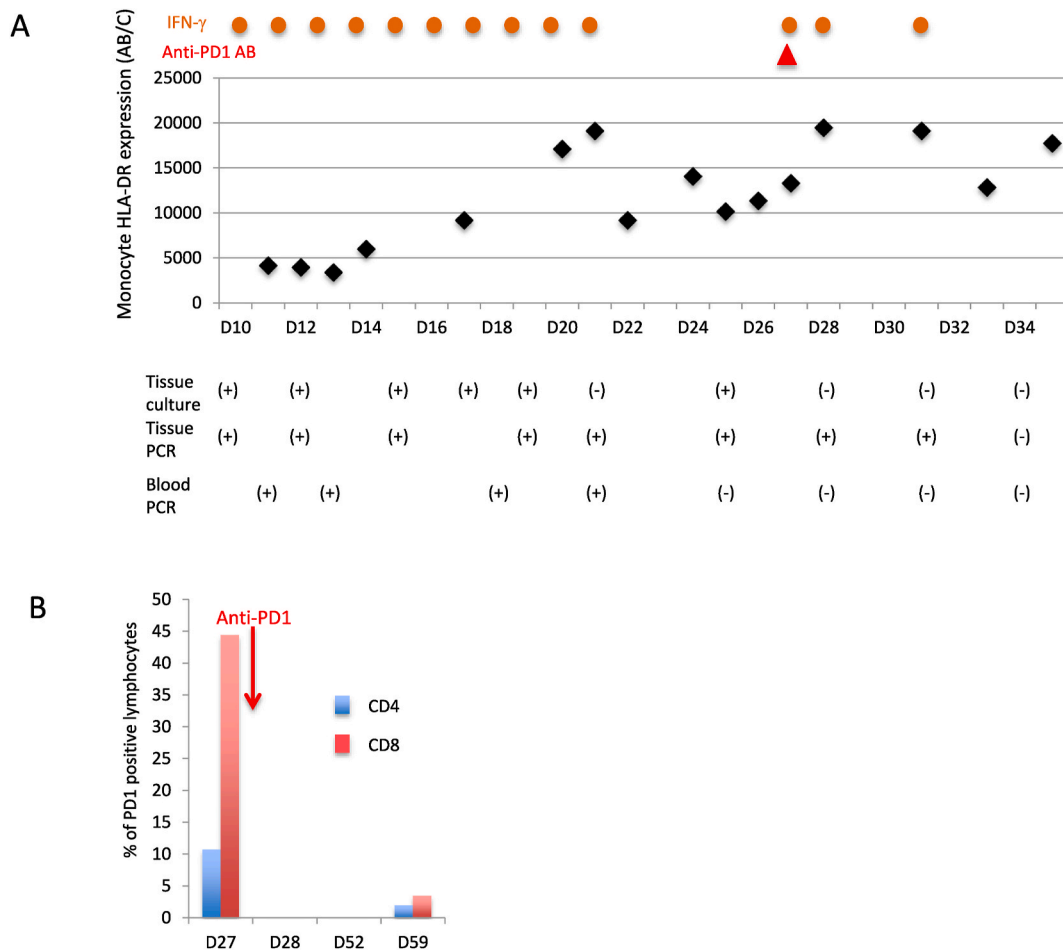


Fig. 3. The changes of a immunological and microbiological parameters under IFN-γ + nivolumab. (A) Serial changes in mHLA-DR under immunotherapy with IFN-γ (daily doses of 100 mcg, orange circles) and one dose of 250 mg nivolumab (anti-PD1 antibody, red triangle) along with results (positive or negative) of tissue and blood cultures or PCR for fungi (*Lichtheimia ramosa*, *Rhizopus arrhizus*) over time. (B) Serial changes in PD-1 expression CD4 (blue bars) and CD8 T (red bars) cells (results as % of positive cells) from anti-PD1 antibody administration (red arrow on day 27). (For interpretation of the references to colour in this figure legend, the reader is referred to the Web version of this article.)

immunotherapy with classical surgical and medical treatments. Immunological monitoring guided this innovative treatment strategy as previously described [5,6]. The patient’s immunological status (i.e., low mHLA-DR and high PD-1 lymphocyte expression) allowed us to target the innate and adaptive component of immunity dysfunction using both IFN-γ and nivolumab as previously reported in a young patient who died from refractory mucormycosis after sustaining bomb blast injuries [5]. Data on the control of such invasive infections and outcomes in ICU patients are scarce [7,8], although we can hypothesise that such immunotherapy has improved the anti-fungi response as described in the case of Turnbull et al. [1].

The respective effectiveness between IFN-γ and nivolumab is difficult to characterise in our case. Because the tissue culture was positive on day 25, we interpreted that the initial treatment with IFN-γ alone increased mHLA-DR, but this effect might not be sustainable enough for controlling such invasive infection (Fig. 3A). The negative culture the day after nivolumab injection suggests that the control of infection was achieved without its effect. However, the addition of nivolumab might have provided the persistency of immunodepression reversion as illustrated by the disappearance of lymphocytic PD-1 expression (Fig. 3B). The effect of one administration of nivolumab seemed adapted to such long-lasting infection. Recent phase-1b randomized trials of the anti-PD-1 monoclonal antibody [9,10] confirmed normalizations in immune parameters (mHLA-DR and lymphopenia) under treatment, suggesting the restoration of immune functions. Importantly, the therapeutic effect

was not associated with an imbalance to hyperinflammation or cytokine storms, nor with many unexpected serious adverse events related treatment. In comparison to these studies, our immune stimulation strategy started later after the onset of septic disease, after assessment of persistence of immunodepression, and we used a lower dose of anti-PD-1 antibody.

Most importantly, initial immunoadjuvant therapy by IFN-γ may have prevented the extensive surgical resection to control the infection. Perhaps the combination of repeated surgeries with antibiotic therapy could have finally controlled the fungal infection. However, these numerous surgeries could have led to serious sequelae, probably not compatible with life. HBOT may have also participated to the limitation of spreading infection. There is no strong evidence of HBOT effectiveness in necrotizing soft tissue infections, often applied as rescue therapy, but could be associated with a better outcome in these complex infection [4]. HBOT was mentioned in clinical guidelines for the diagnosis and management of mucormycosis 2013 as adjunctive therapy reported in uncontrolled settings, but no more in the recent edition [11] because of the lack of solid evidence. These therapies have been an effective strategy to stabilize and recover from organ failures related to bacterial sepsis. Fungal infection was an opportunistic invasive infection favoured by the persistence of immunosuppression secondary to initial bacterial septic shock. We considered reversion of immunosuppression to be an essential objective to control the spread of infection.

We conclude that in severe ICU patients with invasive fungal

infections and severe immunosuppression, the benefit of immunostimulation should be further investigated.

Ethical Form

Ethical Form downloaded.

Declaration of competing interest

There are none.

Acknowledgements

The authors recognize the support action of the commission of medicines and sterile medical devices (COMEDIMS) for obtaining immunotherapies.

The outcome of this patient would have been different without the involvement of other members of our team: Dr Morgane Gossez (biological immunology, Hospices Civils de Lyon), Dr Meja Rabodonirina (mycology, Hospices Civils de Lyon), Dr Laure Fayolle (Anesthesia and Critical care in burns, Hospices Civils de Lyon), Pr Fabienne Braye (plastic surgery, Hospices Civils de Lyon), Pr Olivier Monneuse (emergency surgery, Hospices Civils de Lyon), Dr Thierry Joffre (hyperbaric medicine, Hospices Civils de Lyon), Dr Pierre-Antoine Moreau (Intensivist, Hospital fo Annecy).

References

- [1] I.R. Turnbull, M.B. Mazer, M.H. Hoofmagle, J.P. Kirby, J.M. Leonard, C. Mejia-Chew, et al., IL-7 Immunotherapy in a nonimmunocompromised patient with intractable fungal wound sepsis, *Open Forum Infect. Dis.* 8 (6) (2021) ofab256, <https://doi.org/10.1093/ofid/ofab256>, 23.
- [2] F. Venet, J. Textoris, S. Blein, M.L. Rol, M. Bodinier, B. Canard, et al., Immune profiling demonstrates a common immune signature of delayed acquired immunodeficiency in patients with various etiologies of severe injury, *Crit. Care Med.* 10 (2021 Nov), <https://doi.org/10.1097/CCM.0000000000005270> (Epub ahead of print).
- [3] R.S. Hotchkiss, G. Monneret, D. Payen, Sepsis-induced immunosuppression: from cellular dysfunctions to immunotherapy, *Nat. Rev. Immunol.* 13 (12) (2013) 862–874, <https://doi.org/10.1038/nri3552>.
- [4] J.F. Thrane, T. Ovesen, Scarce evidence of efficacy of hyperbaric oxygen therapy in necrotizing soft tissue infection: a systematic review, *Inf. Disp.* 51 (7) (2019) 485–492, <https://doi.org/10.1080/23744235.2019.1597983>.
- [5] D. Grimaldi, O. Pradier, R.S. Hotchkiss, J.L. Vincent, Nivolumab plus interferon- γ in the treatment of intractable mucormycosis, *Lancet Infect. Dis.* 17 (1) (2017) 18, [https://doi.org/10.1016/S1473-3099\(16\)30541-2](https://doi.org/10.1016/S1473-3099(16)30541-2).
- [6] D. Payen, V. Faivre, J. Miatello, J. Leentjens, C. Brumpt, P. Tissières, et al., Multicentric experience with interferon gamma therapy in sepsis induced immunosuppression. A case series, *BMC Infect. Dis.* 19 (1) (2019) 931, <https://doi.org/10.1186/s12879-019-4526-x>, 5.
- [7] R. Larcher, L. Platon, M. Amalric, V. Brunot, N. Besnard, R. Benomar, et al., Emerging invasive fungal infections in critically ill patients: incidence, outcomes and prognosis factors, a case-control study, *J Fungi (Basel)* 7 (5) (2021) 330, <https://doi.org/10.3390/jof7050330>, 24.
- [8] M. Bassetti, E. Bouza, Invasive mould infections in the ICU setting: complexities and solutions, *J. Antimicrob. Chemother.* 72 (suppl_1) (2017) i39–i47, <https://doi.org/10.1093/jac/dkx032>, 1.
- [9] R.S. Hotchkiss, E. Colston, S. Yende, E.D. Crouser, et al., Immune checkpoint inhibition in sepsis: a Phase 1b randomized study to evaluate the safety, tolerability, pharmacokinetics, and pharmacodynamics of nivolumab, *Intensive Care Med.* 45 (10) (2019 Oct) 1360–1371, <https://doi.org/10.1007/s00134-019-05704-z>.
- [10] E. Watanabe, O. Nishida, Y. Kakihana, M. Odani, T. Okamura, et al., Pharmacokinetics, pharmacodynamics, and safety of nivolumab in patients with sepsis-induced immunosuppression: a multicenter, open-label phase 1/2 study, *Shock* 53 (6) (2020 Jun) 686–694, <https://doi.org/10.1097/SHK.0000000000001443>.
- [11] O.A. Cornely, A. Alastruey-Izquierdo, D. Arenz, S.C.A. Chen, E. Dannaoui, et al., Mucormycosis ECMM MSG global guideline writing group. Global guideline for the diagnosis and management of mucormycosis: an initiative of the European confederation of medical mycology in cooperation with the mycoses study group education and research consortium, *Lancet Infect. Dis.* 19 (12) (2019 Dec) e405–e421, [https://doi.org/10.1016/S1473-3099\(19\)30312-3](https://doi.org/10.1016/S1473-3099(19)30312-3).