



ELSEVIER

Contents lists available at ScienceDirect

JSES International

journal homepage: www.jseinternational.org

Risk factors related to loss of reduction after anatomic repair of acromioclavicular joint dislocation in patients with acute traumatic acromioclavicular joint dislocation

Adinun Apivatgaroon, MD^a, Sorachat Sukkarnkosol, MD^{a,*},
Natsuda Chua Pukrittayakamee, MD^a, Ratirat Limjumroonrat^b,
Supapitchaya Boonyongsunchai^b, Warisra Watcharaporn^b

^aDepartment of Orthopaedics, Faculty of Medicine, Thammasat University, Khlong Nueng, Pathum Thani, Thailand

^bChulabhorn International College of Medicine, Thammasat University, Khlong Nueng, Pathum Thani, Thailand

ARTICLE INFO

Keywords:

Shoulder
AC joint
General sports trauma
Imaging and radiology
General
AC-CC fixation

Level of evidence: Level III; Retrospective
Cohort Comparison; Prognosis Study

Background: Suspension stabilization is a commonly used surgical method for acute acromioclavicular (AC) joint dislocation. However, a failure rate of around 26% caused various emerging surgical techniques and recommendations. We aimed to identify the significance of postulated factors relevant to the radiographic success of AC joint stabilization.

Methods: The data of patients with acute AC joint dislocation treated with suspension stabilization in our institution from January 2012 to December 2022 were reviewed. Zanca views x-ray films of both AC joints were reviewed including the preoperative, immediate postoperative, and final follow-up film. Failure of stabilization was classified by coracoclavicular distance, AC joint subluxation ratio, and AC joint widening. Factors of interest were age, type of injury classified by Rockwood, K-wire augmentation, over-reduction, clavicular tunnels osteolysis, tunnel position, AC ligament repair, the timing of surgery, and stabilization technique. Univariate and multivariate logistic regression analysis was done for the factors contributing to each failure mode.

Results: There were 57 patients included in the study. Multivariate logistic regression analysis showed that AC ligament repair was significantly related to the success of stabilization using coracoclavicular distance criteria (odds ratio [OR] 0.22, $P = .04$). Age older than 40 years significantly related to the success of stabilization using AC subluxation ratio and by any type of failure (OR 0.23, $P = .02$ and OR 0.20, $P = .049$). Other factors failed to show their significance by any mean of failure criteria.

Conclusion: AC ligament repair is related to the success of AC joint stabilization, while additional of K-wire augmentation, direct tunnel position, over-reduction, and earlier surgery could not show their significance in maintaining the reduction.

© 2025 The Author(s). Published by Elsevier Inc. on behalf of American Shoulder and Elbow Surgeons. This is an open access article under the CC BY-NC-ND license (<http://creativecommons.org/licenses/by-nc-nd/4.0/>).

Acromioclavicular (AC) joint injury accounts for 12% of overall shoulder trauma. Its incidence is the highest in males aged 20–40 years old. The acromioclavicular – coracoclavicular (AC-CC) complex, together with the periscapular muscles, acts as a link joining the upper extremity to the body, thus injury to the complex might hinder the function of the upper extremity.¹

This study was ethically approved by Thammasat University's Institutional Human Research Ethics Committee (MTU-EC-OT-0-183/66).

*Corresponding author: Sorachat Sukkarnkosol, MD, Department of Orthopaedics, Faculty of Medicine, Thammasat University, Khlong Nueng, Pathum Thani, Thailand.
E-mail address: Sorachat.suk@gmail.com (S. Sukkarnkosol).

<https://doi.org/10.1016/j.jseint.2024.12.020>

2666-6383/© 2025 The Author(s). Published by Elsevier Inc. on behalf of American Shoulder and Elbow Surgeons. This is an open access article under the CC BY-NC-ND license (<http://creativecommons.org/licenses/by-nc-nd/4.0/>).

AC joint injury can present with varying severity. The most common classification used nowadays is the Rockwood classification.⁷ Surgical stabilization is indicated in Rockwood type 4–6, and some of the type 3 patients. There are many ways to stabilize the AC-CC complex. A frequently used technique is the anatomical repair of the AC-CC complex with suspension technique, which also has various technical details according to the surgeons' preferences, such as a number of tunnels and suturing materials.¹ Even with decades of improvement in surgical techniques, loss of reduction, which is a common complication found in 26.8% of the cases, can lead to pain and poor functional outcomes.²⁵ Many surgeons tried to propose techniques to improve the loss of reduction rate, such as using K-wire augmentation or over-reduction.^{9,15,23,27} However,

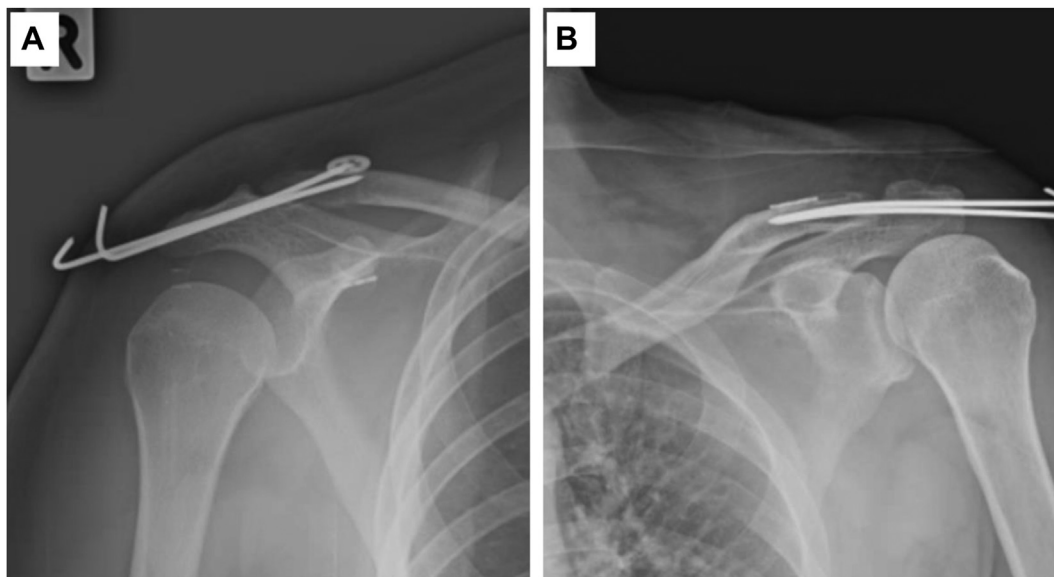


Figure 1 The Zanca radiograph of the shoulders. (A) A Single coracoid and clavicular tunnel technique of the right shoulder. (B) Coracoid loop around the clavicle with 2 clavicular tunnels.

studies that evaluate the factors related to the success or failure of fixation are scarce, especially when considering the contribution of the added-on technique to suspension fixation. Furthermore, the criteria for failure of fixation or loss of reduction are different from previous studies. Usually, the coracoclavicular distance (CCD) compared to the uninjured side is used but the value of the threshold to determine loss of reduction varies, including 2 mm, 5mm, or 50%.^{12,20,21} With the heterogeneity of technique and criterion of failure, our study aims to evaluate the effect of contributing factors to the success or failure of acute AC-CC fixation using different criteria.

Materials and methods

Study design, patient selection, and data collection

This study is a retrospective cohort study and was approved by our Institutional Human Research Ethics Committee (MTU-EC-OT-0-183/66). The patients aged 18-60 years with acute AC joint injury who underwent AC-CC fixation from January 2012 to December 2022 in our institution were included. Patients with graft augmentation or AC-CC reconstruction, hook plate augmentation, prior history of AC-CC complex trauma on either side of the shoulder, and latest follow-up x-ray less than 3 months postoperatively were excluded from the study.

The demographic data including sex, age, side of injury, weight, body mass index, type of AC joint injury classified by Rockwood classification, evaluated in preoperative bilateral AC joint Zanca view x-ray digital film, and the operating surgeon's name were recorded. Then the acute postoperative and the most recent postoperative (final follow-up film) bilateral AC joint Zanca view x-ray digital film, which must be at least 3 months after the operation, were reviewed. Only good quality Zanca view x-ray digital films, which defined by no superimposition of the AC joint, were used for measurement.

The most recent postoperative bilateral AC joint Zanca view x-ray digital film was used to classify the patient into success and failure groups. We defined failure using 3 radiographic parameters. Each parameter has its own thresholds that define failure. First, by using the CCD - the patient had CCD of the injured side $\geq 150\%$

compared to the uninjured side.¹² Second, by using the AC subluxation - the patient had the AC subluxation ratio $\geq 50\%$.⁶ Third, by using AC widening ≥ 2 mm compared to the uninjured side.¹⁹

After we classified patients into success or failure groups according to the 3 criteria, we evaluated the factors that might related to the outcome which were age >40 years or ≤ 40 years, AC injury type 3 or 5, the use of trans AC joint K wire augmentation, over-reduction, the presence of tunnel osteolysis, the tunnel position, the AC ligament repair, the timing of operation ≥ 14 days or < 14 days after the injury, and the technique used which were coracoid loop around with 2 clavicular tunnels and single coracoid and clavicular tunnel (Fig. 1).

The measurement was done by the author, S.S., 2 times, one month apart, and the result was then used for intrarater reliability analysis. The data were then measured again by a same-level evaluator for inter-rater reliability analysis.

Measurement

The process of reviewing digital film was done on a picture archiving and communication system workstation (PACS).

1. CCD was measured in bilateral AC joint Zanca view x-ray digital film from the superior most of the cortex of the coracoid process vertically up to the inferior cortex of the clavicle
2. AC joint subluxation ratio was measured in bilateral AC joint Zanca view x-ray digital film. Starting by drawing a line along the inferior border of the acromion process and drawing a perpendicular line to the superior border of the acromion process at the center of the acromion process and the length was measured (A). Then another perpendicular line was drawn from the line of inferior border of the acromion process to the inferior border of the clavicle and the length was measured (D). The AC joint subluxation ratio was calculated by $D/A \times 100\%$.
3. AC joint widening was measured in bilateral AC joint Zanca view x-ray digital film. The value was derived from a mean of the distance between the upper border of the clavicle to the upper border of the acromion and the distance between the lower border of the clavicle and the lower border of the acromion.

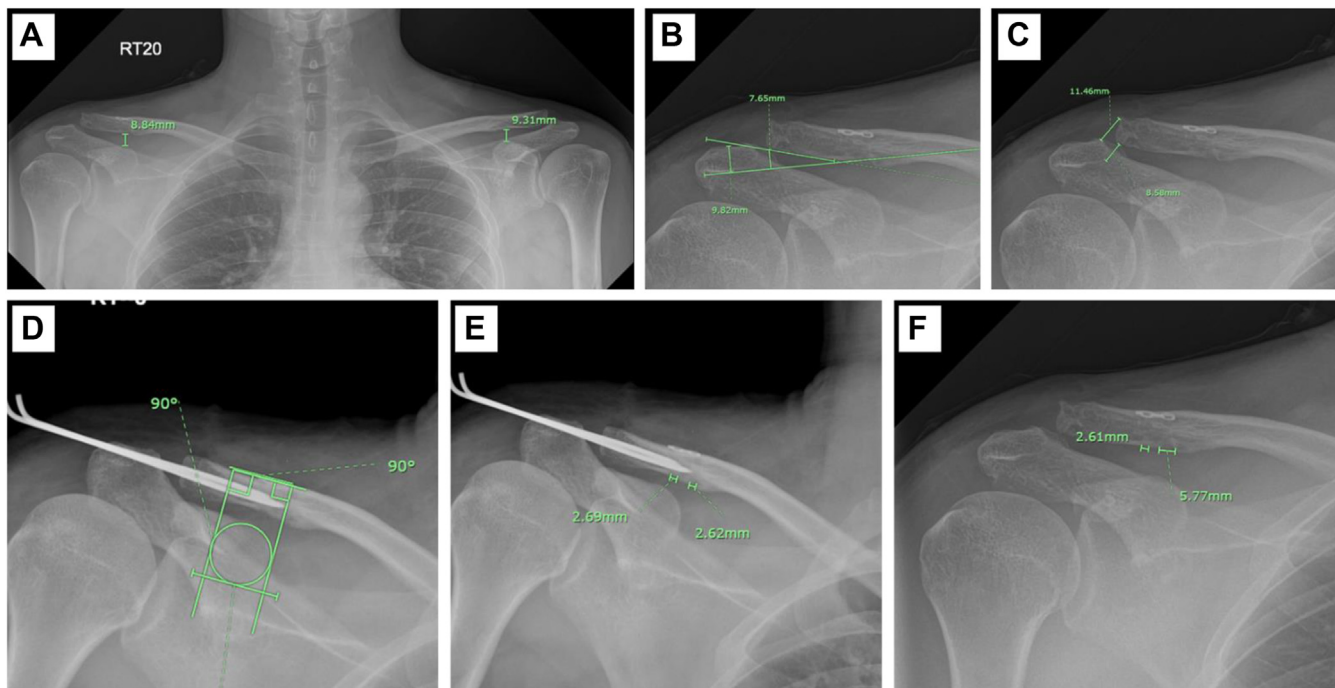


Figure 2 The radiographic measurement parameter in the study. (A) CCD measurement in both shoulders. (B) AC subluxation ratio measurement of the right shoulder. (C) AC joint widening measurement of the right shoulder. (D) Tunnel position measurement of the right shoulder. (E) An immediate postoperative measurement of clavicular tunnels of the right shoulder. (F) The final follow-up measurement of the clavicular tunnel of the right shoulder. CCD, coracoclavicular distance; AC, acromioclavicular.

4. Tunnel position was evaluated in immediate postoperative bilateral AC joint Zanca view x-ray digital film, starting by drawing a circle over the cortex of the coracoid process and drawing another line along the superior cortex of the clavicle. Then, a rectangle was created with its upper border touching the line on the superior cortex of the clavicle, and other borders touching the circle. If all tunnels fall within the rectangle, consider it a good tunnel position, otherwise, a bad tunnel position.²²
5. Over-reduction was defined as a CCD of the operated side <2mm compared with the uninjured side in immediate postoperative bilateral AC joint Zanca view x-ray digital film.²⁰
6. Tunnel widening was defined by a ratio of final tunnel diameter over initial tunnel diameter $\geq 150\%$. The measurement was done in the immediate postoperative and the final follow-up bilateral AC joint Zanca view x-ray digital film.⁸

All measurement examples are shown in [Figure 2](#).

Data analysis

After the data were complete, we then analyzed the data using Stata software (version 14.2; StataCorp, College Station, TX, USA). The continuous data were expressed in mean \pm SD and categorical data were expressed in percentage. Univariate analysis for all factors contributing to the failure was done. Then we included factors that had *P* value < .4 into a multivariate logistic regression model. The result was expressed in odd ratio (OR) and *P* value. We consider the *P* value of <.05 as a statistical significance level. The risk factor analyses for the failure were done for CCD failure, AC subluxation failure, AC widening failure, and any of the three failure modes. The agreement between mode of failure (CCD, AC subluxation, and AC widening), intrarater reliability, and inter-rater reliability were then analyzed using Kappa analysis.

Results

74 patients met the inclusion criteria. After exclusion, there was a total of 57 patients left for the analysis (13 patients had graft reconstruction, 2 patients had hook plate implemented, and 2 patients had final follow-up x-rays less than 3 months postoperatively).

The mean age was 43.65 ± 1.86 years, with male sex predominance (*n* = 46, 80.70%). For the severity of the injury, 40 patients (70.18%) sustained an AC joint injury type 5, and the rest had type 3 injuries (*n* = 17, 29.82%). The mean follow-up time was 8.23 ± 1.11 months (range 3–36 months). The patients were operated by 3 sports surgeons separately. There was 89.47% of the patients that had K-wire augmentation, and the K-wire was removed at 6 weeks for every patient. There was 42.11% of the patient that got over-reduction. Tunnel osteolysis occurred in 64.91% of the patients and good tunnel position was identified in 56.14% of the patients. AC ligament repair was done in 71.93% of the patients; all surgeons had both repair and unrepaired cases as their surgical technique changes over 10 years. Mean time from injury to surgery is 8.23 ± 7.82 days (range 3–21 days), of which, 68.42% of the patients had a surgery less than 14 days after the accident. Coracoid loop around with 2 clavicular tunnels technique was used in 84.21% of the patient, while single tunnel on clavicle and coracoid technique was used for the rest (15.79%). Note that the surgeon with the most case performed (28 cases) had 10 (35.71%) overreduction, 20 (71.43%) good tunnel position, 25 (89.29%) AC ligament repair, 25 (89.29%) K-wire augmentation and 28 (100%) coracoid loop around with 2 clavicular tunnels technique.

Loss reduction occurred in 20 patients (35.09%) classified by CCD, 20 patients (35.09%) classified by AC subluxation ratio, and 34 patients (59.65%) classified by AC widening. There were only 16 patients (28.07%) who did not meet any of the failure criteria. The complete data are shown in [Table I](#).

Table I
Demographic data and binary data are shown as N (percentage).

Factors	Binary data	
Age	Mean 43.65 ± 1.86	
	>40 y: 34 (59.65%)	≤40 y: 23 (40.35%)
BMI	Mean 25.62 ± 2.94	
Sex	Male: 46 (80.70%)	Female: 11 (19.30%)
Side of injury	Right: 33 (57.89%)	Left: 24 (42.11%)
AC injury type	Type 5: 40 (70.18%)	Type 3: 17(29.82%)
Surgeon	A: 31 (54.39%)	
	B: 19 (33.33%)	
	C: 7 (12.28%)	
CCD loss reduction	Yes: 20 (35.09%)	No: 37 (64.91%)
AC subluxation loss reduction	Yes: 20 (35.09%)	No: 37 (64.91%)
AC widening loss reduction	Yes: 34 (59.65%)	No: 23 (40.35%)
Any failure	Yes: 41 (71.93%)	No: 16 (28.07%)
K-wire augmentation	Yes: 51 (89.47%)	No: 6 (10.53%)
Over-reduction	Yes: 24 (42.11%)	No: 33 (57.89%)
Tunnel osteolysis	Yes: 37 (64.91%)	No: 20 (25.09%)
Good tunnel position	Yes: 32 (56.14%)	No: 25 (43.86%)
AC ligament repair	Yes: 41 (71.93%)	No: 16 (28.07%)
Timing of surgery	≤14 d: 39 (68.42%)	>14 d: 18 (34.58%)
Technique of CC stabilization	Single	Double
	tunnel: 9 (15.79%)	tunnel: 48 (84.21%)
AC joint OA change	Yes: 21 (36.84%)	No: 36 (63.16%)

BMI, body mass index; CCD, coracoclavicular distance; AC, acromioclavicular; CC, coracoclavicular; OA, osteoarthritis; SD, standard deviation. The continuous data was shown in mean ± SD.

Table II
The relation between each mode of failure in the same patient was evaluated by Kappa analysis.

Mode of failure	Kappa
CCD and AC subluxation	0.45
CCD and AC widening	0.14
AC subluxation and AC widening	0.3

CCD, coracoclavicular distance; AC, acromioclavicular.

The result of multivariate logistic regression analyses showed that doing AC ligament repair could prevent the loss of reduction defined by CCD with OR = 0.22 ($P = .04$), and by AC subluxation ratio with OR = 0.23 ($P = .046$). Age older than 40 years was identified as a protective factor for loss of reduction by AC subluxation ratio with OR = 0.23 ($P = .02$). We found no factor that was significantly related to the loss of reduction by AC widening. For analysis factors contributing to the failure by one of any criteria, we also found that age older than 40 years was a protective factor with OR = 0.20 ($P = .049$).

The relation between each mode of failure in the same patient was evaluated by Kappa analysis. The result showed only poor to moderate agreement. (Table II)

The results of univariate analyses for each factor and each definition of failure were shown in Table III and the total results for multivariate logistic regression analyses for each definition of failure were shown in Table IV.

Intrarater reliability and inter-rater reliability fell into the range of substantial agreement to almost perfect agreement. The detailed data are shown in Table V.

Among 57 cases, there were 6 cases (10.53%) with recorded complication. There were 2 cases with shoulder stiffness. The patients were treated with rehabilitation. There were 2 cases with pin tract infection. One case needed surgical débridement while the other case, the infection is mild and was treated with oral antibiotics and wound dressing. There were 2 cases that underwent revision surgery. Both cases reached failure by all criteria (CCD, AC subluxation ratio and AC widening). The patient was symptomatic and got revision surgery with AC-CC reconstruction with hamstring

graft. Osteoarthritic change of AC joint occurred in 21 patients, 20/51(39.22%) in K-wire augmentation group and 1/6 (16.67%) in non-K-wire group. From univariate analysis, K-wire augmentation did not relate with osteoarthritic change (OR 3.23, $P = .30$).

Discussion

Nowadays, acute AC joint dislocation is commonly treated by either open reduction - internal fixation with hook plate or AC-CC stabilization. The functional and radiologic outcomes are comparable. However, AC-CC stabilization mitigates the need for reoperation for hook plate removal and risk for subacromial osteolysis making it an appealing option for many surgeons.^{4,10}

Even though AC-CC stabilization is an effective treatment option, one of the most common complications after AC-CC stabilization was a loss of reduction which in turn might cause pain and poor functional outcome. In the literature, the CCD was the most common and acceptable parameter to evaluate radiographic success or failure of fixation. Our study showed an overall loss of reduction rate of 35% which was within the range of previous studies that showed a failure rate between 6.5%-80%, but slightly higher than the pooled rate of 26.8%.²⁵ Performing AC ligament repair and patient's age older than 40 years were strong protective factors found in this study. However, other surgical factors including K-wire augmentation, over-reduction, and even having a direct straight, perpendicular tunnel position to the clavicle related to the coracoid process had failed to have a significant effect on the success or failure of the fixation by any of the radiographic criteria evaluated in this study.

Kai Chen, et al² conducted a study identifying factors related to loss of reduction after AC-CC stabilization using the EndoButton (Smith & Nephew, Andover, MA, USA) device. There were 107 patients with acute AC joint dislocation with a mean follow-up time of 24 months. The loss of reduction rate was 14%. They found that the noncenter drilling of coracoid EndoButton, early upper limb weight bearing (<6 weeks), and the presence of osteolysis were significant risk factors for postoperative loss of reduction, while the number of EndoButton (2 or 3), the time between injury and surgery and Rockwood classification were not significant risk factors. The result regarding the time between injury and surgery, and the Rockwood classification was concordant with our study, even though the technique of fixation was different from our study.

Liao-Jun Sun, et al²² also conducted a multivariate regression analysis on the risk factors related to the loss of reduction after AC-CC fixation with the suture button. There were 130 patients investigated with a mean follow-up of 26 months. They found that osteoporosis, clavicular tunnel location, and position of coracoid button plate were risk factors that were significantly associated with the loss of reduction. The type of injury classified by Rockwood between the loss of reduction group and remain reduction group did not differ significantly. Our study had a similar result regarding the insignificance of the type of injury. Contrary to our study, they found that AC ligament repair was not a significant factor from the multivariate logistic regression analysis, even though there was a significant difference between groups. However, in the biomechanics study, the AC capsule had a significant contribution to the translational stability.⁵ Many studies incorporate AC ligament repair into their repertoire. Their studies showed good radiologic and clinical outcomes but did not directly investigate the merit of AC ligament repair.^{9,13,23,27} Furthermore, in the case of ligament reconstruction, the addition of AC reconstruction to the CC reconstruction using either synthetic tapes, grafts, or allografts without bone tunnels significantly improved the radiologic outcomes and improved reoperation rate.²⁴ We believed that a combination of AC-CC ligament repair would reduce the failure rate

Table III
Univariate analysis of each factor for failure of fixation by each mode of failure and by any mode of failure.

Factors	CCD		AC subluxation		AC widening		Any failure	
	OR	P value	OR	P value	OR	P value	OR	P value
Age >40 y	1.98	.25	0.28	.03	0.68	.48	0.24	.05
AC injury type 5	3.45	.08	1.44	.56	0.34	.10	0.45	.26
K wire augmentation	1.09	.92	0.50	.43	0.71	.71	0.48	.52
Over-reduction	0.63	.43	0.88	.81	0.68	.47	0.64	.45
Tunnel osteolysis	1.42	.56	2.05	.25	2.55	.10	3.51	.04
Good tunnel position	1.28	.67	0.93	.90	0.97	.96	0.99	.99
AC ligament repair	0.41	.15	0.41	.15	1.22	.74	0.50	.33
Timing <14 d	0.56	.32	0.56	.32	0.91	.88	0.98	.97
Single tunnel technique	0.19	.13	0.48	.39	0.48	.32	0.24	.06

Factors with P value < .4 are highlighted in bold letters, and will be further included in multivariate logistic regression analysis. CCD, coracoclavicular distance; AC, acromioclavicular; OR, odd ratio.

Table IV
Multivariate logistic regression analysis for each mode of failure and for reaching any of the failure modes.

Factors	CCD		AC subluxation		AC widening		Any failure	
	OR	P value	OR	P value	OR	P value	OR	P value
Age >40 y	2.15	.25	0.23	.02			0.20	.049
AC injury type 5	2.56	2.00			0.33	.11	0.58	.52
K wire augmentation								
Over-reduction								
Tunnel osteolysis			2.59	.18	2.03	.24	4.29	.06
Good tunnel position								
AC ligament repair	0.22	.04	0.23	.046			0.27	.14
Timing <14 d	0.29	.08	0.33	.12				
Single tunnel technique	0.10	.72	0.27	.21	0.43	.26	0.18	.09

Factors with P value < .05 were bolded. CCD, coracoclavicular distance; AC, acromioclavicular; OR, odd ratio.

Table V
Kappa analysis for intrarater and inter-rater reliability.

Categorization	Intrarater reliability (Kappa)	Inter-rater reliability (Kappa)
CCD loss reduction	0.89	0.83
AC subluxation loss reduction	0.87	0.79
AC widening loss reduction	0.85	0.66
Over-reduction	0.79	0.85
Tunnel osteolysis	0.83	0.83
Good tunnel position	0.80	0.80

CCD, coracoclavicular distance; AC, acromioclavicular.

as it might have a higher chance of AC ligament healing. We also believed that the repaired AC ligament could share the load with the repaired CC ligament which resisted vertical translation as shown in the result as it was a significant preventing factor for failure by CCD and AC subluxation ratio criteria. Further, AC ligament repair might help prevent failure from horizontal translation, which had not been investigated in our study, because the trans-axillary view and Alexander view were not routinely used for follow-up in our institution.

Another result that conflicted with previous studies mentioned earlier^{2,22} was that patients with an age of more than 40 years at the time of injury were a significant factor in preventing the failure defined by AC subluxation ratio and by any type of failure. The reason behind the result might be that the older patients yielded to have lower postoperative activity and thus might have better compliance to the immobilization protocol and less strenuous daily activities compared to the younger counterpart.

The relationship between good tunnel position and clavicular tunnel widening was postulated in a study by Jeon N, et al⁸ They

found that fixation using one cortical button on the clavicle and suture looping around the coracoid process had more tunnel widening compared to using a button fixing under a coracoid tunnel. The final follow-up CCD was not different between the two groups but 3 out of 14 in the coracoid loop group had a subsequent clavicular fracture, while none of the coracoid tunnel group had a clavicular fracture. The reason behind tunnel widening in the study was that the oblique line of pull had a windshield-wiper or bungee cord effect.²⁶ Our study found that good tunnel position and tunnel widening were not significant factors for failure by any criteria. We hypothesized that even if the fixation line of pull was not ideal and caused the windshield-wiper or bungee cord effect if the construct was able to last until the AC and CC ligament healed, it would not affect the radiographic outcome even if tunnel widening occurred. This could also explain the finding that the technique used in our study which were two clavicular tunnels – coracoid loop around technique and one clavicular tunnel – coracoid tunnel technique, did not relate to the loss of reduction. Cook, et al found that CC stabilization which had the tunnel fell into distal 25% of the clavicle had no failure in their study.³ Noted that 20 of 25 cases that fell into bad tunnel position group in our study, had the tunnel lateral to the coracoid process.

The merit of K-wire augmentation was not found in our study. We found that the augmentation of fixation with trans AC joint K-wire did not significantly prevent the loss of reduction by any criteria. Further, there were 20 out of 51 cases (39.22%) with osteoarthritic change or distal clavicle osteolysis following the use of trans AC joint K-wire, compared to 1 out of 6 cases (16.67%) in the group without the use of K-wire (P = .40). However, the number of attempts drilling with K-wire, which might affect the rate of osteoarthritic change or distal clavicle osteolysis was not recorded. Further, the use of K-wire had its complications such as breakage, migration, and pin tract infection.¹⁷ Our study did not support the use of trans AC joint K-wire

augmentation as it did not help reduce loss of reduction and the complications of using K-wire were avoided.

Over-reduction was supported by some studies.^{9,16} Maziak N, et al¹⁶ found that over-reduction could prevent dynamic posterior translation, which was significantly related to pain, but not vertical translation. They also found that from an overall of 26 patients that had over-reduction done, 12 (4%), remained over-reduced during final follow-up, while 8 (31%) returned to anatomical position, and 10 (38%) to a nearly anatomical position (1-2mm CCD difference). The result concurred with our study. Our study showed that over-reduction did not affect the success rate of fixation judging by a vertical parameter (CCD and AC subluxation), however, the horizontal plane instability was not evaluated by our study. We also found that 2 of 24 (8.33%) cases with over-reduction remained over-reduced. The clinical effect of remaining over-reduced was not yet to be determined. So, with the rate of around 4-8% remaining over-reduced compared to the prevention of dynamic posterior translation, the over-reduction might be considered beneficial.

This study is one of very few studies that analyze factors relating to the failure and success of AC-CC stabilization. Many surgically adjustable factors, including the use of K-wire augmentation, over-reduction, AC ligament repair, tunnel positioning, and technique for CC stabilization (two clavicular tunnels – coracoid loop around technique and one clavicular tunnel – coracoid tunnel technique), were studied and thus might provide more evidence supporting or against the use of mentioned additional to the fixation techniques. However, this study is not without limitations. First, this study is retrospective. The performing surgeons gained more experience during the 10 years that the patients were included. There were also some differences between the 3 surgeons as two were seniors with different surgical techniques and one was younger. The details about AC ligament repair were not sufficiently recorded, such as repair material, suture configuration, suture to a bone tunnel, suture anchor, or just soft tissue repair. The number of K-wire and size of K-wire also have many differences throughout the cases. The number of attempts that may affect the rate of distal clavicle osteolysis or the injury to the CC fixation construct was not recorded. Most of the bad tunnel position was laterally deviated and fell in the distal 25% length of the clavicle, which had been related to good radiographic outcome. Second, the sample size is significantly smaller than previous study. Third, the functional outcome and horizontal plane stability were not investigated. As of current evidence, there was weak to no significant correlation between increased CCD and functional outcomes.^{11,14,18} It is unfortunate that we lack functional outcome data. Further study might shed light on this aspect.

Conclusion

In acute AC dislocation types 3 and 5, integrating an AC ligament repair with CC repair using suspension technique is a significant factor contributing to the success of vertical stability judged by CCD and AC subluxation ratio, while age older than 40 years old at the time of injury might have better radiographic outcome than younger counterpart. K-wire augmentation and over-reduction failed to show their significance in preventing vertical instability. Thus, we recommend AC ligament repair as it significantly reduces failure and is easy to perform, and we are against the use of trans AC joint K-wire augmentation as it increases risk for complications without benefit.

Disclaimers:

Funding: This study was funded by Faculty of Medicine, Thammasat University.

Conflicts of interest: The authors, their immediate families, and any research foundation with which they are affiliated have not received any financial payments or other benefits from any commercial entity related to the subject of this article.

References

- Berthold DP, Muench LN, Dyrna F, Mazzocca AD, Garvin P, Voss A, et al. Current concepts in acromioclavicular joint (AC) instability - a proposed treatment algorithm for acute and chronic AC-joint surgery. *BMC Musculoskelet Disord* 2022;23:1078. <https://doi.org/10.1186/s12891-022-05935-0>.
- Chen K, Xu B, Lao YJ, Yang Y. Risk factors related to the loss of reduction after acromioclavicular joint dislocation treated with the EndoButton device. *Ann Transl Med* 2021;9:345. <https://doi.org/10.21037/atm-21-404>.
- Cook JB, Shaha JS, Rowles DJ, Bottoni CR, Shaha SH, Tokish JM. Clavicular bone tunnel malposition leads to early failures in coracoclavicular ligament reconstructions. *Am J Sports Med* 2013;41:142-8. <https://doi.org/10.1177/0363546512465591>.
- Dündar A, İpek D. Comparison of the hook plate versus TightRope system in the treatment of acute type III acromioclavicular dislocation. *Adv Orthop* 2022;2022:8706638. <https://doi.org/10.1155/2022/8706638>.
- Dyrna F, Imhoff FB, Haller B, Braun S, Obopilwe E, Apostolakos JM, et al. Primary stability of an acromioclavicular joint repair is affected by the type of additional reconstruction of the acromioclavicular capsule. *Am J Sports Med* 2018;46:3471-9. <https://doi.org/10.1177/0363546518807908>.
- Gastaud O, Raynier JL, Duparc F, Baverel L, Andrieu K, Tarissi N, et al. Reliability of radiographic measurements for acromioclavicular joint separations. *Orthop Traumatol Surg Res* 2015;101(8 Suppl):S291-5. <https://doi.org/10.1016/j.otsr.2015.09.010>.
- Gorbaty JD, Hsu JE, Gee AO. Classifications in brief: Rockwood classification of acromioclavicular joint separations. *Clin Orthop Relat Res* 2017;475:283-7. <https://doi.org/10.1007/s11999-016-5079-6>.
- Jeon N, Choi NH, Ha JH, Kim M, Lim TK. Clavicular tunnel complications after coracoclavicular reconstruction in acute acromioclavicular dislocation: coracoid loop versus coracoid tunnel fixation. *Clin Orthop Surg* 2022;14:128-35. <https://doi.org/10.4055/cios21094>.
- Klabklay P, Chuaychoosakoon C. Functional and radiographic outcomes of intraoperatively decreasing the coracoclavicular distance to 50% of the unaffected side in stabilization of acute acromioclavicular joint injury: a retrospective evaluation. *Orthop J Sports Med* 2021;9:2325967120988798. <https://doi.org/10.1177/2325967120988798>.
- Ko SH, Lee CC, Jeon YD, Han JW, Lee KJ. Long-term clinical outcomes after TightRope versus hook plate fixation for acute acromioclavicular joint dislocation. *Orthop J Sports Med* 2023;11:23259671231165097. <https://doi.org/10.1177/23259671231165097>.
- Kumar Y, Kambhampati S, Rahul P, Chirag NR. Functional results following acromioclavicular joint reconstruction using gracilis tendon augmented with fibertape: a prospective study. *Arch Trauma Res* 2022;11:123. https://doi.org/10.4103/atrr.24_22.
- Lee YS, Kim DS, Jung JW, Jo YH, Lee CH, Lee BG. Risk factors of loss of reduction after acromioclavicular joint dislocation treated with a hook plate. *J Orthop Traumatol* 2023;24:10. <https://doi.org/10.1186/s10195-023-00685-8>.
- Liu T, Bao F-I, Jiang T, Ji G-W, Li J-M, Jerosch J. Acromioclavicular joint separation: repair through suture anchors for coracoclavicular ligament and nonabsorbable suture fixation for acromioclavicular joint. *Orthop Surg* 2020;12:1362-71. <https://doi.org/10.1111/os.12771>.
- Madi S, Pandey V, Murali S, Acharya K. Clinical and radiological outcome of acute high-grade acromioclavicular joint dislocation: a retrospective cohort study on Hook plate versus arthroscopic assisted single coracoclavicular tunnel with DogBone™ button dual FiberTape® construct. *J Clin Orthop Trauma* 2022;27:101825. <https://doi.org/10.1016/j.jcot.2022.101825>.
- Matsumura N, Kawano Y, Furuhashi R, Kimura H, Suzuki T, Iwamoto T. Comparison between trans-articular and subacromial stabilization with ligament repair for acute acromioclavicular dislocation. *Open J Orthop* 2020;14:8-14. <https://doi.org/10.2174/1874325002014010008>.
- Maziak N, Audige L, Hann C, Minkus M, Scheibel M. Factors predicting the outcome after arthroscopically assisted stabilization of acute high-grade acromioclavicular joint dislocations. *Am J Sports Med* 2019;47:2670-7. <https://doi.org/10.1177/0363546519862850>.
- Modi CS, Beazley J, Zywiell MG, Lawrence TM, Veillette CJ. Controversies relating to the management of acromioclavicular joint dislocations. *Bone Joint J* 2013;95-b:1595-602. <https://doi.org/10.1302/0301-620x.95b12.31802>.
- Mori D, Nishiyama H, Haku S, Funakoshi N, Yamashita F, Kobayashi M. Coracoclavicular and acromioclavicular ligament reconstruction with a double-bundle semitendinosus autograft and cortical buttons for chronic acromioclavicular joint dislocations: clinical and imaging outcomes. *J Shoulder Elbow Surg* 2024;33:e507-18. <https://doi.org/10.1016/j.jse.2024.01.019>.
- Petersson CJ, Redlund-Johnell I. Radiographic joint space in normal acromioclavicular joints. *Acta Orthop Scand* 1983;54:431-3.
- Simonian LE, Simonian TL, Simonian PT. Recommendations for optimizing acromioclavicular fixation success with the tight rope device. *MOJ Orthop Rheumatol* 2017;8:00302. <https://doi.org/10.15406/mojor.2017.08.00302>.

21. Spencer HT, Hsu L, Sodl J, Arianjam A, Yian EH. Radiographic failure and rates of re-operation after acromioclavicular joint reconstruction: a comparison of surgical techniques. *Bone Joint J* 2016;98-b:512-8. <https://doi.org/10.1302/0301-620x.98b4.35935>.
22. Sun LJ, Lu D, Tao ZY, Yu XB, Hu W, Ma YF, et al. Analysis of risk factors for loss of reduction after acromioclavicular joint dislocation treated with the suture-button. *J Orthop Sci* 2019;24:817-21. <https://doi.org/10.1016/j.jos.2019.01.014>.
23. Vijayan S, Kulkarni MS, Jain CP, Shetty S, Aror MN, Rao SK. Bifocal stabilisation of acute acromioclavicular joint dislocation using suture anchor and temporary K-wires: a retrospective analysis. *Malays Orthop J* 2022;16:104-12. <https://doi.org/10.5704/moj.2211.016>.
24. Walters JD, Ignozzi A, Bustos F, Werner BC, Brockmeier SF. Better radiographic reduction and lower complication rates with combined coracoclavicular and acromioclavicular ligament reconstruction than with isolated coracoclavicular reconstruction. *Arthrosc Sports Med Rehabil* 2021;3:e441-8. <https://doi.org/10.1016/j.asmr.2020.10.009>.
25. Woodmass JM, Esposito JG, Ono Y, Nelson AA, Boorman RS, Thornton GM, et al. Complications following arthroscopic fixation of acromioclavicular separations: a systematic review of the literature. *Open Access J Sports Med* 2015;6:97-107. <https://doi.org/10.2147/oajsm.S73211>.
26. Yoo JC, Choi NH, Kim SY, Lim TK. Distal clavicle tunnel widening after coracoclavicular ligament reconstruction with semitendinous tendon: a case report. *J Shoulder Elbow Surg* 2006;15:256-9. <https://doi.org/10.1016/j.jse.2005.02.019>.
27. Zheng J, Chen J, Chen L, Ni Y, Lin Z. A novel hybrid fixation (coracoclavicular screw supplemented with K-wire) for the treatment of acute acromioclavicular joint dislocation: a prospective study. *Int J Surg* 2018;59:61-6. <https://doi.org/10.1016/j.ijssu.2018.09.019>.