

Early Demonstration of Spontaneous Perinodal Lymphangiogenesis by Lymphoscintigraphy after Vascularized Lymph Node Transplantation - A Pilot Study

Abstract

Background: Despite the lymphatic system being so important and extensive, the field of lymphatic diseases, research is still very young. Lymphedema is a progressively debilitating condition with no known “cure.” Specific pathologies that could benefit from improved lymphatic drainage by advanced super surgical techniques or engineered tissue transfer are being sought. Microsurgical techniques like lymphovenous bypass and anastomosis have spurred interest as they tend to physiologically restore the damaged lymphatic channels and may be a key to permanent cure. The latest in the field is vascularized lymph node transfer (VLNT), indicated in post mastectomy or other post operative settings producing disruption of regional lymphatic channels and draining lymph nodes. Autologous healthy lymph nodes are transferred along with surrounding fat and vascular pedicle to the affected limb in a bid to promote lymphangiogenesis. Lymphoscintigraphy (LS) is a simple, noninvasive nuclear technique used in identifying upper or lower limb lymphatic dysfunction and obstruction with a high degree of sensitivity. Quantitative LS is extremely useful in follow-up assessment of lymphedema postmanual lymphatic drainage (MLD) or other forms of medical management. **Aim:** We hypothesize that LS can document perinodal lymphangiogenesis post VLNT. **Material and Methods:** Three cases of acquired lymphedema (suspected filariasis and postmastectomy conditions) who underwent VLNT in our institute were prospectively studied with LS. The imaging findings highlight the subtle lymphatic regeneration along with the vascularized graft in all three patients during the early postoperative period. **Conclusion:** This is the first (pilot) study documenting early spontaneous perinodal lymphangiogenesis after VLNT in human subjects. ^{99m}Tc Nanocolloid LS has been found to be incremental in demonstrating early lymphangiogenesis.

Keywords: ^{99m}Tc Nano colloid lymphoscintigraphy, chronic lymphedema, lymph node transplantation, lymphangiogenesis, vascularised lymph node transfer

Introduction

Lymphedema is a chronic and debilitating disease that occurs due to poor lymphatic flow through the affected limb. It can occur because of congenital disorders, cancer, side effects of oncosurgery, chemoradiation, cardiac disorders, and immunological diseases. Filariasis, in developing countries, is found to be the major contributor for pedal lymphedema. Antifilarial measures are initiated in endemic zones in a bid to control the disease progression. Manual lymphatic drainage (MLD) is a conservative but effective form of management in early stages of lymphedema to reduce the interstitial fluid volume in affected limb and enhance fluid drainage through collateral lymphatic channels before contemplating

surgical options. Lymphedema causes physical and psychological morbidity in patients affected with this condition. Generally, the involved limb becomes swollen, heavy, fibrotic, and deformed. Limb pain can co-exist. Due to lymphatic collection, the affected limb may become prone to infections, and typically require lifelong palliative interventions to prevent disease progression, rather than to cure the condition.

Historically, lymphedema was treated with debulking, ablative procedures where the excess fat and fluid accumulation was directly excised or removed through liposuction.^[1] However, these approaches are far from physiologic and are often disfiguring or can only achieve temporary improvement. Although it was first described in 1960s,

This is an open access journal, and articles are distributed under the terms of the Creative Commons Attribution-NonCommercial-ShareAlike 4.0 License, which allows others to remix, tweak, and build upon the work non-commercially, as long as appropriate credit is given and the new creations are licensed under the identical terms.

For reprints contact: WKHLRPMedknow_reprints@wolterskluwer.com

How to cite this article: Subramanyam P, Janarthanan R, Palaniswamy SS. Early demonstration of spontaneous perinodal lymphangiogenesis by lymphoscintigraphy after vascularized lymph node transplantation - A pilot study. Indian J Nucl Med 2022;37:1-6.

Padma Subramanyam, Janarthanan R¹, Shanmuga Sundaram Palaniswamy

Departments of Nuclear Medicine and Molecular Imaging and ¹Plastic and Reconstructive Surgery, Amrita Institute of Medical Sciences, Cochin, Kerala, India

Address for correspondence:
Dr. Padma Subramanyam,
Department of Nuclear Medicine and Molecular Imaging, Amrita Institute of Medical Sciences, Amrita Viswavidyapeetham, Cochin - 682 041, Kerala, India.
E-mail: drpadmasundaram@gmail.com

Received: 08-08-2021
Revised: 27-09-2021
Accepted: 22-11-2021
Published: 25-03-2022

Access this article online

Website: www.ijnm.in

DOI: 10.4103/ijnm.ijnm_123_21

Quick Response Code:



the field of lymphedema surgery and supermicrosurgical treatment of lymphedema through a lymphovenous bypass (LVB) or lymphaticovenular anastomosis (LVA) has only recently become more common and is considered one of the gold standard treatments for lymphedema. In 1977, O'Brien *et al*^[2] introduced LVA for the treatment of obstructive lymphedema in the extremities. Further development of super microsurgery has facilitated anastomosis of vessels of 0.3 mm to 0.8 mm in caliber.^[3] LVB creates a new pathway to drain excess lymphatic fluid that is trapped in lymphedematous areas into the venous circulation. It increases the transport capacity of the lymphatic fluid. In preparation for LVB/LVA, lymphoscintigraphy (LS) followed by MR lymphangiography is ideal in the background of normal venous supply (normal Doppler study). LVB/LVA can be performed only in those patients demonstrating faint or intact lymphatic channels in the affected limb, some amount of dermal lymphatics/backflow, and draining node/s. The main prerequisite being identification of an ideal lymphatic vessel (with good caliber) demonstrated by MR lymphangiography with the absence of adequately sized venules near it. Once this finding is confirmed, LVB and anastomosis can be attempted. However, our cases were better suited for vascularized lymph node transfer (VLNT) as per the LS finding of nodal absence in respective draining basin (axilla/groin) and surgeon's opinion. We present three cases of chronic lymphedema who displayed early spontaneous lymphangiogenesis 4–12 weeks' postsurgery. Although various etiologies can lead to lymphedema, we shall be presenting three cases of VLNT performed in our institute.

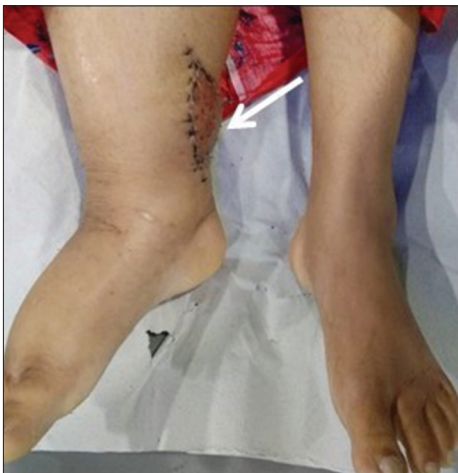

Figure 1: Case 1; Right ankle depicting graft site. Submental vascularized lymph node transfer was performed along right ankle (white arrow showing the flap placement). 3 - 4 subcentimetric healthy submental nodes with arterial supply were harvested with preserved architecture and transplanted at the ankle by making a pocket.

Case Report

Case 1: Vascularized lymph node transfer at right ankle

A 37-year-old female presented with right lower limb lymphedema of 17 years duration. There was a slow progressive increase in limb swelling and pain for the last 3 years, exacerbated for past 6 months. The patient had repeated episodes of lymphangitis almost every month for the past 6 months. Filariasis was clinically suspected. Initial baseline blood investigations such as hemogram, erythrocyte sedimentation rate, C reactive protein, blood sugar, urea, creatinine, calcium were done and a Doppler study of the right lower limb was performed. There was no evidence of deep vein thrombosis. The right saphenofemoral junction was found to be incompetent. There was subcutaneous edema in the right lower limb. The patient was subjected to MLD for 8 weeks and was prescribed antiedema medications (Tab. Torsemide 5 mg 1 daily, Tab. Glucosamine 1500 mg per day at night) for limb swelling reduction. Preoperative bilateral lower limb LS was done just prior to surgery [Figure 2a]. 800 microcurie of ^{99m}Tc nanocolloid (NC) in 0.4 ml volume (subcutaneous web space 2 injections [0.1 ml each] in each foot, using 1 ml syringe) was used. Images revealed lymphatic dysfunction-scintigraphic grade III obstruction of the right lower limb.^[4]

After plastic surgery expert panel discussion, the patient was considered for VLNT of right lower limb at the ankle. Submental VLNT was performed under general anesthesia. Supraclavicular flap harvest and markings done on the right side. Ellipsoid skin paddle was marked above the clavicle between the sternocleidomastoid (SCM) and the trapezius, with a size of 7 cm × 3 cm. Incision given (from the lateral border of SCM, 1 cm above the clavicle) and subplatysmal flaps raised. An external jugular vein was identified and included in the flap. Dissection done at the lateral border of SCM and the muscle was retracted. Deep dissection to identify the omohyoid was done, and muscle was divided, subsequently, identification of the transverse cervical vessels deep into the muscle was undertaken. Transverse cervical vessels were found to be anomalous with a tiny branch from the dorsal scapular artery in the plane deep to scalene and brachial plexus. Dissection was completed. Primary closure was done over a suction drain. Submental flap was harvested and donor site closed in layers over a suction drain. Recipient site: Lazy S incision was made on the medial aspect of the right leg above the medial malleolus. Subcutaneous dissection done, creating a compartment for flap insertion. Recipient vascular pedicle was identified and prepared (posterior tibial vessels). Anastomoses of flap artery and vein to posterior tibial artery and vein were performed with 9-0 nylon. Closure done with 4-0 nylon over a suction drain. Right Submental lymph node flap transfer to right ankle

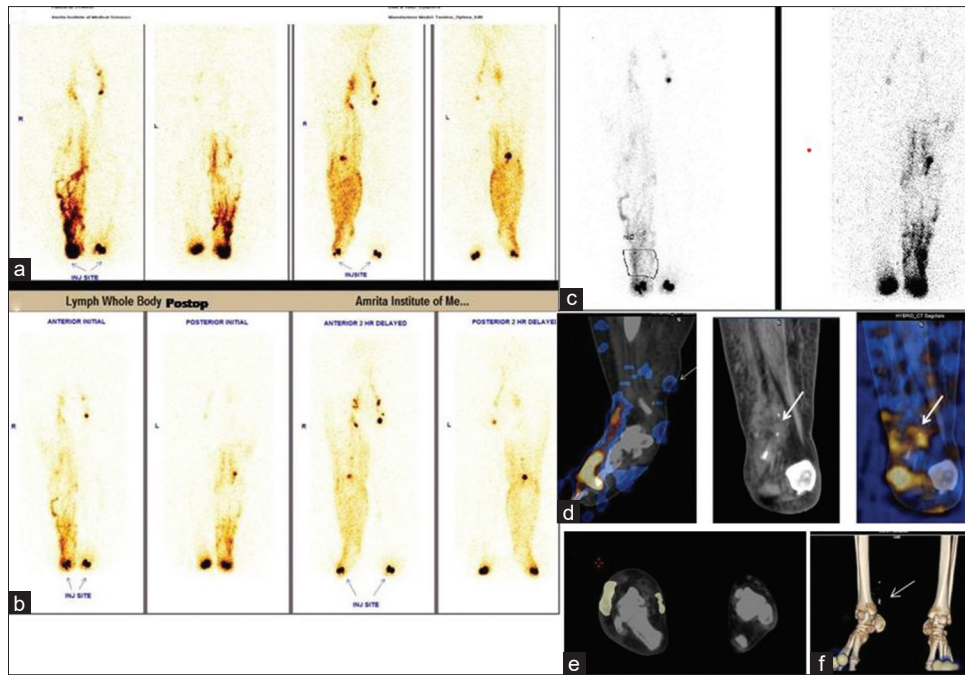


Figure 2: (Case 1): (a), Preoperative LS of bilateral lower limbs - Initial (anterior, posterior) images display significant obstruction to right lower limb superficial lymphatic channels (dilated lymphatic tracts with multiple collaterals/dilated channels, significant dermal backflow in dorsum and distal third of leg, abnormal solitary deep (popliteal) node visualization, and faintly seen right inguinal nodes –lymphatic dysfunction scintigraphic Grade III. There is normal lymphatic flow through the left lower limb. (b) Postoperative LS at 6 weeks. (c) Quantitative LS after surgery showing increasing counts at graft site. (d) Fused SPECTCT sag, CT coronal, fused SPECTCT coronal images, arrow showing functioning VLNT graft. (e) Fused transaxial. (f) 3D fused SPECTCT image with arrow pointing at graft site neolymphangiogenesis.

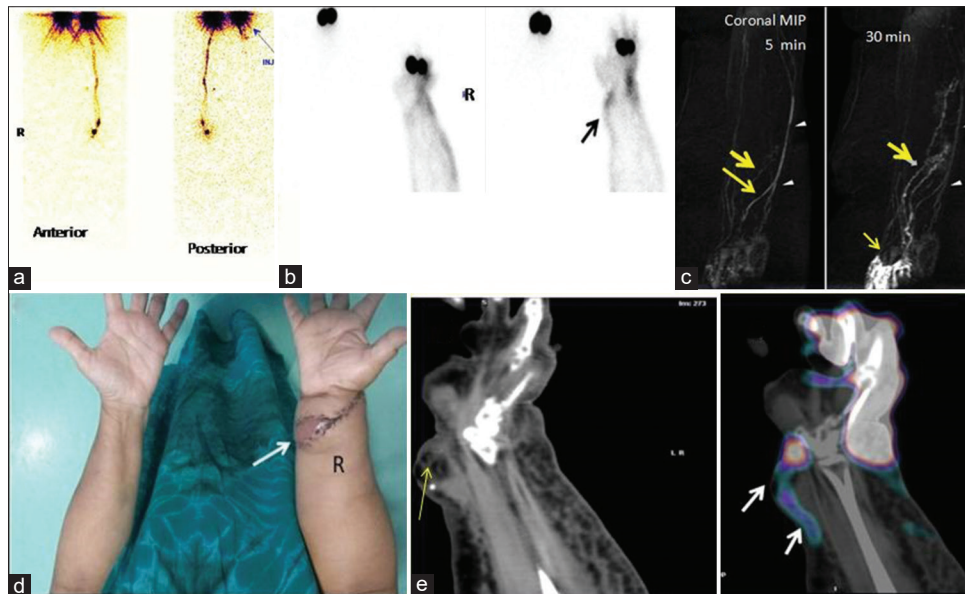


Figure 3: (Case II) (a) Preoperative LS upper limb images showing no discrete lymphatic channels in the right upper limb and no right axillary nodes. (b) Postop static image of right forearm showing count statics improvement at flap site. (c) MR lymphangiogram (coronal MIP) at 5 min and 30 min post contrast. Intracutaneous contrast administration showing enhancement of the subdermal lymphatic channels and veins (bold arrow). On dynamic MRL, the beaded and irregular lymphatic enhancement increases and progresses proximally with time (arrows) while venous enhancement (arrowheads) decreases. (d) Vascularized lymph node transfer site, (e) Noncontrast CT and fused SPECTCT images demonstrating colloid accumulation along new lymphatic channels at graft site (note: fat and surgical clips)

was performed [Figure 1]. Postoperative period was uneventful, and the patient was discharged with adequate antibiotic cover and analgesics after 3 days.

Pre and postoperative LS [Figure 2a, 2b] with single-photon emission computed tomography (SPECT) CT (GE Optima NM/CT 640) was performed at 6 weeks. The site was

aseptically cleaned, and freshly prepared radiotracer was used. A higher dose of radiocolloid was used to identify neo lymphangiogenesis. Three-four subcutaneous injections of 6 mCi ^{99m}Tc NC were given at 2 interdigital webspaces. Lower limbs followed by regional SPECT CT images at graft site were acquired immediately postinjection [Figure 2c quantitative SPECT]. There was a moderate reduction in dermal backflow in right dorsum and ankle. SPECT CT (noncontrast) images (128×128 matrix, zoom 1.2, 30 s/frame, 360° , step and shoot acquisition) showed focal sites of tracer uptake along the graft, fat and surgical clips at medial malleolus indicating possibly the onset of neo lymphangiogenesis [Figure 2d Fused sagittal, computed tomography [CT] and fused coronals, Figure 2e fused transaxial and 2f is three-dimensional fused image with arrow pointing at graft site neolymphangiogenesis]. Patient reported minimal reduction in swelling of limb at 6 weeks' follow-up.

Case II: Vascularized lymph node transfer right wrist

A 54-year-old female with diabetes mellitus complained of right upper limb progressive lymphedema. The patient a known case of carcinoma right breast underwent radical mastectomy and axillary clearance 4 years back. Her present complaints related to repeated episodes of lymphangitis especially for the past 6 months with inability to use the arm actively for more than 30 min. The patient has been treated conservatively but with no relief. Blood investigations including fasting/postprandial blood sugar evaluation were done followed by Doppler study of affected upper limb and ^{99m}Tc NC LS. The patient was scheduled for a VLNT from supraclavicular nodal location. Preoperative LS images showed discrete lymphatic tracts and axillary nodes on the left side with normal colloid transit [Figure 4A]. No discrete lymphatic tract and axillary nodes were seen in right upper limb, consistent with complete disruption of lymphatic channels. SPECTCT confirmed the anatomic absence of right axillary lymph nodes. Postoperative LS [Figure 4B] demonstrated improvement in count statistics at VLNT site after 4 weeks. MR lymphangiogram (MRL) with contrast was also acquired [Figure 4C]. Based on MRL findings, the patient was scheduled for VLNT under general anesthesia. Postoperative LS [Figure 4B] CT and fused SPECT CT coronal images showed focal site of colloid accumulation along the flap site and along the dermis demonstrating neolymphatic channels (arrow).

Case III – Vascularized lymph node transfer right groin

A 68-year-old male with suspected filariasis presented with longstanding right lower limb and scrotal lymphedema and lymphorrhea. The patient experienced frequent bouts of fever, scrotal pain, and inguinal swellings. Baseline blood investigations, ultrasound of scrotum, Doppler study of lower limbs were performed. On local examination, the patient had moderate edema of the right

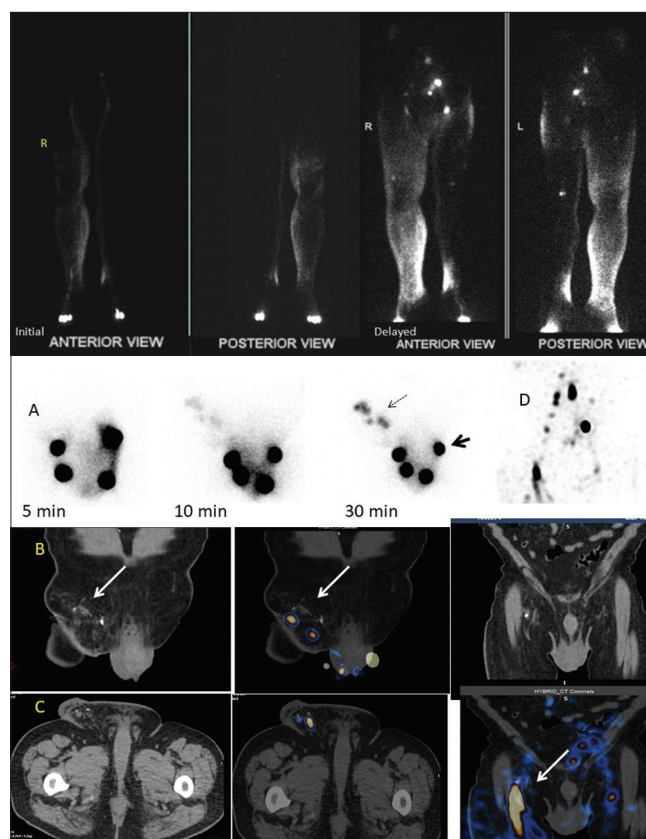


Figure 4: (Case III): (A) Multiple static pelvic images of ^{99m}Tc nanocolloid lymphoscintigraphy (Case III) done at 5 weeks postop. Intradermal injection was performed at 4 locations at base of scrotum (bold arrow). (B) Faint arrow shows the colloid accumulation depicting sites of functioning micro lymph nodes transplanted along right groin in coronal images. (C) Fused coronal image clearly depicts linear colloid tract along medial aspect of right groin indicating possibly the micro lymphatic tract restoration. (D) MIP image

lower limb extending to thigh and scrotum (Lymphangioma circumscriptum over the scrotum) and nonpitting edema over the pubic region. Lower abdomen was normal. The right inguinal lymph node excision biopsy revealed, suppurative granulomatous lymphadenitis. On special staining, (periodic acid–Schiff and, acid-fast bacteria), no microorganisms were seen. Possibilities include mycobacterial infections including atypical mycobacteria due to lymphogranuloma venereum. Tuberculosis (TB) polymerase chain reaction was negative for TB (done on slide block). Preoperative LS [Figure 4A] was reported as grade III lymphatic obstruction of right lower limb with faint accumulation of colloids in scrotum in delayed images (lymphedema of scrotum).

VLNT from the right supraclavicular lymph node was planned. The nodes were harvested and shredded to piecemeal and transferred to right groin intact with fat and vascular pedicle. Postoperative LS (6 mCi of ^{99m}Tc NC was injected intradermally at base of scrotum, 4 injections) done at 12 weeks. Static pelvis images were acquired at 5, 10, and 30 min postinjection. There was faint visualization of grafted nodes in right groin at 10th min image which showed higher

count statics in further delayed images. SPECT CT showed tiny nodes in right groin with focal colloid accumulation confirming functioning grafted nodes [Figure 4B]. On follow-up, clinically, there was symptomatic improvement of scrotal lymphedema and thigh swelling. There was an objective (75%) reduction in right lower limb, scrotal lymphedema and with no further lymphorrhea.

Discussion

⁹⁹mTc NCs are routinely used in the evaluation of lymphedema. We wanted to see if it can be extended as a promising imaging tool to establish neo lymphangiogenesis also. The process of forming new lymphatic channels from either preexisting vessels or as a result of VLNT is a new microsurgical technique being increasingly performed for lymphedema. For limb volume reduction, an additional liposuction is also contemplated.

Lymphangiogenesis is a response that occurs not only during normal development but also in adults during wound healing, inflammation, and as a result of cancer microenvironment.^[5] We found in our pilot study that NC was able to demonstrate sites of neo-lymphangiogenesis in early weeks localized to vascularized pedicle in all three patients after VLNT. Care needs to be taken to avoid false-positive LS findings postoperatively along with subcutaneous fat stranding in our limited experience. To circumvent this issue, SPECTCT images may be helpful. Similarly, LS can be undertaken at various time points to see if the new lymphatic channels are slowly but persistently being formed around VLNT.

VLNT has been found to be 98% successful as reported by Cheng *et al.*^[6] Outcomes were measured. They found greater functional improvements along with arm or leg circumference reduction, reduced episodes of cellulitis, and better quality of life. In 79% of patients, VLNT was preferred over LVA (21%), especially if no patent lymphatic channels were preoperatively evaluated on indocyanine green lymphography. The mechanism of reducing lymphedema in the affected limb is thought to take place by multiple ways. The absence of normal lymphatic channels requires bypassing the congested lymph/stasis through the transferred lymph nodes to the affected limb. Due to the positive interstitial pressure and the new lymphaticovenous connections provided, the stagnant lymph can be effectively drained into the newly anastomosed pedicle vein.^[7,8] The hydrostatic pressure results in the preferential removal of lymphatic fluid through the transferred lymph node flap into the draining venous system, which has been shown in prior studies.^[7]

VLNT promotes the regeneration of functional lymphatic vessels. Endothelial cells, along with keratinocytes, fibroblasts, macrophages, and platelets are involved in any healing process.^[6] However, the exact mechanism of perinodal lymphangiogenesis that takes place between the

transferred lymph node and the recipient lymphatic system has not been identified. Few researchers have used various animal models to study the effect of lymphatic regeneration. One such study by Suami *et al.*^[9] has used canine models to understand this lymphatic restoration mechanism. They investigated anatomical changes in the lymphatic system in the forelimb of a canine after lymph node dissection and irradiation.

Studies have shown that in case of chronic inflammation, lymphangiogenesis can get upregulated.^[10,11] Transferred lymph node and perinodal fat begin to express lymphangiogenic growth factors such as vascular endothelial growth factor C,^[12,13] and along with macrophage infiltration establish spontaneous reconnection to surrounding lymphatics. Yan *et al.*^[14] have reported lymphatic regeneration process in tail skin grafts in nude mice (recipients). Lymphatic regeneration occurred beginning at the peripheral edges of skin grafts, primarily from ingrowth of new lymphatic vessels originating from recipient mice. They also exhibited that donor lymphatic vessels appeared to spontaneously re-anastomosed with recipient vessels. However, the time frame for lymphatic regeneration and formation of discrete channels is unknown. In an animal study, it was observed that by inflammatory lymphangiogenesis,^[15,16] the gene expression of lymphatic endothelial cells is altered and leads to the lymphatic network expanding, along with increased fluid drainage both to and from the site of inflammation. Therefore, our pilot study is the first study on adult lymphedema patients documenting successful VLNT procedure. Second, it goes on to prove that LS can demonstrate lymphangiogenesis that starts as early as 4 weeks postoperative.

Conclusion

Our pilot study objectively demonstrates spontaneous perinodal lymphangiogenesis/upregulation of inflammatory lymphangiogenesis by LS. There are no human-based imaging reports to substantiate our hypothesis on literature search. Larger animal model studies and clinical trials on humans need to be performed to prove that lymphatic regeneration not only occurs around the graft but also along the entire involved limb to relieve lymphedema. We plan to enroll more number of patients and continue imaging patients at varying time points postsurgery to document if there is sustained improvement in establishing lymphatic network and flow around the VLNT site and limb.

Declaration of patient consent

The authors certify that they have obtained all appropriate patient consent forms. In the form the patient (s) has/have given his/her/their consent for his/her/their images and other clinical information to be reported in the journal. The patients understand that their names and initials will not be published and due efforts will be made to conceal their identity, but anonymity cannot be guaranteed.

Financial support and sponsorship

Nil.

Conflicts of interest

There are no conflicts of interest.

References

1. Auba C, Marre D, Rodríguez-Losada G, Hontanilla B. Lymphaticovenular anastomoses for lymphedema treatment: 18 months postoperative outcomes. *Microsurgery* 2012;32:261-8.
2. O'Brien BM, Chait LA, Hurwitz PJ. Microlymphatic surgery. *Orthop Clin North Am* 1977;8:405-24.
3. Koshima I, Inagawa K, Urushibara K, Moriguchi T. Paraumbilical perforator flap without deep inferior epigastric vessels. *Plast Reconstr Surg* 1998;102:1052-7.
4. Sundaram PS, Subramanyam P. Lymphoscintigraphy in the evaluation of limb edema. *Clin Nucl Med* 2013;38:891-903.
5. Alderfer L, Wei A, Hanjaya-Putra D. Lymphatic tissue engineering and regeneration. *J Biol Eng* 2018;12:32.
6. Ito R, Zelken J, Yang CY, Lin CY, Cheng MH. Proposed pathway and mechanism of vascularized lymph node flaps. *Gynecol Oncol* 2016;141:182-8.
7. Cheng MH, Huang JJ, Wu CW, Yang CY, Lin CY, Henry SL, *et al.* The mechanism of VLNT for lymphedema: Natural lymphaticovenous drainage. *Plast Reconstr Surg* 2014;133:192e.
8. Ciudad P, Sabbagh MD, Agko M, Huang TC, Manrique OJ, Carmen RL, *et al.* Surgical management of lower extremity lymphedema: A comprehensive review. *Indian J Plast Surg* 2019;52:81-92.
9. Suami H, Yamashita S, Soto-Miranda MA, Chang DW. Lymphatic territories (lymphosomes) in a canine: An animal model for investigation of postoperative lymphatic alterations. *PLoS One* 2013;8:e69222.
10. Barrientos S, Stojadinovic O, Golinko MS, Brem H, Tomic-Canic M. Growth factors and cytokines in wound healing. *Wound Repair Regen* 2008;16:585-601.
11. Viitanen TP, Visuri MT, Hartiala P, Mäki MT, Seppänen MP, Suominen EA, *et al.* Lymphatic vessel function and lymphatic growth factor secretion after microvascular lymph node transfer in lymphedema patients. *Plast Reconstr Surg Glob Open* 2013;1:1-9.
12. Chang EI, Skoracki RJ, Chang DW. Lymphovenous anastomosis bypass surgery. *Semin Plast Surg* 2018;32:22-7.
13. Raju A, Chang DW. Vascularized lymph node transfer for treatment of lymphedema: A comprehensive literature review. *Ann Surg* 2015;261:1013-23.
14. Yan A, Avraham T, Zampell JC, Aschen SZ, Mehrara BJ. Mechanisms of lymphatic regeneration after tissue transfer. *PLoS One* 2011;6:e17201.
15. Joseph WJ, Aschen S, Ghanta S, Cuzzzone D, Albano N, Gardenier J, *et al.* Sterile inflammation after lymph node transfer improves lymphatic function and regeneration. *Plast Reconstr Surg* 2014;134:60-8.
16. Beerens M, Aranguren XL, Hendrickx B, Dheedene W, Dresselaers T, Himmelreich U, *et al.* Multipotent adult progenitor cells support lymphatic regeneration at multiple anatomical levels during wound healing and lymphedema. *Sci Rep* 2018;8:3852.