

## OPEN

# Antithrombin Perfluorocarbon Nanoparticles Improve Renal Allograft Function in a Murine Deceased Criteria Donor Model

Chandu Vemuri, MD,<sup>1,2</sup> Gundumi A. Upadhyaya, MD,<sup>1</sup> Batool Arif, MD,<sup>1</sup> Jianluo Jia, MD,<sup>1</sup> Yiing Lin, MD, PhD,<sup>1</sup> Joseph P. Gaut, MD, PhD,<sup>3,4</sup> Jawad Fazal, MD,<sup>5</sup> Hua Pan, MD,<sup>5</sup> Samuel A. Wickline, MD,<sup>3,5</sup> and William C. Chapman, MD<sup>1</sup>

**Background.** Over 100000 patients await renal transplantation and 4000 die per year. Compounding this mismatch between supply and demand is delayed graft function which contributes to short-term and long-term graft failures. Previously, we reported that thrombin-targeted perfluorocarbon nanoparticles (PFC-NP) protect kidneys from ischemic renal injury after transient arterial occlusion. Here we hypothesize that perfusion of renal allografts with PFC-NP similarly can protect graft function after an ischemic interval. **Methods.** After 60 minutes of warm ischemia, male Lewis rats underwent left renal explantation followed by renal perfusion with 5 mL of standard perfusate alone (N = 3) or with 0.3 mL of untargeted PFC-NP (N = 5) or 0.3 mL thrombin-targeted PFC NP functionalized with phenylalanine-proline-arginine-chloromethylketone (PPACK) (PFC-PPACK), an irreversible thrombin inhibitor (N = 5). Kidneys underwent 6 hours of cold storage, followed by transplantation into recipients and native nephrectomy. Animals were euthanized at 24 hours for tissue collection or at 48 hours for blood and renal tissue collection. A survival experiment was performed using the same protocol with saline control (N = 3), PFC-NP (N = 3) or PFC-PPACK (N = 6). **Results.** Serum creatinine was improved for the PFC-PPACK groups as compared with control groups ( $P < 0.04$ ). Kaplan-Meier survival curves also indicated increased longevity ( $P < 0.05$ ). Blinded histologic scoring revealed markedly attenuated renal damage in the PFC-PPACK group compared to untreated animals ( $2.75 \pm 1.60$  versus  $0.83 \pm 3.89$ ;  $P = 0.0001$ ) and greater preservation of renal vasculature. **Conclusions.** These results validate an NP-based approach to improve renal graft function as antithrombin NPs improved allograft function, decreased renal damage, protected vasculature, and improved longevity.

(*Transplantation Direct* 2018;4: e384; doi: 10.1097/TXD.0000000000000817. Published online 21 August, 2018.)

In the United States alone, over 100000 patients are listed for renal transplantation for end-stage renal disease with an expected median wait time of 3.6 years. The incidence of renal failure requiring transplant is expected to increase while the number of available organs remains limited. This mismatch of supply and demand results in more than 4000 deaths per year. ([www.kidney.org/news/newsroom/factsheets/Organ-Donation-and-Transplantation-Stats](http://www.kidney.org/news/newsroom/factsheets/Organ-Donation-and-Transplantation-Stats)).

To address this critical shortage, donor organs are sought from living donors and deceased donors with extended criteria in specific circumstances. As critical as it is to receive a renal transplant, it is equally important that the transplant performs well in the recipient. One aspect needing improvement is renal preservation after organ recovery. Currently, after explantation, organs are perfused with University of Wisconsin's (UW) preservation solution and stored at 4°C. Although cold perfusion is intended to decrease cellular metabolism and

Received 11 October 2017. Revision requested 19 June 2018.

Accepted 19 June 2018.

<sup>1</sup> Department of Surgery, Washington University in Saint Louis, Saint Louis MO.

<sup>2</sup> Department of Surgery, University of Michigan, Ann Arbor MI.

<sup>3</sup> Department of Medicine, Washington University in Saint Louis, Saint Louis MO.

<sup>4</sup> Department of Pathology and Immunology, Washington University in Saint Louis, Saint Louis MO.

<sup>5</sup> Department of Cardiovascular Sciences, University of South Florida, Tampa, FL.

Funding from SA Wickline R01 DK102691, R01 HL073646; U54 HL112303.

The authors declare no conflicts of interest.

C.V. designed and conducted experiments, analyzed and reviewed data, wrote and revised the article. G.A.U. designed and conducted the experiments, and revised the article. B.A. helped conduct the experiments and revised the article. J.J. performed the animal experiments. Y.L. helped with the design of experiments, data analysis and review, and revised the article. J.P.G. performed all blinded histologic grading,

data analysis, article writing and revision. J.F. performed histology on the animals. H.P. participated in the experimental design, data analysis and review, article writing and revision. S.A.W. participated in the experimental design, production and testing of nanoparticles, data analysis and review, article writing and revision. W.C.C. participated in the experimental design, animal work performed in his lab, data analysis and review, article writing and revision.

Correspondence: Chandu Vemuri, MD, CVC 5383 1500 East Medical Center Drive, SPC 5867 Ann Arbor, MI 48109. (cvemuri@med.umich.edu).

Copyright © 2018 The Author(s). *Transplantation Direct*. Published by Wolters Kluwer Health, Inc. This is an open-access article distributed under the terms of the Creative Commons Attribution-Non Commercial-No Derivatives License 4.0 (CCBY-NC-ND), where it is permissible to download and share the work provided it is properly cited. The work cannot be changed in any way or used commercially without permission from the journal.

ISSN: 2373-8731

DOI: 10.1097/TXD.0000000000000817

reduce cellular injury, significant ischemia reperfusion injury (IRI) may occur. Ischemia-reperfusion injury causes delayed graft function, long-term graft dysfunction, and poor overall patient outcomes. Thus, a clear clinical need exists for better renal preservation postexplantation.<sup>1-4</sup>

Thrombin is one agent that plays a role in IRI. Thrombin adversely affects renal transplant outcomes through activation of the coagulation cascade and subsequent microvascular thrombosis. Furthermore, thrombin can activate protease-activated receptors, which are abundant in the kidney, resulting in a proinflammatory state.<sup>5</sup> Systemic thrombin inhibition has been shown to be effective in improving renal acute and chronic allograft function in animal models.<sup>6</sup> However, systemic thrombin inhibition is accompanied by bleeding risk that limits its use in the setting of major surgery, such as renal transplantation.

Here we propose nanoparticle (NP)-based antithrombin therapy as a safer strategy for renal preservation when incorporated into a preservation solution. We have developed a perfluorocarbon NP (PFC-NP) platform that inhibits thrombin locally without causing a bleeding diathesis, and which forestalls thrombin signaling and microvascular thrombosis in atherosclerosis and renal ischemic injury.<sup>7-10</sup> To this end, PFC-NP were modified to incorporate a well-known antithrombin moiety, proline-phenylalanine-arginine-chloromethylketone (PPACK), which has been shown to limit acute kidney injury following transient warm ischemia in murine models with no systemic toxicity or bleeding risk.<sup>9,10</sup> Accordingly, in this work, we sought to determine if perfusion of explanted kidneys with antithrombin NPs might improve graft function in a rodent model of deceased criteria donor renal transplantation.

## MATERIALS AND METHODS

### Animal Protocol

Animal experiments were approved by the Washington University Animal Studies Committee. Male Lewis rats (275Y300 g; Charles River Laboratories, Wilmington, MA) were housed in controlled environments. The experimental procedural time line is shown in Figure 1. The donor animal was anesthetized with 2% isoflurane, and the left kidney was mobilized. The aorta was clamped proximal and distal to the renal arteries to create 60 minutes of warm ischemia, and kidneys were explanted and manually perfused through a 25-gauge needle with 5 mL of UW alone (N = 3) or along with 0.3-mL PFC-NP (N = 5) or 0.3-mL PFC-PPACK (N = 5).

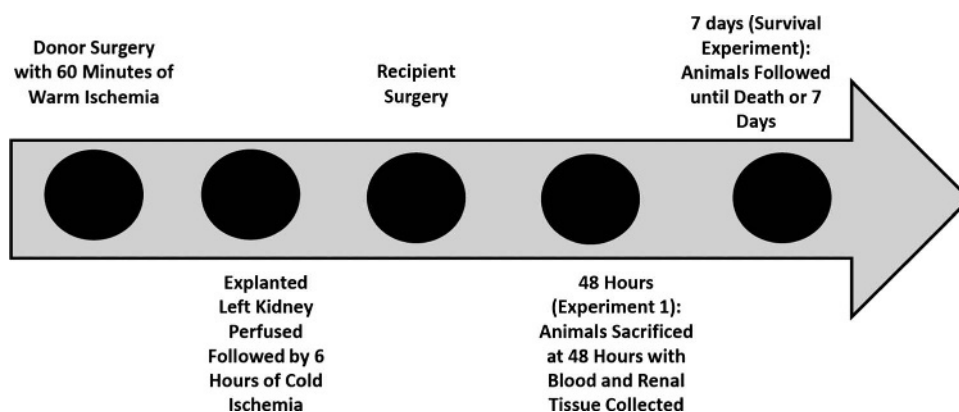
The infrarenal inferior vena cava was transected distal to the renal veins. The left kidney was then placed in UW to create 6 hours of cold ischemia. A syngeneic recipient was then anesthetized, and a left nephrectomy was performed. The transplant was performed first with the arterial anastomosis using the end-in-end sleeve technique in which the recipient renal artery was telescoped into the donor renal artery and then fixed in place with sutures.<sup>11</sup> The donor inferior vena cava was anastomosed end-to-end using a cuff technique. The donor renal vein was passed through and then everted through a cuff. The donor cuffed vein was then telescoped through the recipient renal vein and then fixed into place with sutures. The ureter was anastomosed to the bladder, and a right nephrectomy was performed.<sup>12</sup> For short-term assessment, rats were euthanized at 48 hours and blood and renal tissue collected. The same protocol was followed to obtain additional renal tissue for histologic analysis: saline alone (N = 3) or PFC-PPACK (N = 3), euthanized at 24 hours. For survival assessment, the same protocol was followed (saline alone [N = 3], PFC-NP [N = 3], PFC-PPACK [N = 6]) with postoperative observation until death.

### Blood Sample and Tissue Processing

Blood was processed at the Core Research Animal Diagnostic Laboratory, Washington University School of Medicine. The samples were analyzed using the LIASYS 330 (Charleston, SC) clinical chemistry system and blood urea nitrogen (BUN) and creatinine reported in mg/dL.

The transplanted kidney was excised at the time of euthanasia, formalin-fixed, and paraffin embedded and then stained with hematoxylin and eosin (H&E). All microscopic evaluations were performed blinded by a single pathologist (J.P.G.) using an Olympus BX51 (Melville, NY) microscope outfitted with an Olympus DP71 (Melville, NY) digital camera. Five representative digital images of the renal cortex were sampled randomly from 1 representative H&E-stained section and photographed at 400× magnification. All tubules in each image were counted and scored as necrotic (coagulative-type necrosis) or viable. The ratio of necrotic to total tubules was used as a quantitative assessment of acute tubular necrosis. Vascular injury was scored in a similar fashion, and injury was established by necrosis of the vascular wall.

To quantify overall renal vascular prevalence, rats received an intravenous injection of 500 µL of DyLight 594 labeled Lycopersicon Esculentum (tomato) lectin (Cat: DL-1177; Vector Labs, Burlingame, CA). Excised kidneys were embedded



**FIGURE 1.** Timeline of experimental procedures.

in O.C.T. (Cat: 102094-106; VWR, Radnor, PA) and sectioned for fluorescence microscopic imaging using an Axio Scan.Z1 (Zeiss, Thornwood, NY). All images were acquired at the same power settings, exposure times, and digitization parameters. Total lectin fluorescence intensity of whole kidney sections served as a surrogate for vascular preservation as analyzed with ImageJ (NIH, Bethesda, MD).

### NP Formulation

Perfluorocarbon NP (~250 nm) were formulated with either perfluorooctylbromide (PFOB) or perfluoro-15-crown-5-ether (CE) as previously described.<sup>9</sup> The PFOB emulsion was composed of 20% (vol/vol) of PFOB (Exflur Research), 2.0% (wt/vol) of a surfactant commixture, and 1.7% (w/vol) glycerin, with water comprising the balance. The CE emulsion was composed of 40% (vol/vol) of CE (Exflur Research), 2.0% (wt/vol) of a surfactant commixture, and 1.7% (wt/vol) glycerin, with water comprising the balance. Phenylalanine-proline-arginine-chloromethylketone was conjugated to the PFOB NP using a previously reported method that loaded ~13650 PPACK moieties per particle.<sup>9</sup>

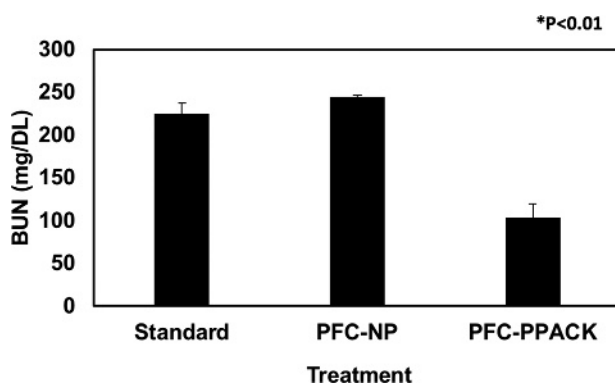
### Statistical Analysis

All statistical analyses were performed with SAS software (SAS Institute). Quantitative data (BUN, creatinine, vascular preservation) are reported as mean  $\pm$  SEM. Analysis of variance (ANOVA) and unpaired Student *t* test was used to determine statistical differences. The log-rank test was used to analyze survival for PFC-NP and PFC-PPACK groups.

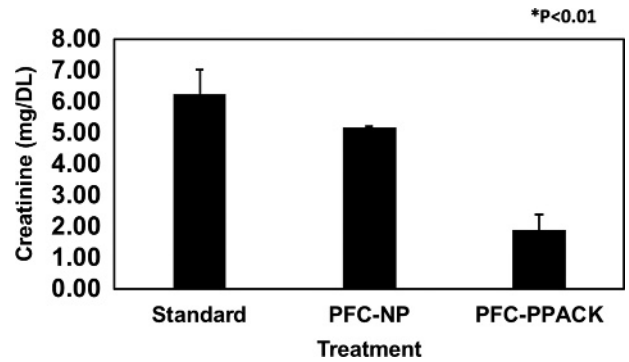
## RESULTS

### Renal Functional Data

The standard perfusate group exhibited a mean BUN (mg/dL) of  $225.33 \pm 11.62$ , the PFC-NP a mean of  $245.33 \pm 1.33$ , and the PFC-PPACK group a mean of  $103.00 \pm 17.04$  (Figure 2). For creatinine (mg/dL), the standard perfusate group exhibited a mean of  $6.25 \pm 0.70$ , the PFC-NP a mean of  $5.16 \pm 0.06$  and the PFC-PPACK group a mean of  $1.89 \pm 0.50$  (Figure 3). By ANOVA, a statistically significant difference was observed between treatment and control groups for both BUN and creatinine ( $P < 0.05$ ). No bleeding complications were observed in any group.



**FIGURE 2.** Improved renal allograft function in treatment ( $n = 5$ ) versus control groups at 48 hours (standard,  $n = 3$ ; PFC-NP,  $n = 5$ ). The y-axis represents serum BUN level and the x-axis is treatment group. \*Statistically significant difference between PFC-PPACK and control groups by ANOVA ( $P < 0.01$ ).



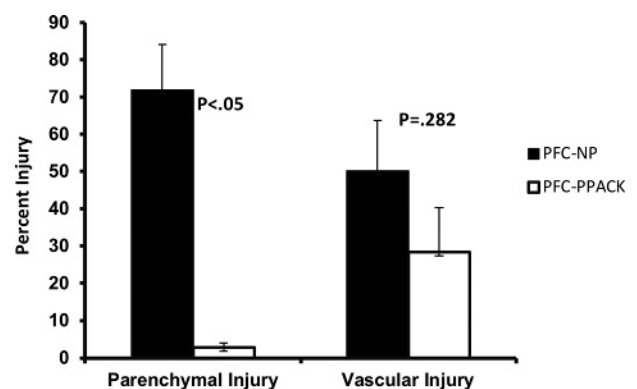
**FIGURE 3.** Improved renal allograft function in treatment ( $n = 5$ ) versus control groups at 48 hours (standard,  $n = 3$ ; PFC-NP,  $n = 5$ ). The y-axis represents serum creatinine and the x-axis is treatment group. \*Statistically significant difference between PFC-PPACK and control groups by ANOVA ( $P < 0.01$ ).

### Renal Parenchymal and Vascular Injury

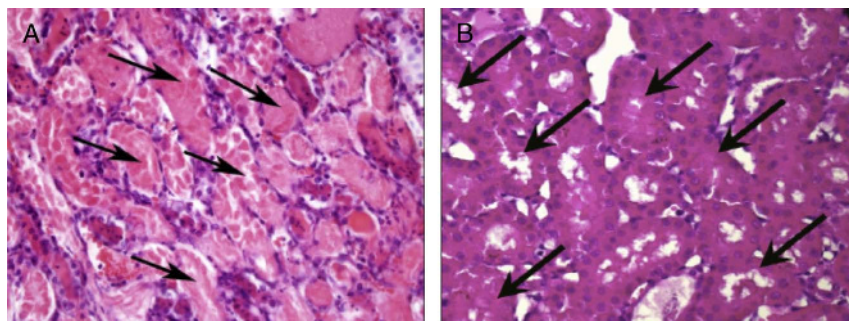
The ratio of necrotic to intact tubules was used as a metric of renal injury. The percentage (%) of parenchymal tubular necrosis in the PFC-NP group was  $71.9 \pm 2.8$  versus  $12.19 \pm 1.24$  in the PFC-PPACK group ( $P < 0.05$ ; Student *t* test). No arteries exhibited intimal mucoid edema, thrombi, or fragmented red blood cells within the vascular walls. The ratio of injured vessels to total number of vessels (%) was used to quantify vascular injury. Vascular injury in the PFC-NP was  $50.14 \pm 13.56$  versus  $28.4 \pm 12.04$  in the PFC-PPACK group ( $P = 0.282$ ; Student *t* test) (Figures 4-6). Analysis of renal vasculature preservation with lectin staining (arbitrary units) revealed significantly greater signal in the PFC-PPACK group compared with saline control  $3672.92 \pm 274.74$  versus  $2098.39 \pm 426.38$  ( $P = 0.006$ ; Student *t* test) (Figures 7-8).

### Survival Data

Given the severe nature of the renal injury, all subjects expectedly died from renal failure, although longevity was lengthened in the treated group. The mean survival in the group treated with PFC-PPACK was 6 days versus 4 days for the control groups (PFC-NP and saline) (Figure 9), which



**FIGURE 4.** Parenchymal and vascular injury after treatment ( $N = 5$ ) versus PFC-NP control ( $N = 3$  per group). The y-axis represents percent injury and the x-axis is treatment group grouped by metric after 48 hours. There was a statistically significant difference in parenchymal injury ( $P < 0.05$ ) and no significant difference in vascular injury ( $P = 0.282$ ).



**FIGURE 5.** A, Representative image of a saline treated kidney demonstrating marked coagulative type acute tubular necrosis (arrows) (H&E, 400 $\times$ ). B, Representative image of a PFC-PPACK treated kidney with essentially no observable tubular necrosis (arrows) (H&E, 100 $\times$ ).

was statistically significant by log-rank survival analysis ( $P = 0.005$ ).

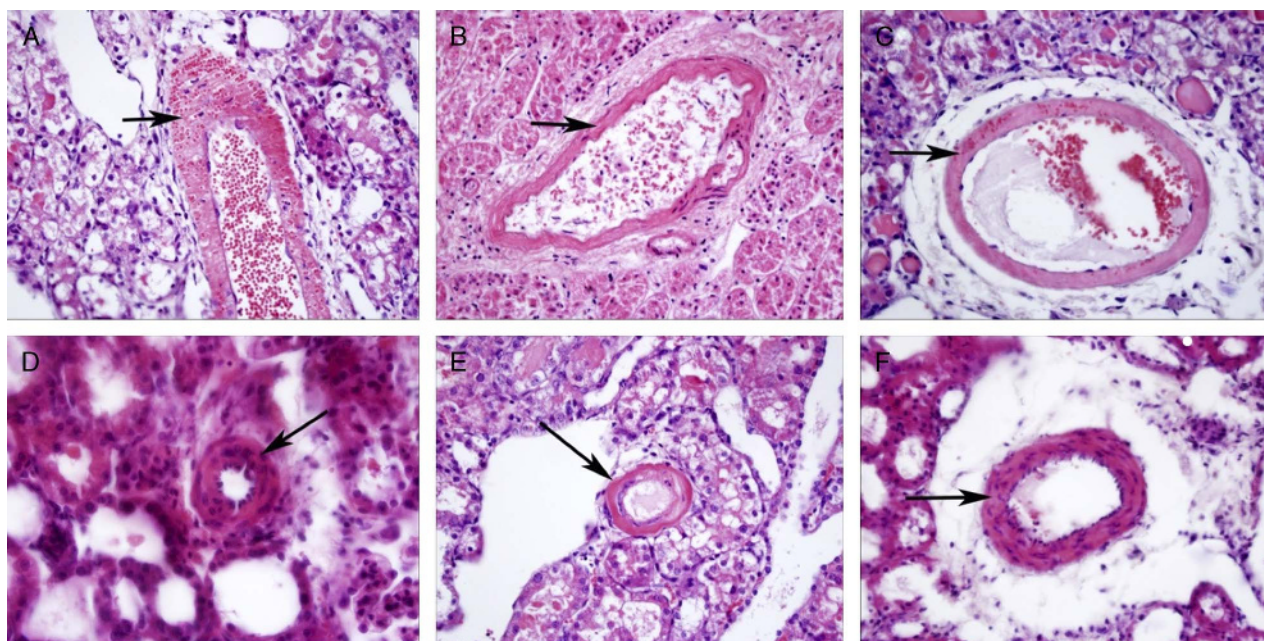
## DISCUSSION

The incidence of end-stage renal disease requiring transplant continues to rise yet there is a critical shortage of available organs. Compounding this shortage is the issue of acute and delayed graft function that often ensues from inadequate protection of explanted organs. Furthermore, patients with poor graft function suffer worse outcomes with respect to function of the transplanted organ and overall survival. Improvements in surgical technique and immunosuppressive therapies have improved outcomes, but transplanted organs can suffer significant IRI after the pretransplant period of warm and/or cold ischemia.<sup>1-3</sup> Unfortunately, specific therapies that address IRI in renal transplant during renal preservation are lacking.

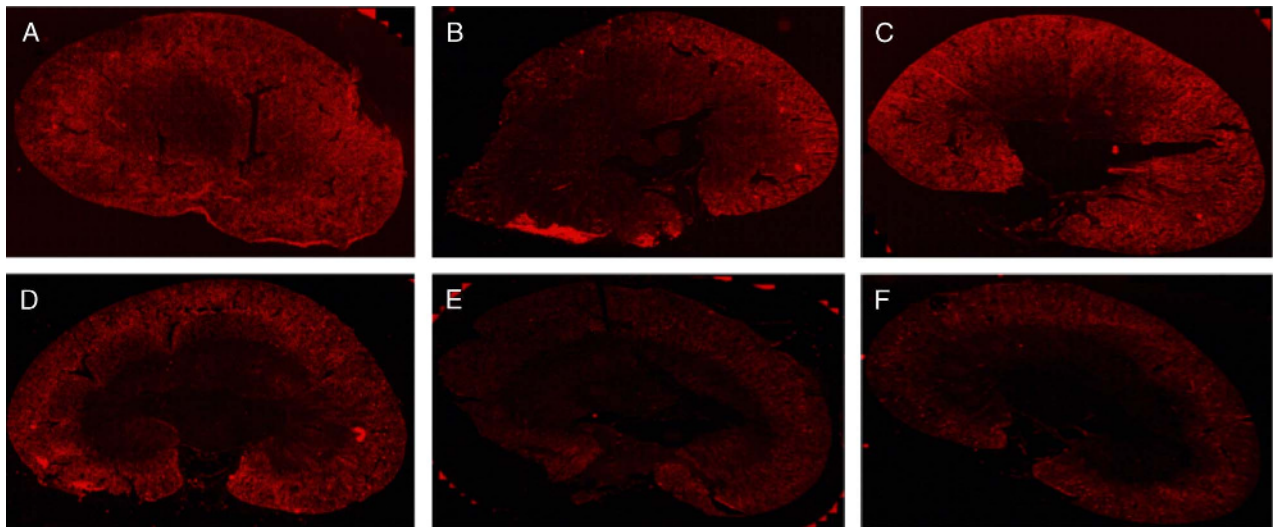
After transient ischemia, reperfusion results in immediate renal injury due to a combination of microvascular thrombosis and inflammation which then synergistically compound renal injury during the extension phase.<sup>13</sup> Thrombin is involved in IRI in both microvascular thrombosis and activation of

proinflammatory pathways through vascular protease activated receptors.<sup>5</sup> Other groups have reported improved acute and chronic graft function for renal allografts in pigs systemically treated with the intravenous thrombin inhibitor Megaltran.<sup>6</sup> However, this therapy has not been adopted for routine patient care as recent reports have noted a surprising risk of glomerular hemorrhage and tubular obstruction with the direct thrombin inhibitor dabigtran.<sup>14</sup>

Accordingly, an opportunity exists to develop more selective and targeted therapeutics to limit IRI in renal grafts. We have reported previously the development of a safe and effective PFC-NP platform for cardiovascular imaging and therapeutics.<sup>7,8</sup> Perfluorocarbon NP consist of a liquid PFC core encapsulated by an outer phospholipid shell in a diameter range of 160 to 300 nm. These particles can be functionalized by surface modifications through covalent incorporation of targeting molecules situated in the lipid shell. Here we used PPACK to serve an irreversible inhibitor of thrombin on PFC-NP. Native PPACK is plagued by a short half-life when used systemically as a single agent, rendering it clinically ineffective. However, incorporation of PPACK into an NP allows targeted delivery of substantial quantities of the antithrombin agent per each PFC-NP to the sites of active vascular



**FIGURE 6.** Representative images highlighting renal vascular injury in the PFC-NP (A-C) group compared with PFC-NP PPACK (D-F).



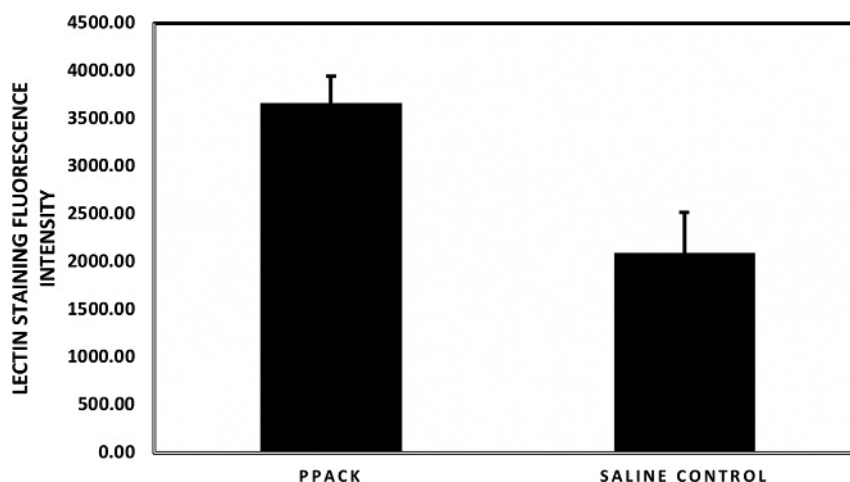
**FIGURE 7.** Representative images illustrating preservation of renal vasculature after treatment. Greater lectin staining is apparent in kidneys treated with PFC-NP PPACK (A-C) as compared to saline (D-F) treatment.

thrombosis while limiting bleeding risk due to rapid diminution of systemic anticoagulant effect via hepatic sequestration of nontargeted particles.<sup>8,9</sup> We have demonstrated previously the ability of PFC-NP PPACK to decrease the time to occlusion in a murine model of arterial injury while only transiently affecting systemic coagulation parameters for less than 60 minutes as the PFC-NP are cleared.<sup>9</sup> Moreover, we have shown that PFC-NP PPACK can attenuate renal injury after transient warm ischemia in a murine model of renal ischemia.<sup>10</sup>

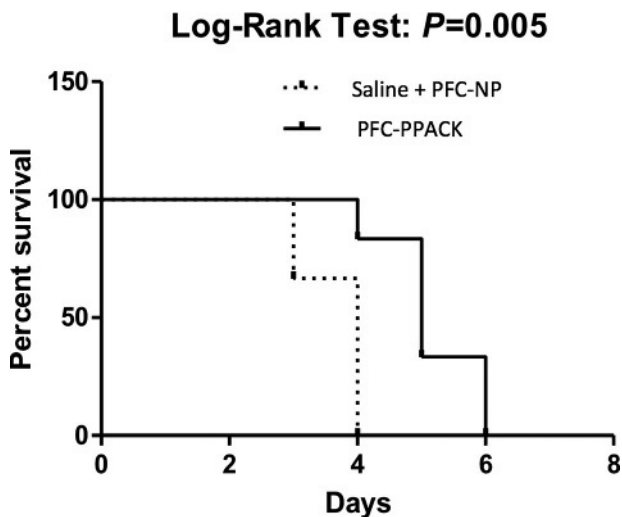
We hypothesized that by perfusing explanted organs with PFC-NP PPACK, we could preserve acute graft function, prevent renal parenchymal and vascular injury, and improve animal survival. Although PPACK itself is not entirely specific for thrombin, it is clearly useful in this ex vivo application. To demonstrate the flexibility of this approach, we have reported the substitution of more selective inhibitors of thrombin such as bivalirudin.<sup>9</sup> Regardless of the specific clot inhibiting moiety incorporated, the pharmacokinetics of the PFC-NP depends only on the particle itself and systemic clotting parameters and bleeding times normalize after 30-60 min when

administered intravenously.<sup>9</sup> Of note, we choose to treat the explanted donor kidneys before cold perfusion to prevent local activation of thrombin during cold perfusion. Using this approach, there were no apparent bleeding complications in the recipient animals.

The present data demonstrate improvements in acute graft function according to BUN and creatinine measures. Blinded histologic analysis revealed significantly decreased renal tubular necrosis but a nonsignificant trend toward reduced vascular injury in the treatment groups as compared to controls. Additionally, despite the severe injury imposed by this murine deceased criteria donor renal transplant model, the PFC-NP PPACK treatment extended survival from 4 to 6 days as compared with standard therapy. To begin to explore the basis for improved renal allograft function, we performed vascular staining with lectin and observed significantly greater vascular abundance in the PFC-NP PPACK treated animals. We suggest that the preservation of renal vasculature may represent in part a physiological basis for improved allograft function in the PFC-NP PPACK groups by limiting vascular



**FIGURE 8.** Vascular preservation according to lectin staining after treatment in the PPACK treated (N = 3) versus saline control treated (N = 3) group ( $P < 0.05$ ). The y-axis represents lectin staining fluorescence intensity (arbitrary units (a.u.)) and the x-axis is treatment group at 24 hours.



**FIGURE 9.** Survival times after treatment. Male Lewis Rats underwent left renal explantation followed by perfusion of standard solution with normal saline control ( $n = 3$ ), PFC-NP ( $n = 3$ ) or PFC-PPACK ( $n = 6$ ). Kidneys then underwent 60 minutes of warm ischemia and 6 hours of cold incubation, followed by transplantation into recipients and native nephrectomy. The y-axis represents percent survival and the x-axis represents days posttransplant. The treatment group exhibited extended survival as compared to the control group ( $P = 0.005$  by log-rank analysis).

pruning after IRI. We speculate that the lack of statistical significance for vessel injury metrics can be attributed to the subsequent pruning and dissolution of irreversibly damaged vessels and partial to near complete recovery of those reversibly damaged. It should be noted that lectin staining of endothelium is only 1 method for examining vascular integrity but it is objective when applied to the entire organ as compared with selections of regions of interest for vascular counting, and it poses an interesting subject for future investigation.

This work is subject to several limitations. Importantly, this is a pilot trial of PFC-NP PPACK in a limited set of experimental subjects addressing acute parameters. Ultimately, additional studies with larger numbers will be required to confirm long-term benefits. However, it is known that acute graft function after implantation correlates directly with long-term graft function.<sup>1,2</sup> The particular dosing regimen with respect to drug volume, amount, and timing of administration were extrapolated from other work and can be refined experimentally. Additionally, as the organs were perfused with NPs before cold storage and transplantation, there was no actual verification of local inhibition of thrombin by PFC-NP PPACK. However, as there is only a single active pharmacological ingredient that yields a known antithrombotic function that is several orders of magnitude more potent for thrombin

versus Factor Xa, it is highly likely that thrombin inhibition is responsible for the functional salvage.<sup>8,9</sup> Lastly, the animal model used may not be entirely representative of the human transplant situation and therefore results could differ in translation to patients.

In conclusion, renal graft IRI continues to hinder acute and long-term kidney function after renal transplantation. There is a clear clinical need for more selective prophylactic therapeutics to enhance renal preservation. This work demonstrates the potential beneficial effects of PFC-NP PPACK on both functional and structural measures of renal graft injury and suggests improved acute survival. Future work will be aimed at understanding the mechanistic basis of these results and optimizing this therapy to improve outcomes in human transplantation of kidneys and other organs.

## REFERENCES

- Quiroga I, McShane P, Koo DD, et al. Major effects of delayed graft function and cold ischaemia time on renal allograft survival. *Nephrol Dial Transplant*. 2006;21:1689–1696.
- Requião-Moura LR, Durão Mde S, Tonato EJ, et al. Effects of ischemia and reperfusion injury on long-term graft function. *Transplant Proc*. 2011;43:70–73.
- Legrand M, Mik EG, Johannes T, et al. Renal hypoxia and dysoxia after reperfusion of the ischemic kidney. *Mol Med*. 2008;14:502–516.
- Vardanian AJ, Busuttill RW, Kupiec-Weglinski JW. Molecular mediators of liver ischemia and reperfusion injury: a brief review. *Mol Med*. 2008;14:337–345.
- Madhusudhan T, Kerlin BA, Isermann B. The emerging role of coagulation proteases in kidney disease. *Nat Rev Nephrol*. 2016;12:94–109.
- Thuillier R, Favreau F, Celhay O, et al. Thrombin inhibition during kidney ischemia-reperfusion reduces chronic graft inflammation and tubular atrophy. *Transplantation*. 2010;90:612–621.
- Palekar RU, Jallouk AP, Lanza GM, et al. Molecular imaging of atherosclerosis with nanoparticle-based fluorinated MRI contrast agents. *Nanomedicine (Lond)*. 2015;10:1817–1832.
- Palekar RU, Jallouk AP, Myerson JW, et al. Inhibition of thrombin with PPACK-nanoparticles restores disrupted endothelial barriers and attenuates thrombotic risk in experimental atherosclerosis. *Arterioscler Thromb Vasc Biol*. 2016;36:446–455.
- Myerson J, He L, Lanza G, et al. Thrombin-inhibiting perfluorocarbon nanoparticles provide a novel strategy for the treatment and magnetic resonance imaging of acute thrombosis. *J Thromb Haemost*. 2011;9:1292–1300.
- Chen J, Vemuri C, Palekar RU, et al. Antithrombin nanoparticles improve kidney reperfusion and protect kidney function after ischemia-reperfusion injury. *Am J Physiol Renal Physiol*. 2015;308:F765–F773.
- Pahlavan PS, Smallegange C, Adams MA, et al. Kidney transplantation procedures in rats: assessments, complications, and management. *Microsurgery*. 2006;26:404–411.
- Lin Y, Manning PT, Jia J, et al. CD47 blockade reduces ischemia-reperfusion injury and improves outcomes in a rat kidney transplant model. *Transplantation*. 2014;98:394–401.
- Molitoris BA, Sutton TA. Endothelial injury and dysfunction: role in the extension phase of acute renal failure. *Kidney Int*. 2004;66:496–499.
- Holmes D. Acute kidney injury: renal hazards of anticoagulant therapy. *Nat Rev Nephrol*. 2013;9:625.