

# Anterior cruciate ligament (ACL) injuries: A review on the newest reconstruction techniques

Mohamad Hadi Gerami<sup>1</sup>, Farshid Haghi<sup>2</sup>, Ferdos Pelarak<sup>3</sup>,  
Seyed Rohallah Mousavibaygei<sup>4</sup>

<sup>1</sup>Bone and Joint Disease Center of Shiraz University of Medical Sciences, Shiraz, Iran, <sup>2</sup>Student of Dalian Medical University, Dalian, Liaoning, China, <sup>3</sup>Department of Nursing, Dezful Branch, Islamic Azad University, Dezful, <sup>4</sup>Assistant Professor, Qom University of Medical Sciences, Qom, Iran

## ABSTRACT

The anterior cruciate ligament (ACL) is considered very important for normal knee function, the disruption of which may result in malfunction, meniscal lesions, and the early onset of joint degeneration. The aim of this comprehensive review was to investigate the different techniques used in the reconstruction of damaged ACL. Current methods in reconstruction of ACL include different types of autograft and allograft to replace native ligaments. The ideal graft for reconstruction of ACL is one which is biomechanically similar to the native ligament, is easily harvested, has least harvest site morbidity, and gets well incorporated with the bone. Cross-fixing of hamstrings has been created for ACL reconstruction in the hopes of improving potential problems related to the interference screw and button fixation technique. Previous clinical results indicated that double-bundle ACL reconstruction is equivalent or even superior to single-bundle ACL reconstruction in regaining anterior and rotational stability.

**Keywords:** Anterior cruciate ligament, reconstruction t, techniques

## Introduction

Anterior cruciate ligament is one of the most important knee-stabilizing ligament, which helps to maintain dynamic-static stability as well as knee joint coordination.<sup>[1]</sup> The main function of ACL is to prevent anterior displacement of the tibia in the femur.<sup>[2]</sup> Therefore, the ACL is considered very important to the normal functioning of the knee, the disruption of which may result in impairment in function and the early onset of joint degeneration.<sup>[3]</sup> ACL rupture is a usual injury in individuals who are involved in physical activities. As participation in sports activities increases, these injuries tends to increase, which may be the result of

sudden deceleration or hyperextension.<sup>[4]</sup> Most patients experience recurrent periods of pain, loss, instability, and reduced function following the injury.<sup>[5]</sup> Injury of ACL has a strong effect not only on individual life, but also on society, owing to loss of productivity and costs.<sup>[6]</sup> The overall consensus is that ACL remodeling is now a gold standard for restoring stability and function, with a high rate of return to preoperative activity and a low rate of relapse, allowing it to return to activity sooner, prevent meniscus damage, and delays the onset of osteoarthritis.<sup>[7,8]</sup> Surgical treatment involves ACL reconstruction by tendon grafting, in which the structure and composition of these tendons differ from that of the ligament, including higher proteoglycan amount in the ligaments and differences in distribution of collagen.<sup>[9]</sup>

After surgical treatment, the tendon graft must undergo a process of remodeling (ligamentization) so that the ACL graft becomes more structurally and biochemically similar to the native ACL.<sup>[10]</sup>

**Address for correspondence:** Dr.Seyed Rohallah Mousavibaygei, Assistant Professor, Qom University of Medical Sciences, Qom, Iran  
E-mail: mmousavi.md@gmail.com

Received: 21-04-2021  
Accepted: 10-11-2021

Revised: 09-08-2021  
Published: 10-03-2022

### Access this article online

#### Quick Response Code:



Website:  
www.jfmpc.com

DOI:  
10.4103/jfmpc.jfmpc\_1227\_21

This is an open access journal, and articles are distributed under the terms of the Creative Commons Attribution-NonCommercial-ShareAlike 4.0 License, which allows others to remix, tweak, and build upon the work non-commercially, as long as appropriate credit is given and the new creations are licensed under the identical terms.

For reprints contact: WKHLRPMedknow\_reprints@wolterskluwer.com

**How to cite this article:** Gerami MH, Haghi F, Pelarak F, Mousavibaygei SR. Anterior cruciate ligament (ACL) injuries: A review on the newest reconstruction techniques. J Family Med Prim Care 2022;11:852-6.

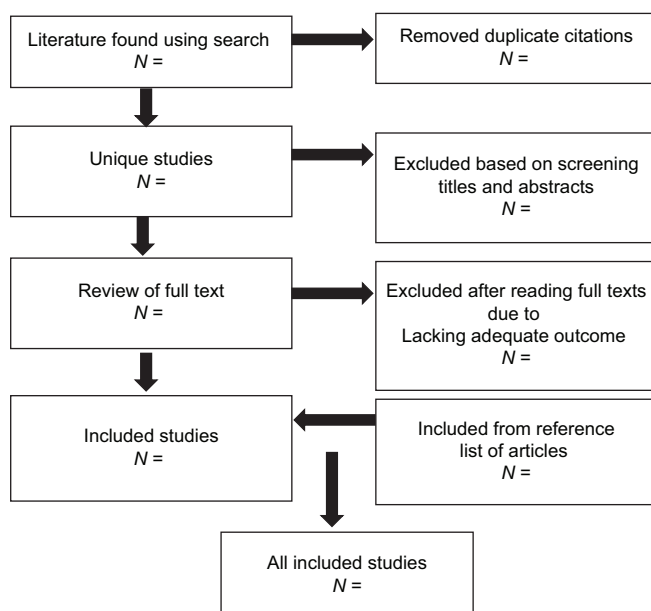
According to literature, various methods with different sources have been used in the reconstruction of ACL. Using any of these methods is associated with certain side effects. Evaluation of these complications and its prevalence can help the treating physician and patient to choose the best treatment. This study was conducted to investigate the different techniques used in the reconstruction of damaged ACL. Our hypothesis was that each technique has diverse risks, benefits, advantages, and disadvantages.

### Search strategy

The electronic databases Medline, PubMed, and Embase were searched on 21 September 2020 for reporting the outcomes of techniques of ACL reconstruction. Reference lists of published papers were then also hand-searched in an attempt to identify further reports. The following key words were used: anterior cruciate ligament; reconstruction; ACL injuries; knee ligaments; outcome and techniques for ACL reconstruction. The search terms were then entered onto Google Scholar to ensure that articles were not missed. Papers were excluded if they were not written in English, lacked documentation, were case reports or had a patient cohort, if ACL reconstruction was used only after failure of non-operative management, non-human studies, narrative reviews, studies without clinical outcomes data, systematic reviews that did not pool data or perform a meta-analysis, and technique articles without outcomes. We then obtained full manuscripts for those studies that met the inclusion criteria. Search algorithm of articles included in the literature review is presented in Figure 1.

### Arthroscopic ACL reconstruction techniques

The surgeon has different techniques which may be used in specific clinical conditions.<sup>[11]</sup> The basic principles of reconstruction of ACL include bone tunnel placement, graft selection and harvest, graft fixation, and postoperative rehabilitation. Each of these has been reported to affect the clinical result of ACL surgery.<sup>[12-15]</sup> ACL



**Figure 1:** Search algorithm of articles included in the literature review

reconstruction with a hamstring (semitendinosus and gracilis) tendon autograft is a standard method of reconstruction.<sup>[16-18]</sup> Hamstring grafts offer potential benefits compared to patellar tendon autografts, including reduced extensor mechanism complications and desirable biomechanical properties. Graft fixation has considered the weak link after ACL reconstruction with hamstring tendons. Demand for accelerated rehabilitation after ACL reconstruction requires optimization features.<sup>[19]</sup>

Options for fixing soft tissue to bone include the use of an interference screw, a button, and a reciprocal stabilizer. Interference screw fixation for quadruple hamstring grafts has failure strengths that may not be sufficient for a progressive rehabilitation program.<sup>[20]</sup> ACL arthroscopic reconstruction methods can be classified into three types: anteromedial portal, transtibial, and outside-in.<sup>[21]</sup> Some patients were not seen in terms of rotational control because of the graft direction being more vertical than the position of the upper femoral tunnel opening after surgery using the transtibial method.<sup>[22]</sup> At present, the standard transtibial method has been developed into a new technique known as the modified transtibial method which is effective in creating oblique femoral tunnels with fewer incisions.<sup>[23]</sup>

However, cross pins are a new technique of graft stabilization and there is limited information about this method. During the early postoperative period, the graft fixation to the bone tunnel is the primary factor in limiting early aggressive rehabilitation. Various studies have shown that the initial fixed strength of patellar bone tendon ligaments fixed with metal interference screws is better than any other method.<sup>[24-26]</sup> Despite the good bonding strength of metal interference screws, these implants have a number of disadvantages, such as distortion of MRI, risk of joint rupture, and the need to remove the hardware.<sup>[24-26]</sup> Bio-absorbable interference screws may have more advantages over metal screws.<sup>[11]</sup>

Since ACL reconstruction is a common orthopedic procedure primarily performed on an outpatient basis, regional anesthesia has been widely used for providing postoperative analgesia required in the outpatient setting of ACL reconstruction. Several studies compares the effects of popular regional anesthetic technique for reducing postoperative pain in patients as well as their effects on functional outcomes after arthroscopic ACL reconstruction.<sup>[27,28]</sup> An extensive study showed that, although femoral nerve block is a common method for reducing the postsurgical pain in patients with ACL reconstruction, it is also associated with a number of adverse effects, such as quadriceps weakness, antalgic ambulation, and increased fall risk. They concluded that adductor canal block can be offered as a motor nerve-sparing alternative to femoral nerve block, which preserves quadriceps function in the early postoperative period after ACL reconstruction while providing a similar level of analgesia.<sup>[27]</sup>

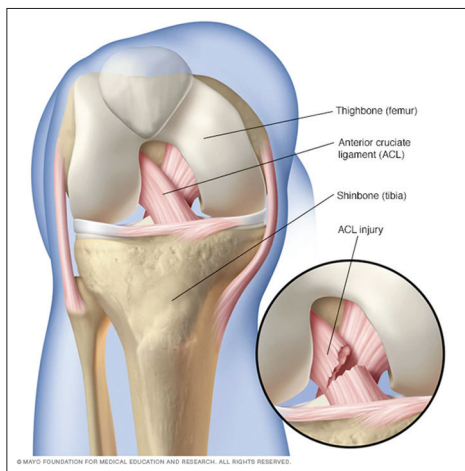
### Graft choices

Various grafts are available for reconstruction of ACL such as autografts (bone patellar tendon bone, Hamstring), allografts

and synthetic grafts. The ideal graft for ACL reconstruction is one which is biomechanically similar to the native ligament, is easily harvested, has least harvest site morbidity and gets well incorporated with the bone.<sup>[29]</sup> There are advantages and disadvantages with each graft; therefore, there is still no ideal graft for reconstruction of ACL.<sup>[30]</sup> Autografts are more commonly used than other types of grafts. Three autograft options that are commonly used are bone patellar tendon bone (BPTB), Hamstring, and bone quadriceps tendon grafts.<sup>[31]</sup> BPTB has historically been considered the gold standard for ACL reconstruction. The BPTB autograft is frequently chosen because of its excellent clinical outcomes and high level of patient satisfaction.<sup>[32]</sup> Hamstring tendon graft is one of the most common grafts for ACL reconstruction. The semitendinosus tendon is harvested from the ipsilateral leg with or without the gracilis tendon.<sup>[33]</sup> Hamstring graft has minimal donor site morbidity but has problems with bone tendon junction healing and elongation. Allograft has poor outcomes in terms of re-rupture rates and immunity, but can be used in multi-ligamentous injuries or in revision. Synthetic grafts are still under evolution; overall, no perfect synthetic graft is available.<sup>[29]</sup>

### One incision or two incisions: Double-bundle or single-bundle

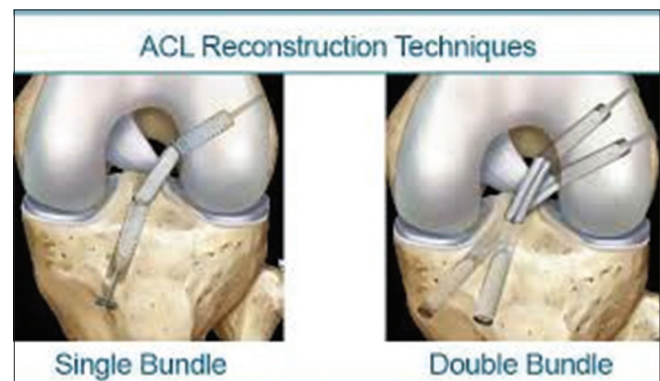
ACL rupture is a serious injury to the knee that is often treated with reconstructive surgery using arthroscopy with a patellar or hamstring tendon graft Figure 2. Rezende *et al.*<sup>[4]</sup> examined the evidence of choice of ACL reconstruction method with arthroscopy in terms of whether one or two incisions should be involved. The selection of technique for reconstruction of ACL is not straightforward. One issue concerns the procedure of drilling the tunnel into the femur. Traditionally, the femoral tunnel is pierced from the outside into the knee joint, and an incision is made from the outside of the thigh to reach the bone (two-incision method).<sup>[34]</sup> In this method, using interference screw with direct visualization of the tunnel by the thigh incision, the bond is fixed into the femur from the outside into the joint.<sup>[4]</sup> Arthroscopic method of one incision involves



**Figure 2:** ACL injury (MAYO foundation for medical education and research)

digging the femoral tunnel from inside the knee joint under arthroscopic imaging, thus reducing the incision and dissection of the quadriceps.<sup>[35]</sup> The graft is fixed to the femur through arthroscopic guidance from the inside to out of the joint and then fixed with an interference screw. The only incision required as a result is an incision to dig a tunnel into the tibia, which (like the two-incision method) is made through an anterior incision below the knee. Rezende *et al.*<sup>[4]</sup> reported that when considering priorities for high-quality randomized trials on techniques for reconstruction of ACL, it is important to note the insufficiency of the evidence available to inform this key comparison.

Some research has shown that single-bundle surgery usually provides sufficient anterior (front-to-back) stability. But it does not provide adequate rotational stability in the knee.<sup>[36]</sup> To improve rotational stability, surgical procedures in “double bundles” have been modified to reconstruct not only the anteromedial bundle but also the posterolateral bundle.<sup>[37]</sup> Therefore, reconstruction of ACL using double-bundle technique was developed to reconstruct the anteromedial and posterolateral bundles. Previous studies have revealed improvement in rotational stability for double-bundle reconstruction compared with single-bundle.<sup>[38]</sup> Anatomic double-bundle reconstruction is able to more closely restore normal kinematics to the knee rather than a single-bundle method in a cadaver model.<sup>[39]</sup> Kurosaka *et al.*<sup>[40]</sup> by examining the clinical results of 54 patients with at least two years of follow-up after reconstructive surgery, observed a better progressive stability in double bundles than in single bundle. The authors found that double bundles could improve repair at the tendon–bone junction by increasing contact areas. Some clinical results obtained through computer guidance, showed better anterior–posterior stability and rotation in double-bundle surgery than single-bundle Figure 3.<sup>[41]</sup> There are other studies that did not show a difference between single bundle and double bundle.<sup>[42]</sup> Probably because of the complexity of the double bundle, the single bundle is considered as the preferred choice for most surgeons for ACL reconstruction.<sup>[43]</sup> However it seems that this choice may have more anatomical and biomechanical reasons related to the complexity of the surgical procedure.<sup>[44]</sup> Biomechanical studies show a significant advantage in anterior and rotational stability with double-bundle compared to single-bundle anterior cruciate



**Figure 3:** Single vs. double bundle technique

ligament reconstruction. Rotational stability increased significantly with the additional reconstruction of the posterolateral bundle when compared to a single-bundle ACL reconstruction. Previous clinical results indicated that double-bundle ACL reconstruction is equivalent or even superior to single-bundle ACL reconstruction in regaining anterior and rotational stability.<sup>[45]</sup>

### All-inside ACL reconstruction

All-inside ACL reconstruction method is a new development in surgery of ACL. This method was originally described over 20 years ago<sup>[46]</sup> and then described by Lubowitz *et al.*<sup>[47]</sup> Some properties of this method include dual suspensory graft fixation, closed-socket tunnels, smaller skin incisions, improved cosmesis, less postoperative pain, decreased bone removal, and gracilis preservation. The all-inside ACL appears to have similar overall results compared to standard ACL techniques and may be related to decreased post-operative pain. However, there is a concern for a higher graft failure rate with the all-inside ACL.<sup>[46]</sup> Standard ACL techniques typically use a BPTB or semitendinosus-gracilis tendon autograft. In contrast, the all-inside ACL technique usually utilizes a triple or quadruple semitendinosus tendon autograft.<sup>[47]</sup> Reducing the length of the graft is essential for the all-inside ACL procedure, because closed sockets of the femur and tibia are drilled instead of full tunnels. A biomechanical study showed that reconstruction using a hamstring tendon can reverse anterior translation of the tibial at 1.3 mm from native ACL and also produce similar rotational and torque properties.<sup>[48]</sup> A study comparing an all-inside ACL technique using a double or triple semitendinosus tendon graft with a standard ACL technique using a semitendinosus-gracilis hamstring tendon autograft reported no significant difference between the two groups for pain, Lysholm and Tegner scores at two years of follow up.<sup>[47]</sup> As a result of previous studies, it can be found that the use of a single hamstring tendon graft in the all-inside ACL method can reproduce similar knee stability compared to the native ACL.<sup>[46]</sup>

### Conclusion

Different grafts are available for ACL reconstruction such as autografts (BPTB, Hamstring, and bone quadriceps tendon), allografts and, synthetic grafts. The ideal graft for ACL reconstruction is one which is biomechanically similar to the native ligament, is easily harvested, has least harvest site morbidity and gets well incorporated with the bone. Cross-fixing of hamstrings has been created for ACL reconstruction in the hopes of improving potential problems associated with the interference screw and button fixation technique. However, cross pins are a relatively new technique of graft stabilization and there is limited information about this method. The all-inside ACL reconstruction method is a relatively new development in surgery of ACL reconstruction. Previous clinical results indicate that double-bundle ACL reconstruction is equivalent or even superior to single-bundle ACL reconstruction in regaining anterior and rotational stability.

### Financial support and sponsorship

Nil.

### Conflicts of interest

There are no conflicts of interest.

### References

1. Al-Khalifa FK, Alhamam NM, Uddin FZ, Aljawder AA, Abubaris RK, Hameed R. Clinical outcomes following anterior cruciate ligament reconstruction utilizing hamstring tendon autografts. *Saudi J Sports Med* 2014;14:89-93.
2. Fu FH, Bennett CH, Lattermann C, Ma CB. Current trends in anterior cruciate ligament reconstruction. *Am J Sports Med* 1999;27:821-30.
3. Herrington L, Wrapson C, Matthews M, Matthews H. Anterior cruciate ligament reconstruction, hamstring versus bone-patella tendon-bone grafts: A systematic literature review of outcome from surgery. *Knee* 2005;12:41-50.
4. Rezende FC, Moraes VY, Franciozi CE, Debieux P, Luzo MV, Belloti JC. One-incision versus two-incision techniques for arthroscopically assisted anterior cruciate ligament reconstruction in adults. *Cochrane Database Syst Rev* 2017;12:CD010875. doi: 10.1002/14651858.CD010875.pub2.
5. Johnson R, Eriksson E, Haggmark T, Pope M. Five-to ten-year follow-up evaluation after reconstruction of the anterior cruciate ligament. *Clin Orthop Relat Res* 1984;183:122-40.
6. Geiger E, Laurer H, Jakob H, Frank J, Marzi I. Behandlungskosten in der Kreuzbandchirurgie. *Unfallchirurg* 2013;116:517-23.
7. Satku K, Kumar V, Ngoi S. Anterior cruciate ligament injuries. To counsel or to operate? *J Bone Joint Surg Br* 1986;68:458-61.
8. Herrington L, Fowler E. A systematic literature review to investigate if we identify those patients who can cope with anterior cruciate ligament deficiency. *Knee* 2006;13:260-5.
9. Lansdown DA, Xiao W, Zhang AL, Allen CR, Feeley BT, Li X, *et al.* Quantitative imaging of anterior cruciate ligament (ACL) graft demonstrates longitudinal compositional changes and relationships with clinical outcomes at 2 years after ACL reconstruction. *J Orthop Res* 2020;38:1289-95.
10. Amiel D, Kleiner JB, Roux RD, Harwood FL, Akeson WH. The phenomenon of "ligamentization": Anterior cruciate ligament reconstruction with autogenous patellar tendon. *J Orthop Res* 1986;4:162-72.
11. Mahirogullari M, Oguz Y, Ozkan H. Reconstruction of the anterior cruciate ligament using bone-patellar tendon-bone graft with double biodegradable femoral pin fixation. *Knee Surg Sports Traumatol Arthrosc* 2006;14:646-53.
12. Aglietti P, Buzzi R, Giron F, Simeone A, Zaccherotti G. Arthroscopic-assisted anterior cruciate ligament reconstruction with the central third patellar tendon A 5-8-year follow-up. *Knee Surg Sports Traumatol Arthrosc* 1997;5:138-44.
13. Becker R, Voigt D, Stärke C, Heymann M, Wilson GA, Nebelung W. Biomechanical properties of quadruple tendon and patellar tendon femoral fixation techniques. *Knee Surg Sports Traumatol Arthrosc* 2001;9:337-42.
14. Frank C. The science of reconstruction of the anterior cruciate ligament. *J Bone Joint Surg* 1997;79:1556-73.
15. Gobbi A, Diara A, Mahajan S, Zanazzo M, Tuy B. Patellar tendon anterior cruciate ligament reconstruction with conical press-fit femoral fixation: 5-year results in athletes population. *Knee Surg Sports Traumatol Arthrosc* 2002;10:73-9.

16. Noojin FK, Barrett GR, Hartzog CW, Nash CR. Clinical comparison of intraarticular anterior cruciate ligament reconstruction using autogenous semitendinosus and gracilis tendons in men versus women. *Am J Sports Med* 2000;28:783-9.
17. Aglietti P, Buzzi R, Zaccherotti G, De Biase P. Patellar tendon versus doubled semitendinosus and gracilis tendons for anterior cruciate ligament reconstruction. *Am J Sports Med* 1994;22:211-8.
18. Maeda A, Shino K, Horibe S, Nakata K, Buccafusca G. Anterior cruciate ligament reconstruction with multistranded autogenous semitendinosus tendon. *Am J Sports Med* 1996;24:504-9.
19. Howell LCSM, Taylor CMA. Brace-free rehabilitation, with early return to activity, for knees reconstructed with a double-looped semitendinosus and gracilis graft. *J Bone Joint Surg Am* 1996;78:814-25.
20. Ahmad CS, Gardner TR, Groh M, Arnouk J, Levine WN. Mechanical properties of soft tissue femoral fixation devices for anterior cruciate ligament reconstruction. *Am J Sports Med* 2004;32:635-40.
21. Lee D-H, Kim H-J, Ahn H-S, Bin S-I. Comparison of femoral tunnel length and obliquity between transtibial, anteromedial portal, and outside-in surgical techniques in single-bundle anterior cruciate ligament reconstruction: A meta-analysis. *Arthroscopy* 2016;32:142-50.
22. Lee MC, Seong SC, Lee S, Chang CB, Park YK, Jo H, *et al.* Vertical femoral tunnel placement results in rotational knee laxity after anterior cruciate ligament reconstruction. *Arthroscopy* 2007;23:771-8.
23. Fu FH, van Eck CF, Tashman S, Irrgang JJ, Moreland MS. Anatomic anterior cruciate ligament reconstruction: A changing paradigm. *Knee Surg Sports Traumatol Arthrosc* 2015;23:640-8.
24. Al-Husseiny M, Batterjee K. Press-fit fixation in reconstruction of anterior cruciate ligament, using bone-patellar tendon-bone graft. *Knee Surg Sports Traumatol Arthrosc* 2004;12:104-9.
25. Brand J, Weiler A, Caborn DN, Brown CH, Johnson DL. Graft fixation in cruciate ligament reconstruction. *Am J Sports Med* 2000;28:761-74.
26. Caborn DN, Coen M, Neef R, Hamilton D, Nyland J, Johnson DL. Quadrupled semitendinosus-gracilis autograft fixation in the femoral tunnel: A comparison between a metal and a bioabsorbable interference screw. *Arthroscopy* 1998;14:241-5.
27. Edwards MD, Bethea JP, Hunnicutt JL, Slone HS, Woolf SK. Effect of adductor canal block versus femoral nerve block on quadriceps strength, function, and postoperative pain after anterior cruciate ligament reconstruction: A systematic review of level 1 studies. *Am J Sports Med* 2020;48:2305-13.
28. Leathers MP, Merz A, Wong J, Scott T, Wang JC, Hame SL. Trends and demographics in anterior cruciate ligament reconstruction in the United States. *J Knee Surg* 2015;28:390-4.
29. Dhammi IK, Kumar S. *Graft Choices for Anterior Cruciate Ligament Reconstruction*. Springer; 2015.
30. Shaerf DA, Pastides PS, Sarraf KM, Willis-Owen CA. Anterior cruciate ligament reconstruction best practice: A review of graft choice. *World J Orthop* 2014;5:23-9.
31. Macaulay AA, Perfetti DC, Levine WN. Anterior cruciate ligament graft choices. *Sports Health* 2012;4:63-8.
32. Koh HS, In Y, Kong C-G, Won H-Y, Kim K-H, Lee J-H. Factors affecting patients' graft choice in anterior cruciate ligament reconstruction. *Clin Orthop Surg* 2010;2:69-75.
33. Chechik O, Amar E, Khashan M, Lador R, Eyal G, Gold A. An international survey on anterior cruciate ligament reconstruction practices. *Int Orthop* 2013;37:201-6.
34. Bach Jr B. Arthroscopy-assisted patellar tendon substitution for anterior cruciate ligament insufficiency. *Am J Knee Surg* 1989;2:3-20.
35. Howell LCSM, Deutsch ML. Comparison of endoscopic and two-incision techniques for reconstructing a torn anterior cruciate ligament using hamstring tendons. *Arthroscopy* 1999;15:594-606.
36. Hemmerich A, van der Merwe W, Batterham M, Vaughan CL. Knee rotational laxity in a randomized comparison of single-versus double-bundle anterior cruciate ligament reconstruction. *Am J Sports Med* 2011;39:48-56.
37. Pena E, Calvo B, Martinez M, Palanca D, Doblare M. Influence of the tunnel angle in ACL reconstructions on the biomechanics of the knee joint. *Clin Biomech (Bristol, Avon)* 2006;21:508-16.
38. Song E-K, Seon J-K, Yim J-H, Woo S-H, Seo H-Y, Lee K-B. Progression of osteoarthritis after double-and single-bundle anterior cruciate ligament reconstruction. *Am J Sports Med* 2013;41:2340-6.
39. Yagi M, Wong EK, Kanamori A, Debski RE, Fu FH, Woo SL. Biomechanical analysis of an anatomic anterior cruciate ligament reconstruction. *Am J Sports Med* 2002;30:660-6.
40. Kurosaka M, Kuroda R, Kubo S, Hoshino Y, Araki D, Yoshiya S. Double-bundle anatomic anterior cruciate ligament reconstruction: The technique and clinical experience. *Oper Tech Sports Med* 2008;16:125-30.
41. Steckel H, Murtha PE, Costic RS, Moody JE, Jaramaz B, Fu FH. Computer evaluation of kinematics of anterior cruciate ligament reconstructions. *Clin Orthop Relat Res* 2007;463:37-42.
42. Bedi A, Musahl V, O'Loughlin P, Maak T, Citak M, Dixon P, *et al.* A comparison of the effect of central anatomical single-bundle anterior cruciate ligament reconstruction and double-bundle anterior cruciate ligament reconstruction on pivot-shift kinematics. *Am J Sports Med* 2010;38:1788-94.
43. Tiamklang T, Sumanont S, Foocharoen T, Laopaiboon M. Double-bundle versus single-bundle reconstruction for anterior cruciate ligament rupture in adults. *Cochrane Database Syst Rev* 2012;11:CD008413. doi: 10.1002/14651858.CD008413.pub2.
44. Grassi A, Carulli C, Innocenti M, Mosca M, Zaffagnini S, Bait C, *et al.* New trends in anterior cruciate ligament reconstruction: A systematic review of national surveys of the last 5 years. *Joints* 2018;6:177-87.
45. Zhao J, Peng X, He Y, Wang J. Two-bundle anterior cruciate ligament reconstruction with eight-stranded hamstring tendons: Four-tunnel technique. *Knee* 2006;13:36-41.
46. Blackman AJ, Stuart MJ. All-inside anterior cruciate ligament reconstruction. *J Knee Surg* 2014;27:347-52.
47. Lubowitz JH, Amhad CH, Anderson K. All-inside anterior cruciate ligament graft-link technique: Second-generation, no-incision anterior cruciate ligament reconstruction. *Arthroscopy* 2011;27:717-27.
48. Zamarra G, Fisher MB, Woo SL, Cerulli G. Biomechanical evaluation of using one hamstrings tendon for ACL reconstruction: A human cadaveric study. *Knee Surg Sports Traumatol Arthrosc* 2010;18:11-9.