

Adrenocortical oncocytoma associated with androgen excess: A rare cause of hirsutism

Prachi*, Hema Malini Aiyer, Vikas Jain¹

Departments of Pathology and ¹Urology, Dharamshila Narayana Superspeciality Hospital, New Delhi, India

*E-mail: prachipath123@gmail.com

ABSTRACT

Adrenal oncocytomas are rare neoplasms that are usually benign and nonfunctional, and often detected incidentally. Very few cases have been reported of functioning adrenal oncocytomas. We report a rare case of adrenocortical oncocytoma in a 29-year-old female presenting with hirsutism and irregular menstrual history. The tumor was functional and was successfully managed by laparoscopic adrenalectomy. Detailed radiological, histological, and immunohistochemical workup was done to come to a definitive diagnosis of adrenal oncocytoma.

INTRODUCTION

Adrenocortical oncocytoma is an extremely rare tumor of the adrenal gland. It was first reported by Kakimoto^[1] in 1986. Since then, around 120 cases of adrenocortical oncocytoma have been reported in the English language literature. There is no uniform consensus on diagnostic criteria and biological behavior.

Oncocytic neoplasms are benign in most cases, commonly arising in the kidneys or thyroid, parathyroid, salivary or pituitary glands. Rarely, they have been reported at other sites including the respiratory tract (as oncocytic neuroendocrine carcinoma), larynx, and choroid plexus. Oncocytomas in the adrenal are extremely rare and are usually non-functional and benign; around 20% of the adrenocortical oncocytomas demonstrate some elements of malignancy and 10%–20% of them appear to affect hormone production in the adrenal glands.^[2]

The term “oncocyte,” first used by Hamper^[3] in 1950, describes a large, highly eosinophilic, granular cell associated with a Hurthle cell tumor of the thyroid

gland. Adrenal cortical oncocytomas often present as large adrenal masses. Imaging alone cannot distinguish between benign and malignant tumors. Hence, a combination of clinical, radiological, and pathological findings is essential for definitive diagnosis.

It is well established that D4-androstenedione can be metabolized into testosterone by different 17b-HSD iso-forms. Occurrence of both 17b-HSD types 3 and 5 isoforms in the tumor at transcript and protein levels is consistent with testosterone synthesis. The oncocytoma expresses proteins synthesized in adrenal zona fasciculata, such as 17a-OH, 3b-HSD2, 21-OH, 11b-OH, and MC2R, as well as enzymes known to be produced in zona reticulata, including 17a-OH, CYB5, and 17b-HSD3/5, indicated an intermediate adrenocortical phenotype.^[4] The rarity of the disease prompted this study, which discusses the clinical, radiological, histological, and immunohistochemical findings of an adrenal oncocytoma.

CASE REPORT

A 29-year-old female patient presented with irregular menstrual bleeding and hirsutism for 3 years. The patient was

This is an open access journal, and articles are distributed under the terms of the Creative Commons Attribution-NonCommercial-ShareAlike 4.0 License, which allows others to remix, tweak, and build upon the work non-commercially, as long as appropriate credit is given and the new creations are licensed under the identical terms.

For reprints contact: WKHLRPMedknow_reprints@wolterskluwer.com

Received: 17.12.2020, **Revised:** 21.02.2021,

Accepted: 19.03.2021, **Published:** 01.07.2021

Financial support and sponsorship: Nil.

Conflicts of interest: There are no conflicts of interest.

Access this article online	
Quick Response Code:	Website: www.indianjurol.com
	DOI: 10.4103/iju.IJU_636_20

on oral contraceptive pills for 4–5 months, and since then she was amenorrheic. A physical examination revealed increased hair over the chest and abdomen with no petechiae or abdominal striae (features suggestive of Cushing syndrome). An ultrasound showed a 7.8 cm × 7.8 cm well-defined heterogeneously hypoechoic solid vascular lesion in the right lobe of the liver which was further re-evaluated by contrast-enhanced computed tomography (CECT) with triphasic liver study, which revealed a well-defined 80 mm × 82 mm mildly enhancing soft-tissue density supra-renal mass indenting the liver and the right adrenal was not seen separate from the mass [Figure 1a-d]. On positron emission tomography-CT, a non-DOTANOC avid well defined rounded heterogeneously enhancing mass lesion in the right suprarenal location was observed.

Baseline liver function test, renal profile, and serum electrolytes were normal. However, her TSH (7.02 µU/L, normal 0.25–5.0 µU/L), testosterone (725.5 ng/dl, normal 6–82 ng/dl) and DHEAS (12714 µg/dl, normal <340 µg/dl) levels were increased [Table 1].

A laparoscopic right adrenalectomy was performed using the lateral transperitoneal approach. The mass was completely encapsulated and easily dissected from the superior pole of the right kidney. The post-operative recovery was uneventful and on follow-up, the hormonal levels were within normal limits.

Pathology findings

A specimen of the right adrenalectomy weighed 280 gm and measured 8.5 cm × 7.5 cm × 5.5 cm with attached fat-measuring 2.5 cm × 1.5 cm × 1 cm. The capsule was intact. Cut surface showed, mahogany brown tumor replacing the entire adrenal parenchyma with areas of hemorrhage, but no necrosis [Figure 1e and f]. Microscopic examination revealed

an encapsulated tumor composed of sheets and nests of lipid poor large cells with abundant granular eosinophilic cytoplasm and foci of marked nuclear atypia with multinucleated cells. No necrosis was seen (mitotic Figures 0 to 1 per 50 hpf). No capsular or vascular invasion was seen. There was no Reinke crystalloid feature. According to the Lin-Weiss-Bisceglia criteria,^[5] it was negative for malignancy [Figure 2a]. Immunohistochemically, the tumor cells were immunoreactive for CK (4+), calretinin (2+), melan-A (2+), synaptophysin (3+), and inhibin (4+) and were negative for chromogranin [Figure 2b-f]. Based on the above morphologic and IHC findings, a final diagnosis of adrenocortical oncocytoma was made. Her postoperative period was uneventful.

DISCUSSION

Adrenal masses are found in 1%–2% of abdominal CT scans and are detected incidentally. These adrenal

Table 1: Plasma hormones concentration at diagnosis

Parameter	Value	Normal range
Epinephrine (ng/L)	25.77	3.7-82
Norepinephrine (ng/l)	131.04	80.0-499.0
Metanephrine (mg/24 h)	14.16	74-297
Normetanephrine (mg/24 h)	36.93	73-808
Plasma renin (mIU/ml)	15.28	4.4-46.1
Serum cortisol (mg/dl)	14.02	10-20
Aldosterone (ng/dl)	14.10	1.76-23.2
Chromogranin (ng/ml)	27.08	<76.3
Alphafoetoprotein (IU/ml)	1.94	<5.8
Insulin (mIU/ml)	5.91	2.6-24.9
Serum prolactin (ng/ml)	14.64	6.0-29.9
VMA (mg/24 h)	5	2-7
TSH (mU/L)	7.02	0.25-5.0
Testosterone (ng/dl)	725.5	6-82
DHEAS (mg/dl)	12714	<340

VMA=Vanillylmandelic Acid, TSH=Thyroid stimulating hormone, DHEAS=Dehydroepiandrosterone sulfate

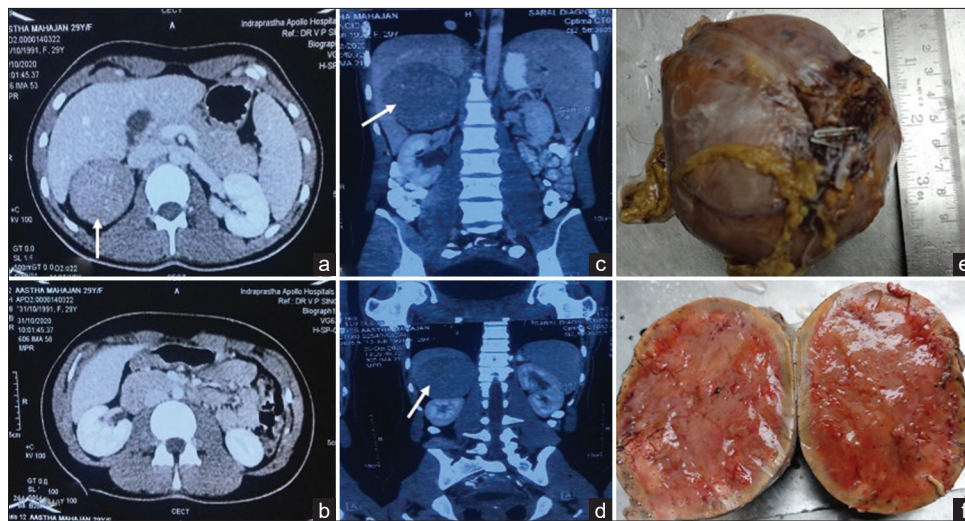


Figure 1: (a and b) Contrast-enhanced computed tomography axial and (c and d) contrast-enhanced computed tomography coronal images show a well-defined mildly enhancing hypodense mass (white arrow) arising from the right adrenal gland displacing the right kidney inferiorly and indenting the medial surface of liver superiorly (e) Gross photograph of well-encapsulated adrenal mass. (f) Gross photograph of cut-section of the mass showing mahogany brown homogenous areas of foci of hemorrhage

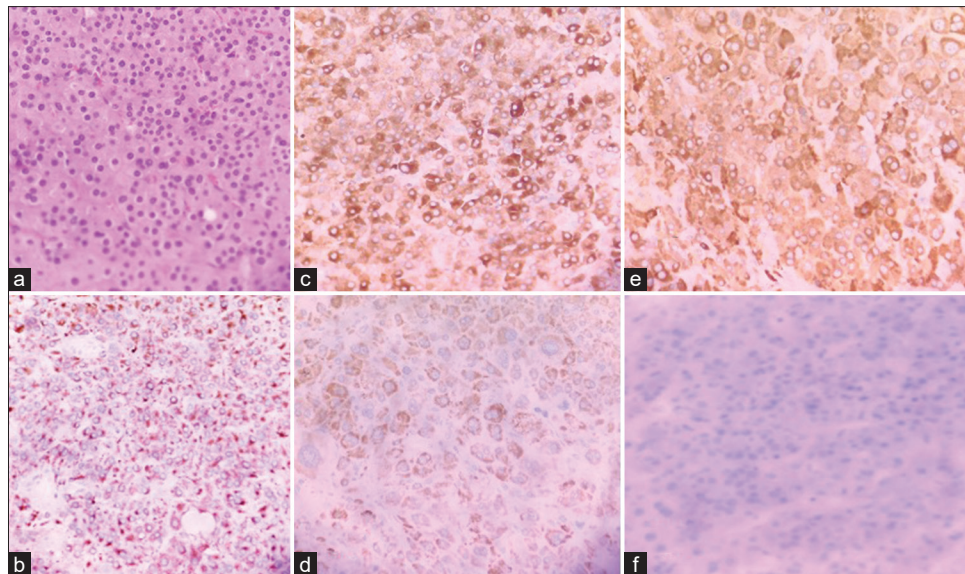


Figure 2: (a) Microphotograph of abundant granular eosinophilic cytoplasm and foci of marked nuclear atypia seen (H and E, $\times 400$). (b) Immunoreactive score 4+ in neoplastic cells (IHC stain CK, $\times 400$). (c) Immunoreactive score 3+ in neoplastic cells (IHC stain synaptophysin, $\times 400$). (d) Immunoreactive score 2+ in neoplastic cells (IHC stain Melan A, $\times 400$). (e) Immunoreactive score 4+ in neoplastic cells (IHC stain inhibin, $\times 400$). (f) Nonimmunoreactive score in neoplastic cells (IHC stain Chromogranin, $\times 400$)

“incidentalomas” can be cortical adenomas, cysts, myelolipomas, ganglioneuromas, pheochromocytomas, adrenocortical carcinomas, and adrenal metastases. The most common adrenal incidentalomas are non-functioning cortical adenomas. A biochemical evaluation aids in differentiating non-functional from functional adrenal masses. As both usually present as an incidental, large adrenal masses, CT and magnetic resonance imaging findings cannot be used to differentiate benign from malignant oncocytic neoplasms and only microscopic criteria are able to define malignancy and clinical behavior. Hence, laparoscopic adrenalectomy being the most common approach is the mainstay of therapy.

Adrenal oncocytic tumors are more common on the left side. Tumor size ranges from 3 to 15 cm. Oncocytomas are generally benign tumors. The Weiss system^[5] distinguishes benign from malignant adrenocortical neoplasms. The Lin-Weiss-Bisceglia system for categorizing malignant oncocytic neoplasm are as follows (1) Major criteria (a mitotic rate of >5 mitoses per 50 high-power fields, any atypical mitoses or venous invasion), (2) Minor criteria (large size [>10 cm and/or >200 g], necrosis, capsular invasion, or sinusoidal invasion) and (3) definitional criteria (predominantly cells with eosinophilic-granular cytoplasm, high nuclear grade, and diffuse architectural pattern). The presence of any one of the major criteria indicates malignancy, the presence of one to four minor criteria is indicative of uncertain malignant potential, whereas the absence of all major and minor criteria indicates benign behavior.^[5]

Grossly these tumors are rounded, well-circumscribed, and encapsulated. Cut surface shows mahogany brown color with areas of hemorrhage and necrosis. Histologically, these

tumors contain cells arranged in solid, tubular, papillary, or trabecular patterns.^[4] Cells are strongly eosinophilic and granular, due to the presence of numerous mitochondria.^[4] The pathogenesis of these tumors is still not known. Some oncocytomas might be tumors of mitochondria at the subcellular level.

The present case was a right-sided well-defined supra-renal mass, on CECT, absence of fat attenuation (excluding myelolipoma). Large tumor size and heterogeneous echotexture on imaging raised the doubt of adrenocortical carcinoma. Investigations revealed the functional nature of the mass. Thus, a detailed microscopic evaluation was mandatory to come to a definitive diagnosis. In our case, a preoperative diagnosis was difficult. Immunohistochemistry revealed non-immunoreactivity for chromogranin A, thus ruling out pheochromocytomas.

CONCLUSIONS

Adrenal oncocytic neoplasm is one of the histological subtypes of incidentally detected adrenal masses. They are generally large, benign, non-functional adrenal tumors, with a prevalence in women and on the left side. However, the possibility of a functional adrenal oncocytoma should be considered. The assessment of their exact biologic behavior requires a detailed gross, microscopic, and comprehensive immunohistochemical evaluation with particular attention to the criteria that define malignancy.

Declaration of patient consent

The authors certify that they have obtained all appropriate patient consent forms. In the form the patient(s) has/have

given his/her/their consent for his/her/their images and other clinical information to be reported in the journal. The patients understand that their names and initials will not be published and due efforts will be made to conceal their identity, but anonymity cannot be guaranteed.

REFERENCES

1. Kakimoto S, Yushita Y, Sanefuji T, Kondo A, Fujishima N, Kishikawa M, *et al.* Non-hormonal adrenocortical adenoma with oncocytoma-like appearances. *Hinyokika Kyo* 1986;32:757-63.
2. Bisceglia M, Ludovico O, Di Mattia A, Ben-Dor D, Sandbank J, Pasquinelli G, *et al.* Adrenocortical oncocytic tumors: Report of 10 cases and review of the literature. *Int J Surg Pathol* 2004;12:231-43.
3. Hamperl H. Onkocytes and the so called hurthle cell tumor. *Arch Pathol* 1950;49:563-70.
4. Tetsi Nomigni M, Ouzounian S, Benoit A, Vadrot J, Tissier F, Renouf S, *et al.* Steroidogenic enzyme profile in an androgen-secreting adrenocortical oncocytoma associated with hirsutism. *Endocr Connect* 2015;4:117-27.
5. Weiss LM, Medeiros LJ, Vickery AL Jr. Pathologic features of prognostic significance in adrenocortical carcinoma. *Am J Surg Pathol* 1989;13:202-6.

How to cite this article: Prachi, Aiyer HM, Jain V. Adrenocortical oncocytoma associated with androgen excess: A rare cause of hirsutism. *Indian J Urol* 2021;37:277-80.