

CASE REPORT

Chronic active Epstein–Barr virus and hydroa vacciniforme-like lymphoproliferative disorder in a pediatric patient complicated by fatal ruptured cerebral artery aneurysm

Troy Yi^{1,2} | Jeffrey Steinberg¹ | Scott Olson¹ | Howaida El-Said^{1,2} | Jun Mo^{1,2} | Eric Anderson^{1,2} | Nicholas Gloude^{1,2} | Deborah Schiff^{1,2} 

¹UCSD School of Medicine, La Jolla, California, USA

²Rady Children's Hospital, San Diego, California, USA

Correspondence

Deborah Schiff, Rady Children's Hospital, 3020 Children's Way, MC 5035 San Diego, CA 92123, USA.
Email: dschiff@rchsd.org

Key Clinical Message

Hydroa vacciniforme-like lymphoproliferative disorder (HV-LPD) is a rare cutaneous form of chronic active Epstein–Barr virus (CAEBV) that presents with vesicular lesions induced by sun-exposure. Arterial aneurysm is a rare but potentially fatal complication of CAEBV and HV-LPD.

KEYWORDS

arterial aneurysm, CAEBV, HV-LPD

1 | INTRODUCTION

Epstein–Barr Virus (EBV) is a common human herpesvirus with a typically benign clinical course, most commonly infecting children with an estimated worldwide prevalence of more than 90%.¹ Chronic active Epstein–Barr virus (CAEBV) is a rare T- and NK-cell lymphoproliferative disorder of EBV origin affecting children mostly in Asia and the Americas.² CAEBV can manifest in a broad spectrum of diseases including a cutaneous disorder known as hydroa vacciniforme-like lymphoproliferative disorder (HV-LPD) and a systemic form with persistent or recurrent infectious mononucleosis-like symptoms following primary EBV infection.³ HV-LPD presents with vesicular lesions induced by sun-exposure. Systemic CAEBV can be associated with a variety of symptoms including viral hepatitis, hemophagocytic syndrome, coronary artery aneurysms (CAA), basal ganglia calcification, oral ulcers, lymphoma, interstitial pneumonia, central nervous system (CNS) disease, pulmonary arterial hypertension (PAH), enteritis, and gastrointestinal perforations.^{4–8}

Here we present a case of a pediatric patient diagnosed with T-cell-associated CAEBV and HV-LPD treated with reduced intensity conditioning (RIC) hematopoietic stem cell transplantation (HSCT) and complicated by transient delirium, CAA, PAH, and fatal ruptured cerebral artery aneurysm. This case was previously reported in two case series.^{9,10}

2 | CASE PRESENTATION

An 11-year-old previously healthy Hispanic female presented with waxing/waning malar rash exacerbated by sunlight (**Figure 1**), submandibular lymphadenopathy, scleritis/keratitis, and oral ulcers/abscesses. Examination revealed an enlarged submandibular lymph node, hemorrhagic crusted papules in sun-exposed areas; and conjunctival injection. She had no hepatosplenomegaly. Complete blood counts, electrolytes, creatinine, liver enzymes, and lactate dehydrogenase were normal. Antinuclear antibody was negative. EBV antibody panel was positive for

This is an open access article under the terms of the [Creative Commons Attribution-NonCommercial-NoDerivs](https://creativecommons.org/licenses/by-nc-nd/4.0/) License, which permits use and distribution in any medium, provided the original work is properly cited, the use is non-commercial and no modifications or adaptations are made.

© 2023 The Authors. *Clinical Case Reports* published by John Wiley & Sons Ltd.

viral capsid antigen IgG and EBV nuclear antigen IgG, and plasma EBV DNA was elevated (975 copies/mL). Oral mucosal biopsy revealed atypical large cells demonstrating marked infiltration and destruction of several medium- and large-caliber blood vessels within the tissue. The large atypical cells were positive for CD3, CD5, CD8, CD30, CD43, TIA1, granzyme, and EBV; and negative for CD1A, CD15, CD20, and CD56. Bone marrow biopsy showed an infiltrate of EBV positive lymphocytes (Figure 2) by in situ hybridization. Atypical cells on biopsies of oral mucosa and bone marrow were T-cell receptor (TCR)-gamma positive. A diagnosis of T-cell-associated CAEBV and HV-LPD was made based on her clinical course, concordant biopsies, and elevated EBV antibody titers and plasma EBV DNA levels.

Initially, her ocular disease was treated with corticosteroid drops and her rash was treated with topical corticosteroids and strict photoprotection with some improvement. At age 14-years, she started oral valganciclovir due to right corneal ulcer with vascular changes of her right retina and recurrent oral ulcers presumed to be secondary to EBV. After 11 months, valganciclovir was discontinued because the frequency and severity of her skin, mouth, and eye symptoms were not significantly improved by valganciclovir treatment. At age 16-years, she developed systemic

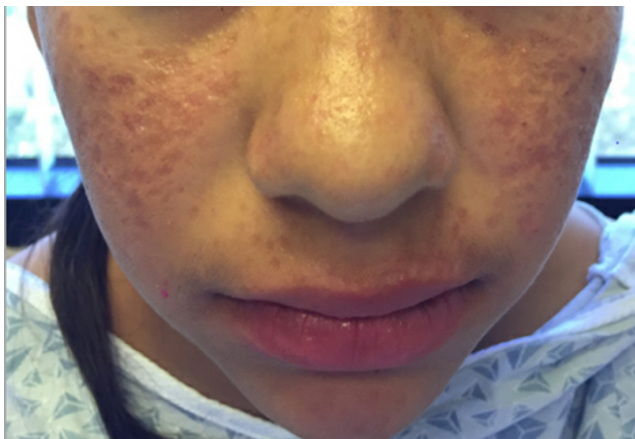


FIGURE 1 Hydroa vacciniforme (HV) skin lesions in sun-exposed areas. Consent to publish photographs of the patient for the case report was obtained from the patient's parent.

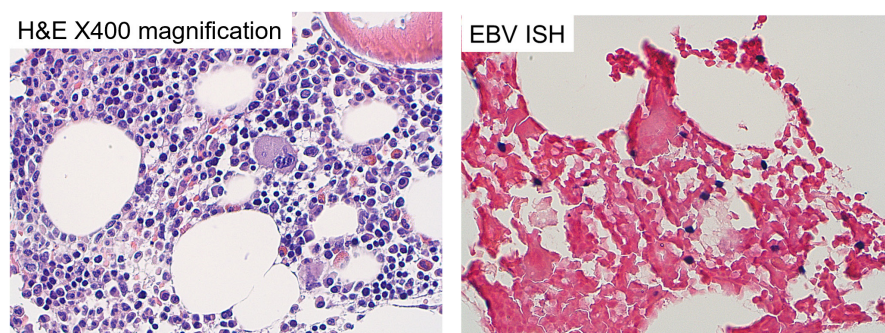


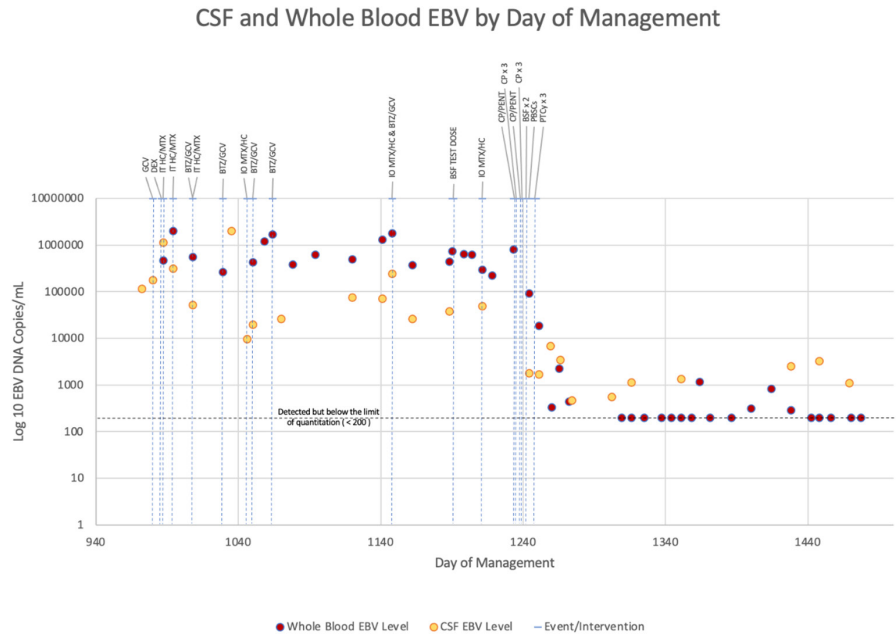
FIGURE 2 Bone marrow with lymphocytic infiltrate and scattered EBV-positive lymphocytes.

symptoms with intermittent fevers and 5kg weight loss, and CNS symptoms with intermittent headaches and one episode of transient delirium lasting several hours with visual hallucinations and amnesia. Cerebral spinal fluid (CSF) showed a mild lymphocytic pleocytosis and CSF EBV DNA levels of 313,858 copies/mL (Figure 3). CSF was positive for TCR-gamma and -beta gene rearrangements. CSF gram stain and culture were negative. Whole blood EBV DNA levels were over 2 million copies/mL (Figure 3). The patient's plasma and whole blood EBV DNA levels were discordant; the whole blood EBV DNA levels were higher, as expected with T-cell-associated CAEBV.¹¹ Hemophagocytic lymphohistiocytosis screening labs were unremarkable. Whole body positron emission tomography revealed mild splenomegaly without abnormal fluorodeoxyglucose activity.

At age 16-years, curative therapy was pursued due to development of systemic symptoms and involvement of the CNS. She received oral high-dose dexamethasone and intrathecal (IT) or intra-Ommaya (IO) methotrexate (MTX) and hydrocortisone (HC) to reduce viral burden with marked symptomatic improvement and decrease in EBV DNA levels (Figure 3). An Ommaya tunneled ventricular reservoir was placed to facilitate CSF administration of MTX/HC and monitoring of CSF EBV viral load. She received 5 cycles of bortezomib and ganciclovir/valganciclovir and seven doses of IT/IO MTX/HC to reduce total EBV viral burden prior to planned HSCT. Pre-HSCT screening echocardiogram revealed a giant right coronary artery (RCA) aneurysm (Figure 4). Cardiac catheterization confirmed severely dilated RCA, left anterior descending artery with multiple aneurysms in a beaded appearance, circumflex artery with multiple large aneurysms, and PAH. She was started on long-term anticoagulation with apixaban for CAA and endothelin receptor antagonist macitentan for PAH. Because of the presence of CAA, pre-HSCT CTA of the head, chest, abdomen, and pelvis were performed prior to HSCT, and were negative for additional arterial aneurysms.

At age 16-years, she received the National Institute of Health (NIH) irradiation-free, serotherapy-free RIC regimen for primary immunodeficiency disorders¹² with

FIGURE 3 Whole Blood and CSF EBV Levels by Day of Management with Interventions. Day 0 represents the initiation of systemic interventions with oral valganciclovir. BSF, busulfan; BTZ, bortezomib; DEX, dexamethasone; GCV, ganciclovir; IT/IO HC/MTX, intrathecal/Intra-Ommaya hydrocortisone and methotrexate; PBSCs, peripheral blood stem cells; PTCy, post-transplantation cyclophosphamide.



pentostatin, cyclophosphamide, and pharmacokinetically-dosed busulfan, followed by peripheral blood stem cell transplant (PBSCT) from a 9/10 HLA mismatched unrelated male donor who was EBV seropositive. Post-transplant cyclophosphamide, sirolimus, and mycophenolate mofetil were used for graft-versus-host disease (GVHD) prophylaxis. Neutrophil engraftment was achieved on post-transplant Day 16, and bone marrow demonstrated 60% cellularity and 94% donor chimerism on post-transplant Day 30. Whole blood EBV DNA level was <200 copies/mL and CSF EBV DNA level was 469 copies/mL on post-transplant Day 30. She continued to have baseline flesh colored papular malar rash but remained asymptomatic for other CAEBV-associated symptoms. Post-transplant course was complicated by Grade II steroid responsive chronic GI GVHD. She had no veno-occlusive disease. Bone marrow aspirate and biopsy obtained 6 months post-HSCT showed a hypocellular marrow (10% cellularity), no evidence of malignancy, negative EBER expression, 100% donor by cytogenetics (46, XY), no abnormal phenotype by flow cytometry, and donor chimerism >95%. Six months post-HSCT, blood and CSF EBV DNA were <200 and 1109 copies/mL, respectively.

On post-transplant day 212, the patient had an episode of syncope with closed head injury that resulted in subarachnoid and intraventricular hemorrhage. Computed tomography demonstrated fusiform aneurysm of distal right internal carotid artery (ICA) with extension into the anterior and medial cerebral artery (MCA) (Figure 5). The patient returned to her neurologic baseline after pipeline flow diverting stent placements from right MCA to ICA and aneurysm

coiling (Figure 6). Unfortunately, 8 months post-transplant, the patient developed a massive spontaneous subarachnoid hemorrhage (Figure 7) resulting in devastating irreversible neurologic injury and she expired 1 day later.

3 | DISCUSSION

Classic HV-LPD is described as the most indolent subset of HV-LPD. It was first mentioned by Bazin in 1862 and subsequently described as a rare photosensitivity disorder with a self-limited clinical course, often lacking systemic symptoms, and frequently resolving by young adulthood.¹³ Classic HV-LPD lesions are located on sun-exposed areas of the face and hands initially appearing as erythematous clustered macules transforming into vesicular or hemorrhagic bullae, healing as crusted lesions, and forming varioliform scars.¹⁴ Severe HV-LPD presents primarily in South and Central American and Asian populations with lesions similar to those seen with classic HV-LPD, but may involve non-sun-exposed areas of the skin and mucosa and include systemic symptoms such as weight loss, persistent fever, lymphadenopathy, facial edema, hepatosplenomegaly, hepatitis, and leukopenia.¹⁵ Reports have supported the belief that HV-LPD in Western populations is an EBV-associated lymphoproliferative disorder of T/NK-cells with a more indolent clinical course and decreased likelihood to need HSCT compared to HV-LPD in South and Central American and Asian populations.^{9,16}

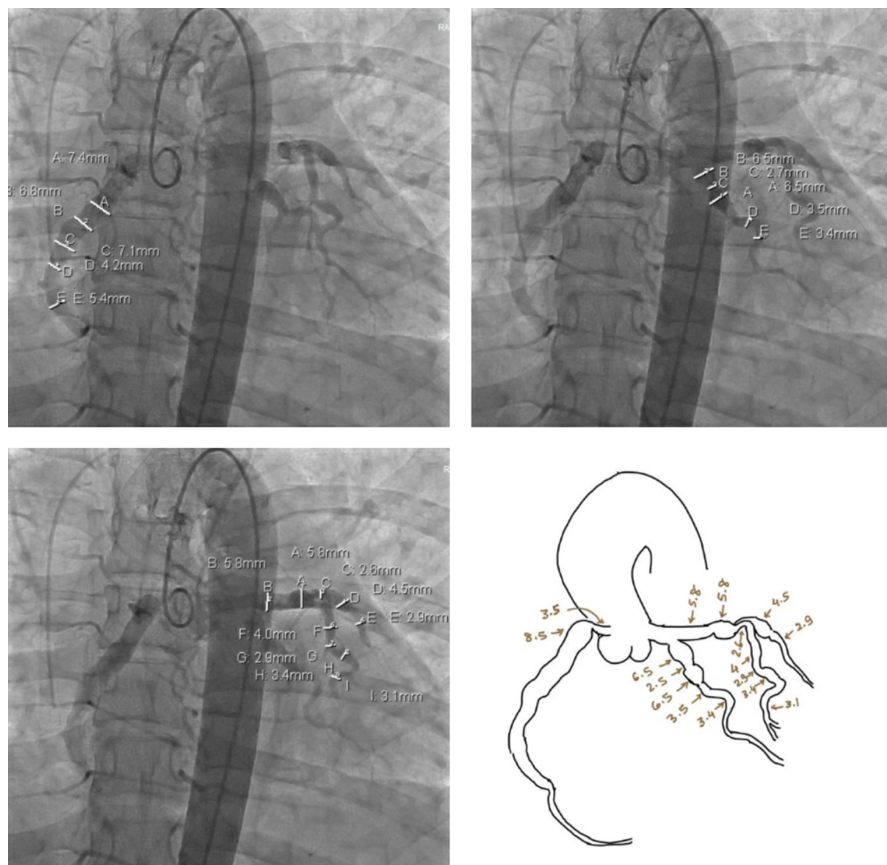


FIGURE 4 Angiography at 6 months Prior to HSCT shows severely dilated RCA with low flow in the right coronary artery (RCA), left anterior descending artery with multiple aneurysms with a beaded appearance, and circumflex artery with multiple large aneurysms.

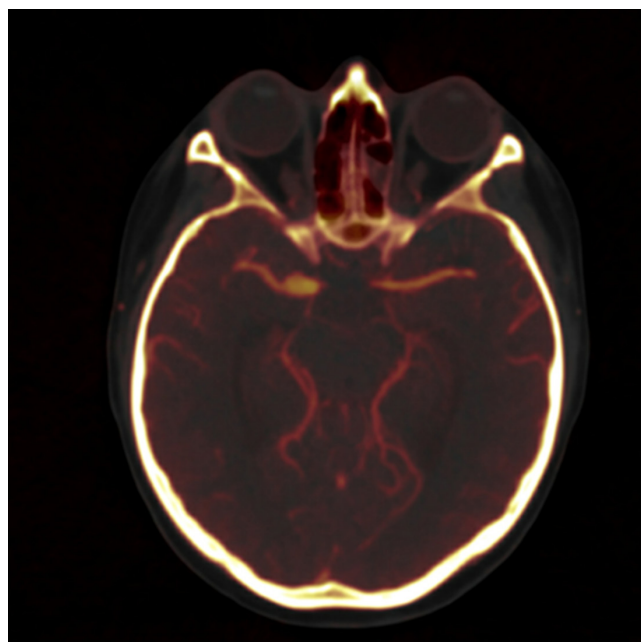


FIGURE 5 CTA performed day +213 after HSCT demonstrates Middle Cerebral Artery Aneurysm.

Treatment of CAEBV has yet to be standardized due to the highly variable clinical outcomes of the disease.¹⁷ The mainstay of treatment for patients with classic HV-LPD has been strict photoprotection.¹⁴ The only curative

treatment for severe HV-LPD and the broader category of disease, CAEBV, has been HSCT.^{18,19} Unfortunately, death as a result of relapse or sequela of CAEBV may occur post-HSCT.¹⁰ Therapies that have demonstrated some benefit or temporary remission include multi-agent chemotherapy, radiotherapy, immunomodulators, anti-inflammatory agents including corticosteroids, antiviral agents, and allogeneic EBV-specific cytotoxic T-lymphocytes.^{10,11,20–24} Of note, chronic immunosuppression with dexamethasone provided interim improvement of symptoms for our patient prior to HSCT, and IT/IO MTX/HC was associated with a resolution of CSF pleocytosis and decreased CSF EBV viral load (Figure 3). Placement of an Ommaya tunneled ventricular catheter greatly facilitated CSF administration of MTX/HC. Our patient did not receive rituximab therapy due to T-cell origin of her disease. She had little clinical improvement with oral valganciclovir alone but demonstrated marked improvement with combined bortezomib and ganciclovir (or oral valganciclovir) (Figure 3). The presumed mechanism of action of combined bortezomib/(val)ganciclovir therapy involves multiple steps. When bortezomib is administered with ganciclovir (or oral valganciclovir), bortezomib induces virus replication and expression of the EBV protein kinase (PK), the EBV PK then phosphorylates (val)ganciclovir, and then phosphorylated (val)ganciclovir inhibits EBV replication.²⁵

FIGURE 6 Flow-diverting stent with aneurysm coiling.

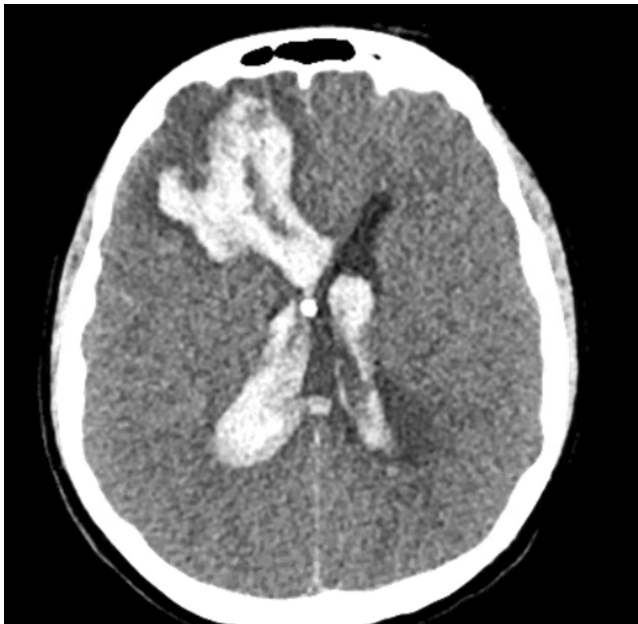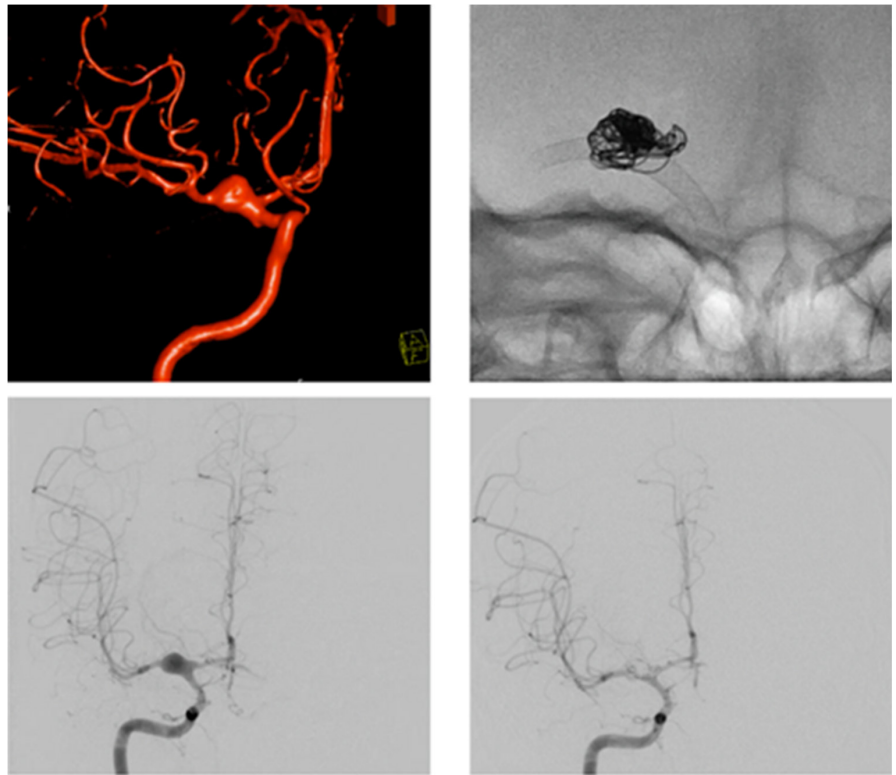


FIGURE 7 Head CT day +235 after hematopoietic stem cell transplantation (HSCT) demonstrates massive diffuse subarachnoid hemorrhage with right frontal lobe hemorrhage and hemorrhage into the ventricular system.

RIC HSCT with fludarabine, melphalan, and cytarabine for patients with CAEBV has shown improved rates in overall survival compared to myeloablative conditioning HSCT with decreased risk of post-transplant

complications.²⁶ Our patient received a RIC HSCT (irradiation-free; serotherapy-free conditioning per NIH Primary Immunodeficiency protocol¹²) with pentostatin, low-dose cyclophosphamide and pharmacokinetically-dosed busulfan with successful engraftment and sustained improvement in EBV viral load (Figure 3). She had minimal transplant-associated toxicity—Grade II steroid responsive chronic GVHD.

Arterial aneurysm is a rare but reported complication of CAEBV.^{6,27,28} This case highlights the risk of arterial aneurysms in patients with CAEBV and HV-LPD. This patient's giant RCA aneurysm and multiple aneurysms of the LAD and circumflex artery were detected by routine pre-HSCT echocardiogram. CTA of the head, chest, abdomen, and pelvis were performed pre-HSCT to screen for additional arterial aneurysms, but none were seen at that time. However, 12 months after the initial screening head CTA and 7 months after HSCT, a cerebral aneurysm was confirmed by head CTA after the aneurysm ruptured and caused a subarachnoid hemorrhage. Screening guidelines for aneurysms in patients with CAEBV have yet to be developed. This case report suggests that screening these patients for arterial aneurysms with CTA of the head, chest, abdomen, and pelvis prior to HSCT is prudent, and subsequent screening for progression of known arterial aneurysms and the development of new arterial aneurysms with CTA after HSCT may be beneficial.

A previous case report described a 4-year-old girl with CAEBV and CAAs who underwent HSCT; her CAAs

remained stable at 3 years post-HSCT.²⁷ A retrospective study of outcomes of 57 patients with CAEBV outside of Asia showed that patients who underwent HSCT had significantly better survival than those who did not (55% vs. 25%).¹⁰ However, there was still a high rate of death in the HSCT group, and 75% of patients with CAEBV who died after HSCT died due to relapsed disease. Only 2 of 57 patients in this cohort—which included this patient—had vascular involvement; both died. Similarly, two patients in this cohort with HV-LPD—which included this patient—did not survive. Early referral for curative therapy with HSCT may potentially lead to improved outcomes for patients with CAEBV and HV-LPD. However, the rarity of patients with CAEBV and HV-LPD currently precludes our ability to confirm this hypothesis. This case report illustrates that additional effective therapy is still needed to decrease post-HSCT mortality due to sequelae of CAEBV.

AUTHOR CONTRIBUTIONS

Troy Yi: Formal analysis; writing – original draft. **Jeffrey Steinberg:** Data curation; writing – review and editing. **Scott Olson:** Data curation; writing – review and editing. **Howaida El-Said:** Data curation; writing – review and editing. **Jun Mo:** Data curation; writing – review and editing. **Eric Anderson:** Writing – review and editing. **Nicholas Gloude:** Writing – review and editing. **Deborah Schiff:** Conceptualization; data curation; formal analysis; writing – original draft.

CONFLICT OF INTEREST STATEMENT

There are no conflicts of interest to report.

DATA AVAILABILITY STATEMENT

The data that support the findings of this study are available from the corresponding author upon reasonable request.

CONSENT

Written informed consent was obtained from the parent to publish this report in accordance with the journal's patient consent policy.

ORCID

Deborah Schiff  <https://orcid.org/0000-0003-3154-8987>

REFERENCES

- Smatti MK, Al-Sadeq DW, Ali NH, Pintus G, Abou-Saleh H, Nasrallah GK. Epstein–Barr virus epidemiology, serology, and genetic variability of LMP-1 oncogene among healthy population: an update. *Front Oncol*. 2018;8:211.
- Swerdlow SH, Campo E, Pileri SA, et al. The 2016 revision of the World Health Organization classification of lymphoid neoplasms. *Blood*. 2016;127:2375–2390.
- Fernandez-Pol S, Silva O, Natkunam Y. Defining the elusive boundaries of chronic active Epstein-Barr virus infection. *Haematologica*. 2018;103:924–927.
- Cohen JI. Optimal treatment for chronic active Epstein-Barr virus disease. *Pediatr Transplant*. 2009;13:393–396.
- Roliński J, Grywalska E, Pyzik A, et al. Interferon alpha as antiviral therapy in chronic active Epstein-Barr virus disease with interstitial pneumonia - case report. *BMC Infect Dis*. 2018;18:190.
- Hongjun B, Xu L, Peng H, et al. Chronic active Epstein-Barr virus infection with systemic Vasculitis and pulmonary arterial hypertension in a child. *Front Pediatr*. 2019;7:219.
- Tseng YJ, Ding WQ, Zhong L, Chen J, Luo ZG. Chronic active Epstein–Barr virus (CAEBV) enteritis. *Int J Infect Dis*. 2019;82:15–17.
- Xiao HJ, Li J, Song HM, Li ZH, Dong M, Zhou XG. Epstein–Barr virus-positive T/NK-cell lymphoproliferative disorders manifested as gastrointestinal perforations and skin lesions. *Medicine*. 2016;95:e2676.
- Cohen JI, Manoli I, Dowdell K, et al. Hydroa Vacciniforme–like lymphoproliferative disorder: an EBV disease with a low risk of systemic illness in whites. *Blood*. 2019;133:2753–2764.
- Dávila Saldaña BJ, John T, Bonifant C, et al. High risk of relapsed disease in patients with NK/T-cell chronic active Epstein-Barr virus disease outside of Asia. *Blood Adv*. 2022;6:452–459.
- Rodriguez-Pinilla SM, Barrionuevo C, Garcia J, et al. EBV-associated cutaneous NK/T-cell lymphoma: Review of a series of 14 cases from peru in children and young adults. *Am J Surg Pathol*. 2010;34:1773–1782.
- Dimitrova D, Gea-Banacloche J, Steinberg SM, et al. Prospective study of a novel, radiation-free, reduced-intensity bone marrow transplantation platform for primary immunodeficiency diseases. *Biol Blood Marrow Transplant*. 2020;26:94–106.
- Gupta G, Man I, Kemmett D. Hydroa Vacciniforme: a clinical and follow-up study of 17 cases. *J Am Acad Dermatol*. 2000;42:208–213.
- Nitiyarom R, Wongpraparut C. Hydroa Vacciniforme and solar Urticaria. *Dermatol Clin*. 2014;32:345–353.
- Hirai Y, Yamamoto T, Kimura H, et al. Hydroa Vacciniforme is associated with increased numbers of Epstein–Barr virus–infected $\gamma\delta$ T cells. *J Invest Dermatol*. 2012;132:1401–1408.
- Quintanilla-Martinez L, Fend F. Deciphering Hydroa Vacciniforme. *Blood*. 2019;133:2735–2737.
- Kimura H, Fujiwara S. Overview of EBV-associated T/NK-cell lymphoproliferative diseases. *Front Pediatr*. 2019;6:417.
- Kawa K, Okamura T, Yasui M, Sato E, Inoue M. Allogeneic hematopoietic stem cell transplantation for Epstein–Barr virus-associated T/NK-cell lymphoproliferative disease. *Crit Rev Oncol Hematol*. 2002;44:251–257.
- Sawada A, Inoue M. Hematopoietic stem cell transplantation for the treatment of Epstein-Barr virus-associated T- or NK-cell lymphoproliferative diseases and associated disorders. *Front Pediatr*. 2018;6:334.
- Guo N, Chen Y, Wang Y, et al. Clinicopathological categorization of Hydroa Vacciniforme-like lymphoproliferative disorder: an analysis of prognostic implications and treatment based on 19 cases. *Diagn Pathol*. 2019;14:82.
- Liu Z, Savoldo B, Huls H, et al. Epstein-Barr virus (EBV)-specific cytotoxic T lymphocytes for the prevention and treatment of EBV-associated post-transplant lymphomas. *Recent Results Cancer Res*. 2002;159:123–133.

22. Kim YJ, Choi SY, Lee WJ, et al. Two cases of Hydroa Vacciniforme-like lymphoproliferative disease controlled by anti-inflammatory agents. *Photodermatol Photoimmunol Photomed*. 2017;33:287-290.
23. Cohen J, Jaffe ES, Dale JK, et al. Characterization and treatment of chronic active Epstein-Barr virus disease: a 28-year experience in the United States. *Blood*. 2011;22:5835-5849.
24. Sawada A, Inoue M, Kawa K. How we treat chronic active Epstein-Barr virus infection. *Int J Hematol*. 2017;4:406-418.
25. Bollard CM, Cohen JI. How I treat T-cell chronic active Epstein-Barr virus disease. *Blood*. 2018;131:2899-2905.
26. Kawa K, Sawada A, Sato M, et al. Excellent outcome of allogeneic hematopoietic SCT with reduced-intensity conditioning for the treatment of chronic active EBV infection. *Bone Marrow Transplant*. 2010;46:77-83.
27. Xiao H, Hu B, Luo R, et al. Chronic active Epstein-Barr virus infection manifesting as coronary artery aneurysm and uveitis. *Virol J*. 2020;17:166-175.
28. Murakami K, Ohsawa M, Hu SX, Kanno H, Aozasa K, Nose M. Large-vessel arteritis associated with chronic active Epstein-Barr virus infection. *Arthritis Rheum*. 1998;41:369-373.

How to cite this article: Yi T, Steinberg J, Olson S, et al. Chronic active Epstein-Barr virus and hydroa vacciniforme-like lymphoproliferative disorder in a pediatric patient complicated by fatal ruptured cerebral artery aneurysm. *Clin Case Rep*. 2023;11:e7436. doi:[10.1002/ccr3.7436](https://doi.org/10.1002/ccr3.7436)