

Optimizing rejection readouts in a corneal allograft transplantation model

Thabo Lapp, Antonia Hildebrand, Daniel Böhringer, Paola Kammrath Betancor, Günther Schlunck, Thomas Reinhard

(The first two authors contributed equally to this work)

Eye Center Medical Center, Faculty of Medicine, University of Freiburg, Germany

Purpose: To evaluate the feasibility of anterior segment spectral domain optic coherence tomography (ASOCT) as rejection readout in a keratoplasty mouse model and to compare ASOCT against the current standard (i.e., a clinical score system). Furthermore, to compare both approaches with respect to intra- and inter-individual observer variability and to calculate a critical point that distinguishes between rejection and non-rejection in ASOCT analysis.

Methods: Allogeneic penetrating keratoplasties (PKs) were performed using C3H/He donor mice and BALB/c recipient mice; syngeneic transplantations served as controls using BALB/c donors and recipients. Corneal graft rejection was determined with a clinical score. ASOCT was used to determine the central thickness of the corneal grafts in the same animals. The rejection status was corroborated with histopathological examination.

Results: The median survival time (MST) of the corneal allografts in the wild-type BALB/c mice was 12 days. Allogeneic transplantation led to a 100% rejection rate, whereas signs of rejection after syngeneic transplantation appeared in up to 20% of the mice. Central corneal thickness (CCT) determination via customized software revealed a direct correlation with the clinical score. Receiver operating curve (ROC) analysis confirmed CCT as a valid surrogate for rejection. Calculation of the area under the curve (AUC) revealed a value of 0.88 with an optimal cut-off at 267 pixels.

Conclusions: An increase in the CCT during acute allogeneic corneal graft rejection significantly correlated with the clinical surrogate parameter “corneal opacity.” ASOCT not only generates source data, but also analysis of the ASOCT data shows lower readout variability and fewer interpreter variations than the clinical score commonly used to define the time point of graft rejection in mice.

Within the last decade, lamellar keratoplasties have extended the surgical spectrum of corneal transplantation [1,2]. However, penetrating keratoplasty (PK) continues to be the most common form of allogeneic tissue transplantation worldwide [3,4]. For PK and lamellar corneal transplantation, immune-mediated corneal graft rejection remains the most common reason for graft failure [5-8]. To gain better insight into the processes that lead to graft rejection, animal models are indispensable.

Until now, the two most commonly used animal systems to study corneal graft rejection have been mouse and rat keratoplasty models. To define the onset of rejection, animal corneal graft rejection models depend on either a clinical score (CS) system (frequently called the rejection index) [9] or measurements of the increase in the central corneal thickness (CCT) during rejection [10].

Clinical score: Clinical score systems describe the corneal opacity through integration of the underlying parameters edema (due to endothelial dysfunction) and cellular infiltration. Currently, the clinical score represents a subjective assessment. This raises issues with interobserver variability, reproducibility, and objectivity. Furthermore, the definition of the time point of rejection is not well standardized. This is because the established score systems vary in the number of grading levels (e.g., four or up to six grades) and the endpoint definition of rejection (e.g., exceeding a score of either “2” or “3” or being calculated differently as the addition of various parameters, such as corneal neovascularization) [10-13]. The clinical score cannot be robustly derived solely from photographs as, for example, the illumination and the light incidence must be individualized for each observer and each animal. In summary, the major disadvantage of the current evaluation of rejection in rodent keratoplasty models is the lack of objectivity and verifiability: none of the CS systems generate source data that provide the requested reproducibility in animal studies.

Central corneal thickness: Therefore, to determine the time point of rejection, Flynn and coworkers suggested

Correspondence to: Thabo Lapp, Eye Center, Faculty of Medicine, Albert-Ludwigs-University of Freiburg, Killianstrasse 5, D-79106 Freiburg, Germany; Phone:+49 (0)761 270 40010; FAX:+49 (0)761 270 40630; email: Thabo.Lapp@uniklinik-freiburg.de

TABLE 1. CLINICAL SCORE.

Grade	Clinical description
0	completely transparent cornea
1	minimal corneal opacity with iris vessels easily visible
2	moderate corneal opacity with iris vessels still visible
3	moderate corneal opacity with only the pupillary margin visible
4	complete corneal opacity, pupil not visible

pachymetry [14]. The most important advantage of pachymetry measurements is that images can be used as source data and these images can be evaluated by different investigators at any time. Nevertheless, it is currently unclear whether an adequate increase in pachymetry is a valid surrogate for graft rejection because other parameters, such as stromal infiltration and/or neovascularization, are disregarded in this approach.

In this context, Liu and coworkers claimed that anterior segment spectral domain optic coherence tomography (ASOCT) not only evaluates corneal thickness more precisely but also analyzes anterior chamber inflammation (i.e., cellular infiltration, an additional surrogate parameter) as an early indicator of graft failure before changes in the rejection index in a rat transplantation model [10]. Thus far, this technique has been tested only in a rat model but not in a murine model.

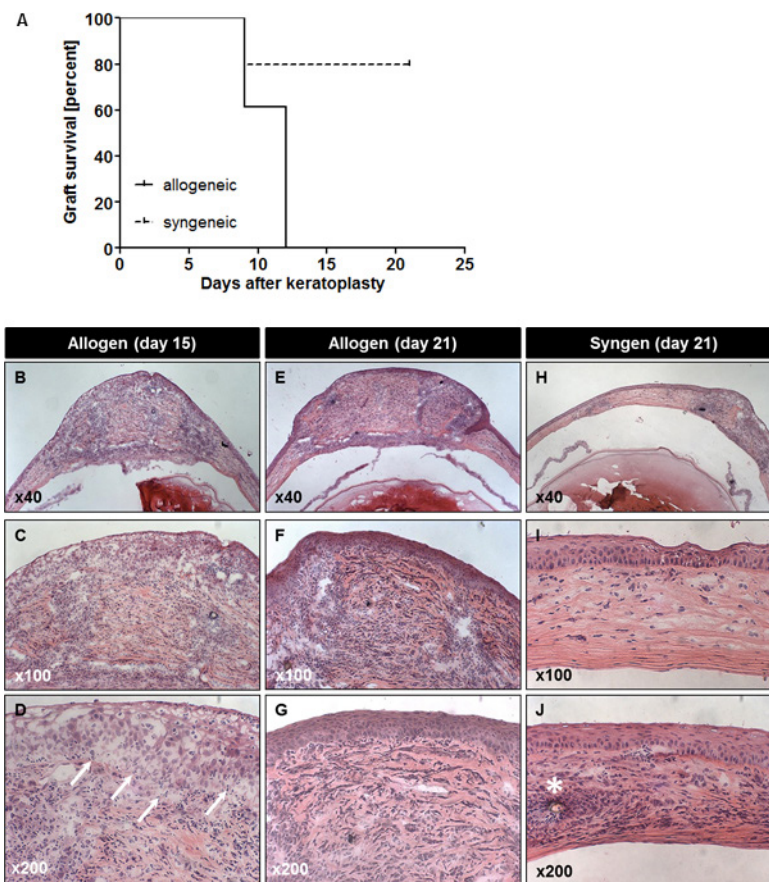


Figure 1. Kaplan–Meier curve and histology. Survival of allogeneic (continuous line) and syngeneic (interrupted line) transplants: 80% of syngeneic transplants survived. A: The median survival of the allogeneic transplants was 12 days. Cryosections were dissected at the indicated days after keratoplasty. B–G: The allogeneic transplants showed dense infiltration of inflammatory cells in addition to stromal edema. The syngeneic transplants showed less cellular infiltration around the sutures () and almost no edema (B–D: allogeneic day 15, E–G: allogeneic day 21, H–J: syngeneic day 21).

Rat and murine graft models are well-established in experimental transplant studies. A major disadvantage of mice is the higher technical skill level required. However, murine models are favored over rat models because the murine immune system is well characterized; more knockouts and siRNA knockdowns and a broader supply of diagnostic tools, such as specific anti-mouse antibodies, are available. Furthermore, economic factors, such as animal logistics and husbandry, encourage the use of mice.

Aim of this study: Thus far, a systemic review of corneal graft rejection characteristics comparing newer techniques, such as ASOCT has not been performed in mice. Therefore, our aims were

- to evaluate the model,
- to introduce ASOCT as a tool for defining graft rejection in a murine keratoplasty model,
- to compare the current standard (i.e., CS) against ASOCT measurements (i.e., CCT),
- to calculate the optimal cut-off value that distinguishes between rejection and non-rejection in ASOCT analysis, and
- to compare both approaches in terms of intra- (performed by one observer) and inter-individual observer variability.

METHODS

Ethics: All animal experiments were approved by the Faculty of Medicine, University of Freiburg and the federal state of Baden-Württemberg represented by the regional council Freiburg. Animals were treated in accordance with the European Union regulations for the care of experimental animals. This animal study was conducted in accordance with the ARVO Statement for the Use of Animals in Ophthalmic and Vision Research.

Animals: Inbred adult female BALB/c (H2^d) mice (Charles River, Sulzfeld, Germany) were used as graft recipients; female C3H/He mice (H2^k; Charles River, Sulzfeld, Germany) were used as allogeneic donors and BALB/c mice as syngeneic donors. Animals were treated in compliance with German, European, and Federation of Laboratory Animal Science Associations (LAS) regulations for the care of experimental animals.

Orthotopic corneal transplantation: Orthotopic corneal transplantation was performed in 6- to 12-week-old mice. The transplantation method we used was initially described by Zhang et al. [15] and further modified by Ardjomand et al. [16]. For our model, we established additional minor modifications. Anesthesia was performed with intraperitoneal

application of 10 mg/kg bodyweight xylazine (Bayer, Leverkusen, Germany) and 100 mg/kg bodyweight ketamine (Essex, München, Germany). A 2.0-mm diameter donor corneal graft was sutured into a 1.5-mm recipient corneal bed with eight 11–0 nylon single sutures (ETHILON® Nylon Suture, Ethicon Inc., Somerville, NJ). The donor female animals were 6 to 12 weeks old. All corneas used for corneal transplantation were completely clear before the grafting procedure; corneas with scarring or other opacifications were excluded. The corneas used for corneal grafting had central corneal thickness of between 52 and 67 pixels. The anterior chamber was reshaped after surgery with sterile saline solution, and Ofloxacin ointment (Floxal, Dr. Gerhard Mann, Chem.-pharm. GmbH, Germany) was applied to the cornea. The corneas were initially clear after keratoplasty. The eyelids were sutured with 7.0 Seralon (Serag-Wiessner GmbH & Co. KG, Naila, Germany) to protect the cornea over the initial 48 h. From the 3rd postoperative day and every 3rd day afterward, the eyes were examined using a surgical microscope. Technical failures, such as intraocular hemorrhage, signs of infection, collapse of the anterior chamber, or cataract, were excluded. The corneal sutures were not removed.

Definition of corneal graft rejection and rejection kinetics: The grading of corneal opacity has been described by Sonoda and Streilein [17], was further modified by Larkin et al. [16], and has been used by our group to assess corneal graft rejection in rats [18]. All grafts were examined every 3rd day in a masked fashion by two independent investigators for signs of opacity according to the following scoring. The onset of graft rejection was diagnosed when the corneal opacity increased to grade 3 (no iris vessels discernible) in a graft previously clear after transplantation. The grading used was defined as follows (see Table 1).

Anterior eye segment optical coherence tomography: The Micron IV Retinal Imaging System (Phoenix Research Laboratories, Pleasanton, CA) and the Anterior Segment Slit Lamp Imaging System and Image Guided Optical Coherence Tomography for Mice (Phoenix Research Laboratories, Cat. No. 9002) were used for ASOCT. For analysis, the animals were anesthetized with an injection of 10 mg/kg bodyweight xylazine (Bayer) and 100 mg/kg bodyweight ketamine (Essex).

Evaluation of OCT images: Tomographic images were used to measure transplant thickness in pixels, defined in a central vertical section using Cell Finder software [19]. OCT tends to distort anatomic structures. To exclude systemic errors, we always performed vertical and horizontal thickness CCT measurements within the same eye and defined the

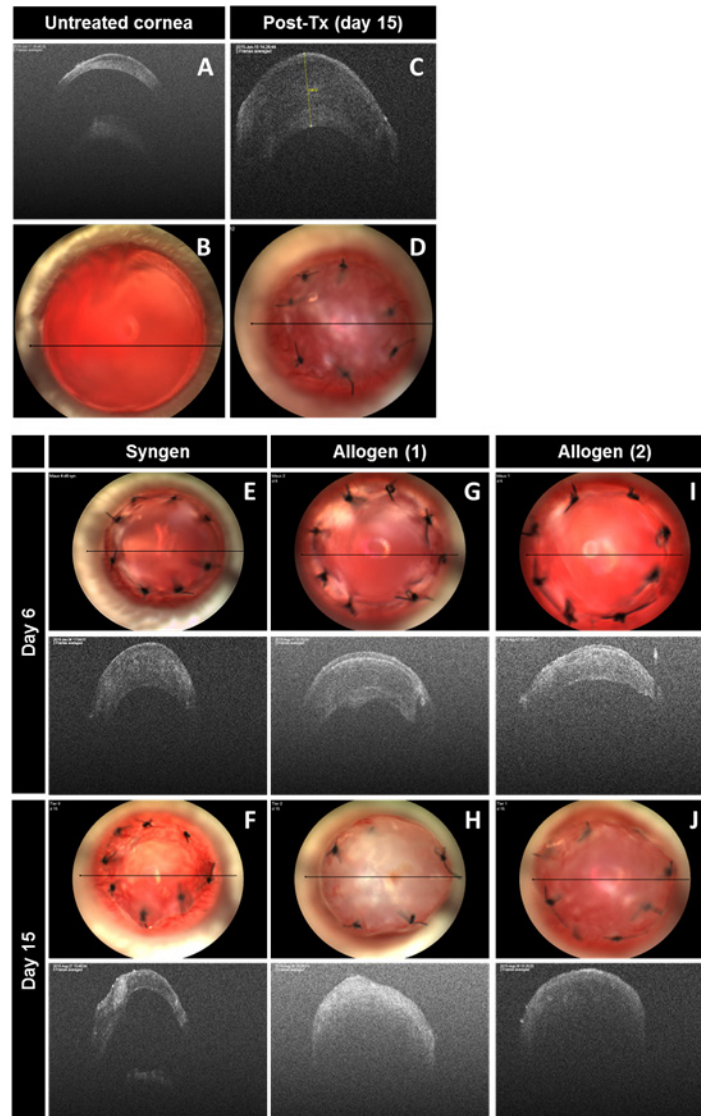


Figure 2. ASOCT. **A**: The upper left panel shows an example of an untreated cornea before transplantation. **C**: The upper right panel shows an anterior segment spectral domain optic coherence tomography (ASOCT) image of a transplanted cornea at day 15 after transplantation; the yellow line indicates the caliper for the graft thickness assessment. The black bars (**B** and **D**) indicate the location of the ASOCT section. Examples of syngeneic (**E** and **F**) and allogeneic grafts at day 6 (**G** and **I**) and day 15 after keratoplasty (**H** and **J**). Each panel shows photographs of the cornea (**E–J**). The black bar indicates the location of the tomographic section. The photographs depict a clear corneal transplant at day 6 for all animals (**E**, **G**, and **I**). After syngeneic transplantation, the cornea remains transparent until day 15. Afterward, the allogeneic transplants show signs of rejection, that is, an increase in opacity and corneal edema (**H** and **J**). ASOCT shows no differences between the syngeneic and allogeneic transplants at day 6 (**E**, **G**, and **I**). However, there is an increase in edema at day 15 in the allogeneic keratoplasties (**H** and **J**). The syngeneic transplants showed a decrease in edema at day 15 (**F**).

average central thickness in pixels. All grafts were analyzed by imaging one horizontal virtual section and one vertical virtual section through the transplant every 3rd day starting with day 6 after keratoplasty.

Histology: All specimens collected were frozen in TissueTek® O.C.T.™ Compound (Sakura Finetek Europe, Alphen aan den Rijn, The Netherlands) and stored at -20°C . Six-micron

sections were cut in a Microtome 3050S (Leica, Wetzlar, Germany), stained with hematoxylin and eosin and periodic acid-Schiff, and examined under a light microscope.

Statistical analysis and ROC analysis: Receiver operating curve (ROC) calculations were performed using the R platform [20]. Data are presented as mean \pm standard error of the mean (SEM). Statistical analysis was performed using

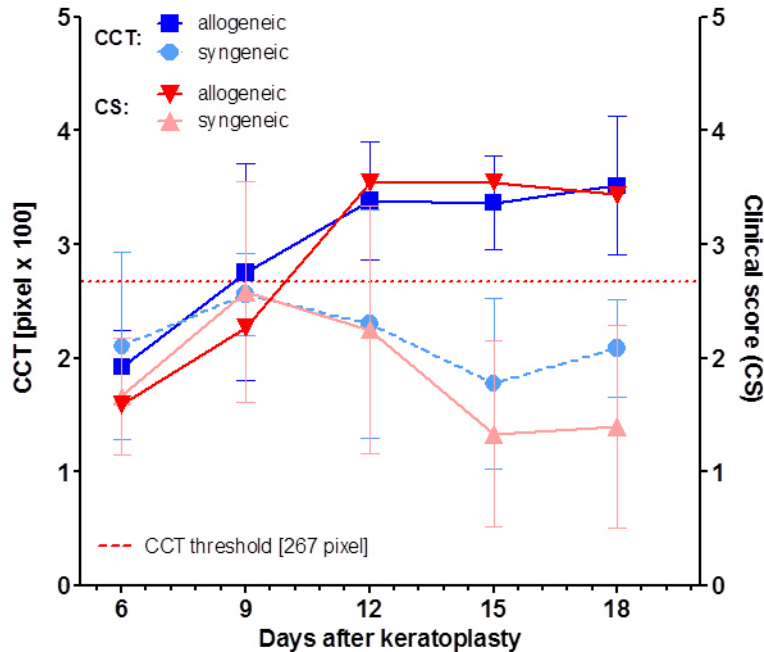


Figure 3. Correlation of CS and CCT. Starting at day 6, the clinical score (CS) increased in both groups until day 9. Thereafter, the score decreased after syngeneic transplantation and increased after allogeneic transplantation. Corresponding to these findings, the corneal thickness (CCT) increased in both groups until day 9. Afterward, the CCT decreased in the syngeneic transplants and increased in the allogeneic transplants. The red line indicates the rejection threshold at 267 pixels.

GraphPad Prism (GraphPad Software Inc., LaJolla, CA; version 6.0) or R. Before the analysis, the results were subjected to descriptive analysis and determination of normality using a Kolmogorov–Smirnov test. For samples with a normal distribution, we applied ANOVA (ANOVA) or Student *t* tests for unpaired samples. Survival analyses were tested with the log-rank test. P values of less than 0.05 were considered statistically significant.

RESULTS

Aim 1: Model evaluation with clinical and histological findings: Orthotopic corneal transplantation was performed in adult female BALB/c mice ($n = 13$). The female C3H/He mice served as allogeneic donors, and the BALB/c female donor mice served as syngeneic controls ($n = 5$). Rejection occurred in the allogeneic group between day 9 and 12 (median day 12.0; Figure 1A). The syngeneic group, however, showed 20% graft rejection as defined in the conventional clinical grading evaluating graft transparency.

Graft rejections were confirmed with histology. Early stages of rejection were associated with endothelial dysfunction and epithelial edema (arrows in Figure 1D). Epithelial edema resulted over time in both groups (Figure 1G,J). Corneal infiltrate and increased corneal thickness persisted in the allogeneic group (Figure 1E-G). The syngeneic group showed fewer inflammatory cells in the corneal stroma (Figure 1I) except for focal inflammation next to the sutures

(* in Figure 1J). Suture removal had no influence on the rate and time point of the onset of graft rejection (data not shown).

Aim 2: Graft imaging via ASOCT in a mouse model: Graft thickness was analyzed with ASOCT every third day. Corneal thickness was derived from ASOCT tomographic pictures using custom software based on the R platform [20] (yellow line in Figure 2C). The left panel (Figure 2A,B) shows an untreated cornea. The center of the cornea, the anterior chamber, and the anterior pole of the lens can be defined. The right panel (Figure 2C,D) depicts a cornea with edema on day 15 after transplantation.

Initially, all grafts were transparent on day 6. The anterior chamber was intact; the corneas showed minor swelling (Figure 2E,G,I, day 6). At later stages (Figure 2F,H,J, day 15), the edema in the syngeneic grafts (Figure 2F) resolved whereas it increased further in the allogeneic group (Figure 2H,J). Photographs depict distinct opacity in the allogeneic transplants (Figure 2H,J in the lower panel) and constant transparency in the syngeneic graft (Figure 2F, lower panel).

Starting from day 6, we analyzed all grafts via ASOCT every 3rd day. Before transplantation (Figure 2A,B) or in the early stages of rejection (here shown for day 6, Figure 2 or Appendix 1 upper panel), the full corneal graft thickness was identified in both groups.

Details in the anterior chamber (e.g., flair or cellular infiltrates) could not be used as a diagnostic parameter in the present study due to the swelling and reduced transparency.

The initial edema in the syngeneic group dissolved over time (Appendix 1, left upper panel). After the initial edema, no further increase in corneal thickness was found in these animals. In contrast, the animals with allogeneic corneal transplantation showed progression in corneal graft thickness. In some cases, this edema even led to an inability to detect Descemet’s membrane (Appendix 1).

Aim 3: Correlation between CS and CCT: Graft rejection was defined clinically by grading graft transparency. Grade 0 was defined as a fully transparent graft, through which the iris vessels and the pupil margin were easily visible. Grade 3 represents progressing opacification with undetectable iris vessels but a still detectable pupil; this grade was defined as “rejected.” Grade 4 was defined as complete corneal opacification (see Table 1). The eyelids were sutured closed to protect the cornea for the initial 48 h; a clinical examination was performed starting at day 6 every 3 days. Both groups showed mild postoperative corneal opacification until day 9 that decreased in the syngeneic group and increased in the allogeneic group (Figure 3; also see histology, Figure 1).

We correlated ASOCT with the CS to evaluate the dynamics and concordance between the corneal edema and

the corneal thickness. The CCT correlated well with the clinical score (Figure 3). The CCT increased between day 6 and day 9 with persisting or increasing corneal swelling in the allogeneic group and decreased swelling in the syngeneic group. In the untreated corneas, ASOCT allowed evaluation of the whole cornea, the anterior chamber, and the anterior lens pole (Figure 2A). Shortly after transplantation and during rejection, the increased corneal thickness precluded discrimination of deeper intraocular structures (Figure 2E-J).

Aim 4: ROC analysis: We calculated the AUC from the ROC analysis for the CCT predicting rejection as defined by the CS. Defining the onset of rejection at a clinical score of 3 or higher (Appendix 2), the ROC analysis showed an AUC of 0.88. Thus, the increased CCT predicted a graft rejection event (see Figure 3). However, this was not the case for a clinical score of 2 or higher (Appendix 2). The AUC calculations revealed the optimal cut-off point for detecting rejection was a CCT value of 267 pixels (the CCT threshold in Figure 3).

Aim 5: Interobserver agreement: We analyzed inter-investigator variability separately for the CS and the CCT. The allogeneic mice were evaluated by two investigators in a

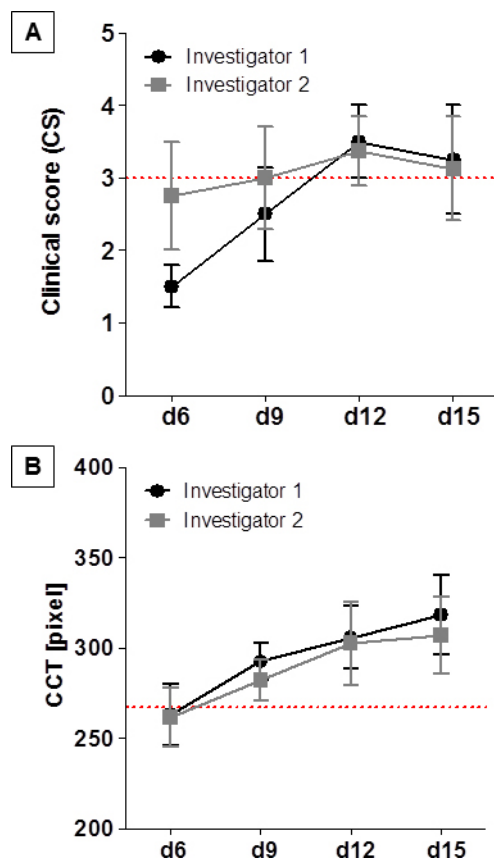


Figure 4. Comparison of CS and CCT between two investigators. Comparison of CS (A) and CCT (B) between two investigators: Two independent investigators evaluated transplants via the clinical score system and anterior segment spectral domain optic coherence tomography (ASOCT) images of the same animals on the indicated days after keratoplasty. The disagreement range using corneal thickness (CCT) measurements was lower in the CCT than using the clinical score (CS).

double-masked fashion. Comparing the day of graft rejection defined by using the CS (Figure 4A) or the CCT (Figure 4B) showed distinct inter-investigator reliability (e.g., graft rejection was already defined by one investigator at day 9 using the clinical score but not by the second investigator).

The central corneal thickness increased over time after transplantation. Both investigators analyzed ASOCT images from day 6, 9, 12, and 15, and defined the CCT (Figure 4B). The disagreement range using CCT measurements—especially within the first 9 days—was lower in the CCT than using the CS.

DISCUSSION

Murine models comprise established *in vivo* systems for corneal graft rejection. Mice provide a well-known genetic background and represent a useful alternative to other rodents (i.e., mainly rats) or mammal corneal graft models.

As the first step, we used an established clinical score for grading corneal opacity. Defined by this score and working with C3H/He donor mice and BALB/c recipients, all grafts developed a rejection period. Using a clinical score system in the allogeneic controls seemed reasonable. However, one of the control animals showed symptoms of immune-mediated rejection (20%), although these symptoms disappeared later. Furthermore, graft rejection could be confirmed and correlated with histological findings. Thus far, when focusing on corneal opacity, we distinguished between syngeneic and allogeneic corneal transplantation and consecutive immune rejection. Nevertheless, the interobserver (dis)agreement using the CS varied significantly, especially within the first 9 days.

To further improve the rejection readout, we introduced ASOCT measurements in this murine corneal graft model. In terms of the increased opacity defined by the clinical score, we found an increase in the CCT measured with ASOCT. From the AUC calculations, the CCT cut-off point was 267 pixels. This threshold distinguished between the rejection and survival of a graft. Additionally, OCT pictures taken of the mice and analyzed by blinded investigators showed better inter-investigator reliability than the clinical score. In a comparison of the two methods, the CCT evaluation showed high conformance. The CS correlated with the increasing corneal thickness in the OCT measurements.

We considered the detectability of Descemet's membrane an anatomic landmark. In all syngeneic cases, Descemet's membrane could be seen over the whole survey; this was not true for all allogeneic transplanted animals. Here, however, a difficulty arose that the corneal thickness could not be

evaluated in its entirety if Descemet's membrane was not accessible. Interestingly, single ASOCT images showed the distinction between epithelium and stroma, most likely Bowman's layer. We therefore conceived the idea that ASOCT might be useful for distinguishing between different types of rejection. In humans, epithelial, stromal, and endothelial rejection has been reported. In rodents, however, this distinction has not been described. Therefore, we suggest further investigation into the correlation between histology and OCT images. There might be a correlation that distinguishes between endothelial versus stromal rejections with prominent graft swelling during stromal or endothelial rejection (and thus the loss of the detectability of Descemet's membrane) versus a visible Bowman's layer as a parameter for epithelial or anterior stromal rejection.

As a final result, we found that corneal graft rejection in a murine model not only can be defined by using a clinical score that determines graft opacity but also newer methods such as anterior eye segment OCT may be superior in terms of precision and objectivity. Two additional advantages of OCT measurements are the generation of source data (which allows other observers to reproduce the time point of the rejection onset) and higher repeatability when working with OCT images. We recommend using this method in the future, not only to improve rejection readouts but also to be able to verify results at later points of time. It is likely that the effects of differently treated recipient groups are more obvious and occur earlier during the observation period.

APPENDIX 1. TIME COURSE OF CORNEAL THICKNESS MEASUREMENTS:

Exemplary syngeneic and allogeneic grafts illustrate the time course of corneal swelling after transplantation. All transplants increased in thickness until day 9. Afterwards syngeneic transplants showed a reduced corneal swelling almost attaining preoperative thickness; allogeneic transplants increased in thickness. To access the data, click or select the words "[Appendix 1.](#)"

APPENDIX 2. ROC ANALYSIS:

The first ROC curve shows a reliable predictability when graft rejection was defined with a clinical score of 3 or higher (A; AUC of 0.88). Changing the definition of graft rejection with score of 2 or higher led to a decrease of the AUC (B; AUC of 0.62). To access the data, click or select the words "[Appendix 2.](#)"

REFERENCES

1. Maier P, Reinhard T, Cursiefen C. Descemet stripping endothelial keratoplasty—rapid recovery of visual acuity. *Dtsch Arztebl Int* 2013; 110:365-71. [PMID: 23795211].
2. Keane M, Coster D, Ziaei M, Williams K. Deep anterior lamellar keratoplasty versus penetrating keratoplasty for treating keratoconus. In: *Cochrane Database of Systematic Reviews*. John Wiley & Sons, Ltd; 2014. <http://onlinelibrary.wiley.com/doi/10.1002/14651858.CD009700.pub2/abstract>. Accessed January 11, 2016.
3. Report of the organ transplant panel. Corneal transplantation. Council on Scientific Affairs. *JAMA* 1988; 259:719-22. [PMID: 3275820].
4. Eye Bank Association of America. 2014 Eye Banking Statistical Report - Eye Bank Association of America. 2015. http://www.restore sight.org/wp-content/uploads/2015/03/2014_Statistical_Report-FINAL.pdf. Accessed January 11, 2016.
5. van Essen TH, Roelen DL, Williams KA, Jager MJ. Matching for Human Leukocyte Antigens (HLA) in corneal transplantation – To do or not to do. *Prog Retin Eye Res* 2015; 46:84-110. [PMID: 25601193].
6. Allan BDS, Terry MA, Price FW, Price MO, Griffin NB, Claesson M. Corneal transplant rejection rate and severity after endothelial keratoplasty. *Cornea* 2007; 26:1039-42. [PMID: 17893530].
7. Mashor RS, Kaiserman I, Kumar NL, Sansanayudh W, Rootman DS. Deep lamellar endothelial keratoplasty: up to 5-year follow-up. *Ophthalmology* 2010; 117:680-6. [PMID: 20189655].
8. Reinhard WJ, Musch DC, Jacobs DS, Lee WB, Kaufman SC, Shtein RM. Deep anterior lamellar keratoplasty as an alternative to penetrating keratoplasty a report by the american academy of ophthalmology. *Ophthalmology* 2011; 118:209-18. [PMID: 21199711].
9. Larkin DF. Corneal allograft rejection. *Br J Ophthalmol* 1994; 78:649-52. [PMID: 7918294].
10. Liu Y-C, Lwin NC, Chan NSW, Mehta JS. Use of anterior segment optical coherence tomography to predict corneal graft rejection in small animal models. *Invest Ophthalmol Vis Sci* 2014; 55:6736-41. [PMID: 25249608].
11. Chen G-L, Zhang J-J, Zhao J, Wang D-J, Zhang H. Evaluation of corneal graft survival in mice model. *Int J Ophthalmol* 2013; 6:578-83. [PMID: 24195028].
12. Plšková J, Kuffová L, Holáň V, Filipec M, Forrester JV. Evaluation of corneal graft rejection in a mouse model. *Br J Ophthalmol* 2002; 86:108-13. [PMID: 11801514].
13. Cursiefen C, Cao J, Chen L, Liu Y, Maruyama K, Jackson D, Kruse FE, Wiegand SJ, Dana MR, Streilein JW. Inhibition of hemangiogenesis and lymphangiogenesis after normal-risk corneal transplantation by neutralizing VEGF promotes graft survival. *Invest Ophthalmol Vis Sci* 2004; 45:2666-73. [PMID: 15277490].
14. Flynn TH, Ohbayashi M, Dawson M, Siddique M, Ono SJ, Larkin DFP. Use of ultrasonic pachymetry for measurement of changes in corneal thickness in mouse corneal transplant rejection. *Br J Ophthalmol* 2010; 94:368-71. [PMID: 19822919].
15. Zhang EP, Schründer S, Hoffmann F. Orthotopic corneal transplantation in the mouse—a new surgical technique with minimal endothelial cell loss. *Graefes Arch Clin Exp Ophthalmol Albrecht Von Graefes Arch Für Klin Exp Ophthalmol* 1996; 234:714-9. [PMID: 8950593].
16. Ardjomand N, McAlister JC, Rogers NJ, Tan PH, George AJT, Larkin DFP. Modulation of costimulation by CD28 and CD154 alters the kinetics and cellular characteristics of corneal allograft rejection. *Invest Ophthalmol Vis Sci* 2003; 44:3899-905. [PMID: 12939307].
17. Sonoda Y, Streilein JW. Impaired cell-mediated immunity in mice bearing healthy orthotopic corneal allografts. *J Immunol Baltim Md*. 1993; 150:1727-34. [PMID: 8436812].
18. Hildebrand A, Jarsch C, Kern Y, Böhringer D, Reinhard T, Schwartzkopff J. Subconjunctivally applied naïve Tregs support corneal graft survival in baby rats. *Mol Vis* 2014; 20:1749-57. [PMID: 25558177].
19. Gasser L, Reinhard T, Böhringer D. Comparison of corneal endothelial cell measurements by two non-contact specular microscopes. *BMC Ophthalmol* 2015; 15:[PMID: 26219961].
20. R Core Team. *R: A Language and Environment for Statistical Computing*. Vienna, Austria: R Foundation for Statistical Computing; 2013. <http://www.R-project.org>.

Articles are provided courtesy of Emory University and the Zhongshan Ophthalmic Center, Sun Yat-sen University, P.R. China. The print version of this article was created on 17 October 2016. This reflects all typographical corrections and errata to the article through that date. Details of any changes may be found in the online version of the article.