

Case Report

Transvaginal Oocyte Retrieval Complicated by Life-Threatening Obturator Artery Haemorrhage and Managed by a Vessel-Preserving Technique.

Ferdia Bolster¹, Edgar Mocanu², Tony Geoghegan¹, Leo Lawler¹

Accepted 11th June 2014

ABSTRACT:

We report the case of a 36-year-old woman with secondary infertility who underwent routine transvaginal oocyte retrieval as part of IVF treatment. Four days following the procedure she presented with life threatening haemorrhagic shock. She underwent surgical laparotomy followed by CT and selective angiography, which demonstrated haemorrhage from a pseudoaneurysm of the obturator artery. The haemorrhage was successfully managed endovascularly with a vessel preserving covered stent.

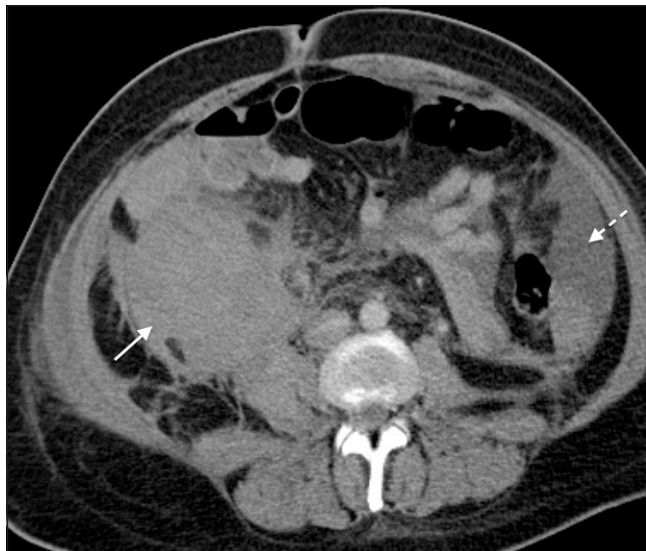


Fig 1. CT demonstrates a large right sided retroperitoneal haematoma (solid white arrow) and intra-abdominal free fluid consistent with haemorrhage (interrupted white arrow).

CASE:

A 36-year-old female with secondary infertility underwent ultrasound-guided transvaginal oocyte retrieval during her third IVF cycle. Postoperative discomfort persisted for longer than usual and she was admitted for observation. As she had persistent right sided back discomfort she remained in hospital while undergoing investigations. On the fourth day she developed light headedness and collapsed. The patient was resuscitated and underwent emergency laparotomy, which revealed a large right sided retroperitoneal haematoma. No

further surgical exploration was pursued as no intraperitoneal bleeding was observed and because of the risk of severe bleeding associated with decompressing. She was transfused and haemodynamically stabilised with 5 units of packed red cells, 3 pools of plasma (Octaplast) and 2 pools of platelets and referred for radiological management. CT angiography (CTA) of abdomen and pelvis demonstrated active bleeding from a right internal iliac artery branch pseudoaneurysm and a large retroperitoneal haemorrhage (Figs 1 and 2). She was transferred directly to the angiography suite for emergency endovascular assessment and therapy.

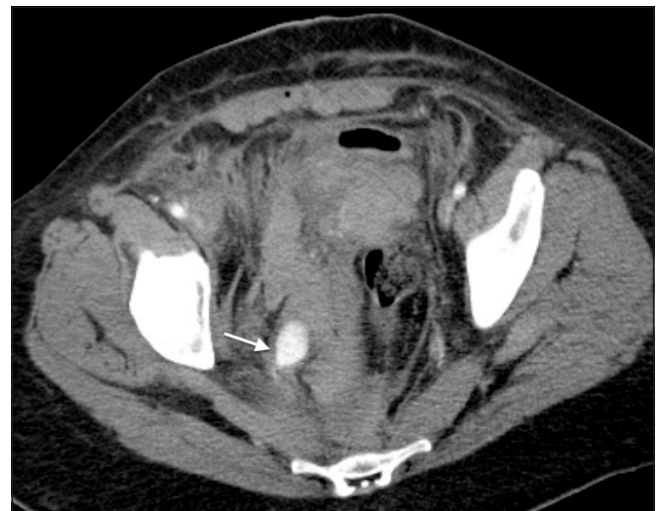

Fig 2. CTA demonstrates a vascular "blush" of a 2cm pseudoaneurysm and active extravasation from a branch of the right internal iliac artery (white arrow).

A retrograde 5Fr sheath was inserted into the left common femoral artery under ultrasound guidance. Up and over selective cannulation of the right internal iliac artery was performed and demonstrated a relatively large obturator artery pseudoaneurysm (see Fig 3). The pseudoaneurysm

1 Department of Radiology, Mater Misericordiae University Hospital, Dublin, Ireland. 2 Department of Obstetrics and Gynaecology, Royal College of Surgeons in Ireland, Dublin, Ireland

Correspondence to: Ferdia Bolster

Email: ferdiabolster@hotmail.com

neck was crossed with a combination microcatheter .014 wire. The bleeding site was treated with a 3mm x10mm coronary artery covered stent (Jo Stent Graftmaster) (see Fig 4). Subsequent DSA showed good stent position and cessation of extravasation of contrast (Fig.5). The patient made a rapid full recovery and a follow up CTA performed the next day confirmed good stent positioning with no extravasation of contrast into the treated pseudoaneurysm.

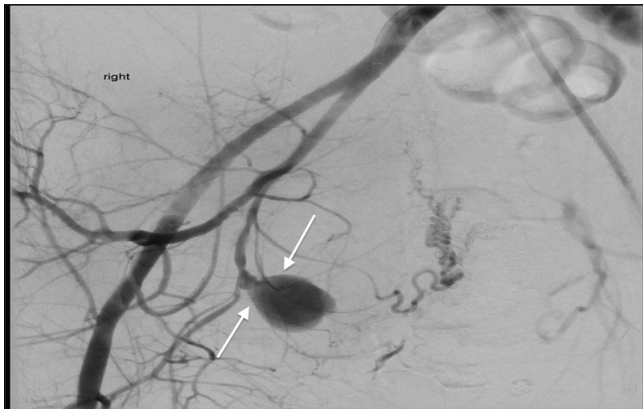

Fig 3. Up and over selective cannulation of the right internal iliac artery was performed and demonstrated a 2cm saccular obturator artery pseudoaneurysm (white arrows).

DISCUSSION:

Transvaginal oocyte retrieval is a frequently performed assisted reproduction technology (ART) procedure. Under direct ultrasound guidance an aspiration needle is passed through the lateral fornix of the vagina into the stimulated ovary with subsequent aspiration of follicles.

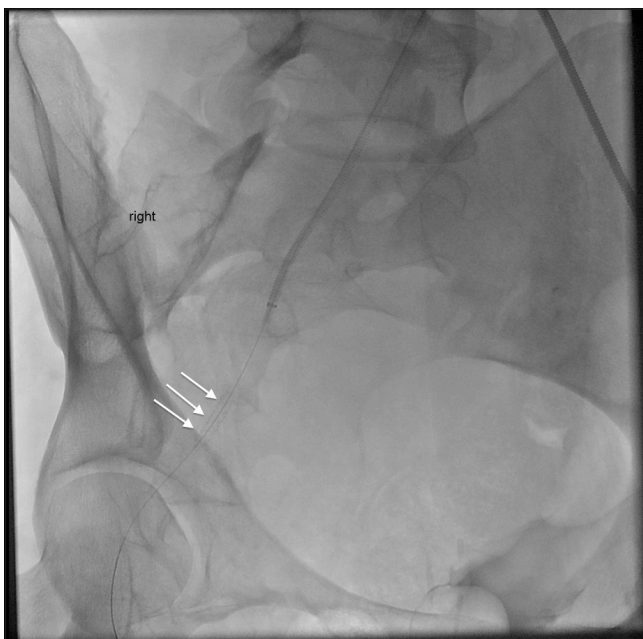

Fig 4. The bleeding site was treated with a 3mm x10mm coronary artery covered stent (Jo Stent Graftmaster) (white arrows).

The internal iliac arteries and their branches are potentially at risk as they lie in close proximity to the ovarian tissue. Pelvic conditions like endometriosis or severe PID, frequently

encountered in patients requiring IVF can fix the ovary upon the pelvic wall increasing the risk of organ injury. Minor arterial/venous haemorrhage, thought to arise from direct trauma to the adjacent vessels, is a common complication occurring in 1.4-18.4% of punctures¹ but can usually be managed with local treatment such as local pressure.² Internal iliac pseudo-aneurysm is an extremely rare but potentially fatal complication of ART. It has only twice been reported in the literature^{3,4}. Both previously described cases presented much later following initial oocyte retrieval with one patient presenting in the 29th gestational week and the other over 10 years after successful IVF^{3,4} and neither case presented in extremis. Lifesaving laparoscopy or laparotomy may be required in cases of large bleeding⁵.

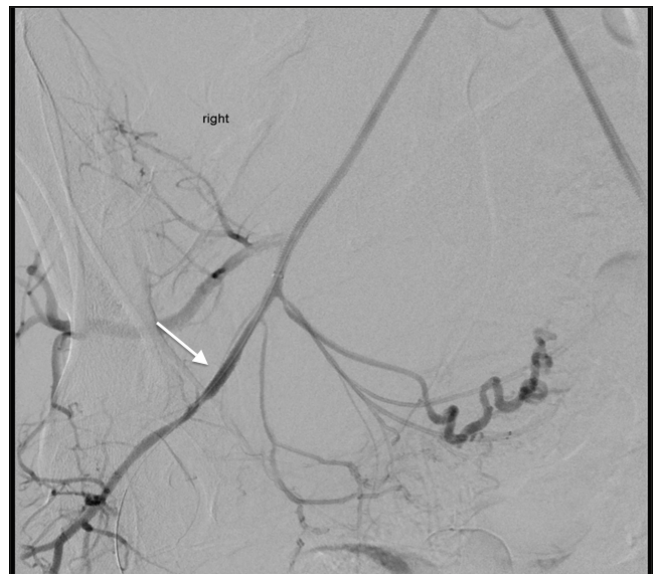


Fig 5. Post stenting DSA showed good stent position and cessation of extravasation of contrast with preservation of the native artery (white arrow).

We are not aware of another case of retroperitoneal bleeding reported to date. While the abdominal bleed or indeed the aneurysm can be easily diagnosed, a retroperitoneal bleed is usually concealed and requires specific management.

An endovascular approach offers an alternative with high success rate and the additional advantage of preserving fertility through organ preservation⁶. Traditionally selective uterine artery embolisation is performed with an embolic agent (e.g. coil, gelfoam, thrombin or glue) and typically involves vessel sacrifice.^{5,6} To our knowledge this is the first case of an internal iliac pseudoaneurysm following transvaginal oocyte retrieval managed with an alternative vessel preserving stent technique.

Rapid access to advanced non-invasive and invasive diagnostic imaging was key to the successful management of this case. CTA permitted direct transfer to fast selective angiography. Microcatheter, covered stent techniques allowed immediate bleeding control and ultimately organ and vessel preservation. As the complexity of cases attending for ART is increasing and the procedure is performed on an ever

expanding number of patients it is important to recognize such complications and avail of rapid and efficient radiological diagnosis and treatment, particularly in the circumstances of concealed bleeding where the surgical intervention is limited.

REFERENCES:

1. El Shawarby S., Margara R, Trew G, Lavery S. A review of complications following transvaginal oocyte retrieval for *in vitro* fertilisation. *Hum Fertil.* 2004;**7**(2):127-33.
2. Tureck RW, Garcia CR, Blasco L, Mastroianni L Jr. Perioperative complications arising after transvaginal oocyte retrieval. *Obstet Gynecol.* 1993;**81**(4):590-3.
3. Bozdag G, Basaran A, Cil B, Esinler I, Yarali H. An oocyte pick-up procedure complicated with pseudoaneurysm of the internal iliac artery. *Fertil Steril.* 2008;**90**(5):2004.e11-3
4. Pappin C, Plant G. A pelvic pseudoaneurysm (a rare complication of oocyte retrieval for IVF) treated by arterial embolisation. *Hum Fertil.* 2006;**9**(3):153-5.
5. Kart C, Guven S, Aran T, Dinc H. Life Threatening intraabdominal bleeding after oocyte retrieval successfully managed with angiographic embolization. *Fertil Steril.* 2011 96;2:e99-e102
6. Winograd RH. Uterine artery embolization for postpartum hemorrhage. *Best Pract Res Clin Obstet Gynaecol.* 2008;**22**(6):1119-32.