

## Customized endovascular repair of common iliac artery aneurysms

Andrew Soo Hoo, MD,<sup>a</sup> Liam Ryan, MD,<sup>b</sup> Richard Neville, MD,<sup>a</sup> and Dipankar Mukherjee, MD,<sup>a</sup> Falls Church, Va

### ABSTRACT

Open technique for elective repair of iliac artery aneurysms can be safely performed with good outcomes but not inconsequential morbidity. An endovascular approach has been shown to have both periprocedural and postoperative advantages with equivalent outcomes. Endovascular repair of common iliac arteries (CIAs) without sacrificing the hypogastric artery using an iliac branch device is a complex endovascular technique requiring a proximal seal zone that may be absent in larger CIA aneurysms. We present two cases in which CIA aneurysms were repaired with a customized endovascular technique using the benefit of the aortic bifurcation for stability in addition to providing a long proximal seal zone with the AFX device (Endologix, Irvine, Calif) paired with the iliac branch device (W. L. Gore & Associates, Flagstaff, Ariz) for internal iliac artery preservation. (*J Vasc Surg Cases and Innovative Techniques* 2018;4:278-82.)

**Keywords:** Common iliac artery aneurysm; Endovascular

Isolated iliac artery aneurysms are uncommon and represent <2% of all abdominal aneurysmal disease. Endovascular repair of iliac artery aneurysms has demonstrated advantages over open repair, and use of an iliac branch device (IBD) is well described.<sup>1,2</sup> Concomitant abdominal aortic aneurysm and common iliac artery (CIA) aneurysm is common; the incidence has been reported to be between 16% and 40%.<sup>3-5</sup> The use of an IBD has been shown to be an effective treatment option for iliac aneurysms, including for patients with challenging anatomies.<sup>6</sup> Complex aortic and iliac anatomy as graded by the anatomic severity grade has been shown to be associated with increased complications, resource utilization, and mortality. We and others think that appropriate preoperative planning in conjunction with a customized endovascular repair yields the best long-term results.<sup>7,8</sup> The following cases highlight a novel approach to the endovascular repair of isolated CIA aneurysms. The patients have consented to publication of their cases, including all associated imaging.

### CASE REPORT

**Case 1.** The patient is a 73-year-old man with history of previous thoracic endovascular aortic repair (TEVAR) for a type B

aortic dissection in 2015. Surveillance imaging demonstrated enlarging bilateral CIA aneurysms with an associated abdominal aortic aneurysm. He was asymptomatic at the time of evaluation. The descending thoracic aorta beyond the covered stent measured 4.4 cm in diameter, with propagation of the dissection (Figs 1 and 2) involving the left CIA, external iliac artery, and common femoral artery (CFA). The celiac, superior mesenteric artery, and single right renal artery arose from the true lumen. Two left renal arteries were identified, one coming off the true lumen and the other from the false lumen. The abdominal aorta was aneurysmal, measuring 4.0 × 5.3 cm. There was bilateral aneurysmal dilation of CIAs, with the right CIA measuring 3.6 cm and the left CIA measuring 3 cm; the left internal iliac artery aneurysm measured 4.3 × 3.5 cm. Three months before the index operation, the patient underwent endovascular coiling of the main trunk of the left hypogastric artery to exclude this diseased vessel.

Given the history of TEVAR, a spinal drain was placed preoperatively. Through-and-through access was gained from the right brachial artery under ultrasound guidance, and a guidewire was directed into the left CFA; the wire was retrieved from the true lumen by performing a cutdown and an arteriotomy on the anterior wall of the left CFA. The right CFA was accessed with percutaneous technique. Intravascular ultrasound was used through the left groin over a Lunderquist wire (Cook Medical, Bloomington, Ind) to confirm access within the true lumen, and the origin of the visceral vessels was confirmed to be arising from the true lumen as well. The patient was then heparinized. To increase the true lumen of the left CIA and external iliac artery for placement of subsequent endovascular devices, a 14.5- × 12-mm Gore iliac limb (W. L. Gore & Associates, Flagstaff, Ariz) was placed in the left common and external iliac arteries under fluoroscopic guidance (Fig 3, A and B) after the left groin sheath had been upsized to a 12F sheath and the right groin had been upsized to a 17F AFX sheath (Endologix, Irvine, Calif). A 25- × 80- × 40-mm AFX bifurcated device was loaded into the infrarenal aorta. The contralateral wire was snared and pulled

From the Division of Vascular Surgery<sup>a</sup> and Cardiothoracic Surgery,<sup>b</sup> Inova Fairfax Hospital.

Author conflict of interest: none.

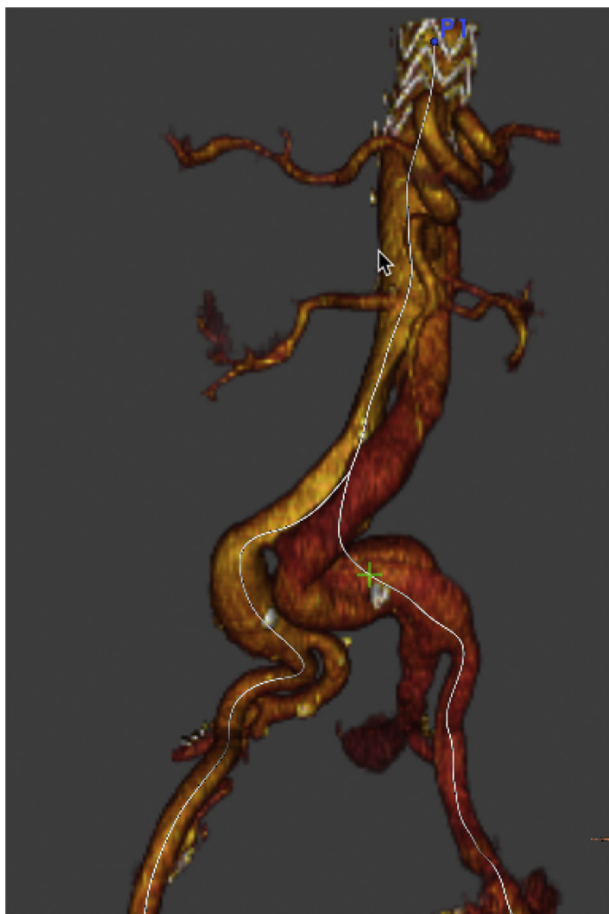
Correspondence: Andrew J. Soo Hoo, MD, Inova Fairfax Hospital, 3300 Gallows Rd, Falls Church, VA 22042 (e-mail: [andrew.j.soo@inova.org](mailto:andrew.j.soo@inova.org)).

The editors and reviewers of this article have no relevant financial relationships to disclose per the Journal policy that requires reviewers to decline review of any manuscript for which they may have a conflict of interest.

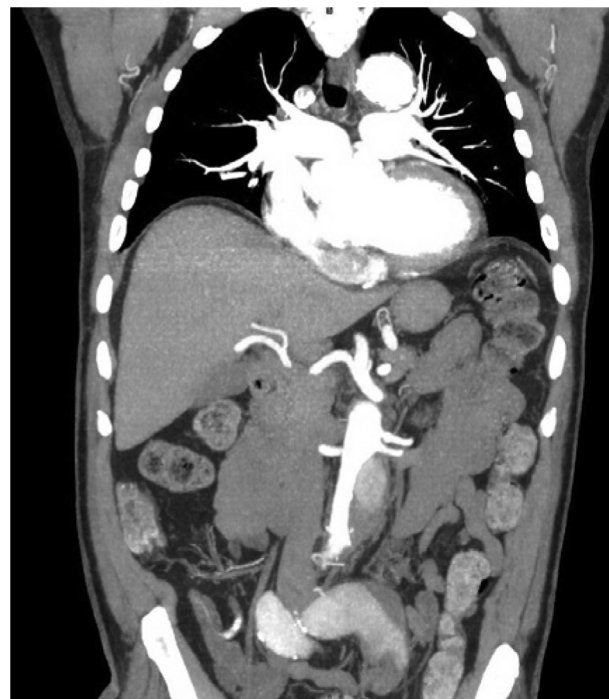2468-4287

Published by Elsevier Inc. on behalf of Society for Vascular Surgery. This is an open access article under the CC BY-NC-ND license (<http://creativecommons.org/licenses/by-nc-nd/4.0/>).

<https://doi.org/10.1016/j.jvscit.2018.07.009>



**Fig 1.** Three-dimensional reconstructed computed tomography (CT) angiogram demonstrating abdominal aortic aneurysm, left common iliac artery (CIA), and left internal iliac artery with propagation of aortic dissection involving the left CIA, external iliac artery, and common femoral artery (CFA).

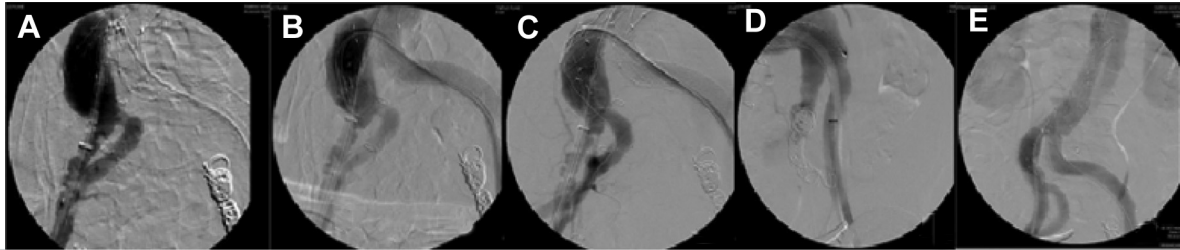


**Fig 2.** Coronal cut of computed tomography (CT) angiogram demonstrating infrarenal abdominal aortic dissection and tortuous left common iliac artery (CIA) with associated dissection.

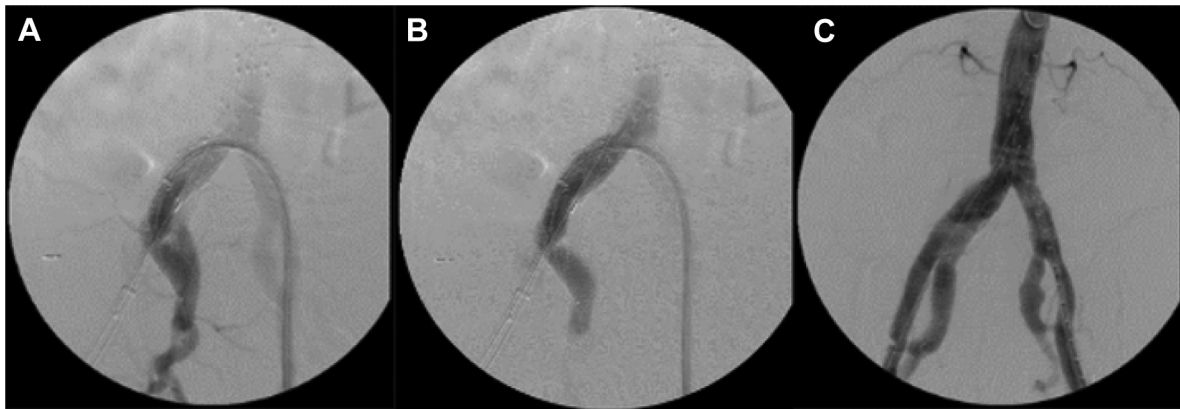out the contralateral side, and the device was pulled down to the aortic bifurcation and deployed. The repair on the left was extended using a 16- × 120-mm Gore iliac extender. The infrarenal and aortic device was ballooned into place for fixation. Next, a 23- × 10-cm right IBD was deployed using a buddy wire to facilitate appropriate orientation of the IBD. Whereas extreme tortuosity of the iliac vessels made deployment difficult, the 12F sheath from the left was advanced over the bifurcation through the iliac branch endoprosthesis (IBE) device, and a directional catheter was used to cannulate the internal iliac artery (Fig 3, C). Using a Rosen wire (Cook Medical) parked in the internal iliac artery, a 12-mm × 7-cm Gore internal iliac artery limb was deployed and ballooned into place. The external iliac limb of the IBD on the right was released and ballooned into place (Fig 3, D). This was followed by deployment of a 28- × 95-mm infrarenal aortic cuff just below the level of the lowest renal artery, which was marked with aortography. Completion angiography demonstrated excellent filling of the renal arteries, aortic endograft, both iliac limbs, and right internal and external iliac arteries as well as of the left external iliac artery. Although

there was filling of the false lumen of the visceral aorta, this did not extend to the repaired large iliac arteries. Intravascular ultrasound was employed again to ensure deployment of the grafts in the true lumen, showing expansion of the true lumen at the expense of the false lumen in the excluded distal abdominal aorta and obliteration of the false lumen in the left CIA (Fig 3, E). After removal of the 12F sheath from the left groin, the left CFA, superficial femoral artery, and profunda femoris artery were occluded, and an open septectomy was performed as the false lumen occupied the majority of the lumen of the CFA, converting the vessel into a common channel to maximize normal distal flow down the superficial femoral and profunda femoris arteries. The arteriotomy was closed primarily, and excellent flow was noted in the runoff vessels. The 17F sheath was removed from the right groin and closed with ProGlide Perclose sutures (Abbott Vascular, Abbot Park, Ill) that had been placed in preclose manner. The patient tolerated the procedure well and was kept in the intensive care unit overnight. His spinal drain was removed on postoperative day 1, and he was discharged on postoperative day 2 without any complications. He remains well on 30-day and 6-month follow-up, with no endoleak involving the bilateral CIA aneurysms by duplex ultrasound. At 6-month follow-up computed tomography (CT) angiography, continued perfusion of the right hypogastric artery and bilateral external iliac arteries and CFAs was demonstrated.

**Case 2.** A 55-year-old man with end-stage renal disease on hemodialysis was being observed for a known asymptomatic right CIA aneurysm that had increased in size on interval CT



**Fig 3.** **A** and **B**, Placement of 14.5- × 12-mm Gore iliac limb into left common and external iliac arteries. **C**, Cannulation of the right internal iliac artery over the aortic bifurcation through the iliac branch endograft device. **D**, Deployment of internal iliac artery limb. **E**, Completion angiogram showing expansion of the true lumen and obliteration of the false lumen in excluded distal abdominal aorta and left common iliac artery (CIA).



**Fig 4.** **A**, Iliac branch endograft being deployed in the right iliac limb of the AFX endograft deployed on the aortic bifurcation. **B**, Deployment of two Gore endoprostheses in overlapping fashion through right internal iliac artery. **C**, Completion angiogram with total exclusion of the right common iliac artery (CIA) aneurysm and preserved flow in the right internal iliac artery.

angiography from 3.1 to 3.5 cm. The right internal iliac artery had increased in size from 2.0 to 2.2 cm, so the decision was made for planned endovascular repair. As there was no proximal landing zone to perform an isolated CIA aneurysm repair, the planned repair was to use the AFX device to sit on the aortic bifurcation and to use the right limb of the aortobi-iliac device to land an IBD to exclude the right CIA aneurysm and to preserve flow in the right hypogastric artery.

The patient was taken to the operating room, and both CFAs were accessed percutaneously with a micropuncture needle upsized to a 6F sheath over a 0.035-inch wire. Two ProGlide sutures were placed in preclose fashion, followed by upsizing to an 11F sheath bilaterally. The patient was heparinized, and aortography was performed. As the patient was on dialysis and had a prior nephrectomy, position of the renal arteries was inconsequential. Positioning of the AFX2 device was performed as described in the previous case with full deployment in the infrarenal aorta, with limbs of the device extending into both CIAs. An 18F sheath was then placed in the right CFA and a 12F sheath into the left CFA. The IBE device was loaded onto the 18F sheath over a stiff wire on the right, and a Glidewire (Terumo Interventional Systems, Somerset, NJ) was snared from the left over the aortic bifurcation and brought out through the right (Fig 4, A). The IBE device was advanced

over a stiff wire until it was flush with the right limb of the AFX device. The sheath was withdrawn until the IBE device opened and the internal iliac limb was sitting just above the origin of the native internal iliac artery on the right. The 12F sheath was maneuvered over the aortic bifurcation into the right CIA. A Kumpe catheter (AngioDynamics, Latham, NY) was advanced over a buddy wire through the 12F sheath, and angiography was performed to identify the origin of the internal iliac artery. After the anatomy was delineated, the Glidewire was advanced into the internal iliac artery and exchanged for a Rosen wire. Angiography was performed to identify the distal landing zone of the internal iliac artery, and two 14.5-mm × 7-cm-long Gore endoprostheses were deployed in an overlapping fashion (Fig 4, B). The section of the iliac branch in the external iliac artery was then fully deployed, and balloon angioplasty of the junctions as well as of the landing zones proximally and distally and the overlap of the two endoprostheses within the internal iliac artery was performed. Completion angiography demonstrated an excellent result, with total exclusion of the right CIA aneurysm with flow preserved in both internal and external iliac arteries (Fig 4, C). All wires and sheaths were removed without complication. The patient had palpable dorsalis pedis and posterior tibial pulses at the conclusion of the case; he was monitored

overnight and discharged home on postoperative day 1. The patient remains well, with no evidence of endoleak on 6-month follow-up by duplex ultrasound. The patient has consistently refused to undergo CT angiography to evaluate the repair.

## DISCUSSION

Compared with open repair, endovascular repair of iliac artery aneurysms results in decreased length of stay, lower blood transfusion requirement, and similar intermediate-term outcomes.<sup>9</sup> More recently, IBDs to treat CIA aneurysms have been shown to have good long-term results as demonstrated by Parlani et al.<sup>10</sup> In their series, endovascular repair of a CIA aneurysm with an IBD had a patency of >90% and freedom from reintervention >80% after 5 years. This was associated with a <5% risk of endoleak or buttock claudication. In a separate study by Donas et al,<sup>11</sup> the investigators were able to demonstrate a <2% reintervention rate of 575 patients treated with IBDs for isolated iliac aneurysms or aortoiliac aneurysms involving the iliac bifurcation.

In both cases, there was no proximal landing zone for an adequate seal to prevent endoleak or to prevent encroachment of the IBD graft on the aortic bifurcation. Well-established criteria require at least 15 mm of proximal nonaneurysmal iliac artery to prevent a complication of endoleak and to ensure a durable repair.<sup>12,13</sup> The Endologix AFX graft device is a unibody design that preserves the native bifurcation of the aorta and allows an adequate proximal landing zone for iliac artery aneurysm endovascular repair. The iliac component of the AFX device is 40 mm in length and 20 mm in diameter, which provides ideal dimensions for obtaining a long seal zone between itself and the IBE device, which measures 23 mm in diameter. The long seal zone between the two grafts may provide a more stable repair in the long term, which may offset the increased cost of this technique in the short term; however, we recognize that longer follow-up is required to establish this hypothesis. The exoskeleton on the Gore device and the endoskeleton of the Endologix device are in apposition in this repair. This may be a matter of some concern, but we have not observed any adverse outcomes in intermediate-term follow-up.

A unibody aortic bifurcated stent graft has shown excellent results in the treatment of isolated abdominal aortic dissection in a recent publication.<sup>14</sup> The ability of this stent graft to exclude fenestrations in an aorta with a narrow proximal landing zone and aortic bifurcation to obtain a secure and stable repair has been demonstrated. This stent graft has the fabric on the outside, similar to the Endologix device. The uniform diameter of the main body and the support obtained from sitting on the aortic bifurcation may play a role in the success of this device in the clinical scenario described before. Whereas this technique may not be conventional, we think that in the

appropriately selected patient, the AFX device offers significant advantages in the treatment of iliac artery aneurysms. Aside from the increased stability and decreased incidence of type II endoleaks, the AFX device is the only graft that does not contain nitinol on the outside, and therefore there is no constant outward force leading to neck and sac expansion. Furthermore, the seal zone is increased as a result of the DuraPly abutting the wall of the aorta on average 5 mm beyond the seal zone.<sup>15</sup> In addition, the ease of secondary intervention is improved with the AFX device, allowing up-and-over intervention that is not possible with any other endograft. These were some of the reasons that went into our decision-making in formulating a treatment plan.

It was previously thought that preserving the hypogastric artery could be possible only for aneurysmal involvement of the proximal CIA with an adequate landing zone proximal to the origin of the hypogastric artery.<sup>16</sup> With the advent of IBE devices, there are more endovascular options for hypogastric salvage. We think that preservation of at least one hypogastric artery is important to reduce symptoms of buttock claudication, impotence, and paraplegia. This was especially true in case 1, in which preservation of the hypogastric artery was essential in a patient with previous TEVAR for maximum spinal cord perfusion. The benefits of hypogastric artery preservation using a side branch endograft vs hypogastric exclusion have been previously well described.<sup>17</sup>

## CONCLUSIONS

There are ongoing improvements in the endovascular repair of CIA aneurysms that have been made possible by improvements in technology and endovascular techniques. Preoperative imaging provides a roadmap for customization of endovascular grafts for safe exclusion of the aneurysmal sac with preservation of the hypogastric artery, which will only improve patients' outcomes and limit postoperative complications. We believe that pairing of the AFX endograft with the IBE device provides a stable repair by providing a long proximal neck that is rarely available in patients with large CIA aneurysms. We recommend this technique in such a patient.

## REFERENCES

1. Pitoulias GA, Donas KP, Schulte S, Horsch S, Papadimitriou DK. Isolated iliac artery aneurysms: endovascular versus open elective repair. *J Vasc Surg* 2007;46:648-54.
2. Malina M, Dirven M, Sonesson B, Resch T, Dias N, Ivancev K. Feasibility of a branched stent-graft in common iliac artery aneurysms. *J Endovasc Ther* 2006;13:496-500.
3. Uberoi R, Tsetis D, Shrivastava V, Morgan R, Belli AM. Standard of practice for the interventional management of isolated iliac artery aneurysms. *Cardiovasc Intervent Radiol* 2011;34:3-13.
4. Hobo R, Sybrandy JE, Harris PL, Buth J; EUROSTAR collaborators. Endovascular repair of abdominal aortic aneurysms with concomitant common iliac artery aneurysm: outcome



- analysis of the EUROSTAR experience. *J Endovasc Ther* 2008;15:12-22.
5. Bannazadeh M, Jenkins C, Forsyth A, Kramer J, Aggarwal A, Somerset AE, et al. Outcomes for concomitant common iliac artery aneurysms after endovascular abdominal aortic repair. *J Vasc Surg* 2017;66:1390-7.
  6. Ferreira M, Monteiro M, Lanzotti L. Technical aspects and midterm patency of iliac branched devices. *J Vasc Surg* 2010;51:545-50.
  7. Rasheed K, Cullen JP, Seaman MJ, Messing S, Ellis JL, Glocker RJ, et al. Aortic anatomic severity grade correlated with resource utilization. *J Vasc Surg* 2015;63:569-76.
  8. Best WB, Ahanchi SS, Larion S, Ammar CP, Lavingia KS, Panneton JM. Abdominal aortic aneurysm anatomic severity grading score predicts implant-related complications, systemic complications, and mortality. *J Vasc Surg* 2015;63:577-84.
  9. Chaer RA, Barbato JE, Lin SC, Zenati M, Kent KC, McKinsey JF. Isolated iliac artery aneurysms: a contemporary comparison of endovascular and open repair. *J Vasc Surg* 2008;47:708-13.
  10. Parlani G, Verzini F, Brambilla D, Coscarella C, Ferrer C, Cao P. Long-term results of iliac aneurysm repair with iliac branched endograft: a 5-year experience on 100 consecutive cases. *Eur J Vasc Endovasc Surg* 2012;43:287-92.
  11. Donas KP, Inchingolo M, Cao P, Pratesi C, Pratesi G, Torsello G, et al. Secondary procedures following iliac branch device treatment of aneurysms involving the iliac bifurcation: the pELVIS registry. *J Endovasc Ther* 2017;24:405-10.
  12. Wolf F, Loewe C, Cejna M, Schoder M, Rand T, Kettenbach J, et al. Endovascular management performed percutaneously of isolated iliac artery aneurysms. *Eur J Radiol* 2008;65:491-7.
  13. Stroumpouli E, Nassef A, Loosemore T, Thompson M, Morgan R, Belli M. The endovascular management of iliac artery aneurysms. *Cardiovasc Intervent Radiol* 2007;30:1099-104.
  14. Zhou M, Cai H, Li Z, Zhang Y, Liu Z, Tang H, et al. Contemporary results of endovascular repair of isolated abdominal aortic dissection with unibody bifurcated stent grafts. *Ann Vasc Surg* 2018;49:99-106.
  15. Welborn MB III, McDaniel HB, Johnson RC, Kennedy RE, Knott A, Mundingher GH, et al. Clinical outcome of an extended proximal seal zone with the AFX endovascular aortic aneurysm system. *J Vasc Surg* 2014;60:876-84.
  16. Mukherjee D, Bown M. Percutaneous common iliac artery aneurysm repair—a case report. *Int J Angiol* 2009;18:37-9.
  17. Verzini F, Parlani G, Romano L, De Rango P, Panuccio G, Cao P. Endovascular treatment of iliac aneurysm: concurrent comparison of side branch endograft versus hypogastric occlusion. *J Vasc Surg* 2009;49:1154-61.

Submitted Nov 6, 2017; accepted Jul 30, 2018.