

Original Article

Clinical features, microsurgical treatment, and outcome of vestibular schwannoma with brainstem compression

Ali Harati, Kai-Michael Scheufler, Rolf Schultheiss, Albaraa Tonkal¹, Kamran Harati², Paul Oni, Thomas Deitmer¹

Neurosurgical Department, ¹Department for Head and Neck Surgery, Klinikum Dortmund, ²Department of Plastic Surgery, Bergmannsheil Bochum, Ruhr-University, Bochum, Germany

E-mail: *Ali Harati - ali.harati@klinikumdo.de; Kai-Michael Scheufler - kai-michael.scheufler@klinikumdo.de; Rolf Schulthei - rolf.schultheiss@klinikumdo.de; Albaraa Tonkal - albaara.tonkal@klinikumdo.de; Kamran Harati - Kamran.harati@bergmannsheil.de; Paul Oni - paul.oni@klinikumdo.de; Thomas Deitmer - thomas.deitmer@klinikumdo.de

*Corresponding author

Received: 25 March 16 Accepted: 25 January 17 Published: 05 April 17

Abstract

Background: Presenting symptoms, treatment considerations, and outcome are strongly related to the extension of vestibular schwannomas (VS). The aim of the current retrospective study was to analyze the clinical features, microsurgical treatment, and outcome of VS with brainstem compression.

Methods: Forty-nine patients presented with VS (Hannover grading scale T4a or T4b) in our department. A subgroup analysis was performed among patients without (T4a) and with (T4b) compression and dislocation of the fourth ventricle.

Results: Patients with type T4b VS presented significantly more often with long tract signs/ataxia ($P < 0.05$), tonsillar herniation ($P < 0.001$), and preoperative hydrocephalus ($P < 0.01$). No significant difference was found between the groups regarding hearing loss and facial nerve, trigeminal nerve, and lower cranial nerve function. Gross total resection was achieved in 83% of the cases, near total resection was achieved in 15% of the cases, and subtotal resection was performed in 2% of the cases. One patient died after massive postoperative bleeding caused by a coagulopathy. At last follow-up, 69% of the patients had excellent facial nerve function (Grade I–II) and the remaining 31% a fair outcome. Six patients (12%) required permanent ventriculoperitoneal shunting. Hearing was preserved in two patients. Forty-six patients (94%) were independent without occasional assistance (Karnofsky scale 70–100%).

Conclusions: VS with brainstem compression is frequently associated with hydrocephalus, ataxia, long tract signs, multiple cranial nerve disorders, and occasionally, signs of intracranial hypertension. Primary microsurgical resection is an appropriate management option for large VS.

Access this article online

Website:

www.surgicalneurologyint.com

DOI:

10.4103/sni.sni_129_16

Quick Response Code:

This is an open access article distributed under the terms of the Creative Commons Attribution-NonCommercial-ShareAlike 3.0 License, which allows others to remix, tweak, and build upon the work non-commercially, as long as the author is credited and the new creations are licensed under the identical terms.

For reprints contact: reprints@medknow.com

How to cite this article: Harati A, Scheufler KM, Schultheiss R, Tonkal A, Harati K, Oni P, et al. Clinical features, microsurgical treatment, and outcome of vestibular schwannoma with brainstem compression. *Surg Neurol Int* 2017;8:45.

<http://surgicalneurologyint.com/Clinical-features,-microsurgical-treatment,-and-outcome-of-vestibular-schwannoma-with-brainstem-compression/>

Key Words: Cystic tumor, Hannover grading scale, hydrocephalus, microsurgery, vestibular schwannoma

INTRODUCTION

Vestibular schwannoma (VS), the most common tumor of the cerebellopontine angle (CPA), is a benign, slow-growing neoplasm. Presenting symptoms, treatment considerations, and outcome are strongly related to the size and extension of VS. Microsurgical treatment of large VS presents unique challenges. However, advances in microsurgical techniques, neuroanesthesia, and intensive care coupled with intraoperative neurophysiological monitoring, have led to remarkable improvements in clinical outcome.^[6] The goals of treatment include complete tumor resection with preservation of hearing and facial nerve function and avoidance of severe perioperative complications. The purpose of the present study is to analyze clinical features, microsurgical treatment, and outcomes of VS with brainstem compression (grade IVa/b, according to the Hannover grading scale) [Table 1].^[26] Subgroup analysis was performed regarding patients with (T4b) and without (T4a) radiological signs of fourth ventricle compression or shift [Figures 1-3].

PATIENTS AND METHODS

Patients

Three hundred and forty patients with VS were treated in our institution between January 2004 and November 2015. Of these patients, 49 (22 women, 27 men) displayed brainstem compression on magnetic resonance imaging (MRI) and were included in the study. The mean age at presentation was 53 years (range: 18–77 years). Patients' files and images were reviewed retrospectively. Follow-up data were collected

throughout follow-up. The last mean follow-up time was 56 months (range: 4–202 months).

Clinical evaluation

All patients underwent complete perioperative neurological evaluation. Functional outcomes at final follow-up were assessed by a phone survey using the Karnofsky performance scale. Facial nerve function was assessed before and after surgery and at each follow-up using the House–Brackmann scale and categorized as good (HB I–II), fair (HB III–IV), and poor (HB V and VI). Pure tone audiograms were performed prior to surgery to assess the option of hearing preservation, as well as postoperatively in patients with serviceable hearing. Dysphagia and vocal cord function were evaluated to assess lower cranial nerve involvement. Evaluation of trigeminal nerve included motor and sensory function. Motor examination, including strength of all extremities, coordination, and gait, were examined routinely to assess brainstem and cerebellar affection. In addition, level of consciousness, orientation, memory, and other signs of elevated intracranial pressure (ICP) were evaluated. In

Table 1: Hannover tumor extension grading scale for VS

Grade	
T1	Purely intracanalicular
T2	Intrameatal or extrameatal
T3a	Filling the cerebellopontine cistern
T3b	Reaching the brainstem
T4a	Compression of the brainstem
T4b	Compression of the brainstem with dislocation of the fourth ventricle

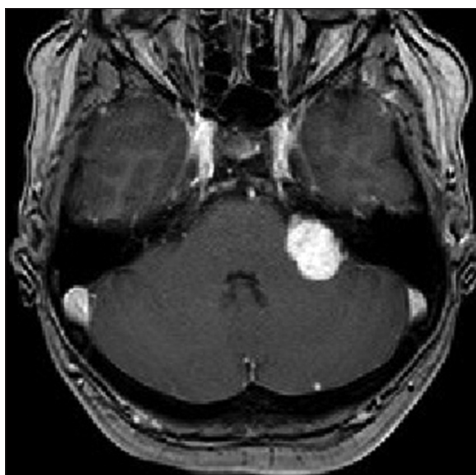


Figure 1: T1-enhanced MRI showing a vestibular schwannoma tumor extension grade 4a (maximal diameter 31 mm) in a 53-year-old man presenting with hearing loss and facial nerve palsy HB grade II

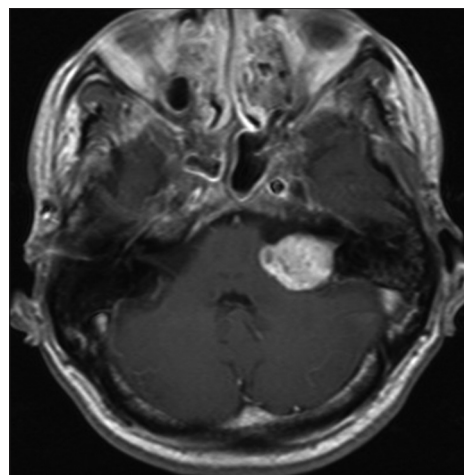


Figure 2: T1-enhanced MRI showing a vestibular schwannoma tumor extension grade 4a (maximal diameter 28 mm) in a 54-year-old man presenting with hearing loss and headache

selected cases (visual impairment, diplopia, nystagmus), ophthalmological examination was performed before and after surgery. Vestibular function was assessed by Frenzel glasses, testing of nystagmus during different manoeuvres, and video-nystagmography with caloric testing.

Radiologic evaluation

High-resolution bone window computed tomography (CT) studies, essential for visualizing the anatomy of the posterior semicircular canal and its vicinity to the posterior wall of the internal auditory canal and a high jugular bulb, were obtained before surgery. In addition, MRI was performed among all patients to assess tumor extension and maximal extrameatal diameter. The size of the tumor was determined based on linear planimetric measurements, and only the largest extrameatal diameter was used. T-2 weighted MR-imaging studies were used to assess hydrocephalus and tumor consistency (solid or cystic). Follow-up MRI was performed in all patients 3 months after the surgery to exclude residual tumor, and then every year to exclude recurrence. Residual contrast enhancement along facial nerve or brainstem with a diameter exceeding 5 mm were indicative of subtotal resection (STR), whereas residual contrast-enhanced tissue measuring less than 5 mm was assumed to represent near-total resection (NTR). However, in the latter case, differentiation between residual tumor and scar tissue remains difficult.

Statistical analysis

Data were analyzed using the Statistical Package for the Social Sciences (SPSS) version 19 (SPSS, Inc., Chicago, IL). Categorical variables were compared using Fisher's exact two-tailed test and Pearson's χ^2 test. Continuous variables were compared between groups with the Mann-Whitney *U* test.

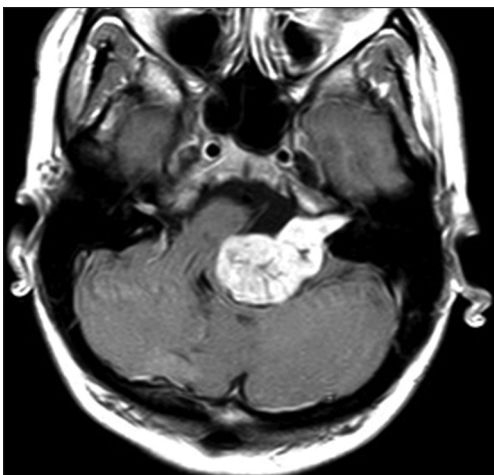


Figure 3: T1-enhanced MRI showing a vestibular schwannoma tumor extension grade 4b (maximal diameter 33 mm) in a 27-year-old woman presenting with hearing loss, facial nerve palsy HB grade III, gait ataxia and mild hemiparesis

RESULTS

Clinical and radiological presentation

Prior to surgery, severe hypacusis was demonstrated in 26 patients (53%) whereas complete hearing loss had occurred in 17 patients (35%). Only 6 patients (11%) had only moderate hearing impairment (pure tone audiogram <30 db). Interestingly, complete hearing loss had occurred in 6 patients more than 5 years before the initial diagnosis of VS was made. Thirteen patients (27%) had trigeminal nerve involvement, and 2 of these patients had symptoms resembling trigeminal neuralgia. Six patients (12%) had facial nerve dysfunction, including moderate palsy (HB Grade II-III) in 4 patients and hemifacial spasm in 2 individuals. Abducens nerve palsy was present in 2 patients (4%). Gait ataxia and long tract signs were observed in 22 patients (45%), and acute hemiparesis was observed in 2 patients (4%).

Signs of intracranial hypertension (severe headache, loss of orientation, nausea, vomiting, and/or papilledema) were present in 9 patients (18%). Mean tumor size was 30 mm (range: 18–55 mm). Radiological signs of hydrocephalus were observed in 16 patients (33%), whereas 10 patients (20%) had signs of tonsillar herniation. Both of these signs were closely associated with type T4b VS ($P > 0.01$). Cystic changes were more common in type 4b tumors than type 4a tumors, though the difference did not reach statistical significance [Table 2].

Operative procedure and postoperative course

Surgery was performed through a retrosigmoid craniotomy, with the patient positioned in the park bench position. Intraoperative monitoring of facial nerve function was used in all cases. We performed standard

Table 2: Patient characteristics at presentation

	Type 4a	Type 4b	P
Patients	22	27	
Sex			
Women	12 (54%)	10 (37%)	ns
Men	10 (46%)	17 (63%)	
Age (years)	56	51	ns
Clinical presentation			
Hypacusis	11 (50%)	14 (52%)	ns
Hearing loss	8 (36%)	10 (37%)	ns
Trigeminal nerve affection	4 (18%)	9 (33%)	ns
Facial nerve palsy	1 (5%)	5 (19%)	ns
Ataxia/long tract signs	6 (27%)	16 (59%)	<0.05
Radiological presentation			
Size (mm)	21	36	<0.001
Cystic tumor	4 (18%)	10 (37%)	ns
Tonsillar herniation	0	10 (37%)	<0.001
Hydrocephalus	3* (14%)	13** (48%)	<0.001

*Communicating hydrocephalus; **Occlusive hydrocephalus

monitoring techniques such as free-running facial nerve electromyography (EMG), direct electrical stimulation EMG, and in recent years, facial motor evoked potential (FMEP). In case of servicable hearing, we additionally performed intraoperative brainstem auditory evoked potential (BAEP) monitoring.

Mean operation time was 6.5 hours (range: 2.5–12 hours). Gross total resection was achieved in 41 patients (84%), near-total resection was achieved in 7 patients (14%), and subtotal resection was performed in 1 patient in whom the tumor had infiltrated the arachnoid of the brainstem; staged resection was performed in another patient. Eight patients required a perioperative ventricular drain due to acute occlusive hydrocephalus. Severe complications were observed in 3 patients (6%). Subarachnoid hemorrhage occurred in a 68-year-old woman. A ventricular drain was inserted and the patient went on to full recovery. In a 47-year-old man, a ventricular drain caused a right frontal lobe hematoma with cerebral herniation prompting immediate surgical revision. A 50-year-old woman died from severe postoperative posterior fossa hematoma caused by a severe platelet disorder, which was not diagnosed before surgery. Subsequently, a bleeding time test (Ivy method) was included in our routine preoperative workup. Twenty-seven patients (63%) displayed temporary worsening of facial nerve function after surgery. In 14 patients, a combined upper eye lid loading and lower lid canthopexy were performed to provide symptomatic relief from corneal exposure with a reasonable cosmetic appearance. At latest follow-up, no patient had poor facial nerve outcome (HB V–VI), 43 patients (69%) had favorable facial nerve function (HB I–II), and 19 patients (31%) had fair facial nerve function (HB III–IV) [Table 3]. Hearing preservation was achieved in 2 of the patients, with a pure tone average <50 dB. Preoperative trigeminal nerve dysfunction improved in all affected patients. Six out of the 16 patients who presented with hydrocephalus upon

admission required permanent ventriculoperitoneal CSF diversion. One patient experienced dysarthrophonia caused by lower cranial nerve impairment.

Long-term outcome

Patients were followed clinically for a mean of 54 months (range: 4–124 months). No patient was lost or died during follow-up. Tumor regrowth occurred in the patient who had undergone subtotal resection. He was referred to stereotactic radiation therapy. Overall recovery assessment based on the Karnofsky performance scale (KPS) during long-term follow-up yielded a KPS scores of 90% in 18 patients, 80% in 20 patients, and 70% in 7 patients [Table 3]. A 40-year-old woman had a 60% overall recovery based on KPS 120 months after surgery because of major depression, potentially associated with the underlying disease state. A 74-year-old man, who was referred to our hospital with initial hemiparesis, hydrocephalus and severe ataxia, had a 50% overall recovery and requires considerable assistance. The 47-year-old man who has developed intracerebral hematoma experienced ventilation-associated pneumonia and meningitis; four years after rehabilitation, he is still disabled and needs special care and assistance.

DISCUSSION

The management of large VS is challenging. Patients usually present with multiple cranial nerve deficits and signs of brainstem compression or intracranial hypertension. Our study indicates that even in VS with brainstem compression, complete tumor removal with favorable outcome is feasible.^[3,4,12,17,27,31,33-35,39,41,46,47,49,53]

Clinical considerations

VS is commonly classified according to the maximum extrameatal tumor diameter.^[21] However, the diameter as a singular parameter does not account for tumor-related mass effect against cerebellum and brainstem [Figures 1-3]. In general, there is a large degree of individual variability in osseous posterior fossa anatomy, size of the cerebellopontine cistern, and presence of cerebellar atrophy.^[37] In addition, the direction of tumor growth needs to be taken into account. The extension of the tumor in the CPA and the severity of brainstem and/or fourth ventricle compression may be more relevant than tumor diameter. Unlike the Koos grading system,^[22] the Hannover grading scale distinguishes between brainstem and fourth ventricle compression.

VS is diagnosed more frequently and in earlier stages nowadays due to increased utilization of cranial MRI for a variety of indications. However, in many countries, large and giant VS are still frequently encountered at initial diagnosis because of a less developed healthcare system or other reasons.^[19] In our case series, hearing loss occurred in 6 patients at least 5 years before cranial

Table 3: Functional long-term outcome

	Type 4a	Type 4b	P
Facial nerve function			ns
HB Grade I	6 (27%)	4 (15%)	
HB Grade II	8 (36%)	11 (41%)	
HB Grade III	7 (32%)	7 (26%)	
HB Grade IV	1 (5%)	4 (15%)	
HB Grade V & VI	0	0	
Shunt dependent hydrocephalus	0	6 (22%)	<0.01
Resection			
Gross-total resection	18 (82%)	22 (81%)	ns
Near-total resection	4 (18%)	4 (15%)	ns
Subtotal resection	0	1 (4%)	ns
Tumor recurrence	0	1 (4%)	ns

HB: House-Brackmann scale

imaging was performed. In a 13-year-old girl, hearing loss did not result in adequate imaging. She had suffered from headaches for many years and was treated conservatively. She was finally referred to our institution at the age of 29 with severe headaches, papilledema, and rapidly deteriorating consciousness. MRI revealed a giant VS [Figure 4a-d]. Despite increased symptom awareness among the general population along with a raised suspicion of VS among otorhinolaryngologists, inadequate screening and delayed referral remain a major problem even in developed countries. Hearing loss and tinnitus are the most frequent presenting symptoms in VS. However, patients with large or giant VS additionally suffer from other symptoms: The trigeminal nerve is affected in 40–80% of patients and the facial nerve is affected in 10–20% of patients.^[23,25,39,46,49] Further, impaired vestibular function and cerebellar and brainstem compression lead to gait instability and long tract signs in 30–50% of patients.^[25,39,49] Clinical symptoms of intracranial hypertension include papilledema and abducens nerve palsy. Communicating hydrocephalus is common in VS and is caused by the sloughing of protein from the tumor secondary to increased vascular endothelial permeability, the development of meningeal adhesions, arachnoiditis, or seeding of tumor cells.^[15,19,27,31] However, only 6% of our patients presented with communicating hydrocephalus, whereas obstructive hydrocephalus due to fourth ventricle compression was present in 26% of the patients. The incidence of cystic regression in VS varies between 11% and 50%. In accordance with other studies of large VS,

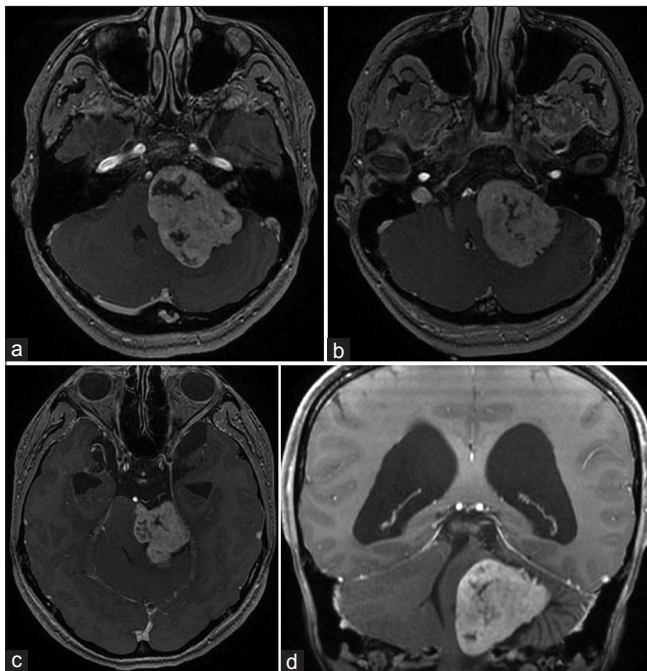


Figure 4: (a-d) T1-enhanced MRI demonstrating a 55 × 42 × 44 mm vestibular schwannoma and consecutive obstructive hydrocephalus in a 27-year-old woman presenting with headache, drowsiness, gait ataxia, and visual obscuration due to papilledema

the incidence of cystic changes in our patient cohort was 18% in type 4a and 37% in type 4b.^[13,20,42,46] Cystic VS are associated with shorter symptomatic periods before presentation and an unpredictable growth velocity. The presence of a cyst may be associated with rapid expansion of the lesion, brainstem compression, and hydrocephalus associated with neurologic symptoms.^[13,20,42,46]

Treatment

Treatment options for VS generally include observation, microsurgical resection, and radiosurgery. A wait-and-scan policy is generally not recommended for large VS with brainstem compression because of potentially life-threatening complications caused by further tumor growth. Radiosurgery does not induce immediate relief from tumor mass effect from large VS, and tumor volume may increase as a result of radiation-induced swelling.^[29] Van de Langenberg *et al.* treated 33 patients with large VS by radiosurgery. During a median follow-up of 30 months, 15% of the patients required additional microsurgical treatment. Indications for surgery included tumor swelling with consecutive shunt-dependent hydrocephalus, papilledema, ataxia, and worsening of facial nerve function.^[45] Therefore, in patients with large VS with brainstem compression and neurological deterioration, surgical removal with decompression of the brainstem and alleviation of the intracranial hypertension is the primary treatment of choice.^[14,39] The three main surgical routes for VS removal are the retrosigmoid, translabyrinthine, and middle fossa approaches.^[2,7] The middle fossa approach offers a very restricted access to the CPA, and is therefore inappropriate for large VS.^[8] The translabyrinthine and retrosigmoid approaches allow removal of VS of almost any size.^[7] Each approach has advantages and disadvantages. The benefits of the translabyrinthine approach are a short distance to the tumor and avoidance of cerebellar retraction with early identification of the facial nerve. The disadvantages of the translabyrinthine approach include inevitable hearing loss and, in cases of large VS, restricted access to the trigeminal nerve, caudal cranial nerves, and anterior aspect of the CPA.^[11,24] The transapical extension of the enlarged translabyrinthine approach allows enhanced surgical control of the tumor as well as the anterior aspect of the CPA, including the prepontine cistern and trigeminal nerves. However, the surgical access trajectory is oriented at 90° to the arachnoidal cleavage plane between tumor and brainstem.^[5] High tumor control rates and favorable outcomes via the translabyrinthine approach and its modifications have been published in the past.^[5,11,17,24,30,43,53] The retrosigmoid approach is the most popular approach among neurosurgeons.^[1,9,16,25,32,38-40,46,50,51] It is fast, straightforward, and offers excellent visualization of the CPA [Figure 5], trigeminal nerve, lower cranial nerves, and majority of the posterior fossa arteries including the upper part of the vertebral artery,

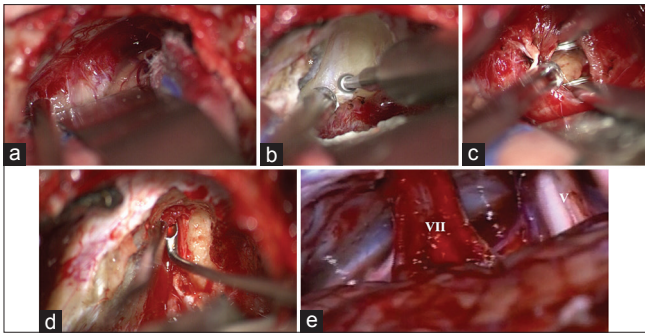


Figure 5: (a-d) Intraoperative image of a vestibular schwannoma (T4b) exposed through a retrosigmoid approach on the right side in park bench position. (a) Tumor exposure; (b) Drilling of internal acoustic canal in close relationship to the jugular bulb*; (c) Tumor debulking; (d) Removal of the intrameatal tumor; (e) The cerebellopontine angle after tumor removal

a high origin of the posterior inferior cerebellar artery, and distal parts the anterior inferior cerebellar artery and superior cerebellar artery.^[37] Some authors have pointed out that the visualization of the internal acoustic canal (IAC) may be limited in the retrosigmoid approach. After drilling the IAC, removal of the tumor in the lateral portion of the IAC might necessitate blind dissection, and therefore, increase the risk of incomplete tumor removal.^[24,36] Numerous studies have demonstrated that gross total resection through the retrosigmoid approach is possible in 84–97.6% of patients with large VS.^[39,49] One potential benefit of the retrosigmoid approach is hearing preservation. However, some authors argue that hearing preservation is extremely unlikely in large VS and should not influence the choice of surgical approach.^[36] In our series and prior studies, serviceable hearing was preserved in 9–56% of patients with large VS.^[2,10,12,17,39,47]

A major factor influencing postoperative quality of life is facial nerve dysfunction. Ansari *et al.* in their systematic review reported that the translabyrinthine approach was associated with inferior facial nerve function. However, their analysis might have been confounded by the inclusion of larger VS approached through the translabyrinthine route.^[2] In another systematic review including large VS, the retrosigmoid and translabyrinthine approaches provided similar rates of facial nerve functional outcomes.^[17] The extended translabyrinthine approach, which was reserved for larger VS, was associated with poor facial nerve outcome.^[17] Raslan *et al.* proposed staged resection of large VS, presenting a high rate of gross total resection (97.6%) with a low incidence of facial nerve palsy.^[36] However, staged resection is associated with high rates of CSF leakage and the patients carry the inherent risk associated with two procedures.^[33,36]

Because a randomized trial comparing the different operative approaches is not feasible, there is no general recommendation regarding the surgical approach for VS. It is generally accepted that surgeon's preference

and experience may be the key determinant of the surgical approach. Because VS grows slowly, the facial nerve becomes stretched out flat along the tumor surface in large VS. The arachnoid dissection plane becomes obscured, and microsurgical dissection therefore becomes very challenging. Following tumor resection, a collagen sponge coated with fibrinogen was used to stabilize the thinned facial nerve in its course through the CPA in most patients of our series. Microsurgical skills and experience of the surgeon influence postoperative facial nerve function.^[10,48]

Another major factor influencing facial nerve function is the tumor size. The risk of facial nerve palsy may increase by up to six-fold in large VS.^[48] In our series, poorer facial nerve function resulted in patients with type 4b VS (compared with type 4a), although the difference did not reach statistical significance. Tumor consistency might be another factor influencing outcome. Preoperative assessment of tumor consistency by dedicated MRI studies is subject to future investigation and may influence surgical strategy.

The implementation of intraoperative neuromonitoring during resection of VS is associated with improvements in functional preservation of the cranial nerves. Among these methods, the most frequently used are direct electrical stimulation EMG, free-running EMG, and FMEP for the facial nerve and BAEP together with cochlear nerve action potentials (CNAP) for the vestibulocochlear nerve.^[50,52] The facial nerve demonstrates high rates of functional preservation with the use of EMG. One of its main functions is determining the intraoperative anatomical location of the facial nerve by direct electrical stimulation during tumor dissection. In addition, free running EMG prevents unplanned damage of the facial nerve by emitting acoustic signals whenever muscle stimulation is detected.^[52] Especially, in large VS, EMG directly influences surgical planning and strategy. FMEP can be a valuable adjunct to conventional facial nerve EMG during surgery for VS. It may be especially useful when the facial nerve course is obscured by tumor or inaccessible to direct electric stimulation.^[52] The use of BAEPs in case of attempted hearing preservation is also a standard tool but has several limitations. Because the stimulus response must be summed and averaged to obtain a wave of sufficiently high amplitude, this process is associated with a significant time delay. Naturally, such a delay can negatively influence the course of surgery.^[50,52]

Some authors advocate subtotal resection to reduce the risk of hearing loss and facial nerve dysfunction. In our series, subtotal resection was performed in one patient only, who later displayed tumor recurrence. Incomplete resection is associated with high recurrence rates (up to 39%).^[18,31] In a retrospective study, Carlson *et al.* found that tumor recurrence was nine times more likely after subtotal resection than after near total and gross

total resection.^[6] Another treatment option is subtotal resection followed by radiosurgery, to reduce the growth of the remnant tumor.^[44] Although any effort to preserve hearing and facial nerve function is commendable, the long-term risk of tumor recurrence – especially in younger patients – is unclear. The rate of radiation control of growing remnants is questionable.^[25] In addition, microsurgery after radiosurgery in case of tumor regrowth becomes even more challenging and is associated with higher complication rates.^[14]

CONCLUSIONS

We demonstrate the distinct clinical findings of VS with brainstem compression, noting that these tumors are frequently associated with hydrocephalus, ataxia, long tract signs, multiple cranial nerve disorders, and in some cases with signs of intracranial hypertension. Primary microsurgical resection (gross total or near total) appears to be the first-line management option of choice for large VS.

Financial support and sponsorship

Nil.

Conflicts of interest

There are no conflicts of interest.

REFERENCES

- Anaizi AN, Gantwerker EA, Pensak ML, Theodosopoulos PV. Facial nerve preservation surgery for koos grade 3 and 4 vestibular schwannomas. *Neurosurgery* 2014;75:671-5.
- Ansari SF, Terry C, Cohen-Gadol AA. Surgery for vestibular schwannomas: A systematic review of complications by approach. *Neurosurg Focus* 2012;33:E14.
- Bambakidis NC, Lo SS, Selman WR. Large vestibular schwannomas. *J Neurosurg* 2011;115:894-5.
- Bandlish D, Biswas N, Deb S. Staging in giant vestibular schwannoma surgery: A two consecutive day technique for complete resection in basic neurosurgical setups. *J Neurosci Rural Pract* 2014;5:225-30.
- Ben Ammar M, Piccirillo E, Topsakal V, Taibah A, Sanna M. Surgical results and technical refinements in translabyrinthine excision of vestibular schwannomas: The Gruppo Otologico experience. *Neurosurgery* 2012;70:1481-91.
- Carlson ML, Van Abel KM, Driscoll CL, Neff BA, Beatty CW, Lane JL, et al. Magnetic resonance imaging surveillance following vestibular schwannoma resection. *Laryngoscope* 2012;122:378-88.
- Chamoun R, MacDonald J, Shelton C, Couldwell WT. Surgical approaches for resection of vestibular schwannomas: Translabyrinthine, retrosigmoid, and middle fossa approaches. *Neurosurg Focus* 2012;33:E9.
- Chopra R, Fergie N, Mehta D, Liew L. The middle cranial fossa approach: An anatomical study. *Surg Radiol Anat* 2003;24:348-51.
- Ciric I, Zhao J-C, Rosenblatt S, Wiet R, O'Shaughnessy B. Suboccipital retrosigmoid approach for removal of vestibular schwannomas: Facial nerve function and hearing preservation. *Neurosurgery* 2005; 56:560-70.
- Cole T, Veeravagu A, Zhang M, Azad T, Swinney C, Li GH, et al. Retrosigmoid Versus Translabyrinthine Approach for Acoustic Neuroma Resection: An Assessment of Complications and Payments in a Longitudinal Administrative Database. *Cureus* 2015;7:e369.
- Day JD, Chen DA, Arriaga M. Translabyrinthine approach for acoustic neuroma. *Neurosurgery* 2004;54:391-5.
- Di Maio S, Malebranche AD, Westerberg B, Akagami R. Hearing preservation after microsurgical resection of large vestibular schwannomas. *Neurosurgery* 2011;68:632-40.
- Fundová P, Charabi S, Tos M, Thomsen J. Cystic vestibular schwannoma: Surgical outcome. *J Laryngol Otol* 2000;114:935-9.
- Gerganov VM, Giordano M, Samii A, Samii M. Surgical treatment of patients with vestibular schwannomas after failed previous radiosurgery. *J Neurosurg* 2012;116:713-20.
- Gerganov VM, Pirayesh A, Nouri M, Hore N, Luedemann WO, Oi S, et al. Hydrocephalus associated with vestibular schwannomas: Management options and factors predicting the outcome. *J Neurosurg* 2011;114:1209-15.
- Gharabaghi A, Samii A, Koerber A, Rosahl SK, Tatagiba M, Samii M. Preservation of function in vestibular schwannoma surgery. *Neurosurgery* 2007;60:ONS124-7.
- Gurgel RK, Dogru S, Amdur RL, Monfared A. Facial nerve outcomes after surgery for large vestibular schwannomas: Do surgical approach and extent of resection matter? *Neurosurg Focus* 2012;33:E16.
- Iwai Y, Ishibashi K, Watanabe Y, Uemura G, Yamanaka K. Functional Preservation After Planned Partial Resection Followed by Gamma Knife Radiosurgery for Large Vestibular Schwannomas. *World Neurosurg* 2015;84:292-300.
- Jain VK, Mehrotra N, Sahu RN, Behari S, Banerji D, Chhabra DK. Surgery of vestibular schwannomas: An institutional experience. *Neurol India* 2005;53:41-5.
- Jian BJ, Sughrue ME, Kaur R, Rutkowski MJ, Kane AJ, Kaur G, et al. Implications of cystic features in vestibular schwannomas of patients undergoing microsurgical resection. *Neurosurgery* 2011;68:874-80.
- Kanzaki J, Tos M, Sanna M, Moffat DA, Monsell EM, Berliner KI. New and modified reporting systems from the consensus meeting on systems for reporting results in vestibular schwannoma. *Otol Neurotol* 2003;24:642-8.
- Koos WT, Day JD, Matula C, Levy DI. Neurotopographic considerations in the microsurgical treatment of small acoustic neuromas. *J Neurosurg* 1998;88:506-12.
- Lanman TH, Brackmann DE, Hitselberger WE, Subin B. Report of 190 consecutive cases of large acoustic tumors (vestibular schwannoma) removed via the translabyrinthine approach. *J Neurosurg* 1999;90:617-23.
- Mamikoglu B, Wiet RJ, Esquivel CR. Translabyrinthine approach for the management of large and giant vestibular schwannomas. *Otol Neurotol* 2002;23:224-7.
- Matthies C, Samii M. Management of 1000 vestibular schwannomas (acoustic neuromas): Clinical presentation. *Neurosurgery* 1997;40:1-9.
- Matthies C, Samii M, Krebs S. Management of vestibular schwannomas (acoustic neuromas): Radiological features in 202 cases—their value for diagnosis and their predictive importance. *Neurosurgery* 1997;40:469-81.
- Mehrotra N, Behari S, Pal L, Banerji D, Sahu RN, Jain VK. Giant vestibular schwannomas: Focusing on the differences between the solid and the cystic variants. *Br J Neurosurg* 2008;22:550-6.
- Monfared A, Corrales E, Theodosopoulos P, Blevins NH, Oghalai JS, Selesnick SH, et al. Facial Nerve Outcome and Tumor Control Rate as a Function of Degree of Resection in Treatment of Large Acoustic Neuromas: Preliminary Report of the Acoustic Neuroma Subtotal Resection Study. *Neurosurgery* 2016;79:194-203.
- Nagano O, Higuchi Y, Serizawa T, Ono J, Matsuda S, Yamakami I, et al. Transient expansion of vestibular schwannoma following stereotactic radiosurgery. *J Neurosurg* 2008;109:811-6.
- Nickele CM, Akture E, Gubbels SP, Başkaya MK. A stepwise illustration of the translabyrinthine approach to a large cystic vestibular schwannoma. *Neurosurg Focus* 2012;33:E11.
- Pai I, Bowman J, Thomas N, Kitchen N, Strong A, Obholzer R, et al. Management of large and giant vestibular schwannomas. *Skull Base* 2011;21:379-84.
- Park CE, Park BJ, Lim YJ, Yeo SG. Functional outcomes in retrosigmoid approach microsurgery and gamma knife stereotactic radiosurgery in vestibular schwannoma. *Eur Arch Otorhinolaryngol* 2011;268:955-9.
- Patni AH, Kartush JM. Staged resection of large acoustic neuromas. *Otolaryngol Head Neck Surg* 2005;132:11-9.
- Raftopoulos C, Abu Serieh B, Duprez T, Docquier MA, Guérit JM. Microsurgical results with large vestibular schwannomas with preservation of facial and cochlear nerve function as the primary aim. *Acta Neurochir* 2005;147:697-706.
- Ramina R, Coelho Neto M, Bordignon KC, Mattei T, Clemente R,

- Pires Aguiar PH. Treatment of large and giant residual and recurrent vestibular schwannomas. *Skull Base* 2007;17:109-17.
36. Raslan AM, Liu JK, McMenomey SO, Delashaw JB. Staged resection of large vestibular schwannomas. *J Neurosurg* 2012;116:1126-33.
 37. Rhoton AL. The cerebellopontine angle and posterior fossa cranial nerves by the retrosigmoid approach. *Neurosurgery* 2000;47:S93-129.
 38. Samii M, Matthies C. Hearing preservation in acoustic tumour surgery. *Adv Tech Stand Neurosurg* 1995;22:343-73.
 39. Samii M, Gerganov VM, Samii A. Functional outcome after complete surgical removal of giant vestibular schwannomas. *J Neurosurg* 2010;112:860-7.
 40. Samii M, Gerganov V, Samii A. Improved preservation of hearing and facial nerve function in vestibular schwannoma surgery via the retrosigmoid approach in a series of 200 patients. *J Neurosurg* 2006;105:527-35.
 41. Silva J, Cerejo A, Duarte F, Silveira F, Vaz R. Surgical removal of giant acoustic neuromas. *World Neurosurg* 2012;77:731-5.
 42. Sinha S, Sharma BS. Cystic acoustic neuromas: Surgical outcome in a series of 58 patients. *J Clin Neurosci* 2008;15:511-5.
 43. Springborg JB, Fugleholm K, Poulsgaard L, Cayé-Thomasen P, Thomsen J, Stangerup S-E. Outcome after translabyrinthine surgery for vestibular schwannomas: Report on 1244 patients. *J Neurol Surg B Skull Base* 2012;73:168-74.
 44. van de Langenberg R, Hanssens PEJ, van Overbeeke JJ, Verheul JB, Nelemans PJ, de Bondt B-J, et al. Management of large vestibular schwannoma. Part I. Planned subtotal resection followed by Gamma Knife surgery: Radiological and clinical aspects. *J Neurosurg* 2011;115:875-84.
 45. van de Langenberg R, Hanssens PEJ, Verheul JB, van Overbeeke JJ, Nelemans PJ, Dohmen AJC, et al. Management of large vestibular schwannoma. Part II. Primary Gamma Knife surgery: Radiological and clinical aspects. *J Neurosurg* 2011;115:885-93.
 46. Wang M, Jia D, Shen J, Zhang J, Li G. Facial nerve function after large cystic vestibular schwannomas surgery via the retrosigmoid approach. *Turk Neurosurg* 2013;23:161-9.
 47. Wanibuchi M, Fukushima T, McElveen JT, Friedman AH. Hearing preservation in surgery for large vestibular schwannomas. *J Neurosurg* 2009;111:845-54.
 48. Wiet RJ, Mamikoglu B, Odum L, Hoistad DL. Long-term results of the first 500 cases of acoustic neuroma surgery. *Otolaryngol Head Neck Surg* 2001;124:645-51.
 49. Yamakami I, Uchino Y, Kobayashi E, Yamaura A, Oka N. Removal of large acoustic neurinomas (vestibular schwannomas) by the retrosigmoid approach with no mortality and minimal morbidity. *J Neurol Neurosurg Psychiatr* 2004;75:453-8.
 50. Yamakami I, Ito S, Higuchi Y. Retrosigmoid removal of small acoustic neuroma: Curative tumor removal with preservation of function. *J Neurosurg* 2014;121:554-63.
 51. Yang J, Grayeli AB, Barylyak R, Elgarem H. Functional outcome of retrosigmoid approach in vestibular schwannoma surgery. *Acta Otolaryngol* 2008;128:881-6.
 52. Youssef AS, Downes AE. Intraoperative neurophysiological monitoring in vestibular schwannoma surgery: Advances and clinical implications. *Neurosurg Focus* 2009;27:3-6.
 53. Zhang Z, Wang Z, Huang Q, Yang J, Wu H. Removal of large or giant sporadic vestibular schwannomas via translabyrinthine approach: A report of 115 cases. *J Otorhinolaryngol Relat Spec* 2012;74:271-7.