



Is simple decompression enough for the treatment of idiopathic cubital tunnel syndrome: A prospective comparative study analyzing the outcomes of simple decompression versus partial medial epicondylectomy

Orçun Şahin, MD¹, Bahtiyar Haberal, MD¹, Mehmet Şükrü Şahin, MD², Hüseyin Demirörs, MD¹, İlhami Kuru, MD¹, İsmail Cengiz Tuncay, MD¹

¹Department of Orthopedics and Traumatology, Medicine Faculty of Başkent University, Ankara, Turkey

²Department of Orthopedic Surgery, Başkent University Alanya Application and Research Center, Alanya, Turkey

Cubital tunnel syndrome (CuTS) is the second most commonly seen entrapment neuropathy of the upper limb in adults.^[1] Many surgical procedures have been described in the literature, including simple decompression,^[2] submuscular,^[3] intramuscular,^[4] or subcutaneous;^[5] ulnar nerve transposition; medial epicondylectomy;^[6,7] and endoscopic *in-situ* cubital tunnel release.^[8-10]

Although there are a number of different studies in the literature comparing different kinds of surgical techniques for the treatment of idiopathic CuTS, the best surgical technique for ulnar nerve decompression has not yet been established. Simple decompression of the ulnar nerve at its entrance to the cubital

Received: February 20, 2020

Accepted: June 25, 2020

Published online: September 11, 2020

Correspondence: Orçun Şahin, MD, Başkent Üniversitesi Tıp Fakültesi Ortopedi ve Travmatoloji Anabilim Dalı, 06490 Bahçelievler, Ankara, Türkiye.

E-mail: drorcunsahin@gmail.com

Doi: 10.5606/ehc.2020.74400

Citation: Şahin O, Haberal B, Şahin MŞ, Demirörs H, Kuru İ, Tuncay İC. Is simple decompression enough for the treatment of idiopathic cubital tunnel syndrome: A prospective comparative study analyzing the outcomes of simple decompression versus partial medial epicondylectomy. Jt Dis Relat Surg 2020;31(3):523-531.

©2020 All right reserved by the Turkish Joint Diseases Foundation

This is an open access article under the terms of the Creative Commons Attribution-NonCommercial License, which permits use, distribution and reproduction in any medium, provided the original work is properly cited and is not used for commercial purposes (<http://creativecommons.org/licenses/by-nc/4.0/>).

ABSTRACT

Objectives: This study aims to compare the clinical and functional outcomes of simple *in-situ* decompression and partial medial epicondylectomy for the treatment of idiopathic cubital tunnel syndrome (CuTS).

Patients and methods: Between March 2014 and December 2016, 71 patients (31 males, 40 females; mean age 46.7 years; range, 38 to 62 years) with CuTS scheduled to undergo simple *in-situ* decompression (group 1) or partial medial epicondylectomy (group 2) were prospectively reviewed. All patients were analyzed with clinical examination (Tinel sign, Froment's and Wartenberg's signs, elbow flexion test, subluxation), and McGowan scores before and after surgery. Final outcomes were reviewed with Wilson and Krout grading system.

Results: There was no significant difference between the study groups in regard to Wilson and Krout grading and McGowan scores postoperatively. Group 1 had significantly better grip and key pinch strength values compared to group 2 at the final follow-up control.

Conclusion: *In-situ* decompression and partial medial epicondylectomy represent efficient and safe methods for the treatment of idiopathic CuTS. When their efficiency is compared, *in-situ* decompression had better grip and key pinch strength values and more excellent outcomes compared to partial medial epicondylectomy.

Keywords: Cubital tunnel syndrome, *in-situ* decompression, medial epicondylectomy.

tunnel was first reported in the 1950s by Osborne,^[11] Feindel, and Stratford.^[12] Since then, it is widely used in clinical practice with a high success rate. Partial medial epicondylectomy with *in-situ* decompression was first described by Kaempffe and Farbach in 1998.^[13] Various studies have been published in the literature analyzing the outcomes of these techniques.

Nevertheless, the data comparing partial medial epicondylectomy with simple decompression are scarce and inconclusive. Therefore, whether to perform just simple decompression or partial epicondylectomy with *in-situ* decompression is still a controversial issue with no clear-cut indications. In order to solve this issue, more studies are needed comparing the outcomes of these two techniques. To our knowledge, this is one of the first studies in the English literature comparing simple *in-situ* decompression with partial medial epicondylectomy. Hence, in this study, we aimed to compare the clinical and functional outcomes of simple *in-situ* decompression and partial medial epicondylectomy for the treatment of idiopathic CuTS.

PATIENTS AND METHODS

Between March 2014 and December 2016, all patients with CuTS scheduled to undergo simple *in-situ* decompression or partial medial epicondylectomy were prospectively reviewed at Medicine Faculty of Baškent University. The study protocol was approved by the Baškent University Institutional Review Board and Ethics Committee (project no: KA20/106). A written informed consent was obtained from each patient. The study was conducted in accordance with the principles of the Declaration of Helsinki.

Diagnosis of CuTS was established based on clinical findings, with subsequent confirmation using electrophysiological tests.^[14] Clinical findings included sensory disturbance in the ulnar nerve sensory zone and motor dysfunction induced by intrinsic muscle atrophy. Operative treatment was performed for patients who still had significant symptoms of tingling, pain, or weakness after at least two months of conservative treatment including two times of steroid injections (40 mg methylprednisolone acetate [Depo-Medrol; Pfizer, New York, USA] and 10 mg lidocaine hydrochloride). Before the injection, medial epicondyle and the course of the ulnar nerve were marked with a surgical marker and all steroid injections were performed with the elbow in 90 degrees of flexion and under local anesthesia by using topical vapocoolant spray, just posterior to the medial epicondyle with a no-touch technique.

As inclusion criteria, only “idiopathic CuTS” cases who had either simple *in-situ* decompression or partial medial epicondylectomy surgeries were recruited for the study group. All syndromic CuTS cases (tumors, ganglion cysts, repetitive use, anatomical variations, and diseases of the neighboring blood vessels etc.) were excluded in the study group in order to prevent any bias and achieve a homogeneous study population. A total of 86 patients were enrolled for the study.

Exclusion criteria were previous decompression of the ulnar nerve (n=1), other entrapment neuropathies such as cervical radiculopathy, or carpal tunnel syndrome (n=4), osseous canal deformity from previous trauma or osteophytes of the elbow joint (n=1), valgus instability of elbow (n=1), thoracic outlet syndrome, and a follow-up period of less than 24 months (n=8). Finally, a total of 71 patients (31 males, 40 females; mean age 46.7 years; range, 38 to 62 years) were found eligible for the study and two study groups were created according to the surgeries performed as group 1 (simple *in-situ* decompression group, n=38) and group 2 (partial medial epicondylectomy group, n=33).

All surgical procedures were performed in supine position and under general anesthesia by three surgeons experienced in upper extremity surgeries. The type of the surgical procedure (either *in-situ* decompression or partial medial epicondylectomy) was determined according to personal preference of the surgeon with a shared opinion of the patient. The indication for simple *in-situ* decompression was established according to the pre-/intraoperative ulnar nerve subluxation or instability. If no subluxation or instability was determined during elbow flexion, only *in-situ* decompression was performed. On the contrary, all partial medial epicondylectomy surgeries were performed for patients who demonstrated ulnar nerve subluxation pre- or intraoperatively about the medial epicondyle with elbow flexion, following *in-situ* decompression.

All simple ulnar nerve decompression operations were performed as described by Huang et al.^[15] In short, after a sterile tourniquet application, 6 to 8 cm medial incision was performed in-line with the posterior condylar groove. The ulnar nerve was identified and followed distally to the musculus flexor carpi ulnaris. It was decompressed in the cubital tunnel, without mobilization, up to the medial intermuscular septum in proximal direction and up to the two heads of the flexor carpi ulnaris distally.

Each patient had an *in-situ* ulnar nerve release with partial medial epicondylectomy as described by Heithoff et al.,^[16] with preservation of the medial collateral ligament. After the ulnar nerve decompression procedure, the medial epicondyle was exposed with subperiosteal dissection. After adequate exposure, the medial epicondyle was partially removed approximately 7 mm from its tip using a 3/8-inch osteotome, avoiding disturbing the anterior medial collateral ligament (Figure 1). The amount of resection should be sufficient to allow a spontaneous

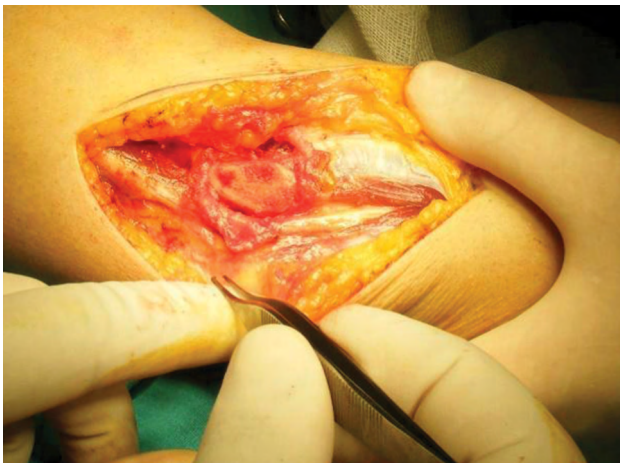

FIGURE 1. Partial medial epicondylectomy.

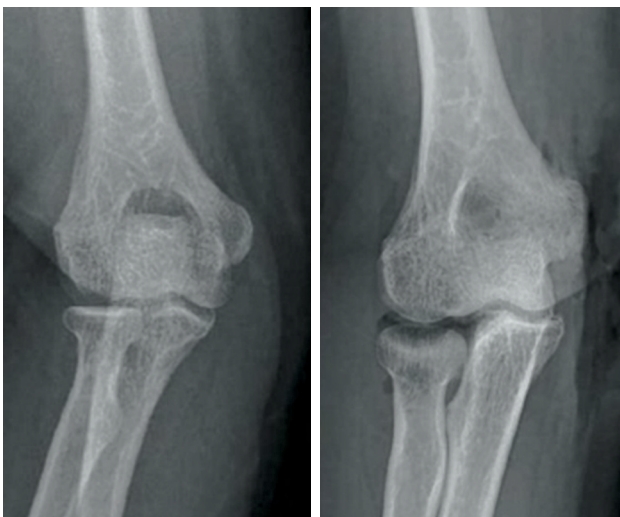


FIGURE 2. Pre- and postoperative anteroposterior radiographs of a patient who had partial medial epicondylectomy.

anterior translation of the ulnar nerve at flexion, but not excessively so, in order to avoid damage to the medial collateral ligament (Figure 2).

Postoperatively, a soft bandage was applied for two days, followed by encouraged motion as tolerated by the patient with the basic home exercises for the operated upper extremity. No support was obtained from the physical treatment department in the follow-up period.

Postoperatively, follow-up visits were performed at two weeks, six weeks, six months, and annually, thereafter. All patients were followed-up for at least 24 months.

All clinical assessments were performed by one investigator blinded to the surgical procedure. Data

including the duration of symptoms, the occupation of the patients, Tinel sign over the course of the ulnar nerve in the postcondylar groove, Froment's and Wartenberg's signs, elbow flexion test, and palpation for any subluxation of the nerve were recorded pre- and postoperatively. Grip strength and key pinch strength were also evaluated (Jamar dynamometer; Preston, Jackson, MI, USA) by the same investigator preoperatively and at the final follow-up visit.

Two independent investigators evaluated the patients' functional status pre- and postoperatively by the use of the modified McGowan grading system (Table I).^[17] The postoperative state of the patients was classified by using the modified Wilson and Krout grading system, in which excellent means minimal motor and sensory changes and no tenderness at the incision site, good means occasional ache and mild sensory or motor changes, fair means improved but persistent sensory or motor changes, and poor means no improvement or a worsened condition. Patient satisfaction was also evaluated with the status of the patients' return to former job/daily activities.

Statistical analysis

Statistical comparisons between the study groups on demographic factors including age, sex and duration of symptoms, the preoperative status, and outcome parameters were performed by using the Student's t-test or the Pearson's chi-square test. All calculations were performed using the SPSS for Windows version 14.0 software (SPSS Inc., Chicago, IL, USA). P values less than 0.05 were considered statistically significant.

RESULTS

The average follow-up period for the study group was 27.3 (range, 24 to 36) months. The occupational survey of the study population revealed that there were 31 housewives (43.6%), 16 government officials (22.5%), 14 retired employees (19.7%), seven teachers (9.8%), and three unemployed persons (4.2%). The most common preoperative symptom of the study

TABLE I

McGowan classification as modified by Goldberg^[17]

Stage 1	Purely subjective symptoms
Stage 2	Muscle weakness and/or objective sensory signs 2A: No atrophy of intrinsic muscles 2B: Some atrophy of intrinsic muscles
Stage 3	Significant sensory and motor deficits with noticeable atrophy of intrinsic muscles

TABLE II					
Demographic features of each study group and statistical comparison results					
Demographic features	Group 1		Group 2		<i>p</i>
	n	Mean	n	Mean	
Age (year)		44.7		47.3	0.312
Sex					
Male	17		14		0.911
Female	22		18		0.567
Follow-up (month)		26.5		27.9	0.219
Side					
Left	12		14		0.438
Right	21		24		0.067
Duration of symptoms (month)		13.2		13.9	0.145

group was paresthetic pain (n=58, 81.7%). All patients had idiopathic CuTS approved by electromyography (EMG) studies. The average duration of symptoms of the study population was 13.7 (range, 8 to 17) months. Right and left elbows were operated in 45 and 26 patients (63.3% and 36.7%, respectively). Among the patients, 49 (69%) had surgery for the dominant extremity (28 in group 1 and 21 in group 2). There were no bilateral cases. The demographic features of each study group including the duration of symptoms and statistical comparison results were summarized in Table II.

There were two patients in group 2 with prolonged wound drainage postoperatively which was treated with daily wound dressing changes. No patients needed a second surgery for any complications. The Tinel sign was present in 67 patients. The elbow flexion test was positive in 59 patients, whereas 18 patients had a Froment's sign and nine had a Wartenberg's sign. Local tenderness was present around the cubital tunnel region in 70 patients, and four patients had palpable subluxation of the ulnar nerve. The preoperative clinical data for each study group including Tinel's sign over the course of the

ulnar nerve in the postcondylar groove, Froment and Wartenberg's signs, elbow flexion test, and palpation for any subluxation were summarized in Table III. There was no statistically significant difference between the study groups in regard to clinical findings preoperatively (Table III). The postoperative clinical status of patients in each group at the final control is shown in Table IV. Although there was no statistically significant difference between the postoperative clinical findings of the study groups (Table IV), there was a statistically significant difference between all the pre- and postoperative clinical findings ($p < 0.005$ for all parameters).

The average grip strength and key pinch strength values for the study groups pre- and postoperatively and the statistical comparison results were summarized in Table V. Group 1 had significantly better grip and key pinch strength values compared to group 2 at the final follow-up control ($p < 0.005$). This significant difference in strength values between the study groups mostly resulted from the muscle repair after epicondylectomy in group 2 which may have led to weakness of the hand grip and key pinch strengths of the operated arm.

TABLE III				
Preoperative clinical findings for study groups and statistical comparison results				
Preoperative clinical findings	Group 1	Group 2	Total	<i>p</i>
	n	n	n	
Tinel's sign	36	31	67	0.367
Elbow flexion test	29	30	59	0.712
Froment's sign	10	8	18	0.143
Wartenberg's sign	4	5	9	0.067
Nerve subluxation	2	2	4	0

TABLE IV				
Postoperative clinical findings for study groups and statistical comparison results				
Preoperative clinical findings	Group 1	Group 2	Total	p
	n	n	n	
Tinel's sign	1	2	3	0.831
Elbow flexion test	0	1	1	0.072
Froment's sign	0	0	0	0
Wartenberg's sign	1	0	1	0.08
Nerve subluxation	0	0	0	0

TABLE V					
Average grip strength and key pinch strength values for study groups pre- and postoperatively and statistical comparison results					
	Group 1		Group 2		P values between the study groups
	Preoperative	Postoperative	Preoperative	Postoperative	p
	%	%	%	%	
Grip strength*	71	89	69	75	<0.005
Key pinch strength*	74	90	72	80	<0.005
P values within the study groups	p<0.005		p<0.005		

* All mechanical tests were compared with the contralateral side of the patient.

Among the 71 patients, there was only one patient with a preoperative McGowan score of stage 1, 42 patients of stage 2A, 20 patients of stage 2B, and eight patients of stage 3. Postoperatively, a total of 68 patients (95.8%) had improved McGowan scores. Among the three patients who had no improvement, one had stage 2B and two had stage 3 CuTS. All these patients without improvement were in group 2. Although there was a statistically significant difference for the McGowan scores pre- and postoperatively ($p<0.005$), no significant difference was found in regard to McGowan scores between the study groups postoperatively ($p=0.317$).

The modified Wilson and Krout grading system revealed that a total of 34 patients had excellent outcomes (20 patients in group 1 and 14 patients in group 2), 33 patients had good outcomes (19 patients in group 1 and 14 patients in group 2), and four patients had fair outcomes (one patient in group 1 and three patients in group 2) at the final follow-up visit. There was no patient with poor outcome. All patients were able to return to their former job/daily activity routines in the follow-up period. There was a significant difference between the study groups in regard to Wilson and Krout grading after surgery ($p=0.002$). Group 1 had significantly better final outcomes with no pain and excellent outcomes compared to group 2.

DISCUSSION

This study is one of the first studies in the literature that prospectively compared single *in-situ* decompression with partial medial epicondylectomy with a minimum of two years of follow-up.

Idiopathic CuTS is one of the most commonly seen neurological problems of the upper limb in the outpatient clinics. The majority of CuTS patients with weakness/numbness of the hand or elbow and forearm pain while doing daily activities are commonly treated with conservative methods. Nevertheless, some patients with CuTS require surgical treatment due to failure of these conservative treatment methods. In the literature, several studies emphasized that the decision for the surgical treatment may also depend on the nerve conduction velocity of the ulnar nerve, generally accepted as below 40 mm per second derived from the EMG studies.^[18-24] In our study, we used EMG findings for the diagnostic purposes only and the decision of surgical treatment was established according to the failure of conservative treatment including the steroid injections for at least two months regardless of the EMG findings. Future prospective comparative studies should be designed including the patients who have surgical treatment according to the EMG findings. Today, although the literature contains numerous studies about the outcomes of patients who

had surgical treatment for idiopathic CuTS, the gold standard surgical treatment option is still a matter of discussion.

Surgical treatment of idiopathic CuTS has been widely used in clinical practice with various methods in a wide array including simple *in-situ* decompression, decompression with anterior transpositions (intramuscular, submuscular, or subcutaneous), and medial epicondylectomy. Nevertheless, there are no clear-cut indications for different surgical techniques in the literature due to heterogeneous study populations, different outcome measures with short follow-up periods, and lack of prospective comparative studies.

Simple *in-situ* decompression and medial epicondylectomy are the two most widely used surgical techniques for the treatment of idiopathic CuTS with a reported success rate of more than 85%. Although prospective studies and meta-analyses comparing simple *in-situ* decompression and transpositions revealed that simple *in-situ* decompression is as equally effective as transpositions, the comparative data between simple *in-situ* decompression and medial epicondylectomy are very scarce and inconclusive in the literature. Hence, prospective comparative studies are needed for the evaluation of these two surgical procedures in order to understand the best option for the surgical treatment of idiopathic CuTS.

Many surgeons prefer simple *in-situ* decompression for having an easy technique and requiring a smaller incision, which causes less tissue damage, preserves nerve vascularization, and requires less rehabilitation time.^[15,18,25] In the literature, most of the studies reported that more than 80% of patients had satisfactory outcomes with simple *in-situ* decompression. In a recent meta-analysis by Zlowodzki et al.,^[25] randomized, controlled trials comparing the simple decompression with the anterior transposition (submuscular or subcutaneous) were analyzed and it was concluded that there were no significant differences for the postoperative outcomes, which supports the use of a simple *in-situ* decompression.^[25] On the contrary, one of the most controversial issues of *in-situ* decompression is the subluxation of the ulnar nerve with elbow flexion after surgery. Although there are considerable data about the subluxation of the ulnar nerve after *in-situ* decompression, there is still controversy about the real incidence and possible risk factors of this postoperative complication. Most surgeons perform anterior translation or medial epicondylectomy if they observe ulnar nerve subluxation during elbow flexion. However, there is insufficient evidence in the literature to suggest that anterior translation

or medial epicondylectomy is superior to *in-situ* decompression in regard to ulnar nerve subluxation. In a study by Childress,^[26] it was shown that the ulnar nerve subluxes naturally in 16.2% of the normal population. In another cadaveric study by Butler et al.,^[27] an *in-situ* ulnar nerve decompression was performed in 10 fresh frozen right cadaver arms and it was concluded that *in-situ* ulnar nerve decompression from the flexor carpi ulnaris aponeurosis to the intermuscular septum did not result in significant ulnar nerve translation or subluxation. In the current study, there was no postoperative complication of ulnar nerve subluxation for the *in-situ* decompression group in a minimum of two years of follow-up.^[28] Therefore, we believe that for the idiopathic CuTS, simple *in-situ* decompression does not have any risk of ulnar nerve subluxation only if there is no local problem like as osteophytes, scarring or alignment problems of the elbow.

Medial epicondylectomy was first described in 1959 by King and Morgan^[6] as a "mini anterior transposition" and since then, most of the studies in the literature have confirmed the success rates between 72% and 94%.^[29] Compared with decompression plus anterior transposition, medial epicondylectomy better preserves the blood supply of the ulnar nerve, causes less injury to the nerve, and preserves the small proximal nerve branches that might be sacrificed with an anterior transposition. On the other hand, total medial epicondylectomy, which results in removal of 40% of the medial epicondyle (until the medial margin of the trochlea), puts the anterior medial collateral ligament (AMCL) at risk leading to elbow instability. Additionally, total medial epicondylectomy may result in medial elbow pain, ulnar nerve subluxation, flexor-pronator weakness, and elbow flexion contracture.^[19,30] In order to solve these problems, partial medial epicondylectomy was described by Kaempffe and Farbach^[13] in 1998, which resects approximately 6 to 7 mm of the epicondyle (20 to 40%) preserving the entire anterior medial collateral ligament. The terms partial medial epicondylectomy (6-7 mm of the epicondyle) and minimal medial epicondylectomy (<6 mm of the epicondyle) have been used rather interchangeably in the literature.^[19,31-33] Although these two types of techniques are somehow similar, in that each procedure describes a resection of the medial epicondyle that is less than 40% of the epicondyle, we believe that minimal medial epicondylectomy resection is not enough for the ulnar nerve to simultaneously transpose through the anterior part of the elbow while elbow flexion, leading to the recurrence of the CuTS in the postoperative period. For this reason,

if we want to perform epicondylectomy, we prefer partial epicondylectomy to warrant the spontaneous ulnar nerve transposition while elbow flexion.

The literature contains various studies in favor of partial medial epicondylectomy with a success rate similar to total epicondylectomy in regard to alleviation of symptoms and better stability of the elbow. In 2000, Amako et al.^[31] compared minimal medial epicondylectomy with total epicondylectomy. Although the outcomes were similar with respect to alleviation of postoperative symptoms, 74% of the total epicondylectomy patients (10/14) demonstrated valgus instability of the elbow, and 20% of those patients (2/10) were symptomatic. Nevertheless, the minimal epicondylectomy group demonstrated no instability postoperatively. Thus the authors concluded that minimal medial epicondylectomy is a safer procedure with comparable outcomes to total medial epicondylectomy. In another study by Kim et al.,^[30] 25 patients treated with minimal medial epicondylectomy for advanced CuTS were analyzed with a minimum follow-up of 12 months. The authors reported that 23 of the 25 patients improved at least one McGowan stage with no complications, such as medial elbow instability. Consequently, it was stated that minimal medial epicondylectomy is an effective treatment even for patients with moderate to severe CuTS. A systematic review by O'Grady et al.^[34] reviewed 21 case series reported on 886 medial epicondylectomies. Among these studies, the mean percentage of patients obtaining improvement of one or more McGowan stages was reported as 79% and the mean percentage for those obtaining a good/excellent Wilson and Krout stage of outcomes was reported as 83%. In our study, we also found that medial epicondylectomy patients had over 80% of good/excellent outcomes according to Wilson and Krout grading system. Nevertheless, O'Grady's study also stated that the studies of medial epicondylectomy do not have any standard outcome measures and more studies are needed to understand the real effectiveness of medial epicondylectomy surgeries. We believe that the current study may be a step for this with future comparable studies.

The literature also contains various studies with long-term follow-ups of medial epicondylectomy, reporting a functional improvement in approximately 90% of patients.^[32,35,36] For partial epicondylectomies, Erol et al.^[35] reported 94% excellent and good results in 17 elbows in a follow-up period of over two years. In another study by Göbel et al.,^[32] an overall success rate of 94% was reported (79% excellent and good results) in 66 elbows in a mean follow-up

of 27 months. We had comparable results with the literature with an 85% of excellent and good outcomes for the medial epicondylectomy group.

One of the most emphasized problems in the literature after medial epicondylectomy is the pain and tenderness at the surgical area leading to flexor/pronator weakness in the postoperative period. Kaempffe and Farbach^[13] reported medial epicondylar tenderness in 44% of their patients at an average of 11 months after partial medial epicondylectomy surgery. Manske et al.^[37] reported prolonged and persistent discomfort at the operative site due to healing bone. In another study by Efsthopoulos DG,^[19] 80 elbows with CuTS were retrospectively analyzed and almost half of the patients (45%) reported mild pain at the six-month follow-up. Another problem of medial epicondylectomy is the amount of bone resection. It is commonly stated in the literature that a 7 mm of epicondylar resection is enough for the ulnar nerve transposition without the risk of damaging the AMCL. Nevertheless, this 7 mm of resection is mostly dependent on patient factors including sex, anatomical variations of the distal humerus, and even body mass indices. It is very commonly accepted in the surgical practice that the patient's characteristics should be kept in mind during surgery and if necessary, a more thicker bone resection should be performed without damaging the AMCL. In the current study, partial medial epicondylectomy was performed for patients who demonstrated ulnar nerve subluxation about the medial epicondyle intraoperatively, following *in-situ* decompression; and, we almost always controlled the tracking of the ulnar nerve while elbow flexion intraoperatively to understand if the epicondylectomy was sufficient or not. If we believed that it was not sufficient, we resected only slightly more medial epicondyle without damaging the AMCL. Consequently, none of the patients in the partial medial epicondylectomy group had valgus instability postoperatively. Nevertheless, partial medial epicondylectomy group had statistically more pain and tenderness compared to simple *in-situ* decompression group which had better Wilson and Krout grading scores.

Although the literature contains a wide array of studies comparing different surgical procedures for the treatment of CuTS, the comparative data between medial epicondylectomy and simple *in-situ* decompression for the treatment of solely idiopathic CuTS are very scarce and inconclusive.

In a recent meta-analysis by Zlowodzki et al.,^[25] four randomized comparative studies between anterior transposition and *in-situ* simple decompression for

the treatment of idiopathic CuTS were analyzed. The results of this meta-analysis revealed that there is no difference in motor nerve-conduction velocities or clinical outcome scores between simple decompression and ulnar nerve transposition. The authors suggest that simple decompression of the ulnar nerve is a reasonable alternative to anterior transposition for the surgical management of ulnar nerve compression at the elbow. In another meta-analysis by Macadam et al.,^[38] 10 randomized controlled trials comparing simple decompression with anterior transposition were analyzed. The authors concluded that there was no statistically significant difference between the procedures. Additionally, a systematic review published in 2000 by Mowlavi et al.^[39] also grouped patients from 30 studies into categories of symptom severity. The authors stated that for minimum-staged patients, all modalities produced similar degrees of satisfaction. Nevertheless, for severe-staged patients, current therapeutic modalities were not consistently effective, with medial epicondylectomy producing the poorest operative result. The current study also revealed comparative outcomes with the literature. In our study, simple decompression group had significantly better grip and key pinch strength values compared to medial epicondylectomy at the final follow-up control with significantly better outcomes with no pain and excellent outcomes. The reason for this weakness may be the type of the muscle repair technique. Thus we believe that using a different muscle repair technique can be practiced in future studies to solve this problem.

The failure of these two techniques and recurrence of the CuTS are also major drawbacks of this pathology leading to patient dissatisfaction. Although the failure rates are definitely low compared with the other nerve entrapment syndromes (overall recurrence rate was 10% in 10-year period), the definitive treatment plan is a matter of discussion. The most common reason for a failure is reported as insufficient decompression of the ulnar nerve along the cubital tunnel. Accordingly, we believe that if any failure and recurrence occur, a meticulous control of other pathologies should be carried out and if necessary, a second-look revision surgery with a more extensive approach should be performed.

There are some limitations that must be emphasized for this study. First of all, the study contained only simple decompression and medial epicondylectomy. Other treatment options were not analyzed. Secondly, no postoperative EMG studies were performed to understand the nerve conduction velocities. In our study, postoperative

nerve healing was analyzed by the time to return to work and McGowan stages, which predominantly evaluate the clinical and functional statuses of the patients. Thirdly, all surgeries were performed independently by two surgeons. Although surgical procedures were standardized, it may be a factor that may have led to different surgical outcomes. Fourthly, no cost-utility analysis was performed for the current study due to the lack of the data about the cost of the surgical procedures and the high variety of the health insurance programs with different coverage. Finally, only a limited number of factors were analyzed; the inclusion of other factors could have provided more valuable information. For example, the anatomical configuration of the cubital tunnel may also play an important part in the development of postoperative ulnar nerve instability, and further studies could be performed in this aspect. We also did not analyze specific patient characteristics including body mass indices and smoking habits. It is well known in the literature that particularly smoking can influence the outcomes of treatment methods for CuTS.

In conclusion, the current study reported the comparative clinical and functional outcomes of idiopathic CuTS treated by either *in-situ* decompression or partial medial epicondylectomy with a minimum of two years of follow-up. *In-situ* decompression and partial medial epicondylectomy represent efficient and safe methods for the treatment of idiopathic CuTS. In long-term, these two surgical methods for CuTS have a great potential for patients with high effectiveness and low complication rates. Patients' satisfaction is also very high in long-term follow-up with very scarce recurrence or no elbow instability. When their efficiency is compared, *in-situ* decompression had better grip and key pinch strength values and more excellent outcomes compared to partial medial epicondylectomy. For these reasons, we believe that although the two surgical procedures have satisfactory outcomes, performing only *in-situ* decompression may be adequate for selected cases of idiopathic CuTS. Further prospective comparative studies are needed with larger sample sizes and different patient characteristics to have more definitive outcomes.

Declaration of conflicting interests

The authors declared no conflicts of interest with respect to the authorship and/or publication of this article.

Funding

The authors received no financial support for the research and/or authorship of this article.

REFERENCES

1. Mondelli M, Giannini F, Ballerini M, Ginanneschi F, Martorelli E. Incidence of ulnar neuropathy at the elbow in the province of Siena (Italy). *J Neurol Sci* 2005;234:5-10.
2. Dellon AL. Review of treatment results for ulnar nerve entrapment at the elbow. *J Hand Surg Am* 1989;14:688-700.
3. Dellon AL, Coert JH. Results of the musculofascial lengthening technique for submuscular transposition of the ulnar nerve at the elbow. *J Bone Joint Surg [Am]* 2004;86-A Suppl 1:169-79.
4. Kleinman WB, Bishop AT. Anterior intramuscular transposition of the ulnar nerve. *J Hand Surg Am* 1989;14:972-9.
5. Eaton RG, Crowe JF, Parkes JC 3rd. Anterior transposition of the ulnar nerve using a non-compressing fasci dermal sling. *J Bone Joint Surg [Am]* 1980;62:820-5.
6. King T, Morgan FP. Late results of removing the medial humeral epicondyle for traumatic ulnar neuritis. *J Bone Joint Surg [Br]* 1959;41:51-5.
7. Neblett C, Ehni G. Medial epicondylectomy for ulnar palsy. *J Neurosurg* 1970;32:55-62.
8. Hoffmann R, Siemionow M. The endoscopic management of cubital tunnel syndrome. *J Hand Surg Br* 2006;31:23-9.
9. Krishnan KG, Pinzer T, Schackert G. A novel endoscopic technique in treating single nerve entrapment syndromes with special attention to ulnar nerve transposition and tarsal tunnel release: clinical application. *Neurosurgery* 2006;59(1 Suppl 1):ONS89-100.
10. Porcellini G, Paladini P, Campi F, Merolla G. Arthroscopic neurolysis of the ulnar nerve at the elbow. *Chir Organi Mov* 2005;90:191-200.
11. Osborne G. Ulnar neuritis. *Postgrad Med J* 1959;35:392-6.
12. Feindel W, Stratford J. Cubital tunnel compression in tardy ulnar palsy. *Can Med Assoc J* 1958;78:351-3.
13. Kaempffe FA, Farbach J. A modified surgical procedure for cubital tunnel syndrome: partial medial epicondylectomy. *J Hand Surg Am* 1998;23:492-9.
14. Novak CB, Lee GW, Mackinnon SE, Lay L. Provocative testing for cubital tunnel syndrome. *J Hand Surg Am* 1994;19:817-20.
15. Huang JH, Samadani U, Zager EL. Ulnar nerve entrapment neuropathy at the elbow: simple decompression. *Neurosurgery* 2004;55:1150-3.
16. Heithoff SJ, Millender LH, Nalebuff EA, Petruska AJ Jr. Medial epicondylectomy for the treatment of ulnar nerve compression at the elbow. *J Hand Surg Am* 1990;15:22-9.
17. Goldberg BJ, Light TR, Blair SJ. Ulnar neuropathy at the elbow: results of medial epicondylectomy. *J Hand Surg Am* 1989;14:182-8.
18. Bartels RH, Verhagen WI, van der Wilt GJ, Meulstee J, van Rossum LG, Grotenhuis JA. Prospective randomized controlled study comparing simple decompression versus anterior subcutaneous transposition for idiopathic neuropathy of the ulnar nerve at the elbow: Part I. *Neurosurgery* 2005;56:522-30.
19. Efstathopoulos DG, Themistocleous GS, Papagelopoulos PJ, Chloros GD, Gerostathopoulos NE, Soucacos PN. Outcome of partial medial epicondylectomy for cubital tunnel syndrome. *Clin Orthop Relat Res* 2006;444:134-9.
20. Keiner D, Gaab MR, Schroeder HW, Oertel J. Comparison of the long-term results of anterior transposition of the ulnar nerve or simple decompression in the treatment of cubital tunnel syndrome--a prospective study. *Acta Neurochir (Wien)* 2009;151:311-5.
21. Macadam SA, Bezuhly M, Lefavre KA. Outcomes measures used to assess results after surgery for cubital tunnel syndrome: a systematic review of the literature. *J Hand Surg Am* 2009;34:1482-91.e5.
22. Muermans S, De Smet L. Partial medial epicondylectomy for cubital tunnel syndrome: Outcome and complications. *J Shoulder Elbow Surg* 2002;11:248-52.
23. O'Driscoll SW, Jalszynski R, Morrey BF, An KN. Origin of the medial ulnar collateral ligament. *J Hand Surg Am* 1992;17:164-8.
24. Pavelka M, Rhomberg M, Estermann D, Löscher WN, Piza-Katzer H. Decompression without anterior transposition: an effective minimally invasive technique for cubital tunnel syndrome. *Minim Invasive Neurosurg* 2004;47:119-23.
25. Zlowodzki M, Chan S, Bhandari M, Kallianen L, Schubert W. Anterior transposition compared with simple decompression for treatment of cubital tunnel syndrome. A meta-analysis of randomized, controlled trials. *J Bone Joint Surg [Am]* 2007;89:2591-8.
26. Childress HM. Recurrent ulnar-nerve dislocation at the elbow. *Clin Orthop Relat Res* 1975;108:168-73.
27. Butler B, Peelman J, Zhang LQ, Kwasny M, Nagle D. The effect of in-situ decompression on ulnar nerve stability: a cadaveric study. *J Hand Surg Eur Vol* 2017;42:715-9.
28. Atik OŞ. Is there something new and interesting in my article? *Eklemler Hastalıkları Cerrahisi* 2019;30:69.
29. Heithoff SJ. Cubital tunnel syndrome does not require transposition of the ulnar nerve. *J Hand Surg Am* 1999;24:898-905.
30. Kim KW, Lee HJ, Rhee SH, Baek GH. Minimal epicondylectomy improves neurologic deficits in moderate to severe cubital tunnel syndrome. *Clin Orthop Relat Res* 2012;470:1405-13.
31. Amako M, Nemoto K, Kawaguchi M, Kato N, Arino H, Fujikawa K. Comparison between partial and minimal medial epicondylectomy combined with decompression for the treatment of cubital tunnel syndrome. *J Hand Surg Am* 2000;25:1043-50.
32. Göbel F, Musgrave DS, Vardakas DG, Vogt MT, Sotereanos DG. Minimal medial epicondylectomy and decompression for cubital tunnel syndrome. *Clin Orthop Relat Res* 2001;393:228-36.
33. Osterman AL, Spiess AM. Medial epicondylectomy. *Hand Clin* 2007;23:329-37.
34. O'Grady EE, Vanat Q, Power DM, Tan S. A systematic review of medial epicondylectomy as a surgical treatment for cubital tunnel syndrome. *J Hand Surg Eur Vol* 2017;42:941-5.
35. Erol B, Tetik C, Sirin E. The mid-term results of minimal medial epicondylectomy and decompression for cubital tunnel syndrome. *Acta Orthop Traumatol Turc* 2004;38:330-6.
36. Geutjens GG, Langstaff RJ, Smith NJ, Jefferson D, Howell CJ, Barton NJ. Medial epicondylectomy or ulnar-nerve transposition for ulnar neuropathy at the elbow? *J Bone Joint Surg [Br]* 1996;78:777-9.
37. Manske PR, Johnston R, Pruitt DL, Strecker WB. Ulnar nerve decompression at the cubital tunnel. *Clin Orthop Relat Res* 1992;274:231-7.
38. Macadam SA, Gandhi R, Bezuhly M, Lefavre KA. Simple decompression versus anterior subcutaneous and submuscular transposition of the ulnar nerve for cubital tunnel syndrome: a meta-analysis. *J Hand Surg Am* 2008;33:1314.e1-12.
39. Mowlavi A, Andrews K, Lille S, Verhulst S, Zook EG, Milner S. The management of cubital tunnel syndrome: a meta-analysis of clinical studies. *Plast Reconstr Surg* 2000;106:327-34.