

Detection of High Levels of Heparin Binding Growth Factor-1 (Acidic Fibroblast Growth Factor) in Inflammatory Arthritic Joints

Hajime Sano, Reza Forough,* Jeanette A. M. Maier,* John P. Case, Anthony Jackson,* Kurt Engleka,* Thomas Maciag,* and Ronald L. Wilder

Arthritis and Rheumatism Branch, Connective Tissue Disease Section, National Institute of Arthritis and Musculoskeletal and Skin Diseases, National Institutes of Health, Bethesda, Maryland 20892; and *Laboratory of Molecular Biology, Jerome H. Holland Laboratory for the Biomedical Sciences, American Red Cross, Rockville, Maryland 20855

Abstract. The synovium from patients with rheumatoid arthritis (RA) and LEW/N rats with streptococcal cell wall (SCW) arthritis, an experimental model resembling RA, is characterized by massive proliferation of synovial connective tissues and invasive destruction of periarticular bone and cartilage. Since heparin binding growth factor (HBGF)-1, the precursor of acidic fibroblast growth factor (FGF), is a potent angiogenic polypeptide and mitogen for mesenchymal cells, we sought evidence that it was involved in the synovial pathology of RA and SCW arthritis.

HBGF-1 mRNA was detected in RA synovium using the polymerase chain reaction technique, and its product was immunolocalized intracellularly in both RA

and osteoarthritis (OA) synovium. HBGF-1 staining was more extensive and intense in synovium of RA patients than OA and correlated with the extent and intensity of synovial mononuclear cell infiltration. HBGF-1 staining also correlated with c-Fos protein staining. In SCW arthritis, HBGF-1 immunostaining was noted in bone marrow, bone, cartilage, synovium, ligamentous and tendinous structures, as well as various dermal structures and developed early in both T-cell competent and incompetent rats. Persistent high level immunostaining of HBGF-1 was only noted in T-cell competent rats like the disease process in general. These observations implicate HBGF-1 in a multitude of biological functions in inflammatory joint diseases.

HEPARIN binding growth factor (HBGF)¹-1, the precursor of acidic fibroblast growth factor (FGF), is a potent polypeptide mitogen for mesenchymal and neuroectoderm-derived cells (Thomas, 1987; Lobb et al., 1986; Burgess and Maciag, 1989). HBGF-1 is a member of a larger HBGF family of polypeptides that presently includes basic FGF and the oncogenes *int-2* (Dickson and Peters, 1987), *hst/KS* (Taira et al., 1987; Delli Bovi et al., 1987), FGF-5 (Zhan et al., 1988), FGF-6 (Marics et al., 1989) and keratinocyte growth factor (KGF) (Finch et al., 1989). The amino acid sequences of bovine and human HBGF-1 have been determined (Gimenez-Gallego et al., 1985; Burgess et al., 1986; Gautschi-Sova et al., 1986), and complementary DNA clones encoding human HBGF-1 have been isolated (Jaye et al., 1986). The HBGF-1 polypeptide has been extracted from bone matrix (Huschka et al., 1986), brain (Thomas et al., 1984), retina (Baird et al., 1985), and kidney (Gautschi-Sova et al., 1987), and stimulates the proliferation of chondrocytes (Burgess and Maciag, 1989), calvaria-derived osteoblastic cells (Canalis et al., 1987; Rodan et al., 1987), and synovial fibroblast-like cells in vitro (Remmers

et al., 1989). In addition, HBGF-1 not only stimulates endothelial cell proliferation in vitro (Burgess and Maciag, 1989) but is a potent angiogenic factor in vivo (Folkman and Klagsbrun, 1987; Thompson et al., 1988).

The synovium from patients with rheumatoid arthritis (RA) and LEW/N rats with streptococcal cell wall (SCW) arthritis, an experimental model resembling RA, is characterized by diffuse and nodular mononuclear cell infiltration and pronounced hyperplasia of the stromal connective tissues comprised of fibroblast-like cells and new blood vessels (Harris, 1976; Fassbender, 1983; Bromley and Woolley, 1984a; Bromley and Woolley, 1984b; Wilder et al., 1987; Yocum et al., 1988). The synovial fibroblast-like cells and new blood vessels, and to a lesser extent macrophages and osteoclasts, are the predominant cell populations at sites of cartilage resorption and bone erosion. This high-grade proliferative and invasive disease process resembles a locally invasive tumor (Harris, 1976; Fassbender, 1983; Hamilton, 1983; Haraoui et al., 1985; Wilder et al., 1987; Yocum et al., 1988; Remmers et al., 1989; Lafyatis et al., 1989a; Case et al., 1989a,b). In contrast to malignantly transformed tissues, the tumorlike phenotype of the synovial tissues is not constitutive, and paracrine factors, elaborated locally and systemically by inflammatory cells, appear necessary to induce proliferation and invasion by synovial mesenchymal

1. *Abbreviations used in this paper:* FGF, fibroblast growth factor; H and E, hematoxylin and eosin; HBGF, heparin binding growth factor; OA, osteoarthritis; PCR, polymerase chain reaction; RA, rheumatoid arthritis; SCW, streptococcal cell wall.

cells. PDGF and transforming growth factor- β appear to play important roles in this process (Lafyatis et al., 1989a,b; Remmers et al., 1989). Because angiogenesis is a prominent feature of the destructive process in RA and SCW arthritis, we analyzed the synovium of patients with RA, osteoarthritis (OA) and of SCW-injected rats for the presence of HBGF-1. We present evidence that implicates HBGF-1 in these disease processes.

Materials and Methods

Tissue Specimens and Induction of Arthritis

Synovia were obtained intraoperatively from 20 RA and 11 OA patients at the time of arthroscopic biopsy or total joint replacement. 20 patients with RA met the 1987 revised criteria for the classification of RA (Arnett et al., 1988). No attempt was made to segregate RA or OA patients on basis of duration of disease or disease activity. Specific pathogen-free inbred LEW/N female rats were obtained from Harlan Sprague Dawley (Indianapolis, IN) and congenitally athymic nude LEW.rnu/rnu rats were obtained from the Small Animal Section, Veterinary Resources Branch, National Institutes of Health, Bethesda, MD. Animals were housed in cages with filter tops (Lab Products Inc., Maywood, NJ) in an environment free of known microbial pathogens. The rats were ~6 wk old and weighed 80–100 g at the initiation of each experiment. The preparation of cell wall peptidoglycan-polysaccharide fragments from group A streptococci and the induction of polyarthritis were done as described in detail previously (Wilder et al., 1982). Briefly, a sterile aqueous suspension of sonicated SCW fragments in PBS, pH 7.4 was injected intraperitoneally into rats at a dose equivalent to 20 μ g of cell wall/g body weight. This dose has been shown previously to induce acute and chronic polyarthritis in LEW/N female rats, and acute polyarthritis in athymic nude LEW.rnu/rnu rats with nearly 100% incidence. Rats injected with SCW (day 0) were killed in pairs at days 1–4 and 28; i.e., through the preclinical and clinical stages of disease until the development of maximal clinical arthritis. Hindfoot specimens were preserved in 10% formalin, decalcified in EDTA, embedded in paraffin, and sectioned (6 μ m) onto gelatin-coated microscope slides. Human synovial specimens were prepared similarly, but the decalcification procedure was not necessary.

Purification of HBGF-1 Antibody

Polyclonal antiserum against HBGF-1 was prepared in a rabbit according to Lerner (1981) and affinity-purified on recombinant human HBGF-1 (Forough, R., D. Roeder, J. A. Thompson, D. Scandella, and T. Maciag, unpublished observations) coupled to cyanogen bromide-activated Sepharose 4B (Pharmacia Fine Chemical, Uppsala, Sweden) (Johnstone and Thorpe, 1987). For affinity purification, polyclonal antibody against HBGF-1 was added to the HBGF-1-Sepharose conjugate and incubated at room temperature for 2 h. The suspension was packed in a 1 \times 10-cm column and washed with phosphate buffer (20 mM sodium phosphate, pH 7.3, with 0.5 M NaCl) until the OD₂₈₀ returned to baseline. The antibody bound to the affinity column was eluted with thiocyanate buffer (3 M KSCN with 0.5 M ammonium hydroxide) and dialyzed against several changes of cold PBS.

Western Blot Analysis of Affinity-purified Antibody against HBGF-1

Recombinant human HBGF-1 and 2 (20 ng/lane) were run on 15% polyacrylamide gel in reducing conditions. Proteins were transferred electrophoretically to a nitrocellulose membrane (0.2 μ m pore size; Schleicher & Schuell, Keene, NH) in transfer buffer (25 mM Tris, 192 mM glycine, 0.02% SDS, 20% methanol) for 2 h at 400 mA (Towbin et al., 1979). The filter was then blocked by incubation in 50 mM Tris-HCl-150 mM NaCl, pH 7.4 (TBS) containing 5% BSA for 2 h. The blot was incubated with affinity-purified HBGF-1 antibody (50 μ g/ml) in TBS containing 5% BSA for 1 h. After washing four times in TBS with 0.05% Triton X-100, the filter was incubated with 5 \times 10⁵ cpm of ¹²⁵I-protein A/ml (Calbiochem-Behring Corp., San Diego, CA) as described (Friesel et al., 1989). The blot was washed four times in TBS containing 0.05% Triton X-100 and air dried. Binding of ¹²⁵I-protein A was visualized by autoradiography with Kodak XAR films at -80°C for 10 h.

Immunohistochemistry

Immunoperoxidase staining with Vecstatin ABC kit (Vector Laboratories, Inc., Burlingame, CA) followed the manufacturer's suggested protocol (Hsu and Ree, 1980; Hsu et al., 1981). All subsequent procedures were performed at room temperature. The sections were deparaffinized. Endogenous peroxidase activity was exhausted by incubating in 0.3% peroxide in methanol for 45 min. The sections were preincubated with 0.1% BSA in PBS for 20 min and with diluted goat serum (1:66.7) for 20 min followed by incubation in a humid chamber with affinity-purified HBGF-1 antibody (50 μ g/ml), anti-HBGF-1 antibody that was absorbed extensively on HBGF-1-Sepharose (affinity-negative IgG) 50 μ g/ml or purified rabbit IgG (50 μ g/ml; Jackson Immunoresearch Laboratories, Inc., West Grove, PA). After 30 min, the sections were washed in PBS and incubated with biotinylated goat anti-rabbit IgG for 30 min, the sections were further washed with PBS and incubated with an avidin and biotinylated horseradish peroxidase complex. Finally, the sections were washed and color was developed by immersing sections in a solution of 0.05% wt/vol 3,3'-diaminobenzidine tetrahydrochloride (Sigma Chemical Co., St. Louis, MO), 0.04% wt/vol nickel chloride, and 0.01% hydrogen peroxide in 0.05 M Tris pH 7.4 for 2–7 min. The sections were counterstained with 0.5% light green SF (Roboz Surgical Instrument Co. Inc., Washington, DC).

Anti-c-Fos protein immunostaining employed a commercially available affinity-purified immunoglobulin (OP-11-821; Cambridge Research Biochemicals, Valley Stream, NY) made in sheep by immunization with a synthetic peptide corresponding to amino acid sequence: Met-Phe-Ser-Gly-Phe-Asn-Ala-Asp-Tyr-Glu-Ala-Ser-Ser-Arg-[Cys] derived from a conserved region of both murine and human c-Fos (van Straaten et al., 1983). Optimal staining was achieved at a concentration of 25 μ g/ml. Control slides were incubated with an equal concentration of sheep IgG (Chrompure, Jackson Immunoresearch Laboratories, Inc.), or with the specific antibody preincubated with a 100 \times molar excess of the immunogenic peptide. These were negative in all cases. Positive staining was indicated by brownish black deposits. Control stains with affinity-negative IgG, rabbit IgG, sheep IgG, or the specific antibody absorbed with the Fos peptide were uniformly negative in all cases.

For each tissue specimen, the extent and intensity of staining with HBGF-1 antibody and c-Fos antibody were graded on a scale of 0–4+ by a blinded observer on two separate occasions using coded slides and an average score calculated. The observer assessed all tissue on the slides to assign the scores. Thus, a 4+ grade implies that all staining was maximally intense throughout the tissue specimen, while 0 implies that staining was absent throughout the specimen. Particular attention was also given to the histologic structures that stained most intensely. Mononuclear cell infiltration was assessed similarly on hematoxylin and eosin (H and E) stained sections cut from the same paraffin blocks used for antibody staining. Thus, a 4+ grade implies that all tissue was intensely infiltrated with mononuclear cells, while 0 implies that mononuclear cell infiltration was absent throughout.

RNA Isolation

Tissue specimens were either flash-frozen in liquid nitrogen for subsequent storage, or immediately homogenized in lysing buffer with a homogenizer (Brinkmann Instruments, Westbury, NY) for storage at -70°C or immediate use; specimens stored in liquid nitrogen were later homogenized in lysing buffer as frozen pieces. RNA was isolated by the method of Chomczynski and Sacchi (1987); for tissue specimens, the second extraction step was replaced by proteinase K digestion followed by multiple extractions with phenol-chloroform in a microfuge tube. RNA was aliquotted and stored as ethanol precipitates at -20°C.

Southern Blot Analysis of Polymerase Chain Reaction of Reverse-transcribed RNA

Total RNA (1 μ g) was extracted from synovial tissues of RA patients and reverse-transcribed. The cDNA fragments were amplified for 40 cycles with the polymerase chain reaction (PCR) technique (Saiki et al., 1988; Stoffel et al., 1988) using a pair of sequence specific primers for HBGF-1: nucleotides 166–186 on (+) strand and 483–503 on (-) strand (Jaye et al., 1986). Specifically, the samples were heated at 94°C for 1 min to denature the cDNA, cooled to 52°C for 2 min to anneal the primers and heated to 72°C for 3 min to extend the annealed primers with Taq DNA polymerase. PCR amplified products were resolved on a composite gel of 2% NuSieve and 1% agarose (Bethesda Research Laboratories, Gaithersburg, MD) in Tris-

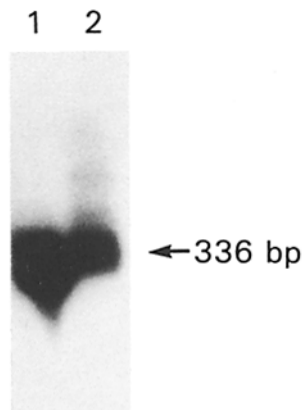


Figure 1. Southern blot analysis of PCR-amplified products of reverse-transcribed RNA isolated from synovial tissues of RA patients. Total RNA (1 μ g) was extracted from synovial tissues of RA patients and reverse-transcribed. The HBGF-1 cDNA fragments were amplified for 40 cycles with the PCR technique using a pair of sequence specific primers: nucleotides 166–186 on (+) strand and 483–503 on (–) strand. The expected product (336 bp) was demonstrated by hybridization with [³²P]-labeled HBGF-1 cDNA (lane 1). PCR-amplified products of reverse-transcribed RNA isolated from chicken gizzard (lane 2) served as a control.

borate-EDTA buffer and capillary transferred to a nitrocellulose membrane. For hybridization, [³²P]-labeled HBGF-1 isolated from a human brain stem cDNA library (R. Forough and T. Maciag, unpublished observation) was used, and corresponded to the nucleotide sequence reported by Jaye et al. (1986).

Statistical Analysis

Analyses of data were performed using the Wilcoxon rank-sum test and Spearman's rank correlation (Remington and Schork, 1985).

Results

Southern Blot Analysis of PCR-amplified Products of Reverse-transcribed RNA Isolated from Synovial Tissues of RA Patients

Northern blot analysis of poly A-selected RNA extracted from RA and OA synovium failed to detect the HBGF-1 mRNA transcript. As an alternative, RNA purified from RA synovium was reverse transcribed and the cDNA fragments amplified using the PCR technique. Products of the PCR were subjected to gel electrophoresis and validated by Southern blot analysis. As shown in Fig. 1, RNA from RA synovium expressed HBGF-1 mRNA transcripts. The expected size band (336 bp) was detected by hybridization with [³²P]-labeled HBGF-1 isolated from a human brain stem cDNA library (Fig. 1, lane 1).

HBGF-1 Immunostaining of Synovium from Patients with RA and OA

To determine whether the HBGF-1 mRNA transcript was translated and to identify the microanatomical location of the polypeptide, we immunohistochemically stained synovial tissues. The affinity-purified HBGF-1 antibody was used to stain synovium from patients with RA and OA. Western blot analysis of the affinity-purified antibody demonstrated that HBGF-1 antibody recognized HBGF-1 but not HBGF-2 (basic FGF) (Fig. 2). This also occurred with exaggerated concentrations of HBGF-2. Furthermore, the antibody recognized between 1 to 5 ng HBGF-1 per lane loaded onto SDS-PAGE, indicating that the antibody had a relatively high affinity for HBGF-1. As shown in a representative synovial tissue section (Fig. 3), diffuse and intense intracellular stain-

ing was observed within the synovial lining cell layer (Fig. 3, A and C). Prominent HBGF-1 polypeptide staining was also observed in the sublining stromal fibroblast-like cells (Fig. 3, A, C, and D), vascular endothelial cells (Fig. 3 D) and inflammatory cells (Fig. 3, A, C, and D). In addition to the intense cytoplasmic staining, many cells appeared to show nuclear staining as well (e.g., Fig. 3 C, inset). Control staining with nonspecific rabbit IgG (Fig. 3 B) or affinity-negative IgG was absent in all cases. Synovial tissue sections from patients with OA, in sharp contrast, stained strongly only on the lining cell layer and sublining vascular endothelial cells (Fig. 3, E and F). Stromal fibroblast-like cells appeared to stain very weakly (Fig. 3, E and F).

Statistical Analysis of HBGF-1 Immunostaining In Vivo

The extent and intensity of staining with HBGF-1 antibody was graded 0–4+ by a blinded observer on 20 RA and 11 OA synovial specimens. HBGF-1 immunostaining was more extensive and intense in synovium of RA patients than in that of OA patients ($P < 0.05$; Wilcoxon rank-sum test) as shown in Fig. 4 A. That is, RA specimens showed much more synovial sublining cell staining than OA specimens. Moreover, there was a significant correlation ($r = 0.92$; $P = 0.0001$; Spearman's rank correlation) between the extent and intensity of staining with HBGF-1 antibody and the extent and intensity of mononuclear cell infiltration (assessed on H and E-stained sections) in synovium of RA patients (Fig. 4 B).

HBGF-1 Immunostaining in SCW-Injected Euthymic LEW/N and Athymic LEW.rnu/rnu Rats with Arthritis

The kinetics of positive anti-HBGF-1 immunostaining in the synovium were examined in SCW injected euthymic LEW/N and athymic LEW.rnu/rnu rats. Within 24 h of SCW administration, both rat strains developed erythema and swelling of peripheral joints. Histologically, the acute inflammation,

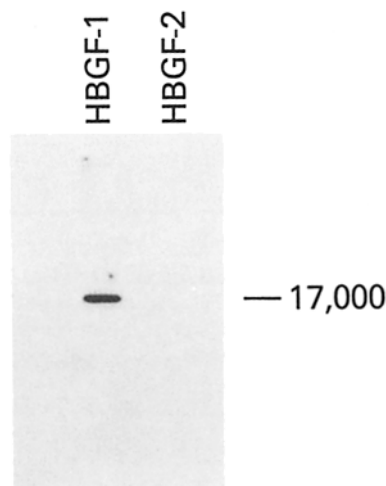


Figure 2. Western blot analysis of affinity-purified antibody against HBGF-1. Recombinant human HBGF-1 and 2 were processed for Western blot as described in the text. The figure shows autoradiogram visualizing proteins that were separated on a 15% polyacrylamide gel, transferred to a nitrocellulose membrane, and probed with affinity-purified HBGF-1 antibody.

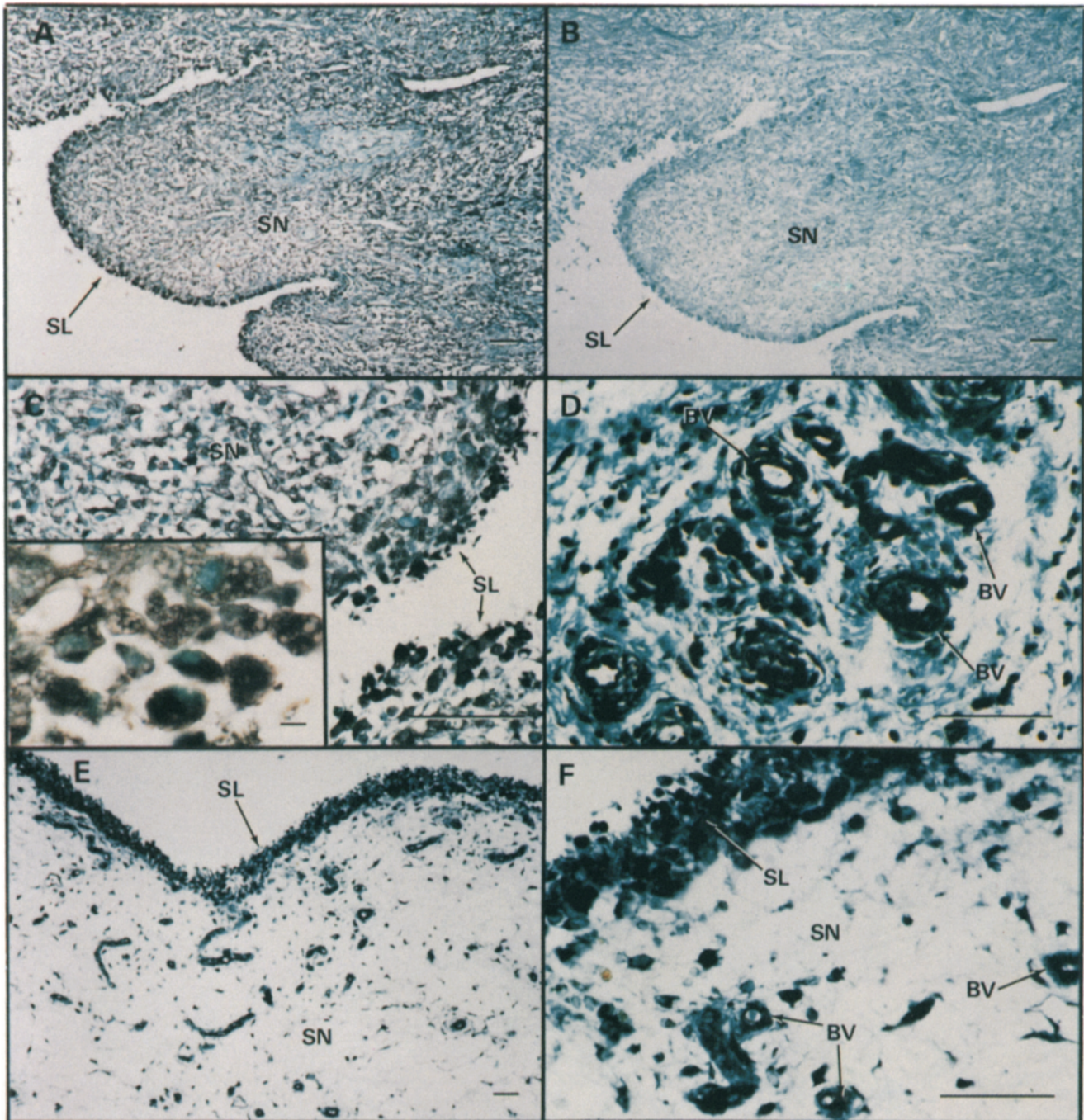


Figure 3. Representative HBGF-1 immunoperoxidase-stained sections of synovium from patients with RA and OA. HBGF-1 was stained using affinity-purified HBGF-1 antibody (50 $\mu\text{g/ml}$) as described in Materials and Methods. Positive staining is indicated by brownish black deposits. Control staining with rabbit IgG or affinity-negative IgG was uniformly negative. *A*, *C*, and *D* Representative RA synovium stained with HBGF-1 antibody. *B* RA synovium stained with rabbit IgG demonstrating negative staining. *E* and *F* Representative OA synovium stained with HBGF-1 antibody. The labels denote synovial lining cell layer (*SL*), sublining stromal tissue cells (*SN*), and blood vessels (*BV*). Bars, (*A-F*) 100 μm ; (*inset*) 10 μm .

which reflects synovial microvascular injury, is characterized by edema, fibrin deposition in the joint space and synovium, and cellular infiltration by granulocytes and macrophages. This initial phase of disease reaches maximal severity at day 3 and substantially subsides over the next week (Wilder et al., 1982; Allen et al., 1985; Wilder et al., 1987).

By day 1 after SCW injection, anti-HBGF-1 staining was readily demonstrated. The synovial lining cell layer, synovial

stromal fibroblast-like cells and blood vessels, perivascular inflammatory cells, chondrocytes and numerous cells within the bone matrix and bone marrow stained intensely (Fig. 5 *B*). The extent and intensity of staining was similar in the euthymic and athymic rats at day 3 (Fig. 5 *C*). Control rats occasionally exhibited weak staining in dispersed cells within the synovium, bone matrix and bone marrow (Fig. 5 *A*).

A thymic-dependent phase of disease develops in eu-

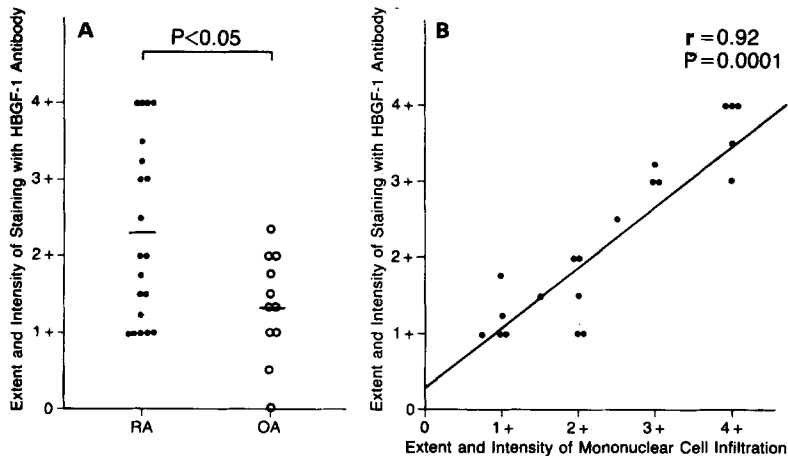


Figure 4. Statistical analysis of HBGF-1 immunostaining in vivo. (A) Extent and intensity of staining with HBGF-1 antibody in synovium from patients with RA and OA. The extent and intensity of staining with HBGF-1 antibody was graded 0–4+ by a blinded observer on synovial specimens from 20 RA and 11 OA patients. HBGF-1 immunostaining was more intense and diffuse in synovium of RA patients (●) than in that of OA patients (○) ($P < 0.05$; Wilcoxon rank-sum test). (B) Correlation between extent and intensity of staining with HBGF-1 antibody and extent and intensity of mononuclear cell infiltration in synovium from patients with RA. The extent and intensity of mononuclear cell infiltration was graded 0–4+ on hematoxylin and eosin sections by a blinded observer. The extent and intensity of staining with HBGF-1 antibody on synovium from 20 RA patients was significantly correlated ($r = 0.92$; $P = 0.0001$; Spearman's rank correlation) to the extent and intensity of mononuclear cell infiltration.

thymic, but not athymic, rats 14–28 d after injection. It is characterized by intense synovial-lining cell proliferation and villus formation, infiltration of the sublining synovial tissue by lymphocytes and macrophages, and proliferation of fibroblast-like cells and blood vessels. Marginal erosions develop during this phase at the junctions of synovium with bone and cartilage, and eventually destroy the more severely involved joints (Wilder et al., 1982; Allen et al., 1985; Wilder et al., 1987).

During the chronic phase, joints from euthymic (Fig. 5, D and E), but not athymic (Fig. 5 F), rats stained intensely with anti-HBGF-1. Staining was noted in the synovial lining cell layer, sublining stromal cells, blood vessels, cartilage chondrocytes, bone matrix cells, and numerous bone marrow cells, as well as ligamentous and tendinous structures. As observed in the rheumatoid tissues, many cells appeared to show nuclear, as well as cytoplasmic staining (Fig. 5 E, *inset*). In addition to the staining of connective tissue and bone, both SCW injected euthymic and athymic rats with arthritis showed intense HBGF-1 staining in the skin. Interestingly, cells in the epidermis, as well as blood vessels and hair follicles in the dermis, stained intensely (Fig. 5 H). Control rats not injected with SCW did not stain with HBGF-1 antibody in the skin (Fig. 5 G).

Immunodetection of the *c-Fos* Polypeptide in Synovium from Patients with RA and OA

Protooncogenes such as *c-myc* are expressed in synovium of rats with SCW arthritis as well as synovium from patients with RA (Case et al., 1989a,b). These genes are usually expressed in cells committed to mitosis or activation (Müller and Wagner, 1984) and play an important role in the control of cell proliferation (Müller et al., 1984; for review, see Johnson and McKnight, 1989). As shown in a representative RA synovial tissue section, extensive and intense *c-Fos* specific nuclear staining was observed within the synovial lining cell layer (Fig. 6, A, C, and D). Prominent *c-Fos* protein staining was also observed in the sublining stromal fibroblast-like cells (Fig. 6, A and C), vascular endothelial cells (Fig. 6 A), and inflammatory cells (Fig. 6, A and C). Control staining with the specific antibody absorbed with a 100×

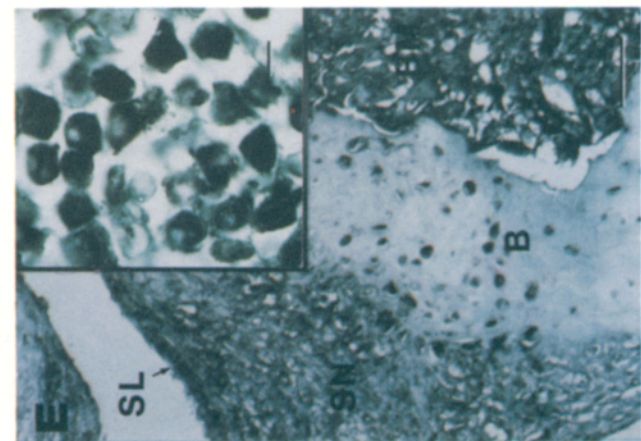
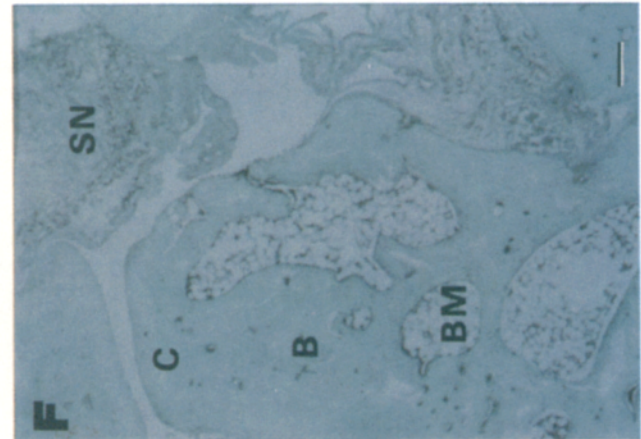
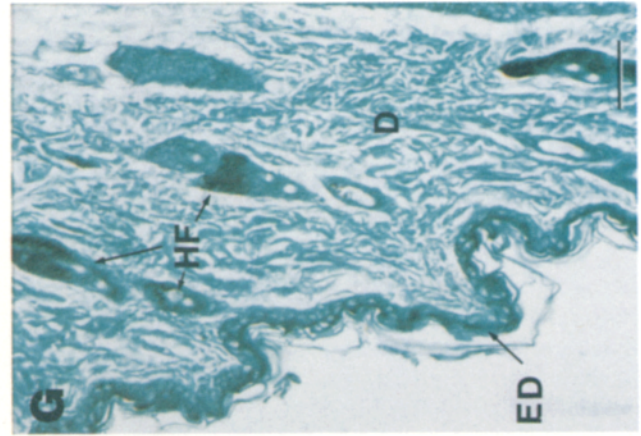
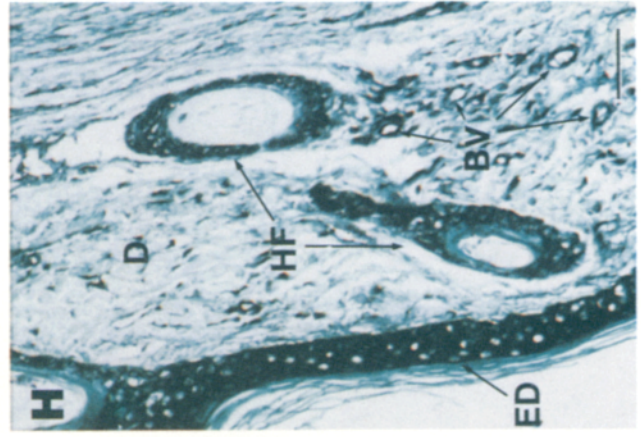
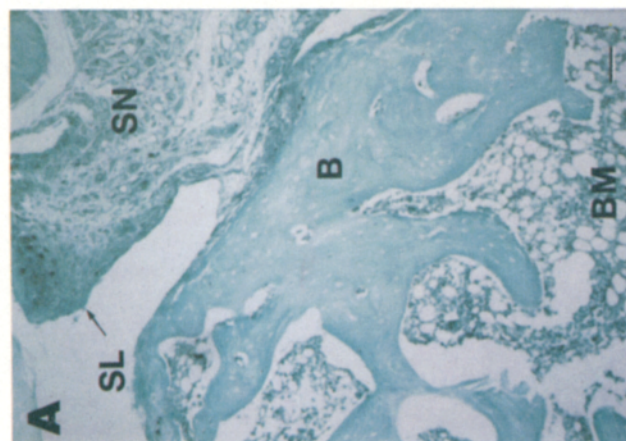
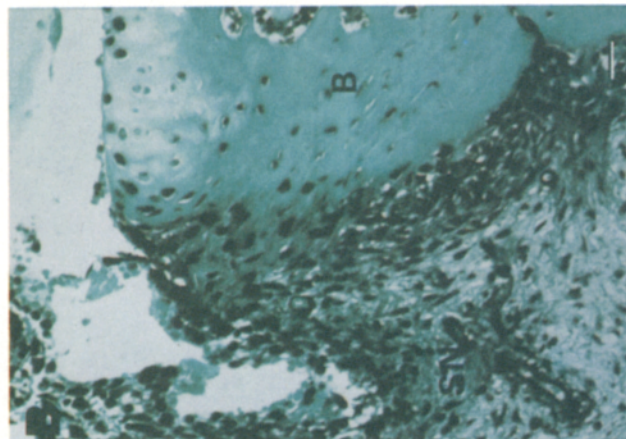
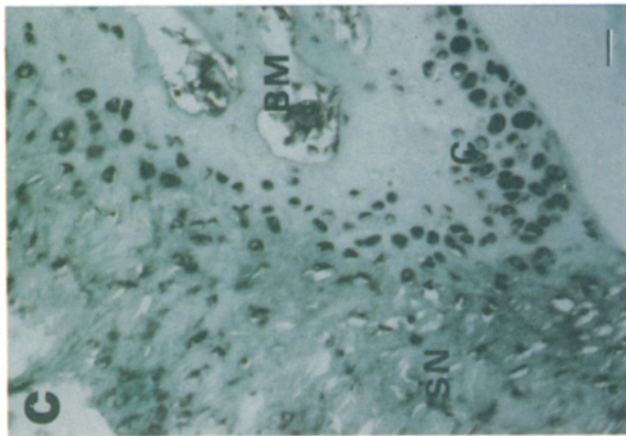
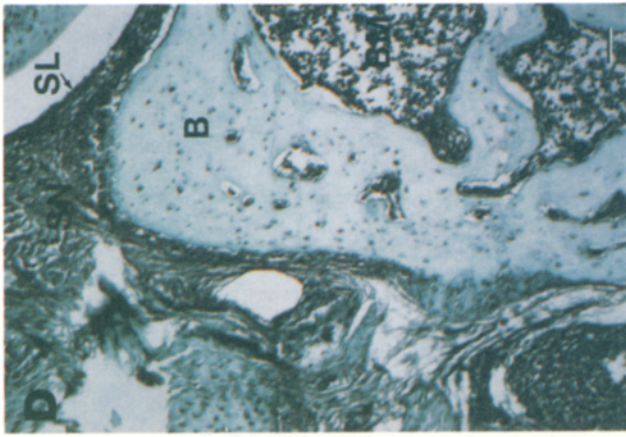
molar excess of the immunogenic peptide (Fig. 6 B) or sheep IgG (Fig. 6 F) was negative in all cases. Synovial tissue sections from patients with OA, in sharp contrast, stained at relatively low levels on the synovial lining cell layer, sublining vascular endothelial cells, and stromal fibroblast-like cells (Fig. 6 E).

Statistical Analysis of *c-Fos* Protein Immunostaining In Vivo

The extent and intensity of staining with anti-*c-Fos* was graded 0–4+ by a blinded observer on 18 RA and 11 OA synovial specimens. The immunostaining with anti-*c-Fos* was more extensive and intense in the synovium of RA patients than in that of OA patients ($P < 0.01$; Wilcoxon rank-sum test) as shown in Fig. 7 A. Moreover, there was a significant correlation ($r = 0.71$, $P = 0.0024$; Spearman's rank correlation) between the extent and intensity of staining and the extent and intensity of mononuclear cell infiltration of RA patients (Fig. 7 B).

Discussion

Although it is generally accepted that the genesis of arthritis involves the complementary interaction between the pathways initiated by the inflammatory response and angiogenesis (Folkman and Klagsbrun, 1987; Folkman, 1989), the molecular basis for the initiation of the angiogenic response has eluded investigators (Maciag, 1989). In this manuscript, we have provided experimental evidence demonstrating high level immunodetection of the angiogenic polypeptide, HBGF-1, in synovium from RA patients (Fig. 3). Immunostaining in OA, a low-grade synovial fibroproliferative joint disease, was much less prominent (Figs. 3 and 4 A). The presence of the HBGF-1 mRNA transcript in RA synovial tissue was confirmed by PCR technique (Fig. 1). Further, we documented the kinetics of anti-HBGF-1 polypeptide staining in an arthritic rat model and demonstrated that the persistent staining of HBGF-1, like the disease itself, was T-cell dependent (Fig. 5). Statistical analysis suggested that the extent and intensity of human HBGF-1 polypeptide immunostaining in RA tissue correlated with the extent and intensity of



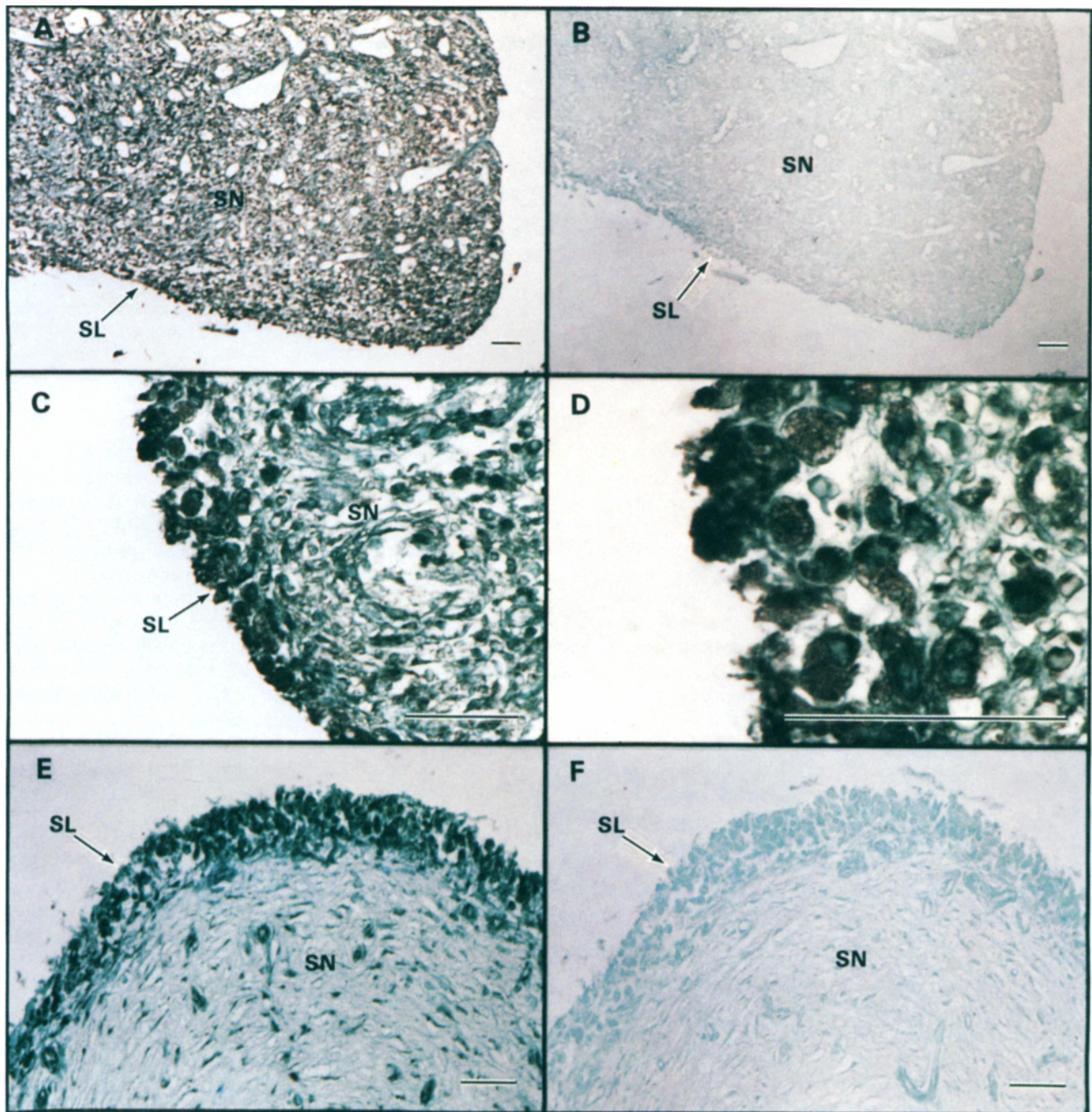


Figure 6. Representative c-Fos immunoperoxidase-stained sections of synovium from patients with RA and OA. c-Fos oncoprotein was stained using affinity-purified anti-c-Fos antibody (25 $\mu\text{g/ml}$) as described in Materials and Methods. Positive staining is indicated by brownish black deposits. Control staining with the specific antibody absorbed with the immunogenic peptide or sheep IgG (25 $\mu\text{g/ml}$) was uniformly negative. (A, C, and D) Representative RA synovium stained with anti-c-Fos antibody. (B) RA synovium stained with anti-c-Fos antibody absorbed with the immunogenic peptide. (E) Representative OA synovium stained with anti-c-Fos antibody. (F) OA synovium stained with sheep IgG. The labels denote synovial lining cell layer (SL) and sublining stromal tissue cells (SN). Bar, 100 μm .

Figure 5. HBGF-1 immunostaining in SCW injected euthymic LEW/N and athymic LEW.rnu/rnu rats. Sections were stained as described in Materials and Methods with affinity-purified HBGF-1 antibody (50 $\mu\text{g/ml}$). Positive staining is indicated by brownish-black deposits. Control staining with affinity-negative IgG or rabbit IgG was uniformly negative. A shows a hindfoot joint from a non-cell wall-injected euthymic LEW/N rat. B shows a representative hindfoot joint from SCW-injected euthymic LEW/N rat with acute arthritis at day 3. C shows a hindfoot joint from a representative SCW injected athymic LEW.rnu/rnu rat with acute arthritis at day 3. D and E show a representative hindfoot joint from SCW-injected euthymic LEW/N rat with chronic arthritis at day 28. (F) Hindfoot joint from a representative SCW injected athymic LEW.rnu/rnu rat without arthritis at day 28. (G and H) Hindfoot skin from a non-cell wall-injected and a SCW-injected euthymic LEW/N rat with chronic arthritis at day 28, respectively. The labels denote cartilage (C), synovial lining cell layer (SL), subsynovial tissue (SN), bone (B), bone marrow (BM), blood vessels (BV), epidermis (ED), dermis (D), and hair follicle (HF). Bars, (A-H) 100 μm ; (inset) 10 μm .

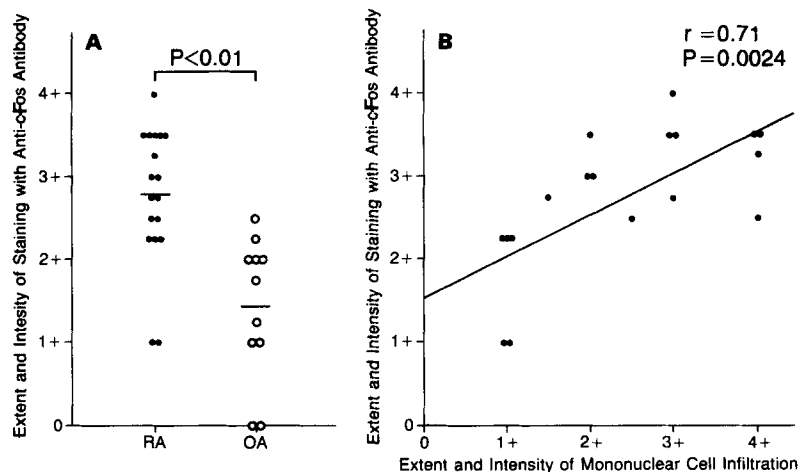


Figure 7. Statistical analysis of *c-Fos* protein immunostaining in vivo. (A) Extent and intensity of staining with anti-*c-Fos* antibody in synovium from 18 RA and 11 OA patients: *c-Fos* protein immunostaining was more extensive and intense in synovium of RA patients (●) than in that of OA patients (○) ($P < 0.01$; Wilcoxon rank-sum test). (B) Correlation between extent and intensity of staining with anti-*c-Fos* antibody and extent and intensity of mononuclear cell infiltration in synovium from patients with RA. The extent and intensity of staining with anti-*c-Fos* antibody on synovium from 18 RA patients was significantly correlated ($r = 0.71$; $P = 0.0024$; Spearman's rank correlation) to the extent and intensity of mononuclear cell infiltration.

the inflammatory response as measured by mononuclear cell infiltration in the synovium (Fig. 4 B).

The synovium in RA tissue and in the experimental animal model, LEW/N rat SCW-induced arthritis, is characterized by exuberant hypertrophy and hyperplasia of the normally thin, delicate synovium, resulting primarily from proliferation of stromal fibroblast-like mesenchymal cells (synoviocytes) and new blood vessels. These cells, as well as macrophages and osteoclasts, are the predominant cell populations at the sites of cartilage resorption and bone erosion in diseased joints, where they directly mediate articular destruction (Bromley and Woolley, 1984a; Yocum et al., 1988). The observations that freshly explanted synoviocytes from rheumatoid and SCW arthritic joints (a) proliferate rapidly in vitro; (b) do not undergo contact inhibition, but rather form foci; and (c) grow under anchorage-independent conditions (Yocum et al., 1988; Lafyatis et al., 1989a), support the suggestion that the aggressive invasiveness of the highly proliferative lesion resembles a localized, nonmetastatic neoplasm (Harris, 1976; Fassbender, 1983; Hamilton, 1983; Haraoui et al., 1985; Wilder et al., 1987; Yocum et al., 1988). Moreover, synovial tissues from both patients with RA (Brinckerhoff and Harris, 1981) and rats with SCW arthritis (Yocum et al., 1988) form short-lived tumorlike nodules when implanted in nude, athymic mice. These data suggest that synoviocytes may exhibit properties generally associated with malignant tumor cells.

Since growth of tumors depends on angiogenesis (Folkman, 1989) and angiogenesis is a central feature of synovial lesions in RA (Folkman and Klagsbrun, 1987) and SCW arthritis in the rat (Yocum et al., 1988), we reasoned that angiogenic polypeptide growth factors may be present at high levels in these tissues. The HBGF family of peptides has gained general acceptance as initiators of angiogenesis, notably during development (Folkman and Klagsbrun, 1987; Burgess and Maciag, 1989). Because anti-HBGF-1 staining correlated with severity of the inflammatory process, as reflected by the extent and intensity of mononuclear cell infiltration, we suggest that HBGF-1 may participate in the induction of neovascularization in the synovia of patients with RA and rats with SCW arthritis. Alternatively, since other polypeptide growth factors and cytokines induce angiogenesis in vivo (Folkman and Klagsbrun, 1987), these agents may also participate in the arthritic process.

Protooncogenes such as *c-myc* are expressed at high levels in synovium from RA and rats with SCW arthritis, compared to OA or normal rat synovium, respectively (Case et al., 1989a,b). In addition, we have also shown in the present study that anti-*c-Fos* staining in synovium from RA patients is more intense than synovium from OA patients (Fig. 6 and 7). Interestingly, HBGF-1 induces *c-myc* and *c-fos* expression in fibroblast cultures (Müller et al., 1984) and *c-fos* and *c-myc* play a prominent role in cellular growth and differentiation (Johnson and McKnight, 1989). Moreover, the HBGF prototypes stimulate tyrosine kinase activity (Coughlin et al., 1988; Friesel et al., 1989) and may therefore play a role in the stimulation of rheumatoid synovial stromal fibroblast-like mesenchymal cell proliferation and angiogenesis through the induction of protooncogenes such as *c-myc* and *c-fos*.

HBGF-1 also induces high levels of both plasminogen activator and collagenase activities in capillary endothelial cells in vitro (Gross et al., 1983; Moscatelli and Rifkin, 1988) and potentiates interleukin-1-induced collagenase production in chondrocytes (Chandrasekhar and Harvey, 1989). The expression of plasminogen activator and collagenase is elevated in the synovium of RA patients and SCW rats (Dayer et al., 1976; Decker et al., 1984). Thus, we suggest that the expression of these proteolytic enzymes during the genesis of RA and SCW arthritis (Hamilton, 1983; Decker et al., 1984) is regulated, in part, by HBGF-1.

Enhanced HBGF-1 immunostaining developed early in both T-cell competent and incompetent LEW rats, but persistent high level staining of HBGF-1 was T-cell dependent, as is the disease process in general (Fig. 5). The induction of acute arthritis is not T-cell dependent, whereas the induction of chronic arthritis is T-cell dependent (Wilder et al., 1987). It is noteworthy that HBGF-1 was immunolocalized in cells throughout the diseased extremities of arthritic rats including bone marrow, bone, cartilage, synovium, and ligamentous and tendinous structures (Fig. 5, B-E). Surprisingly, we also observed significant HBGF-1 polypeptide immunostaining in the skin of the arthritic rats (Fig. 5 H). These observations serve as an alternative control for the immunohistochemical analysis because HBGF-1 staining in the rat before the induction of arthritis was minimal at best. However, 28 d after the initiation of arthritis, HBGF-1 staining remained readily visible in the skin; an observation that parallels the staining of

HBGF-1 in the arthritic joints. Interestingly, the presence of HBGF-1 in the epidermis is consistent with the observation that HBGF-1 can stimulate the proliferation of keratinocytes in vitro (Fourtanier et al., 1986; Shipley et al., 1989). Further, these observations implicate HBGF-1 in the physiology of dermal blood vessels, hair follicles, and keratinocytes and suggest that HBGF-1 may also play a role in dermal wound and ulcer healing, hair growth and reepithelization in vivo.

The apparent presence of HBGF-1 within the nucleus of a wide variety of cells in situ is also noteworthy. At the present time, we do not know the significance of nuclear HBGF-1 or the mechanism by which nuclear translocation is achieved. However, HBGF-2 has been detected using immunological methods in the nucleus (Bouche et al., 1987), and HBGF-1 (Friesel and Maciag, 1988) and HBGF-2 (Moscatelli, 1988) remain structurally intact for relatively long periods of time following receptor-mediated endocytosis in vitro. Further, the detection of HBGF-1 as a predominantly intracellular polypeptide is consistent with the signal peptide-less structure of the HBGF-1 precursor (Jaye et al., 1986). It is possible that HBGF-1 was also associated with the extracellular matrix but was in form not readily accessible to immunological detection. HBGF-2 has been detected in the extracellular matrix in vitro and in vivo (Vlodavsky et al., 1987; Moscatelli and Rifkin, 1988; Folkman et al., 1988) and heparin protects HBGF-2 from proteolytic modification (Saksela et al., 1988) in a manner similar to the protection afforded HBGF-1 (Rosengart et al., 1988). Our data do not completely eliminate the possibility that HBGF-1 is present within the extracellular matrix (especially next to blood vessels where the intensity of staining may mask this detail). However, our data demonstrate that HBGF-1 does not reside in the basement membrane. In addition, HBGF-2 has been detected in macrophages (Baird et al., 1985), and we observed the presence of HBGF-1 as an intracellular polypeptide in mononuclear cells within the human RA and rat SCW arthritic tissue in vivo. Thus, while it is possible that the intracellular HBGF-1 detected by our antibody may be derived from the translation of the HBGF-1 mRNA transcript and/or proteolytic extraction from sites within the extracellular matrix, the exaggerated immunostaining of HBGF-1 in the mononuclear cell infiltrate suggests that HBGF-1 may also be delivered to the inflammatory site by these cells.

We would like to thank Ms. Sally Young for help in manuscript preparation. We would like to thank Drs. Hereward Cattell, Patrick Caufield, Anthony Unger, Edward Bieber, Lewis Ottenritter, and Randall Lewis for their help in obtaining synovial tissues. We also gratefully acknowledge Drs. Robert Lafyatis, Elaine F. Remmers, and Mr. Gregory K. Kumkumian for their suggestions and critical review of manuscript.

J. A. M. Maier was supported by a fellowship from the Associazione Italiana per la Ricerca sul Cancro. This work was supported in part by U.S. Public Health Service Grants HL 32348 and HL 32627 and Grant-in-Aid 881281 from the American Heart Association Maryland Affiliate to T. Maciag. This work was performed in partial fulfillment of the requirement for the Ph.D. from the Genetics Graduate Group (R. Forough) and Department of Biochemistry (K. Engleka), George Washington University, Washington, DC.

Received for publication 14 June 1989 and in revised form 10 October 1989.

References

Allen, J. B., D. G. Malone, S. M. Wahl, G. B. Calandra, and R. L. Wilder.

1985. Role of the thymus in streptococcal cell wall-induced arthritis and hepatic granuloma formation: comparative studies of pathology and cell wall distribution in athymic and euthymic rats. *J. Clin. Invest.* 76:1042-1056.
- Arnett, F. C., S. M. Edworthy, D. A. Bloch, D. J. McShane, J. F. Fries, N. S. Cooper, L. A. Healey, S. R. Kaplan, M. H. Liang, H. S. Luthra, T. A. Medsger, Jr., D. M. Mitchell, D. H. Neustadt, R. S. Pinals, J. G. Schaller, J. T. Sharp, R. L. Wilder, and G. G. Hunder. 1988. The American Rheumatism Association 1987 revised criteria for the classification of rheumatoid arthritis. *Arthritis Rheum.* 31:315-324.
- Baird, A., F. Esch, D. Gospodarowicz, and R. Guillemin. 1985. Retina- and eye-derived endothelial cell growth factors: partial molecular characterization and identity with acidic and basic fibroblast growth factors. *Biochemistry.* 24:7855-7860.
- Bouche, G., N. Gas, H. Prats, V. Baldin, J.-P. Tauber, J. Teissie, and F. Amalric. 1987. Basic fibroblast growth factor enters the nucleolus and stimulates the transcription of ribosomal genes in ABAE cells undergoing G₀ to G₁ transition. *Proc. Natl. Acad. Sci. USA.* 84:6770-6774.
- Brinckerhoff, C. E., and E. D. Harris. 1981. Survival of rheumatoid synovium implanted into nude mice. *Am. J. Pathol.* 103:411-418.
- Bromley, M., and D. E. Woolley. 1984a. Histopathology of the rheumatoid lesion; identification of cell types at sites of cartilage erosion. *Arthritis Rheum.* 27:857-863.
- Bromley, M., and D. E. Woolley. 1984b. Chondroclasts and osteoclasts at subchondral sites of erosion in the rheumatoid joint. *Arthritis Rheum.* 27:968-975.
- Burgess, W. H., and T. Maciag. 1989. The heparin-binding (fibroblast) growth factor family of proteins. *Annu. Rev. Biochem.* 58:575-606.
- Burgess, W. H., T. Mehlman, D. R. Marshall, B. A. Fraser, and T. Maciag. 1986. Structural evidence that endothelial cell growth factor β is the precursor of both endothelial cell growth factor α and acidic fibroblast growth factor. *Proc. Natl. Acad. Sci. USA.* 83:7216-7220.
- Canalis, E., J. Lorenzo, W. H. Burgess, and T. Maciag. 1987. Effects of endothelial cell growth factor on bone remodelling in vitro. *J. Clin. Invest.* 79:52-58.
- Case, J. P., H. Sano, R. Lafyatis, E. F. Remmers, G. K. Kumkumian, and R. L. Wilder. 1989a. Transin/stromelysin expression in the synovium of rats with experimental erosive arthritis: in situ localization and kinetics of expression of the transformation-associated metalloproteinase in euthymic and athymic Lewis rats. *J. Clin. Invest.* 84:1731-1740.
- Case, J. P., R. Lafyatis, E. F. Remmers, G. K. Kumkumian, and R. L. Wilder. 1989b. Transin/stromelysin expression in rheumatoid synovium: a transformation-associated metalloproteinase secreted by phenotypically invasive synoviocytes. *Am. J. Pathol.* 135:1055-1064.
- Chandrasekhar, S., and A. K. Harvey. 1989. Induction of interleukin-1 receptors on chondrocytes by fibroblast growth factor: a possible mechanism for modulation of interleukin-1 activity. *J. Cell. Physiol.* 138:236-246.
- Chomczynski, P., and N. Sacchi. 1987. Single-step method of RNA isolation by acid guanidinium thiocyanate-phenol-chloroform extraction. *Anal. Biochem.* 162:156-159.
- Coughlin, S. R., P. J. Barr, L. S. Cousens, L. J. Fretto, and L. T. Williams. 1988. Acid and basic fibroblast growth factors stimulate tyrosine kinase activity in vivo. *J. Biol. Chem.* 263:988-993.
- Dayer, J.-M., S. M. Krane, R. G. G. Russell, and D. R. Robinson. 1976. Production of collagenase and prostaglandins by isolated adherent rheumatoid synovial cells. *Proc. Natl. Acad. Sci. USA.* 73:945-949.
- Decker, J. L., D. G. Malone, B. Harauoi, S. M. Wahl, L. Schrieber, J. H. Klippel, A. D. Steinberg, and R. L. Wilder. 1984. Rheumatoid arthritis: evolving concepts of pathogenesis and treatment. *Ann. Intern. Med.* 101:810-824.
- Delli Bovi, P., A. M. Curatola, F. G. Kern, A. Greco, M. Ittmann, and C. Basilio. 1987. An oncogene isolated by transfection of Kaposi's sarcoma DNA encodes a growth factor that is a member of the FGF family. *Cell.* 50:729-737.
- Dickson, C., and G. Peters. 1987. Potential oncogene product related to growth factors. *Nature (Lond.).* 326:833.
- Fassbender, H. G. 1983. Histomorphological basis of articular cartilage destruction in rheumatoid arthritis. *Collagen Relat. Res.* 3:141-155.
- Finch, P. W., J. S. Rubin, T. Miki, D. Ron, and S. A. Aaronson. 1989. Human KGF is FGF-related with properties of a paracrine effector of epithelial cell growth. *Science (Wash.).* 245:752-755.
- Folkman, J. 1989. Successful treatment of an angiogenic disease. *N. Engl. J. Med.* 320:1211-1212.
- Folkman, J., and M. Klagsbrun. 1987. Angiogenic factors. *Science (Wash.).* 235:442-447.
- Folkman, J., M. Klagsbrun, J. Sasse, M. Wadzinski, D. Ingber, and I. Vlodavsky. 1988. A heparin-binding angiogenic protein - basic fibroblast growth factor - is stored within basement membrane. *Am. J. Pathol.* 130:393-400.
- Fourtanier, A. Y., J. Courty, E. Muller, Y. Courtois, M. Prunieras, and D. Barritault. 1986. Eye-derived growth factor isolated from bovine retina and used for epidermal wound healing in vivo. *J. Invest. Dermatol.* 87:76-80.
- Friesel, R., and T. Maciag. 1988. Internalization and degradation of heparin binding growth factor-I by endothelial cells. *Biochem. Biophys. Res. Commun.* 151:957-964.
- Friesel, R., W. H. Burgess, and T. Maciag. 1989. Heparin-binding growth

- factor-1 stimulates tyrosine phosphorylation in NIH 3T3 cells. *Mol. Cell Biol.* 9:1857-1865.
- Gautschi-Sova, P., T. Müller, and P. Böhlen. 1986. Amino acid sequence of human acidic fibroblast growth factor. *Biochem. Biophys. Res. Commun.* 140:874-880.
- Gautschi-Sova, P., Z.-P. Jiang, M. Fäter-Schröder, and P. Böhlen. 1987. Acidic fibroblast growth factor is present in nonneural tissue: isolation and chemical characterization from bovine kidney. *Biochemistry.* 26:5844-5847.
- Gimenez-Gallego, G., J. Rodkey, C. Bennett, M. Rios-Candelore, J. DiSalvo, and K. Thomas. 1985. Brain-derived acidic fibroblast growth factor: complete amino acid sequence and homologies. *Science (Wash.).* 230:1385-1388.
- Gross, J. L., D. Moscatelli, and D. B. Rifkin. 1983. Increased capillary endothelial cell protease activity in response to angiogenic stimuli *in vitro*. *Proc. Natl. Acad. Sci. USA.* 80:2623-2627.
- Hamilton, J. A. 1983. Hypothesis: *in vitro* evidence for the invasive and tumorlike properties of the rheumatoid pannus. *J. Rheumatol.* 10:845-851.
- Hararoui, B., R. L. Wilder, J. B. Allen, M. B. Sporn, R. K. Helfgott, and C. E. Brinckerhoff. 1985. Dose-dependent suppression by the synthetic retinoid, 4-hydroxyphenyl retinamide, of streptococcal cell wall-induced arthritis in rats. *Int. J. Immunopharmacol.* 7:903-916.
- Harris, E. D., Jr. 1976. Recent insights into the pathogenesis of the proliferative lesion in rheumatoid arthritis. *Arthritis Rheum.* 19:68-72.
- Hauschka, P. V., A. E. Mavrakos, M. D. Iafrati, S. E. Doleman, and M. Klagsbrun. 1986. Growth factors in bone matrix: isolation of multiple types by affinity chromatography on heparin-sepharose. *J. Biol. Chem.* 261:12665-12674.
- Hsu, S.-M., and H. J. Ree. 1980. Self-sandwich method: an improved immunoperoxidase technique for the detection of small amounts of antigens. *Am. J. Clin. Pathol.* 74:32-40.
- Hsu, S.-M., L. Raine, and H. Fanger. 1981. Use of avidin-biotin-peroxidase complex (ABC) in immunoperoxidase techniques: a comparison between ABC and unlabeled antibody (PAP) procedures. *J. Histochem. Cytochem.* 29:577-580.
- Jaye, M., R. Howk, W. Burgess, G. A. Ricca, I.-M. Chiu, M. W. Ravera, S. J. O'Brien, W. S. Modi, T. Maciag, and W. N. Drohan. 1986. Human endothelial cell growth factor: cloning, nucleotide sequence, and chromosome localization. *Science (Wash.).* 233:541-545.
- Johnson, P. F., and S. L. Mcknight. 1989. Eukaryotic transcriptional regulatory proteins. *Annu. Rev. Biochem.* 58:799-839.
- Johnstone, A., and R. Thorpe. 1987. Immunohistochemistry in Practice. Blackwell Scientific Publications, Boston. 306 pp.
- Lafyatis, R., E. F. Remmers, A. B. Roberts, D. E. Yocum, M. B. Sporn, and R. L. Wilder. 1989a. Anchorage-independent growth of synoviocytes from arthritic and normal joints: stimulation by exogenous platelet-derived growth factor and inhibition by transforming growth factor-beta and retinoids. *J. Clin. Invest.* 83:1267-1276.
- Lafyatis, R., N. L. Thompson, E. F. Remmers, K. C. Flanders, N. S. Roche, S.-J. Kim, J. P. Case, M. B. Sporn, A. B. Roberts, and R. L. Wilder. 1989b. Transforming growth factor- β production by synovial tissues from rheumatoid patients and streptococcal cell wall arthritic rats: studies on secretion by synovial fibroblast-like cells and immunohistologic localization. *J. Immunol.* 143:1142-1148.
- Lerner, E. A. 1981. How to make a hybridoma. *Yale J. Biol. Med.* 54:387-402.
- Lobb, R. R., J. W. Harper, and J. W. Fett. 1986. Purification of heparin-binding growth factors. *Anal. Biochem.* 154:1-14.
- Maciag, T. 1989. Molecular and cellular mechanisms of angiogenesis. In *Advances in Oncology: Cancer: Principles and Practice of Oncology*. 3rd ed. V. T. DeVita, S. Hellman, and S. A. Rosenberg, editors. J. B. Lippincott Co., Philadelphia. In press.
- Marics, I., J. Adelaide, F. Raybaud, M.-G. Mattei, F. Coulier, J. Planche, O. de Lapeyriere, and D. Birnbaum. 1989. Characterization of the HST-related FGF.6 gene, a new member of the fibroblast growth factor gene family. *Oncogene.* 4:335-340.
- Moscatelli, D. 1988. Metabolism of receptor-bound and matrix-bound basic fibroblast growth factor by bovine capillary endothelial cells. *J. Cell. Biol.* 107:753-759.
- Moscatelli, D., and D. B. Rifkin. 1988. Membrane and matrix localization of proteinases: a common theme in tumor cell invasion and angiogenesis. *Biochim. Biophys. Acta.* 948:67-85.
- Müller, R., and E. F. Wagner. 1984. Differentiation of F9 teratocarcinoma stem cells after transfer of *c-fos* proto-oncogenes. *Nature (Lond.).* 311:438-442.
- Müller, R., R. Bravo, J. Burckhardt, and T. Curran. 1984. Induction of *c-fos* gene and protein by growth factors precedes activation of *c-myc*. *Nature (Lond.).* 312:716-720.
- Remington, R. D., and M. A. Schork. 1985. *Statistics with Applications to the Biological and Health Sciences*. Prentice-Hall, Inc., New Jersey. 415 pp.
- Remmers, E. F., R. Lafyatis, G. K. Kumkumian, J. P. Case, A. B. Roberts, M. B. Sporn, and R. L. Wilder. 1989. Cytokines and growth regulation of synoviocytes from patients with rheumatoid arthritis and streptococcal cell wall arthritis. *Growth Factors*. In press.
- Rodan, S. B., G. Wesolowski, K. Thomas, and G. A. Rodan. 1987. Growth stimulation of rat calvaria osteoblastic cells by acidic fibroblast growth factor. *Endocrinology.* 121:1917-1923.
- Rosengart, T. K., W. V. Johnson, R. Friesel, R. Clark, and T. Maciag. 1988. Heparin protects heparin-binding growth factor-I from proteolytic inactivation *in vitro*. *Biochem. Biophys. Res. Commun.* 152:432-440.
- Saiki, R. K., D. H. Gelfand, S. Stoffel, S. J. Scharf, R. Higuchi, G. T. Horn, K. B. Mullis, and H. A. Erlich. 1988. Primer-directed enzymatic amplification of DNA with a thermostable DNA polymerase. *Science (Wash.).* 239:487-491.
- Saksela, O., D. Moscatelli, A. Sommer, and D. B. Rifkin. 1988. Endothelial cell-derived heparan sulfate binds basic fibroblast growth factor and protects it from proteolytic degradation. *J. Cell. Biol.* 107:743-751.
- Shipley, G. D., W. W. Keeble, J. E. Hendrickson, R. J. Coffey, Jr., and M. R. Pittelkow. 1989. Growth of normal human keratinocytes and fibroblasts in serum-free medium is stimulated by acidic and basic fibroblast growth factor. *J. Cell. Physiol.* 138:511-518.
- Stoflet, E. S., D. D. Koeberl, G. Sarkar, and S. S. Sommer. 1988. Genomic amplification with transcript sequencing. *Science (Wash.).* 239:491-494.
- Taira, M., T. Yoshida, K. Miyagawa, H. Sakamoto, M. Terada, and T. Sugimura. 1987. cDNA sequence of human transforming gene *hst* and identification of the coding sequence required for transforming activity. *Proc. Natl. Acad. Sci. USA.* 84:2980-2984.
- Thomas, K. A. 1987. Fibroblast growth factors. *FASEB (Fed. Am. Soc. Exp. Biol.) J.* 1:434-440.
- Thomas, K. A., M. Rios-Candelore, and S. Fitzpatrick. 1984. Purification and characterization of acidic fibroblast growth factor from bovine brain. *Proc. Natl. Acad. Sci. USA.* 81:357-361.
- Thompson, J. A., K. D. Anderson, J. M. DiPietro, J. A. Zwiebel, M. Zametta, W. F. Anderson, and T. Maciag. 1988. Site-directed neovessel formation *in vivo*. *Science (Wash.).* 241:1349-1352.
- Towbin, H., T. Staehelin, and J. Gordon. 1979. Electrophoretic transfer of proteins from polyacrylamide gels to nitrocellulose sheets: Procedure and some applications. *Proc. Natl. Acad. Sci. USA.* 76:4350-4354.
- van Straaten, F., R. Müller, T. Curran, C. van Beveren, and I. M. Verma. 1983. Complete nucleotide sequence of a human *c-onc* gene: Deduced amino acid sequence of the human *c-fos* protein. *Proc. Natl. Acad. Sci. USA.* 80:3183-3187.
- Vlodavsky, I., J. Folkman, R. Sullivan, R. Fridman, R. Ishai-Michaeli, J. Sasse, and M. Klagsbrun. 1987. Endothelial cell-derived basic fibroblast growth factor: synthesis and deposition into subendothelial extracellular matrix. *Proc. Natl. Acad. Sci. USA.* 84:2292-2296.
- Wilder, R. L., G. B. Calandra, A. J. Garvin, K. D. Wright, and C. T. Hansen. 1982. Strain and sex variation in the susceptibility to streptococcal cell wall-induced polyarthritis in the rat. *Arthritis Rheum.* 25:1064-1072.
- Wilder, R. L., J. B. Allen, and C. Hansen. 1987. Thymus-dependent and independent regulation of Ia antigen expression *in situ* by cells in the synovium of rats with streptococcal cell wall-induced arthritis: differences in site and intensity of expression in euthymic, athymic, and cyclosporin A-treated LEW and F344 rats. *J. Clin. Invest.* 79:1160-1171.
- Yocum, D. E., R. Lafyatis, E. F. Remmers, H. R. Schumacher, and R. L. Wilder. 1988. Hyperplastic synoviocytes from rats with streptococcal cell wall-induced arthritis exhibit a transformed phenotype that is thymic-dependent and retinoid inhibitable. *Am. J. Pathol.* 132:38-48.
- Zhan, X., B. Bates, X. Hu, and M. Goldfarb. 1988. The human FGF-5 oncogene encodes a novel protein related to fibroblast growth factors. *Mol. Cell. Biol.* 8:3487-3495.