



Review

Cardiomyopathies in China: A 2018–2019 state-of-the-art review

Tian-Rui Hua, Shu-Yang Zhang*

Department of Cardiology, Peking Union Medical College Hospital, Chinese Academy of Medical Sciences and Peking Union Medical College, Beijing 100730, China

Received 29 March 2020
Available online 5 July 2020

Abstract

Cardiomyopathies are diseases of the cardiac muscle and are often characterized by ventricular dilation, hypertrophy, and cardiac arrhythmia. Patients with cardiomyopathies often experience sudden death and cardiac failure and require cardiac transplantation during the course of disease progression. Early diagnosis, differential diagnosis, and genetic consultation depend on imaging techniques, genetic testing, and new emerging diagnostic tools such as serum biomarkers. The molecular genetics of cardiomyopathies has been widely studied recently. The discovery of mechanisms underlying heterogeneity and overlapping of the phenotypes of cardiomyopathies has revealed the existence of disease modifiers, and this has led to the emergence of novel disease-modifying therapy. This 2018–2019 state-of-the-art review outlines the pathogenesis, diagnosis, and treatment of cardiomyopathies in China.

© 2020 Chinese Medical Association. Production and hosting by Elsevier B.V. on behalf of KeAi Communications Co., Ltd. This is an open access article under the CC BY-NC-ND license (<http://creativecommons.org/licenses/by-nc-nd/4.0/>).

Keywords: Cardiomyopathies; Genetics; Heart failure

Introduction

Cardiomyopathies are diseases of the cardiac muscle; they occur in all age groups and are caused by electrical or mechanical dysfunction. The World Health Organization classifies cardiomyopathies as dilated cardiomyopathy (DCM), hypertrophic cardiomyopathy (HCM), restrictive cardiomyopathy (RCM),

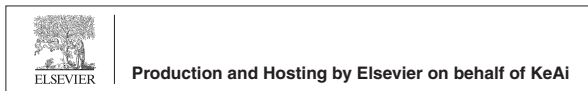arrhythmogenic right ventricular cardiomyopathy (ARVC), and unclassified cardiomyopathies on the basis of the dominant pathophysiology or etiological and pathogenetic factors.¹ Genetic basis has been widely noted in cardiomyopathies ever since the first gene causing hypertrophic cardiomyopathy was identified 30 years ago. Further, substantial heterogeneity and overlapping between and within groups of cardiomyopathies suggest that gene mutations as well as disease modifiers and the environment play important roles in disease development. Genetic and clinical studies have shed light on the underlying mechanisms and raised expectations in terms of the advanced management of cardiomyopathies.

Chinese researchers began to focus on familial cardiomyopathies in the 1990s, and the first genetic

* Corresponding author.

E-mail address: shuyangzhang103@nrdrs.org (S.-Y. Zhang).

Peer review under responsibility of Chinese Medical Association.



linkage analysis was published in 1996.^{2,3} Currently, in terms of the relevant research, China is on the same wavelength as the international cardiovascular research community and is in fact leading in some domains. This state-of-the-art review aims to summarize our current understanding of and treatment paradigm for cardiomyopathies.

Dilated cardiomyopathy

DCM is the most common type of cardiomyopathy, with a disease prevalence of approximately 1:250.⁴ It is characterized by left or biventricular dilatation and systolic dysfunction without coronary artery disease, hypertension, valvular disease, or congenital heart disease and can lead to substantial morbidity and mortality owing to complications such as cardiac failure and arrhythmia.

Pathogenesis

Genetics

The etiology of DCM can be genetic, acquired, or mixed. Common etiologies include genetic mutations, infections, inflammation, exposure to toxins, and endocrine or neuromuscular causes, with genetic and idiopathic DCM being the most commonly reported. Cohort studies have established that 30%–50% of patients with idiopathic DCM may be diagnosed with pathogenic or likely pathogenic variants.⁵ The genes most commonly known to cause DCM in Han Chinese patients (*TTN*, *LMNA*, *RBM20*, *NEXN*, etc.) were identified in large DCM pedigrees (Table 1).⁵ Studies evaluating Chinese families have recently reported several novel genes and variations associated with DCM, including *MEF2C*, *HAND2*, *ZBTB17*, *ISL1*, *KLF5*, *CASZ1*, etc.^{6–10} Basic studies have been conducted based on novel gene reporting to deepen our understanding of the pathogenesis of DCM. Myocardial fibrosis and ventricular remodeling stand as the fundamental pathological changes observed in DCM. An *in vivo* study investigated the role of *LTBP2* in these processes.¹¹ Lamin A/C (*LMNA*) mutation causes not only DCM but also heart block. The mechanism underlying *LMNA* nonsense mutation-induced cardiac conduction defects through atrioventricular (AV) node fibrosis is upregulated extracellular matrix gene expression upon activation of cardiac apoptosis; this explains heart block in *LMNA* mutation-carrying DCM patients.¹² D₅ dopamine receptor (D5R) has been suggested to participate in cardiac function regulation. Compared to hD5^{WT}-TG mice, cardiac-specific hD5^{F173L}-TG mice presented with

DCM and increased expression of cardiac injury markers. D5R may play an important role in the preservation of normal cardiac functions by inhibiting reactive oxygen species (ROS) production, nicotinamide adenine dinucleotide phosphate (NADPH) oxidase activity, nuclear factor erythroid 2-related factor 2 (Nrf2) degradation, and extracellular signal-regulated kinase 1/2/c-Jun N-terminal kinase (ERK1/2/JNK) pathways.¹³ Cardiac lipoprotein receptor-related protein 6 (LRP6) deficiency reportedly suppresses autophagic degradation and fatty acid utilization and subsequently leads to lethal DCM and cardiac dysfunction via the activation of the dynamin-related protein 1/carnitine palmitoyltransferase 1b pathway with c-Myc involved. Furthermore, LRP6 expression was dramatically decreased in patients with end-stage DCM, indicating that heart failure progression may be attenuated by the therapeutic modulation of LRP6 expression.^{14,15} Another study reported that besides dynamin-related protein 1 downregulation, mitofusin-2 upregulation maintains cardiac mitochondrial function and is a safe strategy for correcting excessive cardiac mitochondrial fragmentation.¹⁶ Mitochondrial protein homeostasis and mitochondrial function play essential roles in maintaining myocardial function.¹⁷ Cardiac-specific deletion of the mitochondrial acyl carrier protein *NDUFAB1* in mice causes defective bioenergetics and elevates ROS levels, leading to progressive dilated cardiomyopathy and eventual cardiac failure and sudden death. A recent study revealed that *NDUFAB1* serves as a complex I subunit and coordinates the assembly of respiratory complexes I, II, and III and supercomplexes, serving as a crucial regulator of mitochondrial energy and ROS metabolism.¹⁸

Variant curation is challenging in DCM-associated genes. A recent study demonstrated that gene polymorphisms could contribute to the causality of DCM. Differences in the statistical distribution of synonymous polymorphisms between DCM patients and controls were addressed according to genotype and allele distribution.¹⁹

Recent studies have suggested that long non-coding RNA (lncRNA) can directly interact with microRNA (miRNA) and indirectly interact with mRNA, playing important roles in the pathogenesis of cardiac diseases. An *ex vivo* study reconstructed and analyzed the lncRNA–miRNA–mRNA network using cardiac tissue samples from explanted hearts of DCM patients and healthy controls. Results showed that two lncRNAs targeting miR-144/451 and four lncRNAs targeting miR-21 were highly related to DCM (Fig. 1).²⁰

Table 1

Genes most commonly involved in cardiomyopathies in China (as reported by Lu et al.,³⁶ Mak et al.,³⁵ Zhao et al.,¹²³ Zhang et al.,⁵ Zhou et al.,¹²⁴ Chen et al.,⁹³ Wang et al.,⁹² Bao et al.¹²⁵).

Gene	Protein	Function	DCM	HCM	ACM	RCM
ACTC	α -actin	Sarcomere protein		✓		✓
DES	Desmin	Intermediate filament protein	✓		✓	
DSC2	Desmocollin-2	Cell–cell adhesion			✓	
DSG2	Desmoglein-2	Cell–cell adhesion			✓	
DSP	Desmoplakin	Cell–cell adhesion			✓	
JUP	Plakoglobin	Cell–cell adhesion			✓	
LMNA	Lamin A/C	Nuclear lamina associated protein	✓		✓	
MYBPC3	Myosin Binding Protein C3	Sarcomere protein		✓		✓
MYH6	Myosin Heavy Chain 6	Sarcomere protein			✓	
MYH7	Myosin Heavy Chain 7	Sarcomere protein	✓	✓	✓	✓
MYL3	Myosin Light Chain 3	Sarcomere protein				✓
NEBL	Nebulette	Z-band protein			✓	
NEXN	Nexilin	Sarcomere protein	✓			
PKP2	Plakophilin 2	Cell–cell adhesion			✓	
PLN	Phospholamban	Regulator of SERCA			✓	
PRKAG2	Protein Kinase AMP Activated Non-catalytic G2	Energy sensor kinase				
RBM20	RNA Binding Protein 20	Splicing factor	✓			
SLC25A4	Solute Carrier Family 25 Member 4	Mitochondrial carrier				
TMEM43	Transmembrane Protein 43	Nuclear lamina associated protein			✓	
TMPO	Thymopoietin	Protein of nuclear envelope		✓		
TNNC1	Cardiac Troponin C	Sarcomere protein	undefined			
TNNI3	Cardiac Troponin I	Sarcomere protein	✓		✓	✓
TNNT2	Cardiac Troponin T	Sarcomere protein	✓			✓
TPM1	Tropomyosin 1	Sarcomere protein		✓		
TTN	Titin	Sarcomere protein	✓	✓	✓	✓

DCM: dilated cardiomyopathy; HCM: hypertrophic cardiomyopathy; ACM: arrhythmogenic cardiomyopathy; RCM: restrictive cardiomyopathy; SERCA: sarcoendoplasmic reticulum Ca^{2+} -ATPase.

DNA methylation is a form of epigenetic regulation and may be relevant in the development of DCM. A study investigating the underlying mechanism reported that mice exposed to chronic restraint stress for 4 weeks exhibited ventricular remodeling toward heart failure, as characterized by ventricular chamber dilatation, wall thinning, and decreased contractility. The chronic stress may have induced ventricular remodeling and arrhythmias via altered methylation of DCM-associated myocardial genes.²¹

Inflammation

The most common causes of inflammatory DCM are infections and autoimmunity. Infections reportedly account for up to 30% of the etiology of DCM. Enteroviruses, including type A and B coxsackieviruses, account for a large proportion of DCM caused by infections. In cells infected with coxsackievirus type B3 (CVB3), the abundance of miR-146a was significantly increased, blocking the nuclear factor kappa B pathway by targeting toll-like receptor 3 and tumor necrosis factor receptor-associated factor 6, the

negatively regulated inflammatory response, and an intrinsic protective factor in CVB infection.²² Indoleamine 2,3-dioxygenase-1 (IDO1) also plays a role in immunosuppression. IDO1 depletion induced anti-inflammatory response in macrophages in mice with CVB3-infected DCM and consequently ameliorated cardiomyocyte injury.²³

Autoimmunity

DCM can result from autoimmune diseases. During autoimmune myocarditis, immune cells are under precise regulation. Metabolic reprogramming reportedly occurs in T-cells of mice and patients with autoimmune-induced DCM. Further, glycolytic metabolism considerably contributes to T-cell dysfunction and DCM immunopathogenesis.²⁴ Studies investigating potential mechanisms of immune regulation in autoimmune-induced DCM have been conducted. Protosappanin A confers immunosuppressive and protective effects on experimental autoimmune myocarditis (EAM) by metabolically reprogramming DCs, and this could contribute to the development of a new

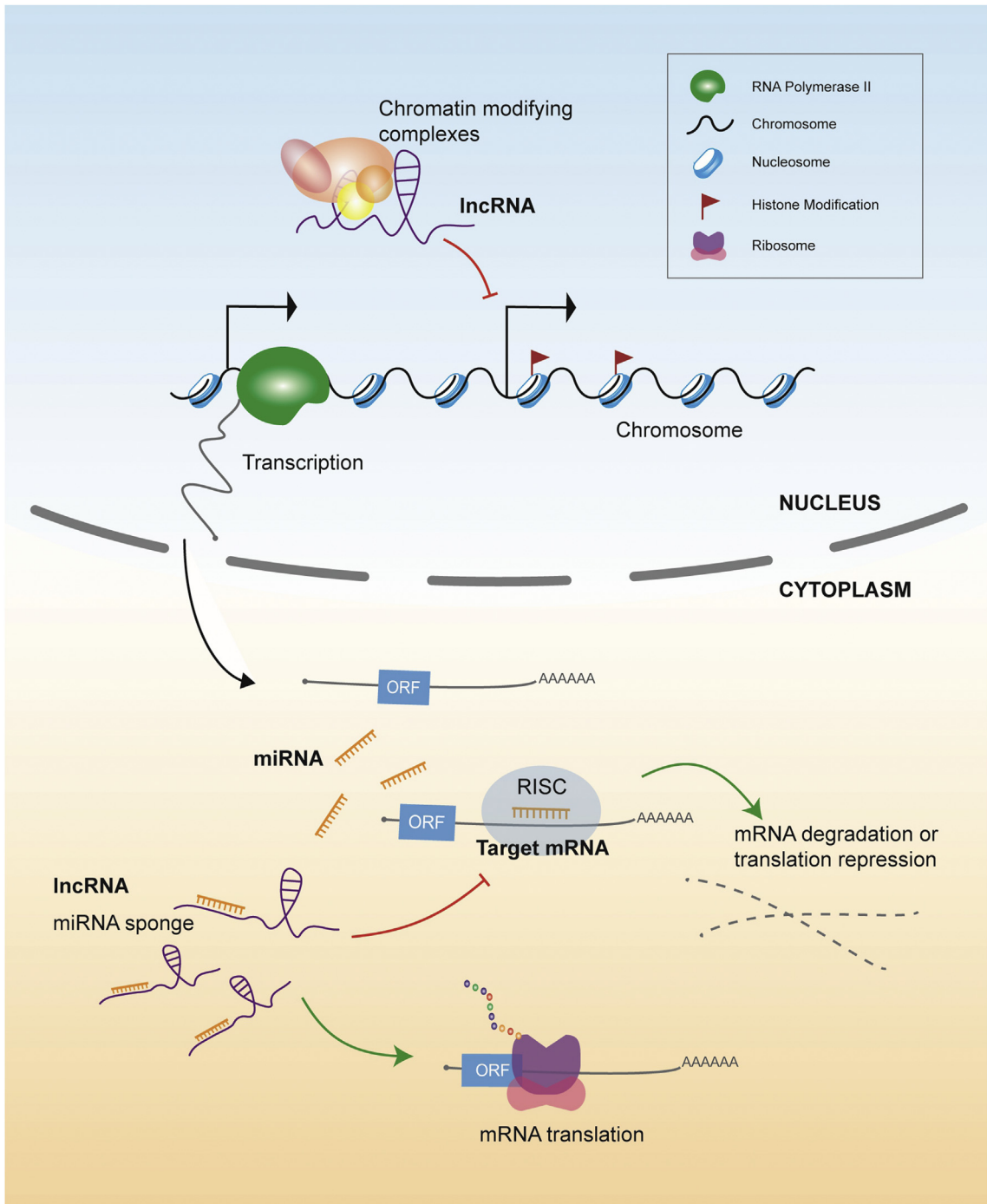


Fig. 1. Possible model of lncRNA–miRNA–mRNA interaction in cardiomyopathies. In the nucleus, lncRNAs targeting promoters of cardiomyopathy-related genes recruit chromatin-modifying complexes to induce histone modification, preventing the transcription of cardiomyopathy-related genes. In the cytoplasm, miRNAs targeting cardiomyopathy-related genes bind to mature mRNAs, leading to mRNA degradation or translation repression. lncRNAs serve as an miRNA sponge, competitively bind to miRNA, and inhibit their effect on targeted mRNAs.

potential immunotherapy for EAM and immune-related disorders. MiRNAs are also potential regulators of tolerance to autoimmune myocarditis.²⁵

Clinical diagnosis

Imaging techniques

DCM is typically diagnosed between 20 and 50 years of age. Imaging techniques, particularly Doppler technique and two-dimensional (2D) echocardiography, remain the primary method for identifying DCM. Magnetic resonance imaging (MRI) can assist with imaging dilation and fibrosis, which are suggestive of inflammation.²⁶ Echocardiography cannot definitively establish the underlying cause of DCM but is of value in differentiating ischemic from nonischemic DCM.²⁷ Three-dimensional speckle-tracking imaging is a promising tool for identifying the presence of inflammatory infiltrates in patients with DCM. Impairment of the global longitudinal strain, which provides an assessment of regional contractility, can distinguish patients with inflammation from those without.²⁸ Strain analyses based on a deformable registration algorithm can be a great tool for identifying DCM patients with varying degrees of mechanical dyssynchrony, which is associated with the prognosis of patients with DCM. Further, circumferential uniformity ratio estimate is the best parameter for differentiating DCM patients with normal QRS duration from patients with left bundle branch block (LBBB).²⁹

Endomyocardial biopsy

Endomyocardial biopsy is recommended for identifying the underlying etiology and treatment in all patients with suspected inflammatory cardiomyopathy. Many centers do not conduct endomyocardial biopsy due to the high risk of complications. However, histological examination, immunohistochemistry, and microbial genome and gene expression profiling are still valuable for diagnosis, follow-up, and prognosis.³⁰

Prognosis

Patients with DCM with a left ventricular ejection fraction of <35%, right ventricular involvement, and New York Heart Association (NYHA) functional class III or IV exhibit poor prognosis. The use of machine learning (ML) in predicting 1-year cardiovascular events in patients with severe DCM was tested. The top, highly relevant features selected for the ML model included left atrial size, QRS duration, and systolic blood pressure. ML performed well in predicting

cardiovascular events in patients with severe DCM [area under the curve (AUC), 0.887; 95% confidence interval, 0.813–0.961]. In recent years, studies have been conducted to discover circulating biomarkers for DCM prognosis. Circulating thyroid stimulating hormone, D-dimer, microRNA, and lncRNA levels and nutritional index might predict clinical outcomes in patients with idiopathic dilated cardiomyopathy.^{31,32}

Management

DCM management aims at reducing cardiac failure symptoms and improving cardiac function. The efficacy and safety of most pharmacological options and devices for cardiac failure with reduced ejection fraction extend to patients with DCM. As for patients with advanced disease, cardiac transplantation and implantation of long-term mechanical circulatory support are the two major options. An *ex vivo* study demonstrated that angiotensin-converting enzyme inhibitors, prorenin or renin receptor inhibitors, phosphodiesterase III inhibitors and sacubitril/valsartan (LCZ696) might be effective in children with DCM. However, β -receptor blockers were not effective against pediatric DCM.³³

Hypertrophic cardiomyopathy

HCM is a common inherited cardiovascular disease affecting every 1 in 250–500 adults. Its prevalence seems to be similar among different races.⁴ This heterogeneous myocardial disease is most often caused by sarcomeric gene mutations. A Chinese cohort of patients with HCM have shown a genetic diagnosis rate of up to 42.8%.^{34–36} HCM is phenotypically manifested by left ventricular (LV) hypertrophy, myocardial hypercontractility, reduced compliance, myofibrillar disarray, and fibrosis. Septal hypertrophy and abnormalities of the mitral valve and subvalvular apparatus contribute to LV outflow tract obstruction and systolic anterior motion. HCM is the primary cause of sudden deaths among young people and can lead to cardiac failure, thrombogenesis, and myocardial ischemia. Among all the cardiomyopathies, HCM has been studied most extensively. Nowadays, patients with HCM generally have an excellent overall prognosis when managed with contemporary therapy.

Pathogenesis

The phenotypic heterogeneity and variation in penetrance are evident between and within HCM families, suggesting that single sarcomere gene

mutations are insufficient to explain the complete clinical and endophenotypic profile of HCM (Table 1).³⁷ HCM endophenotypes include mitral-valve enlargement, microvascular abnormalities (prominent thickening of the intima and media as well as perivascular fibrosis), segmental LV hypertrophy, myocardial fibrosis,³⁸ and LV apical aneurysms.³⁹ Moreover, exophenotypes, for example the age of onset and right ventricular systolic dysfunction, also have different penetrance between groups.⁴⁰ These facts indicate a possible role of modifier genes and environmental factors. Ca^{2+} handling is a shared mechanism in cardiomyopathies. Muscle LIM protein, a key regulator of striated muscle function, generates HCM phenotype by increasing intracellular Ca^{2+} concentration.⁴¹ Pathological hypertrophy leading to cardiac remodeling is accompanied by the reactivation of a fetal gene program. Mesenchyme homeobox 1 (*Meox1*) gene is a fetal program gene. In a recent study, *Meox1* overexpression was found to exacerbate phenotypes in familial HCM, and *GATA4* was identified as a potential downstream target of *Meox1*.⁴² Several studies have focused on mitochondrial dysfunction and its role in HCM pathogenesis.^{43,44} The previously reported pathogenic mutation of the tRNA-modifying enzyme GTPBP3 may contribute to mitochondrial dysfunction, altering embryonic heart development and reducing fractional shortening of ventricles in zebrafish. This study highlighted the role of defective nucleotide modifications of tRNAs in the pathogenesis of HCM.⁴⁵ The decreased stability of 16S rRNA caused by mitochondrially encoded 16S rRNA mutation might contribute to HCM as well, as indicated in a study on induced pluripotent stem cell-derived cardiomyocytes.⁴⁶ Furthermore, co-expression analysis of two identified modules and nine hub genes prominently associated with HCM, indicating that the immune system may play a crucial role in HCM.⁴⁷

Non-coding RNAs also play an essential role in regulating genes associated with HCM and can serve as potential targets in HCM management (Fig. 1). Different cardiomyopathies have a unique miRNA expression pattern. The expression levels of miR-1-3p, miR-27a, miRNA-20, and miRNA-92b-3p were disease-specific and -sensitive in HCM.^{48–50} Overexpression of miR-92b-3p ameliorated Ang-II-induced cardiomyocyte hypertrophy, possibly by targeting *HAND2*.⁵⁰ Antihypertrophic interrelated transcript (Ahit), an lncRNA, was identified to be upregulated in mouse heart after transverse aortic constriction. Further, overexpression of Ahit attenuated

stress-induced cardiac hypertrophy *in vitro*, and serum Ahit levels were upregulated in patients with HCM. Mechanistically, Ahit triggers trimethylation on H3 lysine 27 of the promoter of MEF2A, mediating the downregulation of MEF2A and thereby preventing cardiac hypertrophy.⁵¹

External factors can induce cardiac hypertrophy via epigenetic regulation. DNA methyltransferase 1 (Dnmt1) is upregulated in familial HCM. Transcriptome and genome-wide DNA methylation analyses revealed that Dnmt1 knockout in rats is associated with resistance to cardiopathological changes and protection in response to pathological stress.⁵² Kindlin-2 was reported to partly suppress *GATA4* expression by triggering histone H3K9 methylation and protect the heart from pathological hypertrophy.⁵³

Clinical diagnosis

Imaging techniques

HCM is clinically diagnosed by imaging the hypertrophic cardiomyopathy phenotype using 2D echocardiography, cardiovascular MRI, or both. Imaging findings show an absolute increase in LV wall thickness, which can also be associated with right ventricular (RV) hypertrophy. Further, real-time 3D echocardiography and 2D speckle-tracking imaging are sensitive in detecting LV diastolic dysfunction, systolic dysfunction, and myocardial deformation impairment in both the hypertrophic and non-hypertrophic segments of the hearts of patients.⁵⁴

Tomographic high-resolution cardiac magnetic resonance (CMR) is often considered superior to echocardiography in HCM phenotype characterization, differential diagnosis, and early diagnosis. Extracellular volume (ECV) and late gadolinium enhancement (LGE) on contrast-enhanced MRI have been validated as measures for interstitial fibrosis and inflammation and play roles in the differentiation of HCM from other disorders induced by cardiac hypertrophy.^{55–57} For patients without LGE, myocardial fibrosis should not be excluded as prolonged myocardial T1 and elevated ECV are also strong indicators of diffuse fibrosis. Apparent diffusion coefficient is a feasible alternative to ECV and LGE for detecting myocardial fibrosis by evaluating contractile dysfunction in HCM.⁵⁸ LGE itself is significantly associated with sudden cardiac death (SCD)/aborted SCD risk, all cardiac death, and all-cause mortality in patients with HCM. Implantable cardioverter defibrillators (ICDs) can be considered for patients with positive LGE.⁵⁹ In addition to LGE, the

RV-long axis strain is also an independent predictor of adverse prognosis in HCM. Meanwhile, CMR can detect subclinical LV and RV deformation, which is valuable as familial HCM has great variance in penetrance, particularly age-related penetrance.^{60,61} CMR feature tracking identifies left atrial (LA) dysfunction and deformation at an early stage.⁶²

Genetic diagnosis

Genetic testing is widely used in clinical practice. However, the pathogenicity of gene mutations detected in HCM patients and its association with clinical outcomes should be cautiously interpreted.⁶³ Whether gene-positive phenotype-negative individuals are at risk of disease progression is still not clear. Long-term follow-up studies are warranted for this patient subset.

Prognosis

HCM risk stratification primarily aims to identify those patients who are at highest risk of sudden death and are likely to benefit from an implantable defibrillator. Currently, the widely applied 2014 European Society of Cardiology SCD risk-prediction model for HCM has excellent specificity, poor sensitivity, and moderate discrimination performance.⁶⁴ Functional deterioration is usually gradual, punctuated by long periods of day-to-day variability. HCM associated with RV hypertrophy predicts worse prognosis. As mentioned above, emerging groups of non-coding RNA are found to be associated with HCM. Circulating miRNAs can be consistent with that in myocardial tissue and correlate with myocardial fibrosis and hypertrophy.^{51,65} Procollagen type I carboxy-terminal propeptide and matrix metalloproteinase-2 levels in both plasma and myocardial tissues were consistent, reflecting myocardial fibrosis. Furthermore, comorbidity influencing hemodynamics should be considered in outcome prediction.^{66–70}

Management

Pharmacotherapies for HCM

Patients with symptomatic obstructive HCM (oHCM) are generally offered first-line pharmacotherapy with β -blockers or non-dihydropyridine calcium-channel blockers. No disease-modifying therapies have been addressed for non-oHCM. Novel pharmacotherapies for HCM target mechanisms participating in HCM pathogenesis, including myocardial force generation, myocardial metabolic

modulation, ion channel regulation, and fibrosis and adverse remodeling. Few successes have been reported so far.⁷¹ Direct inhibition of myofilament contraction by fropofol, a small molecule derivative of propofol, prevents phenotypic expression and progression of HCM.⁷² Single-cell reconstruction of progression trajectory during cardiac failure has revealed that a key event at the middle-stage of cardiac hypertrophy, macrophage activation, and subtype switching was successfully targeted by the sodium glucose cotransporter 2 inhibitor dapagliflozin as well as the anti-inflammatory agents TD139 and arglabin.⁷³ Leucine-zipper and sterile- α motif kinase selective inhibitor 3h demonstrated promising *in vivo* anti-HCM efficacy in a rat disease model and showed that the clinical drug–drug interaction potential could be well monitored for 3 h.⁷⁴ Stimulation of Na^+/K^+ -ATPase with DR-Ab attenuated angiotensin II-induced cardiomyocyte hypertrophy by activating the AMPK/Sirt-3/PPAR γ pathway.⁷⁵

Atrial arrhythmia management

Atrial arrhythmia affects approximately 20% of patients with HCM.⁷⁶ Catheter ablation has relatively low efficacy in HCM, with approximately 60% recurrence after a single procedure in 4–5 years. Left axis deviation of >50 mm, NYHA functional class \geq III, female sex, QTc prolongation (specifically >448 ms), and presence of fQRS are independent predictors of atrial fibrillation (AF) recurrence after initial catheter ablation.^{76–78} Generally, no evident difference is observed in thromboembolic events between HCM and non-HCM patients with AF.^{76,77} Based on current data from observational studies, compared with vitamin K antagonists, novel oral anticoagulants had similar or lower risks of thromboembolic and bleeding events in patients with HCM and AF.⁷⁹ A recent report suggested that hyperuricemia is a risk factor for thromboembolism in HCM and that both low and high serum uric acid concentration were associated with HCM-related mortality.^{69,70}

Device therapy

Subcutaneous ICD (S-ICD) is now a reasonable choice for the primary and secondary prevention of SCD, based on the fact that patients with HCM are younger at diagnosis compared to that at other conditions. However, S-ICD's sensing algorithm relies on subcutaneous vectors and the abnormal features of the HCM electrocardiography (ECG) make it a challenge for S-ICD template screening. In China, the screening success of S-ICD is 50.8% in HCM patients and R/

$T \leq 3.5$ in lead V5 in the 12-lead surface ECG is reportedly an independent predicting factor for screening failure.⁸⁰

Surgical intervention

Patients with oHCM and drug-refractory symptoms benefit from septal reduction therapy. Septal myectomy and alcohol septal ablation are the two conventional options.⁸¹ In a cohort of children with oHCM undergoing septal myectomy, the overall survival rates at follow-up were 100% at 1 year and 96.5% at 3 years. The overall survival rates (free from reoperation) were 99.1% at 1 year and 98.0% at 3 years.⁸² Radiofrequency ablation is a novel, minimally invasive technique independent of coronary anatomy. In a recent series of 15 patients with oHCM, patients who underwent percutaneous intramyocardial septal radiofrequency ablation showed significant reduction in gradients and interventricular septum thickness, associated with improvement in NYHA functional class and reduced serum N-terminal-pro hormone B-type natriuretic peptide at 6 months.⁸³ Myocardial bridging (MB) is another phenotype in patients with HCM that requires surgical intervention. Transient MB compression leads to alterations in diastolic flow and wall shear stress distribution. Patients with HCM and an MB compression ratio of >65% require surgical intervention.⁸⁴

Arrhythmogenic cardiomyopathy

ARVC is an inherited cardiomyopathy characterized by the progressive loss of ventricular myocardium and fibrofatty infiltration predominantly in the RV. LV involvement verified by autopsy expanded the spectrum of the disease manifestation, generating a broader term “arrhythmogenic cardiomyopathy (ACM)”. The prevalence of ACM affects approximately 1 in every 2000–5000 individuals.⁴ ACM classically manifests as ventricular arrhythmia (VA), and SCD may be the first presentation. In the advanced stage of the disease, patients suffer from impaired ventricular systolic function and cardiac failure. Genetic mutations and disease modifiers, such as excessive exercise and sex, play a critical role in disease progression of ACM.^{85,86}

Pathogenesis

ACM has been regarded as “desmosomal cardiomyopathy” because it is mainly caused by mutations in five genes of the desmosomal complex [desmocollin-2 (*DSC2*), desmoglein-2 (*DSG2*), desmoplakin (*DSP*),

plakoglobin (*JUP*), and plakophilin-2 (*PKP2*)] (Table 1). Mutations in *PKP2*, *DSP*, and *DSG2* have been identified in 80% of confirmed pathogenic cases. *PKP2* accounts for 36%–92% of the mutations identified in desmosomal genes. Multiple studies have demonstrated the disease mechanisms induced by desmosomal gene mutations.^{87–91} Approximately 10% of the patients with ACM carry pathogenic or likely pathogenic variants.^{36,92,93} In up to 20% of genetically diagnosed ACM patients, compound or digenic heterozygosity may be present, presenting with a more severe phenotype, with higher penetrance, earlier onset of VA, higher SCD risk, more frequent LV involvement, and a higher risk of HF.⁹⁴ Additionally, clinical studies have revealed that ACM probands with different genotypes exhibit different phenotypic expression and prognosis.^{92,95} Modifier genes and other ACM-associated mutations require identification. In most of these cases, the genes encode proteins of the intercalated disc. To date, 16 genes have been associated with AC, including non-desmosome genes, such as desmin (*DES*), phospholamban (*PLN*), *LMNA*, transmembrane protein 43 (*TMEM43*), titin (*TTN*), and cadherin-2 (*CDH2*) (Table 1).⁹⁶ The pathogenicity of any novel gene variation should be carefully evaluated.⁹⁷ Mutated genes participate in regulatory mechanisms associated with the major features of ACM, including cardiomyocyte loss, fibrosis, adipogenesis, inflammation, and arrhythmogenesis, which are worthy of discussion due to their potential of being used as therapy targets.^{96,98,99}

The most groundbreaking finding in the past 2 years has been the establishment of a novel pathological classification system with distinct genetic backgrounds indicating different potential mechanisms in the pathogenesis of ACM based on end-stage patients.¹⁰⁰ The clinical characteristics of patients, their genotype, and CMR imaging findings were assessed along with their pathological characteristics, and a clustering containing four subtypes was constructed. This research effort has not only introduced a novel interpretation of the genetic pathogenesis of ACM but also provided abundant information that would assist the diagnosis of and risk stratification in ACM.

Clinical manifestation

While SCD may be the first presentation of the disease, patients with ACM suffer from palpitations, exertional syncope in the next phase with T-wave inversion in the right precordial leads, VA with an LV pattern in lead V1, and RV structural abnormalities on

imaging. VAs can range from frequent premature ventricular contractions to sustained monomorphic ventricular tachycardia (VT) or ventricular fibrillation (VF). VT with left bundle pattern indicates right-dominant ACM, whereas right bundle morphology can be the first sign of left-dominant or biventricular ACM. A recent series of 522 patients with ARVC reported that 32.4% presented with bradyarrhythmia including intraventricular conduction block (22.6%), atrioventricular block (10.7%), and sick sinus syndrome (3.5%).¹⁰¹ According to a series of 100 patients with ARVC, atrial involvement in ARVC is also common, including right atrial (RA) dilation (45%), LA dilation (16%), and sustained atrial tachyarrhythmias (3%).¹⁰² Genotype was not associated with atrial involvement. Regional ventricular dysfunction occurs in the advanced phase of ACM. The LV-dominant form of ACM is likely to be misdiagnosed as myocarditis or sarcoidosis owing to the lack of diagnostic criteria. Based on a recently published observational study, RV thrombus formation is a potential complication of ARVC with impaired RV function. In patients with biventricular involvement, thrombi may also occur within the LV.^{103–105}

Clinical diagnosis

Currently, diagnosing ACM is challenging. Many types of cardiomyopathies can generate arrhythmia, including not only ACM but also other conditions such as Brugada syndrome, DCM, Chagas disease, cardiac sarcoidosis, and myocarditis. Differential diagnosis can also be difficult.¹⁰⁶ Further, early detection of ACM before SCD has always been challenging. At present, the diagnosis of ACM is based on information derived from six diagnostic categories constituting the revised 2010 Taskforce Criteria (TFC). Other diagnostic tools, including ECG, imaging, VAs, tissue pathology, and genetics serve complementary to TFC. However, these criteria often fail to recognize the left-dominant and biventricular forms of the disease.

Imaging techniques

Cardiac MRI is the gold standard for assessing ventricular chamber dimension and segmental motion abnormalities due to fibrofatty replacement. CMR characteristics in arrhythmogenic left ventricular cardiomyopathy (ALVC) need to be well-studied and included in ACM diagnosis.¹⁰⁷ New techniques hold promise for early disease detection. CMR feature tracking is reported to detect early LV dysfunction.¹⁰⁸ Further, LV global longitudinal strain of $>-12.65\%$ is

an independent prognostic marker for adverse cardiac outcomes.¹⁰⁹

Electrocardiograph

Resting 12-lead ECG is abnormal in most patients with ACM. Repolarization abnormalities (T-wave inversions) are related to ventricular dilatation and endocardial and epicardial scars. Depolarization abnormalities (QRS notching, wider QRS, larger S waves, epsilon waves, late potentials, and LBBB) represent RV scars on causing delayed RV activation. Meanwhile, the voltage of precordial QRS is associated with residual RV myocardium and is an effective predictor of death and cardiac transplantation in ACM patients.¹⁰⁰ High-definition ECG, microvolt T-wave alternans assessment, and electrophysiological studies also affect the diagnosis and prognosis.^{110,111} Further, sympathetic nerve activity measurement with ECG might be used for long-term arrhythmic risk assessment in patients with substrates of VA.¹¹²

Prognosis

Risk stratification in ACM mainly deals with the risk of SCD (caused by sustained VT or VF). Pre-existing risk predictors include prior cardiac arrest, sustained VT, unexplained syncope, non-sustained VT, and severe ventricular dysfunction. Genetic background is also strongly associated with disease progression. Meanwhile, recent research has demonstrated that elevated plasma β -OHB levels predict major adverse cardiovascular events in probands and disease progression in patients with ACM and their clinically asymptomatic relatives.¹¹³

Management

Treatment of ACM includes lifestyle changes, pharmacological treatment, catheter ablation, ICD, and cardiac transplantation. Patients with ACM are advised to avoid physical exercise owing to potential adverse outcomes. However, it has been reported that exercise restored two-thirds of differentially expressed genes in a mouse model of ACM, rescued the main dysregulated pathways, and induced eccentric cardiac hypertrophy without affecting cardiac function. This finding suggests that treadmill exercise has potential benefits in a subset of cardiac phenotypes in ACM.¹¹⁴ Besides pharmacological treatment including β -blockers, anti-arrhythmic drugs, and cardiac failure treatment, ICD and catheter ablation are the most effective ways of managing VA in ACM. In a

recent study of 39 ARVC patients implanted with an ICD with a minimum follow-up of 32.3 months, 71.8% experienced 540 appropriate ICD intervention and 30.8% suffered from an electrical storm. Broad precordial T-wave inversion $\geq V1-V3$ was associated with a shorter event-free period.¹¹⁵ In a study of 48 adults with ARVC undergoing radiofrequency catheter ablation with a minimum follow-up of 2 years, long-term freedom from VT was 56.3% at 71.4 ± 45.7 months after the last procedure. Only 37.5% of the patients had VT-free survival after a single procedure. A combined epicardial and endocardial approach was performed in 25.7% of patients. The mean time to VT recurrence was 13.4 ± 27.2 months for all procedures. Before ablation, all patients had failed medical treatment with at least two anti-arrhythmic drugs.¹¹⁶ Pre-procedural imaging can also aid substrate identification.¹¹⁷

Restrictive cardiomyopathy

Restrictive cardiomyopathy is the rarest cardiomyopathy, with a difficult-to-estimate prevalence. It is characterized as increasing myocardial stiffness that leads to impaired ventricular filling, with normal or near-normal biventricular chamber size and systolic function until the advanced stage of the disease. Clinical manifestations include symptoms of left or right heart failure accompanied by arrhythmias and conduction disturbances. Some patients with RCM also present with myocardial hypertrophy. Pediatric patients with RCM have a high risk of SCD. Further, the disease can progress rapidly, requiring cardiac transplantation.

Pathogenesis

Restrictive cardiomyopathy has a broad spectrum of etiologies, including infiltrative,¹¹⁸ storage disease, non-infiltrative, and endomyocardial. The genetic spectrum of idiopathic RCM is mostly unknown. Several genes have been recognized as the cause of idiopathic RCM, including *MYH7*, *TNNI3*, *TNNT2*, *ACTC*, and *MYBPC3* (Table 1). Patients can be either familial or sporadic. Increased myofilament sensitivity to calcium, activated fibrosis, and marked deposition of desmin have been implicated in the pathogenesis of idiopathic RCM. Meanwhile, the coexistence of HCM, RCM, and DCM phenotypes within the same families has been observed. Modifier genes, epigenetics, and environmental influence may also play important roles in determining the ultimate phenotype.¹¹⁹

Few studies on RCM have been recently published by Chinese researchers. A 6-year-old patient diagnosed with RCM was reported to have endocardial fibrosis complicated with a great amount of adipose tissue accumulated in the subendocardium. Adipose accumulation may have been the cause of the rapid deterioration of the patient's clinical condition. This case highlights an exceedingly rare form of RCM with an unknown underlying mechanism.¹²⁰

Clinical diagnosis

Imaging tests including echocardiography and CMR are key to diagnosing RCM. Besides structural abnormalities, abnormal diastolic compliance can be characterized by echo with restrictive diastolic filling parameters. CMR serves to assess not only structural deformations but also myocardial inflammation, fibrosis, and signs of infiltration. Differentiating idiopathic RCM from acquired etiologies of RCM is crucial as the management differs. For example, speckle-tracking echocardiography can differentiate chronic constrictive pericarditis from RCM based on the incremental value of the tissue motion of annular displacement.¹²¹

Management

Treatments for infiltrative and storage cardiomyopathies lie beyond the scope for discussion in this review. The current management of idiopathic RCM has been largely supported by the use of loop diuretic agents and systemic anticoagulation for thromboembolic complications resulting from atrial fibrillation. Green tea extract catechin has recently been reported to improve cardiac function in pediatric cardiomyopathy patients with diastolic dysfunction.¹²² Cardiac transplantation is an effective therapy for patients with end-stage disease, and LV-assist devices may help to transition these patients to transplantation.

Future prospects

Advances in genomics have led us to a better understanding of disease pathogenesis and progression in cardiomyopathies. Disease models, including animals and newly developed human-induced pluripotent stem cell technology, have provided a complimentary opportunity to model human cardiomyopathies. Basic and clinical research should be combined in investigating the complicated mechanisms underlying cardiomyopathies and beware of differences between

experimental models and human diseases. The novel classification of ACM established the first-ever system of disease interpretation to uncover intrinsic mechanisms and common pathways that have been overlooked before. This accomplishment is also a guiding force for the phenotype–genotype specific management of ACM, which is also required for HCM, DCM, and RCM. Furthermore, the existence of disease modifiers has been revealed in all types of cardiomyopathies, explaining the incomplete penetrance, variation, and overlapping in phenotypes. Thus, the development of disease-modifying therapies, which are hoped to shift disease progression to compensation, is eagerly expected. Efforts have been invested in the domain of HCM; yet, only few translational studies exist for the other kinds of cardiomyopathies. Several non-coding RNAs have been addressed as prognostic biomarkers for atherosclerosis and myocardial infarction. Animal studies have identified changes in miRNAs and lncRNA profile in CM patients as well. Currently, PCR, microarrays, and sequencing are commonly used methods for clinical ncRNAs detection. However, reliable isolation methods, cross-platform accuracy, and standardization need to be improved. Further discoveries in the crosstalk among ncRNAs, localization of ncRNAs, and RNA drug design are needed to transform miRNA and lncRNA into therapeutic targets and diagnostic tools. We hope that young investigators and clinicians can seize the opportunity and supplement the research in this field to improve the quality of life of patients with cardiomyopathies.

Funding

This work was supported by the National Key Research and Development Program of China (No. 2016YFC0901500) and Beijing Training Program of Innovation and Entrepreneurship for college students (No. 2019zlgc0643).

Conflict of interest

None.

References

- Richardson P, McKenna W, Bristow M, et al. Report of the 1995 world Health organization/international society and federation of Cardiology task force on the definition and classification of cardiomyopathies. *Circulation*. 1996;93:841–842.
- Ko YL, Chen JJ, Tang TK, et al. Malignant familial hypertrophic cardiomyopathy in a family with a 453Arg→Cys mutation in the beta-myosin heavy chain gene: coexistence of sudden death and end-stage heart failure. *Hum Genet*. 1996;97:585–590.
- Ko YL, Lien WP, Chen JJ, Wu CW, Tang TK, Liew CC. No evidence for linkage of familial hypertrophic cardiomyopathy and chromosome 14q1 locus D14S26 in a Chinese family: evidence for genetic heterogeneity. *Hum Genet*. 1992;89:597–601.
- McKenna WJ, Maron BJ, Thiene G. Classification, epidemiology, and global burden of cardiomyopathies. *Circ Res*. 2017;121:722–730.
- Zhang XL, Xie J, Lan RF, et al. Genetic basis and genotype-phenotype correlations in han Chinese patients with idiopathic dilated cardiomyopathy. *Sci Rep*. 2020;10:2226.
- Sun YM, Wang J, Xu YJ, et al. ZBTB17 loss-of-function mutation contributes to familial dilated cardiomyopathy. *Heart Vess*. 2018;33:722–732.
- Liu H, Xu YJ, Li RG, et al. HAND2 loss-of-function mutation causes familial dilated cardiomyopathy. *Eur J Med Genet*. 2019;62:103540.
- Xu YJ, Wang ZS, Yang CX, et al. Identification and functional characterization of an ISL1 mutation predisposing to dilated cardiomyopathy. *J Cardiovasc Transl Res*. 2019;12:257–267.
- Di RM, Yang CX, Zhao CM, et al. Identification and functional characterization of KLF5 as a novel disease gene responsible for familial dilated cardiomyopathy. *Eur J Med Genet*. 2020;63:103827.
- Guo J, Li Z, Hao C, et al. A novel de novo CASZ1 heterozygous frameshift variant causes dilated cardiomyopathy and left ventricular noncompaction cardiomyopathy. *Mol Genet Genomic Med*. 2019;7, e828.
- Pang XF, Lin X, Du JJ, Zeng DY. LTBP2 knockdown by siRNA reverses myocardial oxidative stress injury, fibrosis and remodelling during dilated cardiomyopathy. *Acta Physiol*. 2020;228, e13377.
- Cai ZJ, Lee YK, Lau YM, et al. Expression of Lmna-R225X nonsense mutation results in dilated cardiomyopathy and conduction disorders (DCM-CD) in mice: impact of exercise training. *Int J Cardiol*. 2020;298:85–92.
- Jiang X, Liu Y, Liu X, et al. Over-expression of a cardiac-specific human dopamine D5 receptor mutation in mice causes a dilated cardiomyopathy through ROS over-generation by NADPH oxidase activation and Nrf2 degradation. *Redox Biol*. 2018;19:134–146.
- Chen Z, Li Y, Wang Y, et al. Cardiomyocyte-restricted low density lipoprotein receptor-related protein 6 (LRP6) deletion leads to lethal dilated cardiomyopathy partly through Drp1 signaling. *Theranostics*. 2018;8:627–643.
- Wang Y, Yin C, Chen Z, et al. Cardiac-specific LRP6 knockout induces lipid accumulation through Drp1/CPT1b pathway in adult mice. *Cell Tissue Res*. 2020;380:143–153.
- Qin Y, Li A, Liu B, et al. Mitochondrial fusion mediated by fusion promotion and fission inhibition directs adult mouse heart function toward a different direction. *Faseb J*. 2020;34:663–675.
- Fan F, Duan Y, Yang F, et al. Deletion of heat shock protein 60 in adult mouse cardiomyocytes perturbs mitochondrial protein homeostasis and causes heart failure. *Cell Death Differ*. 2020;27:587–600.

18. Hou T, Zhang R, Jian C, et al. NDUFB1 confers cardio-protection by enhancing mitochondrial bioenergetics through coordination of respiratory complex and supercomplex assembly. *Cell Res.* 2019;29:754–766.
19. Wang D, Fang J, Lv J, et al. Novel polymorphisms in PDLIM3 and PDLIM5 gene encoding Z-line proteins increase risk of idiopathic dilated cardiomyopathy. *J Cell Mol Med.* 2019;23:7054–7062.
20. Tao L, Yang L, Huang X, Hua F, Yang X. Reconstruction and analysis of the lncRNA-miRNA-mRNA network based on competitive endogenous RNA reveal functional lncRNAs in dilated cardiomyopathy. *Front Genet.* 2019;10:1149.
21. Zhang P, Li T, Liu YQ, et al. Contribution of DNA methylation in chronic stress-induced cardiac remodeling and arrhythmias in mice. *Faseb J.* 2019;33:12240–12252.
22. Fei Y, Chaulagain A, Wang T, et al. MiR-146a down-regulates inflammatory response by targeting TLR3 and TRAF6 in Coxsackievirus B infection. *RNA.* 2020;26:91–100.
23. Guo G, Sun L, Yang L, Xu H. Ido1 depletion induces an anti-inflammatory response in macrophages in mice with chronic viral myocarditis. *Cell Cycle.* 2019;18:2598–2613.
24. Wu J, Sun P, Chen Q, et al. Metabolic reprogramming orchestrates CD4+ T-cell immunological status and restores cardiac dysfunction in autoimmune induced-dilated cardiomyopathy mice. *J Mol Cell Cardiol.* 2019;135:134–148.
25. Chen L, Hou X, Zhang M, et al. MicroRNA-223-3p modulates dendritic cell function and ameliorates experimental autoimmune myocarditis by targeting the NLRP3 inflammasome. *Mol Immunol.* 2020;117:73–83.
26. Cui Y, Chen Y, Cao Y, et al. Myocardial extracellular volume fraction measurements with MOLLI 5(3)3 by cardiovascular MRI for the discrimination of healthy volunteers from dilated and hypertrophic cardiomyopathy patients. *Clin Radiol.* 2019;74:732. e9-732.e16.
27. Zuo H, Zhang Y, Ma F, et al. Myocardial deformation pattern differs between ischemic and non-ischemic dilated cardiomyopathy: the diagnostic value of longitudinal strains. *Ultrasound Med Biol.* 2020;46:233–243.
28. He J, Yang L. Value of three-dimensional speckle-tracking imaging in detecting left ventricular systolic function in patients with dilated cardiomyopathy. *Echocardiography.* 2019;36:1492–1495.
29. Xu Y, He S, Li W, et al. Quantitative mechanical dyssynchrony in dilated cardiomyopathy measured by deformable registration algorithm. *Eur Radiol.* 2020;30:2010–2020.
30. Chen WH, Guo YS, Zhang DH, Zhang HJ. Long-term prognosis of suspected myocarditis and cardiomyopathy associated with viral infection of the myocardial tissue: a meta-analysis of cohort studies. *Cardiovasc Ther.* 2019;2019:9342792.
31. Jiao M, You HZ, Yang XY, et al. Circulating microRNA signature for the diagnosis of childhood dilated cardiomyopathy. *Sci Rep.* 2018;8:724.
32. Cheng X, Jiang H. Long non-coding RNA HAND2-AS1 downregulation predicts poor survival of patients with end-stage dilated cardiomyopathy. *J Int Med Res.* 2019;47:3690–3698.
33. Guo Q, Liu J, Zhu P, et al. Evaluation of drug-related receptors in children with dilated cardiomyopathy. *Front Pediatr.* 2019;7:387.
34. Cheng S, Choe YH, Ota H, et al. CMR assessment and clinical outcomes of hypertrophic cardiomyopathy with or without ventricular remodeling in the end-stage phase. *Int J Cardiovasc Imag.* 2018;34:597–605.
35. Mak T, Lee YK, Tang CS, et al. Coverage and diagnostic yield of whole exome sequencing for the evaluation of cases with dilated and hypertrophic cardiomyopathy. *Sci Rep.* 2018;8:10846.
36. Lu C, Wu W, Liu F, et al. Molecular analysis of inherited cardiomyopathy using next generation semiconductor sequencing technologies. *J Transl Med.* 2018;16:241.
37. Wang J, Wan K, Sun J, et al. Phenotypic diversity identified by cardiac magnetic resonance in a large hypertrophic cardiomyopathy family with a single MYH7 mutation. *Sci Rep.* 2018;8:973.
38. Chen PF, Peng R, Tang L, Hu XQ. Atrial fibrosis associated with left ventricular apical hypoplasia. *Eur Heart J Cardiovasc Imaging.* 2018;19:583.
39. Gao X, Yang J, Zhang X, Wang P, Li H. A case report of apical aneurysms and myocardial perfusion deficit with myocardial necrosis due to hypertrophic cardiomyopathy. *Medicine (Baltimore).* 2018;97, e10829.
40. Shah JP, Yang Y, Chen S, et al. Prevalence and prognostic significance of right ventricular dysfunction in patients with hypertrophic cardiomyopathy. *Am J Cardiol.* 2018;122:1932–1938.
41. Li X, Lu WJ, Li Y, et al. MLP-deficient human pluripotent stem cell derived cardiomyocytes develop hypertrophic cardiomyopathy and heart failure phenotypes due to abnormal calcium handling. *Cell Death Dis.* 2019;10:610.
42. Lu D, Wang J, Li J, et al. Meox1 accelerates myocardial hypertrophic decompensation through Gata4. *Cardiovasc Res.* 2018;114:300–311.
43. Ma K, Xie M, He X, et al. A novel compound heterozygous mutation in VARS2 in a newborn with mitochondrial cardiomyopathy: a case report of a Chinese family. *BMC Med Genet.* 2018;19:202.
44. Li D, Sun Y, Zhuang Q, et al. Mitochondrial dysfunction caused by m.2336T>C mutation with hypertrophic cardiomyopathy in cybrid cell lines. *Mitochondrion.* 2019;46:313–320.
45. Chen D, Zhang Z, Chen C, et al. Deletion of Gtbp3 in zebrafish revealed the hypertrophic cardiomyopathy manifested by aberrant mitochondrial tRNA metabolism. *Nucleic Acids Res.* 2019;47:5341–5355.
46. Li S, Pan H, Tan C, et al. Mitochondrial dysfunctions contribute to hypertrophic cardiomyopathy in patient iPSC-derived cardiomyocytes with MT-RNR2 mutation. *Stem Cell Reports.* 2018;10:808–821.
47. Chen R, Ge T, Jiang W, et al. Identification of biomarkers correlated with hypertrophic cardiomyopathy with co-expression analysis. *J Cell Physiol.* 2019;234:21999–22008.
48. Li M, Chen X, Chen L, Chen K, Zhou J, Song J. MiR-1-3p that correlates with left ventricular function of HCM can serve as a potential target and differentiate HCM from DCM. *J Transl Med.* 2018;16:161.
49. Sun D, Li C, Liu J, et al. Expression profile of microRNAs in hypertrophic cardiomyopathy and effects of microRNA-20 in inducing cardiomyocyte hypertrophy through regulating gene MFN2. *DNA Cell Biol.* 2019;38:796–807.
50. Yu XJ, Huang YQ, Shan ZX, et al. MicroRNA-92b-3p suppresses angiotensin II-induced cardiomyocyte hypertrophy via targeting HAND2. *Life Sci.* 2019;232:116635.
51. Yu J, Yang Y, Xu Z, et al. Long noncoding RNA Ahit protects against cardiac hypertrophy through SUZ12 (suppressor of

- zeste 12 protein homolog)-mediated downregulation of MEF2A (myocyte enhancer factor 2A). *Circ Heart Fail.* 2020;13:e006525.
52. Wu T, Ma Y, Zhang X, et al. Myocardial tissue-specific Dnmt1 knockout in rats protects against pathological injury induced by Adriamycin. *Lab Invest.* 2020. <https://doi.org/10.1038/s41374-020-0402-y> [Epub ahead of print].
 53. Qi L, Chi X, Zhang X, et al. Kindlin-2 suppresses transcription factor GATA4 through interaction with SUV39H1 to attenuate hypertrophy. *Cell Death Dis.* 2019;10:890.
 54. Huang X, Yue Y, Wang Y, et al. Assessment of left ventricular systolic and diastolic abnormalities in patients with hypertrophic cardiomyopathy using real-time three-dimensional echocardiography and two-dimensional speckle tracking imaging. *Cardiovasc Ultrasound.* 2018;16:23.
 55. Jiang M, Wang Z, Su X, et al. Author correction: the significance of interstitial fibrosis on left ventricular function in hypertensive versus hypertrophic cardiomyopathy. *Sci Rep.* 2018;8:12232.
 56. Cheng S, Fang M, Cui C, et al. LGE-CMR-derived texture features reflect poor prognosis in hypertrophic cardiomyopathy patients with systolic dysfunction: preliminary results. *Eur Radiol.* 2018;28:4615–4624.
 57. Xu J, Zhuang B, Sirajuddin A, et al. MRI T1 mapping in hypertrophic cardiomyopathy: evaluation in patients without late gadolinium enhancement and hemodynamic obstruction. *Radiology.* 2020;294:275–286.
 58. Wu R, An DA, Shi RY, et al. Myocardial fibrosis evaluated by diffusion-weighted imaging and its relationship to 3D contractile function in patients with hypertrophic cardiomyopathy. *J Magn Reson Imag.* 2018;48:1139–1146.
 59. He D, Ye M, Zhang L, Jiang B. Prognostic significance of late gadolinium enhancement on cardiac magnetic resonance in patients with hypertrophic cardiomyopathy. *Heart Lung.* 2018;47:122–126.
 60. Huang L, Ran L, Zhao P, et al. MRI native T1 and T2 mapping of myocardial segments in hypertrophic cardiomyopathy: tissue remodeling manifested prior to structure changes. *Br J Radiol.* 2019;92:20190634.
 61. Li X, Shi K, Yang ZG, et al. Assessing right ventricular deformation in hypertrophic cardiomyopathy patients with preserved right ventricular ejection fraction: a 3.0-T cardiovascular magnetic resonance study. *Sci Rep.* 2020;10:1967.
 62. Yang Y, Yin G, Jiang Y, Song L, Zhao S, Lu M. Quantification of left atrial function in patients with non-obstructive hypertrophic cardiomyopathy by cardiovascular magnetic resonance feature tracking imaging: a feasibility and reproducibility study. *J Cardiovasc Magn Reson.* 2020;22:1.
 63. Cui H, Wang J, Zhang C, et al. Mutation profile of FLNC gene and its prognostic relevance in patients with hypertrophic cardiomyopathy. *Mol Genet Genomic Med.* 2018;6:1104–1113.
 64. Wang J, Zhang Z, Li Y, Xu Y, Wan K, Chen Y. Variable and limited predictive value of the European society of Cardiology hypertrophic cardiomyopathy sudden-death risk model: a meta-analysis. *Can J Cardiol.* 2019;35:1791–1799.
 65. Huang D, Chen Z, Wang J, Chen Y, Liu D, Lin K. MicroRNA-221 is a potential biomarker of myocardial hypertrophy and fibrosis in hypertrophic obstructive cardiomyopathy. *Biosci Rep.* 2020;40, BSR20191234.
 66. Zhang K, Meng X, Wang W, et al. Prognostic value of free triiodothyronine level in patients with hypertrophic obstructive cardiomyopathy. *J Clin Endocrinol Metab.* 2018;103:1198–1205.
 67. Deng T, Ou B, Zhu T, Xu D. The effect of hypertension on cardiac structure and function in different types of hypertrophic cardiomyopathy: a single-center retrospective study. *Clin Exp Hypertens.* 2019;41:359–365.
 68. Luo Q, Chen J, Zhang T, Tang X, Yu B. Retrospective analysis of clinical phenotype and prognosis of hypertrophic cardiomyopathy complicated with hypertension. *Sci Rep.* 2020;10:349.
 69. Wang Z, Liao H, Chen X, He S. Hyperuricemia: risk factor for thromboembolism in hypertrophic cardiomyopathy patients. *Intem Emerg Med.* 2020. <https://doi.org/10.1007/s11739-020-02275-6> [Epub ahead of print].
 70. Wang Z, Xu Y, Liao H, Chen X, He S. U-shaped association between serum uric acid concentration and mortality in hypertrophic cardiomyopathy patients. *Ups J Med Sci.* 2020;125:44–51.
 71. Tuohy CV, Kaul S, Song HK, Nazer B, Heitner SB. Hypertrophic cardiomyopathy: the future of treatment. *Eur J Heart Fail.* 2020;22:228–240.
 72. Huang Y, Lu H, Ren X, et al. Fropofol prevents disease progression in mice with hypertrophic cardiomyopathy. *Cardiovasc Res.* 2020;116:1175–1185.
 73. Ren Z, Yu P, Li D, et al. Single-cell reconstruction of progression trajectory reveals intervention principles in pathological cardiac hypertrophy. *Circulation.* 2020;10:1704–1719.
 74. Jiang W, Ding L, Dai T, Guo J, Dai R, Chang Y. Studies of pharmacokinetics in beagle dogs and drug-drug interaction potential of a novel selective ZAK inhibitor 3h for hypertrophic cardiomyopathy treatment. *J Pharmaceut Biomed Anal.* 2019;172:206–213.
 75. Xiong S, Sun HJ, Cao L, et al. Stimulation of Na⁺/K⁺-ATPase with an antibody against its 4th extracellular region attenuates angiotensin II-induced H9c2 cardiomyocyte hypertrophy via an AMPK/SIRT3/PPAR γ PARR/PPARcyte HypertroOxid. *Med Cell Longev.* 2019;2019:4616034.
 76. Chen X, Dong JZ, Du X, et al. Long-term outcome of catheter ablation for atrial fibrillation in patients with apical hypertrophic cardiomyopathy. *J Cardiovasc Electrophysiol.* 2018;29:951–957.
 77. Zheng S, Jiang W, Dai J, et al. Five-year outcomes after catheter ablation for atrial fibrillation in patients with hypertrophic cardiomyopathy. *J Cardiovasc Electrophysiol.* 2020;31:621–628.
 78. Wen SN, Zhu HJ, Sun PY, et al. Depolarization and repolarization parameters on ECG predict recurrence after atrial fibrillation ablation in patients with hypertrophic cardiomyopathy. *J Cardiovasc Electrophysiol.* 2019;30:2405–2413.
 79. Zhou Y, He W, Zhou Y, Zhu W. Non-vitamin K antagonist oral anticoagulants in patients with hypertrophic cardiomyopathy and atrial fibrillation: a systematic review and meta-analysis. *J Thromb Thrombolysis.* 2019. <https://doi.org/10.1007/s11239-11019-02008-11233> [Epub ahead of print].
 80. Guo L, Zhang M, Hu M, et al. Prevalence of subcutaneous implantable cardioverter-defibrillator based on template ECG screening and ineligible surface ECG predicting factors in patients with hypertrophic cardiomyopathy in China. *Heart Ves.* 2019;34:851–859.
 81. Tang B, Song Y, Cui H, et al. Prognosis of adult obstructive hypertrophic cardiomyopathy patients with different

- morphological types after surgical myectomy. *Eur J Cardio Thorac Surg.* 2018;54:310–317.
82. Zhu C, Wang S, Ma Y, et al. Childhood hypertrophic obstructive cardiomyopathy and its relevant surgical outcome. *Annal Thorac surg.* 2019;19:31752–31757.
 83. Liu L, Li J, Zuo L, et al. Percutaneous intramyocardial septal radiofrequency ablation for hypertrophic obstructive cardiomyopathy. *J Am Coll Cardiol.* 2018;72:1898–1909.
 84. Sharzehee M, Chang Y, Song JP, Han HC. Hemodynamic effects of myocardial bridging in patients with hypertrophic cardiomyopathy. *Am J Physiol Heart Circ Physiol.* 2019;317:H1282–H1291.
 85. Chen LT, Jiang CY. Bioinformatics analysis of sex differences in arrhythmogenic right ventricular cardiomyopathy. *Mol Med Rep.* 2019;19:2238–2244.
 86. Towbin JA, McKenna WJ, Abrams DJ, et al. 2019 HRS expert consensus statement on evaluation, risk stratification, and management of arrhythmogenic cardiomyopathy: executive summary. *Heart Rhythm.* 2019;16:e373–e407.
 87. El-Battrawy I, Zhao Z, Lan H, et al. Electrical dysfunctions in human-induced pluripotent stem cell-derived cardiomyocytes from a patient with an arrhythmogenic right ventricular cardiomyopathy. *Europace.* 2018;20:f46–f56.
 88. Chen K, Rao M, Guo G, et al. Recessive variants in plakophilin-2 contributes to early-onset arrhythmogenic cardiomyopathy with severe heart failure. *Europace.* 2019;21:970–977.
 89. Martewicz S, Luni C, Serena E, et al. Transcriptomic characterization of a human in vitro model of arrhythmogenic cardiomyopathy under topological and mechanical stimuli. *Ann Biomed Eng.* 2019;47:852–865.
 90. Chen P, Li Z, Yu B, Ma F, Li X, Wang DW. Distal myopathy induced arrhythmogenic right ventricular cardiomyopathy in a pedigree carrying novel DSG2 null variant. *Int J Cardiol.* 2020;298:25–31.
 91. Wang Y, Li C, Shi L, et al. Integrin β 1D deficiency-mediated RyR2 dysfunction contributes to catecholamine-sensitive ventricular tachycardia in arrhythmogenic right ventricular cardiomyopathy. *Circulation.* 2020;141:1477–1493.
 92. Wang L, Liu S, Zhang H, Hu S, Wei Y. Arrhythmogenic cardiomyopathy: identification of desmosomal gene variations and desmosomal protein expression in variation carriers. *Exp Ther Med.* 2018;15:2255–2262.
 93. Chen K, Rao M, Guo G, Chen X, Chen L, Song J. Sarcomere variants in arrhythmogenic cardiomyopathy: pathogenic factor or bystander? *Gene.* 2019;687:82–89.
 94. Lin Y, Huang J, He S, et al. Case report of familial sudden cardiac death caused by a DSG2 p.F531C mutation as genetic background when carrying with heterozygous KCNE5 p.D92E/E93X mutation. *BMC Med Genet.* 2018;19:148.
 95. Chen L, Rao M, Chen X, et al. A founder homozygous DSG2 variant in East Asia results in ARVC with full penetrance and heart failure phenotype. *Int J Cardiol.* 2019;274:263–270.
 96. Zheng G, Jiang C, Li Y, et al. TMEM43-S358L mutation enhances NF- κ B-TGF β signal cascade in arrhythmogenic right ventricular dysplasia/cardiomyopathy. *Protein Cell.* 2019;10:104–119.
 97. Chen K, Song J, Wang Z, Rao M, Chen L, Hu S. Absence of a primary role for TTN missense variants in arrhythmogenic cardiomyopathy: from a clinical and pathological perspective. *Clin Cardiol.* 2018;41:615–622.
 98. Rao M, Guo G, Li M, et al. The homozygous variant c.245G > A/p.G82D in PNPLA2 is associated with arrhythmogenic cardiomyopathy phenotypic manifestations. *Clin Genet.* 2019;96:532–540.
 99. Buljubasic F, El-Battrawy I, Lan H, et al. Nucleoside diphosphate kinase B contributes to arrhythmogenesis in human-induced pluripotent stem cell-derived cardiomyocytes from a patient with arrhythmogenic right ventricular cardiomyopathy. *J Clin Med.* 2020;9, E486.
 100. Chen L, Song J, Chen X, et al. A novel genotype-based clinicopathology classification of arrhythmogenic cardiomyopathy provides novel insights into disease progression. *Eur Heart J.* 2019;40:1690–1703.
 101. Liang E, Wu L, Fan S, et al. Bradyarrhythmias in arrhythmogenic right ventricular cardiomyopathy. *Am J Cardiol.* 2019;123:1690–1695.
 102. Wu L, Bao J, Liang E, et al. Atrial involvement in arrhythmogenic right ventricular cardiomyopathy patients referred for ventricular arrhythmias ablation. *J Cardiovasc Electrophysiol.* 2018;29:1388–1395.
 103. Akdis D, Chen K, Saguner AM, et al. Clinical characteristics of patients with a right ventricular thrombus in arrhythmogenic right ventricular cardiomyopathy. *Thromb Haemost.* 2019;119:1373–1378.
 104. Gong S, Wei X, Liu G, Wu F, Chen X. Arrhythmogenic right ventricular cardiomyopathy with multiple thrombi and ventricular tachycardia of atypical left branch bundle block morphology. *Int Heart J.* 2018;59:652–654.
 105. Hu ZC, Wu LM, Liu SY, et al. ARVC clinical characteristics of cardiomyopathies complicated with ventricular thrombosis (in Chinese). *Natl Med J China (Peking).* 2019;99:3587–3591.
 106. Wang M, Chen K, Chen X, Chen L, Song J, Hu S. Endomyocardial biopsy in differential diagnosis between arrhythmogenic right ventricular cardiomyopathy and dilated cardiomyopathy: an in vitro simulated study. *Cardiovasc Pathol.* 2018;34:15–21.
 107. He J, Xu J, Li G, et al. Arrhythmogenic left ventricular cardiomyopathy: a clinical and CMR study. *Sci Rep.* 2020;10:533.
 108. Chen X, Li L, Cheng H, et al. Early left ventricular involvement detected by cardiovascular magnetic resonance feature tracking in arrhythmogenic right ventricular cardiomyopathy: the effects of left ventricular late gadolinium enhancement and right ventricular dysfunction. *J Am Heart Assoc.* 2019;8, e012989.
 109. Shen MT, Yang ZG, Diao KY, et al. Left ventricular involvement in arrhythmogenic right ventricular dysplasia/cardiomyopathy predicts adverse clinical outcomes: a cardiovascular magnetic resonance feature tracking study. *Sci Rep.* 2019;9:14235.
 110. Li GL, Saguner AM, Akdis D, Fontaine GH. Value of a novel 16-lead High-Definition ECG machine to detect conduction abnormalities in structural heart disease. *Pacing Clin Electrophysiol.* 2018;41:643–655.
 111. Xue SL, Hou XF, Sun KY, et al. Microvolt T-wave alternans complemented with electrophysiologic study for prediction of ventricular tachyarrhythmias in patients with arrhythmogenic right ventricular cardiomyopathy: a long-term follow-up study. *Chin Med J.* 2019;132:1406–1413.
 112. Zhang P, Liang JJ, Cai C, et al. Characterization of skin sympathetic nerve activity in patients with cardiomyopathy and ventricular arrhythmia. *Heart Rhythm.* 2019;16:1669–1675.
 113. Song JP, Chen L, Chen X, et al. Elevated plasma β -hydroxybutyrate predicts adverse outcomes and disease progression in patients with arrhythmogenic cardiomyopathy. *Sci Transl Med.* 2020;12, eaay8329.

114. Cheedipudi SM, Hu J, Fan S, et al. Exercise restores dysregulated gene expression in a mouse model of arrhythmogenic cardiomyopathy. *Cardiovasc Res.* 2020;116:1199–1213.
115. Yin K, Ding L, Li Y, Hua W. Long-term follow-up of arrhythmogenic right ventricular cardiomyopathy patients with an implantable cardioverter-defibrillator for prevention of sudden cardiac death. *Clin Cardiol.* 2017;40:216–221.
116. Wei W, Liao H, Xue Y, et al. Long-term outcomes of radiofrequency catheter ablation on ventricular tachycardias due to arrhythmogenic right ventricular cardiomyopathy: a single center experience. *PLoS One.* 2017;12, e0169863.
117. Xie S, Desjardins B, Kubala M, et al. Association of regional epicardial right ventricular electrogram voltage amplitude and late gadolinium enhancement distribution on cardiac magnetic resonance in patients with arrhythmogenic right ventricular cardiomyopathy: implications for ventricular tachycardia ablation. *Heart Rhythm.* 2018;15:987–993.
118. Gao M, Liu Q, Chen L. Cardiac amyloidosis as a rare cause of heart failure: a case report. *Medicine (Baltim).* 2019;98, e15036.
119. Zhao W, Wu X, Wang Z, et al. Epigenetic regulation of phosphodiesterase 4d in restrictive cardiomyopathy mice with cTnI mutations. *Sci China Life Sci.* 2020;63:563–570.
120. Wang B, Wan X, Li Y, Xie M. Endocardial fibrosis complicated with a great amount of fat accumulation in subendocardium: a rare form of restrictive cardiomyopathy. *Eur Heart J.* 2019;40:1740–1741.
121. Liu S, Ren W, Zhang J, et al. Incremental value of the tissue motion of annular displacement derived from speckle-tracking echocardiography for differentiating chronic constrictive pericarditis from restrictive cardiomyopathy. *J Ultrasound Med.* 2018;37:2637–2645.
122. Quan J, Jia Z, Lv T, et al. Green tea extract catechin improves cardiac function in pediatric cardiomyopathy patients with diastolic dysfunction. *J Biomed Sci.* 2019;26:32.
123. Zhao Y, Feng Y, Zhang YM, et al. Targeted next-generation sequencing of candidate genes reveals novel mutations in patients with dilated cardiomyopathy. *Int J Mol Med.* 2015;36:1479–1486.
124. Zhou X, Chen M, Song H, et al. Comprehensive analysis of desmosomal gene mutations in Han Chinese patients with arrhythmogenic right ventricular cardiomyopathy. *Eur J Med Genet.* 2015;58:258–265.
125. Bao JR, Wang JZ, Yao Y, et al. Screening of pathogenic genes in Chinese patients with arrhythmogenic right ventricular cardiomyopathy. *Chin Med J.* 2013;126:4238–4241.

Edited by Yi Cui and Yan-Gang Ren