



Original Article

The role of tunica vaginalis flap in staged repair of hypospadias



Yogender S. Kadian ^{a,*}, Mahavir Singh ^b, Kamal N. Rattan ^a

^a Department of Paediatric Surgery, Pt B D Sharma Post Graduate Institute of Medical Sciences, Rohtak, Haryana, India

^b Department of Surgery, Pt B D Sharma Post Graduate Institute of Medical Sciences, Rohtak, Haryana, India

Received 12 March 2016; received in revised form 7 June 2016; accepted 10 October 2016
Available online 28 November 2016

KEYWORDS

Hypospadias;
Chordee;
Neourethra;
Tunica vaginalis flap

Abstract *Objective:* The surgical repair of hypospadias is done in two stages in a select group of patients with severe anomaly. The first stage (I) procedure consists of correction of penile shaft curvature and second stage (II) repair involves the creation of a neourethra. This neourethra needs a cover of an intermediate layer in order to have good functional and cosmetic results. Among the various local flaps, tunica vaginalis flap is a good option for the use as an intermediate layer.

Methods: We have managed 22 patients of chordee with hypospadias by staged repair. In Stage I, chordee correction was done by dividing the urethral plate and covering the penile shaft with dorsal prepuce flaps. In Stage II, a neourethra was created and covered with tunica vaginalis flap either through the same incision (14/22) or via a subcutaneous tunnel (8/22). An indwelling catheter was kept for 10 to 12 days.

Results: Eighteen (81.8%) patients had successful functional and cosmetic repair. Two patients (9.1%) had urethrocutaneous fistula of which one healed on subsequent dilatation while the other one (4.5%) needed repair. Overall fistula formation rate was 4.5%. In two patients, the external urinary meatus could be made upto subglanular or coronal level.

Conclusion: Staged repair of chordee with hypospadias is valuable in selected group of patients and tunica vaginalis flap is an excellent intermediate layer to cover the neourethra. However preoperative counseling is particularly essential in patients where the external urinary meatus can be created at coronal or subglanular level.

© 2017 Editorial Office of Asian Journal of Urology. Production and hosting by Elsevier B.V. This is an open access article under the CC BY-NC-ND license (<http://creativecommons.org/licenses/by-nc-nd/4.0/>).

* Corresponding author. 8-UH Medical Campus PGIMS, Rohtak, Haryana, India.
E-mail address: yogarin@gmail.com (Y.S. Kadian).
Peer review under responsibility of Second Military Medical University.

1. Introduction

Hypospadias is one of the most common congenital anomalies occurring in approximately 1 of 200 to 1 of 300 live birth [1]. It is usually accompanied by a band of fibrous tissue extending from the abnormal meatus to the glans and this band shortens the ventral aspect of penile shaft and results in the downward curvature (chordee). In hypospadias patients where the chordee is severe many surgeons have elected to proceed with a planned two-stage procedure to minimize complications and improve the outcome [2–5]. The staged repair of hypospadias is essentially consist of two stages wherein Stage I repair involve the complete straightening of penile shaft and in Stage II neourethra is created by rolling out ventral penile shaft skin. This neourethra always need a cover of intermediate layer for good functional and cosmetic results. However, there are not enough reports in literature regarding the choice of intermediate layer for covering the neourethra [6]. There are various available options of different flaps or free grafts to be used as an intermediate layer but tunica vaginalis flap is more frequently used because of its inherent advantages over others [7–10]. In this study of 22 patients of chordee with hypospadias, we are presenting our experience of using tunica vaginalis flap as an intermediate layer for cover of neourethra in second stage repair.

2. Materials and methods

In this study, the analysis of data of 22 patients of hypospadias with chordee was done regarding the functional outcome, fistula rate and cosmesis. These patients were managed by staged repair over a period of 4 years between January, 2010 to December, 2013. The meatal location before correction of the chordee was distal penile in six, mid penile in five, proximal penile/penoscrotal in nine. In two patients the meatus was at coronal level with severe chordee and the distal urethra was hypoplastic and managed by staged repair. Patient age at Stage I repair ranged from 2.5 years to 14 years (mean 7.2 years). Stage II was performed after a minimum of 6 months after the first stage (6 months–2 years). This neourethra was covered by tunica vaginalis flap in all patients. The hypospadias patients with undescended testis or intersex disorder were not included in this study.

2.1. Surgical technique

All patients were operated under general anesthesia with caudal block. A circular incision was given a few mm proximal to coronal level around the penile shaft. The fibrous urethral plate was transected and hypoplastic corpus spongiosum was excised upto the level of normal urethra surrounded by normal spongiosum. Straightening of the penile shaft was confirmed by Gittes test and two patients needed dorsal plication. Then the dorsal prepuce was divided into two equal halves (Byar's flaps) and rotated ventrally to cover the penile shaft. A small midline incision was given into glanular urethra and a portion of prepuce flap was put into place to widen the granular groove. An indwelling catheter was put in place into neomeatus which was shifted proximally and compressive dressing was done. Postoperative

patient were given antibiotics and analgesics. The catheter was removed after 5 days and patients were discharged.

2.2. Stage II repair

The neourethra was created from the strip of ventral skin by making a 'U' shaped incision and this strip was tubularized over an 8 or 10 French Gauge catheter with 6-0 vicryl suture from the level of external meatus upto glans (Fig. 1). However, in 2/22 patients neourethra was created only upto subglanular/coronal level because of flat glans. A second layer of interrupted sutures were applied over the neourethra. Then one testicle was brought out through a transverse scrotal incision (8/22) or via the same incision as for creating neourethra (14/22). The tunica vaginalis was incised and reconfigured as a flap. This flap was then transferred over the neourethra either through the same incision (14/22) or via a subcutaneous tunnel (8/22). The penile shaft skin was closed (Fig. 1). The respective testicle was fixed to scrotal dartos with 4-0 vicryl suture attaching the left over rim of tunica vaginalis with the dartos. The scrotal incision was closed over a pennrose drain (4/8). Post operatively patients were given intravenous antibiotics, cefotaxime and amikacin for 5–7 days. The scrotal drain was removed after 48 h and the dressing was changed on 4th, 7th and 10th postoperative days. An indwelling catheter was kept *in situ* for 10–12 days and no patient required suprapubic diversion.

3. Results

All patients were discharged after removal of indwelling catheter and followed up in out-patient clinic on weekly interval for 1 month and then monthly for 6 months. The maximum follow-up is upto 3 years for earlier operated patients. The neourethra was calibrated with a urethral sound/dilator regularly in all patients in outpatient department only upto first two to three follow-up visits. There was urinary leak from the original meatus site in two patients who needed urethral dilatation under anesthesia. The urinary leak stop in one patient after 3 months and one had persistent leak. This fistula was closed after 6 month of repair. Overall 81.8% (18/22) of patients had successful functional and cosmetic repair. Two patients (9.1%) had urethrocutaneous fistula of which one healed on subsequent dilatation while the other one (4.5%) needed repair and rate of fistula formation was 4.5% in the present study. In two patients, the external meatus was at subglanular area and it was well accepted by the patients.

4. Discussion

The choice of technique of repair of hypospadias largely depends on the components of this anomaly namely urethral plate size, presence or absence of chordee, size of phallus, location of meatus and to some extent the personal experience of the surgeon. The primary goal in management is to straighten the penile shaft and bring the external urinary meatus into glanular area. In patients where division of urethral plate become necessary to correct the chordee, the choice lies either between staging the procedure or other single option well described in literature.

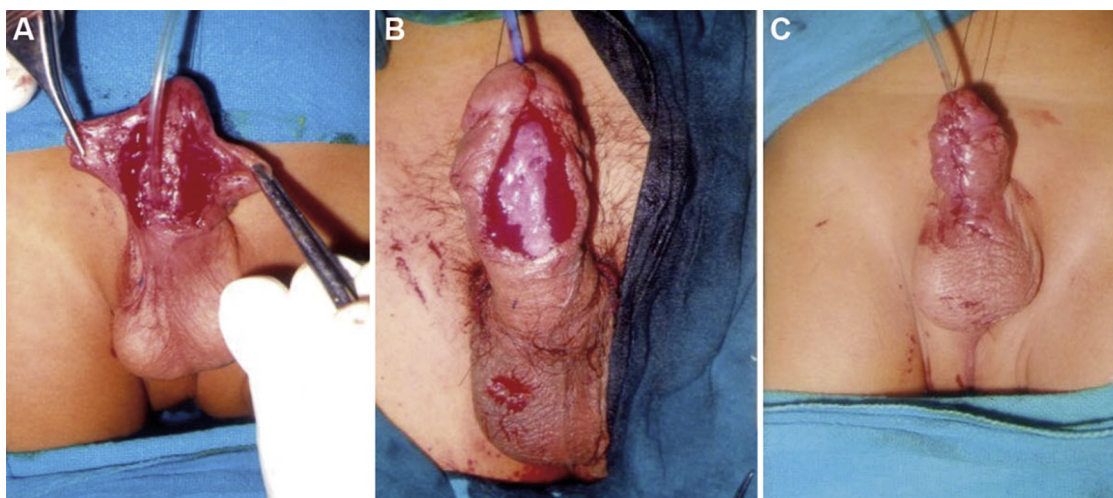


Figure 1 (A) The dissected ventral shaft skin to create neourethra in Stage II repair. (B) The neourethra covered with tunica vaginalis flap. (C) The completed repair.

The two-stage correction of hypospadias is well established procedure and it suits most of the patients from penoscrotal to distal penile variety [5]. The vascularized dorsal skin flap is available to cover the raw area created as a result of chordee correction in 1st stage and this skin is used to create neourethra in 2nd stage. In a recent 20 years review of primary severe hypospadias, the staged repair has been reported to have lower complication rate that is a 10% fistula/dehiscence and a 6% stricture/stenosis rate but it has not commented on the use intermediate layer between neourethra and penile skin sutures by different authors [6].

In present study, we have managed 22 patients of hypospadias with two-stage repair and tunica vaginalis has been used as a intermediate layer to cover the neourethra. For staged repair of hypospadias, the different technique have been described but the surgical concept of Theirsch and Duplay remains the same [3,4]. The Stage I repair involves the correction of chordee and using the dorsal prepuce flaps as cover for penile shaft. In present study, chordee correction was done by dividing the urethral plate and dorsal plication was needed only in 2/22 patients and none of the patient required ventral corporal lengthening. It has also been observed in literature that curvature so severe to require ventral lengthening appears to be rare and there are chances of recurrence of chordee even after the ventral lengthening procedures [6].

The Stage II involves the creation of neourethra from the ventral penile shaft skin. In present study, this neourethra was covered with a tunica vaginalis flap. This flap is reported to have many advantages in the form of good vascularity, easy availability and not being affected by penile disorders. Snow [7] used this flap for the first time in wrapping the neourethra with good results. Since then many authors have augmented the repairs of hypospadias and complex fistula by using this flap [8,11,12]. The technique of harvesting the tunica vaginalis flap is simple but meticulous dissection is needed to avoid the injury to spermatic vessels, vas deference, epididymis or testis. This flap is then transferred over the neourethra either via same incision as per urethroplasty or by tunnel technique [13] as also done in the present study (14/22 and 8/22 patients).

Complications reported in hypospadias repair are fistula formation, stenosis, diverticulum formation and tunica vaginalis flap complications are scrotal haematoma or abscess in range of 2%–4% [7,14]. The commonest one is fistula formation and reported incidence varies as low as 3% to as high as 50% [6,15,16]. In the present study, fistula occurred in 2/22 (9.9%) but subsequent repair needed only in one patient (4.54%) which is acceptable incidence. To avoid scrotal haematoma we have to put scrotal drain in four patients at the time of surgery and in rest there was complete hemostasis. No scrotal abscess occurred in the present study. Other reported complications like ascent of ipsilateral testis or penile torque [17] have not been observed in our patients, but in two patients the external urinary meatus could be achieved upto coronal/subglanular level. In patients where local anatomy does not favour extending the neourethra upto the glans a subglanular or coronal meatus is also acceptable by patients and their family but a pre-repair counseling with family is of utmost importance. Moreover, it is well established that the meatal position at the coronal or subglanular level can be functional and even considered normal [18].

5. Conclusion

Although our study sample is small as compare to experience of other reports and follow-up is maximum of 3 years, we want to highlight the point that the staged repair of hypospadias is still a good option in selected group of patients of hypospadias and that tunica vaginalis flap cover of neourethra in 2nd stage gives good results.

Conflicts of interest

The authors declare no conflict of interest.

References

- [1] Baskin LS, Ebberts MB. Hypospadias: anatomy, etiology and technique. *J Pediatr Surg* 2006;41:463–72.
- [2] Bracka A. Hypospadias repair: the stage alternative. *Br J Urol* 1995;76(Suppl. 3):31–41.

- [3] Greenfield SP, Sadler BT, Wan J. Two stage repair for severe hypospadias. *J Urol* 1993;152:498–501.
- [4] Amukele SA, Stock JA, Hanna MK. Management and outcome of complex hypospadias repairs. *J Urol* 2005;174:1540–3.
- [5] Arshad AR. Hypospadias repair: Byar's two stage operation revisited. *Br J Plast Surg* 2005;58:481–6.
- [6] Castagnetti M, El-Ghoneimi A. Surgical management of primary severe hypospadias in children: systematic 20 years review. *J Urol* 2010;184:1469–74.
- [7] Snow BW. Use of tunica vaginalis to prevent fistulas in hypospadias surgery. *J Urol* 1986;138:861–3.
- [8] Nandoo YR. Role of tunica vaginalis interposition layer in hypospadias surgery. *Indian J Plast Surg* 2006;39:15–6.
- [9] Yamataka A, Ando K, Lane GJ, Miyano T. Pedicled external spermatic fascia flap for urethroplasty in hypospadias and closure of urethrocutaneous fistula. *J Pediatr Surg* 1998;33:1788–9.
- [10] Motiwala HG. Dartos flap: an aid to urethral reconstruction. *Br J Urol* 1993;72:260–2.
- [11] Kadian YS, Rattan KN, Singh J, Singh M, Kajal P, Parihar P. Tunica vaginalis: an aid in hypospadias fistula repair: our experience of 14 cases. *Afr J Pediatr Surg* 2011;8:164–7.
- [12] Kirkali Z. Tunica vaginalis: an aid in hypospadias surgery. *Br J Urol* 1990;65:530–2.
- [13] Routh JC, Walpeol JJ, Reinberg Y. Tunneled tunica vaginalis flap is an effective technique for recurrent urethrocutaneous fistulas following tubularised incised plate urethroplasty. *J Urol* 2006;176:1578–81.
- [14] Snow BW, Castwright PC, Unger K. Tunica vaginalis blanket wrap to prevent urethrocutaneous fistula: an 8 years experience. *J Urol* 1995;153:472–3.
- [15] Horton CE, Devine CJ, Graham JK. Fistulas of the penile urethra. *Plast Reconstr Surg* 1980;66:407–18.
- [16] Retik AB, Baur SB, Mandell J, Peters CA, Colodry A, Atala A. Management of severe hypospadias with a 2-stage repair. *J Urol* 1994;152:749–52.
- [17] Paltaras JG, Rushton HG. Penile torquing after the use of tunica vaginalis blanket wrap as an aid in hypospadias repair. *J Urol* 1999;161:934–5.
- [18] Fichtner J, Filipas D, Moltrie AM, Voges GE, Hohenfellner R. Analysis of meatal location in 500 men: wide variation questions need for meatal advancement in all pediatric anterior hypospadias cases. *J Urol* 1995;154:833–4.