

Characteristics of Earlier Versus Delayed Presentation of Very Late Drug-Eluting Stent Thrombosis: An Optical Coherence Tomographic Study

Seung-Yul Lee, MD;* Jung-Min Ahn, MD;* Gary S. Mintz, MD; Seung-Ho Hur, MD; So-Yeon Choi, MD; Sang-Wook Kim, MD; Jin Man Cho, MD; Soon Jun Hong, MD; Jin Won Kim, MD; Young Joon Hong, MD; Sang-Gon Lee, MD; Dong-Ho Shin, MD, MPH; Jung-Sun Kim, MD; Byeong-Keuk Kim, MD; Young-Guk Ko, MD; Donghoon Choi, MD; Yangsoo Jang, MD; Seung-Jung Park, MD; Myeong-Ki Hong, MD

Background—The pathophysiology underlying very late drug-eluting stent (DES) thrombosis is not sufficiently understood. Using optical coherence tomography, we investigated characteristics of very late stent thrombosis (VLST) according to different onset times.

Methods and Results—A total of 98 patients from 10 South Korean hospitals who underwent optical coherence tomography for evaluation of very late DES thrombosis were retrospectively included in analyses. VLST occurred at a median of 55.1 months after DES implantation. All patients were divided into 2 equal groups of earlier versus delayed presentation of VLST, according to median onset time. In total, 27 patients were treated with next-generation DES and 71 with first-generation DES. Based on optical coherence tomography findings at thrombotic sites, main VLST mechanisms were as follows, in descending order: neoatherosclerosis (34.7%), stent malapposition (33.7%), and uncovered struts without stent malapposition or evagination (24.5%). Compared with patients with earlier VLST, patients with delayed VLST had lower frequency of uncovered struts without stent malapposition or evagination (34.7% versus 14.3%, respectively; $P=0.019$). Conversely, the frequency of neoatherosclerosis was higher in patients with delayed versus earlier VLST (44.9% versus 24.5%, respectively; $P=0.034$). The frequency of stent malapposition was not different between patients with earlier and delayed VLST (34.7% versus 32.7%, respectively; $P=0.831$). The frequency of stent malapposition, evagination, and uncovered struts was still half of delayed VLST.

Conclusions—The pathological mechanisms of very late DES thrombosis changed over time. Delayed neointimal healing remained a substantial substrate for VLST, even long after DES implantation. (*J Am Heart Assoc.* 2017;6:e005386. DOI: 10.1161/JAHA.116.005386.)

Key Words: coronary artery disease • drug-eluting stent • optical coherence tomography

Stent thrombosis is a potentially life-threatening complication of stent therapy, even though overall rates of early and late drug-eluting stent (DES) thrombosis have been halved

from $\approx 3.0\%$ to 1.5% with advances in stent design and pharmacotherapy.^{1–3} Given the lack of consistent clinical protocols for cessation of P2Y₁₂ inhibitor therapy beyond

From the Department of Internal Medicine, Sanbon Hospital, Wonkwang University College of Medicine, Gunpo, Korea (S.-Y.L.); Department of Cardiology, Heart Institute, Asan Medical Center, University of Ulsan, Seoul, Korea (J.-M.A., S.-J.P.); Cardiovascular Research Foundation, New York, NY (G.S.M.); Department of Cardiology, Keimyung University College of Medicine, Daegu, Korea (S.-H.H.); Division of Cardiology, Ajou University Hospital, Suwon, Korea (S.-Y.C.); Department of Cardiology, Chung-Ang University Medical Center, Seoul, Korea (S.-W.K.); Division of Cardiology, Kyung Hee University School of Medicine, Seoul, Korea (J.M.C.); Department of Cardiology, Korea University Anam Hospital, Seoul, Korea (S.J.H.); Department of Cardiology, Korea University Guro Hospital, Seoul, Korea (J.W.K.); Departments of Cardiology, Chonnam National University Medical School, Gwangju, Korea (Y.J.H.); Department of Cardiology, Ulsan University College of Medicine, Ulsan, Korea (S.-G.L.); Division of Cardiology, Severance Cardiovascular Hospital, Yonsei University Health System, Seoul, Korea (D.-H.S., J.-S.K., B.-K.K., Y.-G.K., D.C., Y.J., M.-K.H.); Cardiovascular Research Institute (D.-H.S., J.-S.K., B.-K.K., Y.-G.K., D.C., Y.J., M.-K.H.) and Severance Biomedical Science Institute (Y.J., M.-K.H.), Yonsei University College of Medicine, Seoul, Korea.

Accompanying Table S1 and Figure S1 are available at <http://jaha.ahajournals.org/content/6/4/e005386/DC1/embed/inline-supplementary-material-1.pdf>

*Dr Seung-Yul Lee and Dr Ahn contributed equally to this paper.

Correspondence to: Myeong-Ki Hong, MD, Division of Cardiology, Severance Cardiovascular Hospital, Yonsei University College of Medicine, 50-1 Yonsei-ro, Seodaemun-gu, Seoul 03722, South Korea. E-mail: mkhong61@yuhs.ac and Seung-Jung Park, MD, Department of Cardiology, Heart Institute, Asan Medical Center, 88-1 Poongnap-dong, Songpa-gu, Seoul 138-736, South Korea. E-mail: sjpark@amc.seoul.kr

Received December 19, 2016; accepted January 27, 2017.

© 2017 The Authors. Published on behalf of the American Heart Association, Inc., by Wiley. This is an open access article under the terms of the Creative Commons Attribution-NonCommercial License, which permits use, distribution and reproduction in any medium, provided the original work is properly cited and is not used for commercial purposes.

1 year after DES implantation,^{4,5} it is important to determine the pathophysiology of DES thrombosis that occurs very late.

A retrospective study and 3 prospective multicenter registry studies using optical coherence tomography (OCT) showed that the morphological features of thrombosed DES include stent malapposition, uncovered DES struts, in-stent neoatherosclerosis, and stent underexpansion.^{6–9} Nevertheless, data on these OCT features remain insufficient, especially for patients with very late DES thrombosis. Using OCT, this study investigated the morphological characteristics of very late DES thrombosis and changes in causative OCT findings over time.

Methods

Study Design and Population

Patients who presented with definite very late stent thrombosis (VLST), as defined by the Academic Research Consortium, were considered eligible.¹⁰ The timing of stent thrombosis was classified as acute (within 24 hours), subacute (1 day to 1 month), late (from 1 month to 1 year), and very late (>1 year) after the index procedure. No patient included in the study experienced stent thrombosis <12 months after stent placement. Stent thrombosis was confirmed by coronary angiography. All patients had the following criteria within a 24-hour window: acute onset of ischemic symptoms at rest, with new ischemic electrocardiographic or echocardiographic changes suggesting acute ischemia; and typical rise and fall in cardiac biomarkers. Patients who were asymptomatic or had evidence of chronic myocardial ischemia were not eligible.

All patients from 10 South Korean hospitals who received an OCT examination for evaluation of VLST were retrospectively identified. Between November 2007 and March 2016, 124 patients presenting with VLST underwent preintervention OCT examination. Among these 124 patients, 18 were excluded for the following reasons: 13 for bare metal stents and 5 for poor-quality OCT images. To avoid the possibility of iatrogenic damage to neointimal tissue, 8 patients who underwent balloon angioplasty before OCT evaluation were also excluded. Consequently, 98 patients treated with DES were analyzed, and all patients presented with a first episode of stent thrombosis. The study protocol was approved by the institutional review board of each institution, and written informed consent was obtained from all enrolled patients at the time of VLST treatment.

The selection of DES at the time of coronary intervention was at the discretion of the physician. Of the 98 DESs in this study, 57 were sirolimus-eluting stents (Cypher; Cordis), 14 were paclitaxel-eluting stents (Taxus; Boston Scientific), 15 were zotarolimus-eluting stents (Endeavor Resolute;

Medtronic), 7 were everolimus-eluting stents (Xience [Abbott Vascular] or Promus [Boston Scientific]), and 5 were biolimus-eluting stents (Nobori [Terumo Corp] or BioMatrix [Biosensors Inc]). A first-generation DES was defined as a sirolimus- or paclitaxel-eluting stent, whereas a next-generation DES was defined as a zotarolimus-, everolimus-, or biolimus-eluting stent. DES implantation was performed using conventional techniques, with all patients recommended to receive aspirin at a maintenance dose of 100 mg daily for an indefinite period and clopidogrel at a maintenance dose of 75 mg daily for at least 1 year.

At VLST onset, percutaneous coronary intervention was performed in all patients. A minimum dose of 100 mg aspirin and a loading dose of 300 mg clopidogrel, 180 mg ticagrelor, or 60 mg prasugrel were administered if patients were not on dual antiplatelet therapy. Unfractionated heparin was administered as an initial bolus of 100 IU/kg, with additional boluses administered during the procedure to achieve an activated clotting time >250 seconds. The decision to administer a glycoprotein IIb/IIIa receptor antagonist or to perform thrombus aspiration was left to the operator. Stent implantation or balloon angioplasty was chosen as the final treatment of VLST by considering the patient's clinical condition.

OCT Examination and Analyses

OCT images were acquired with a commercially available time-domain M2 system or frequency-domain C7 system from LightLab/St. Jude. Detailed OCT procedures were performed

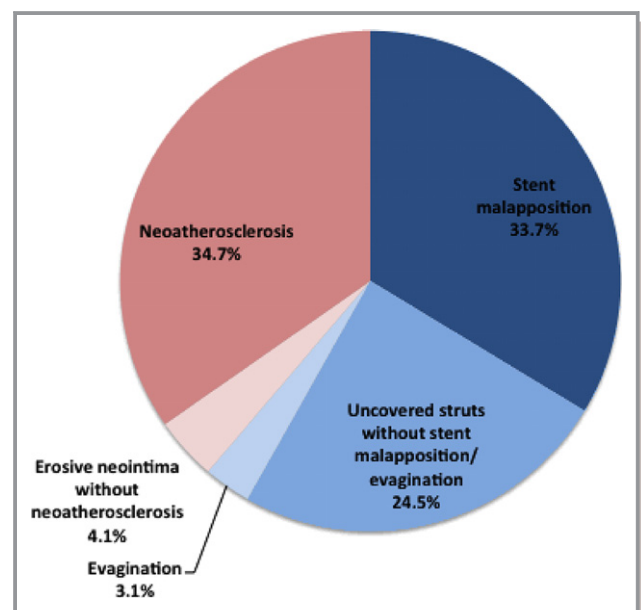


Figure 1. Mechanisms of very late drug-eluting stent thrombosis.

as previously described.¹¹ All OCT images were digitally stored and analyzed using certified offline software (Qlvus; Medis Medical Imaging System) at an independent core laboratory (Cardiovascular Research Center, Seoul, Korea) by 2 independent analysts who were blinded to clinical and angiographic characteristics.

OCT images were measured at 1-mm intervals for quantitative analysis. Stent and lumen outlines were drawn to measure cross-sectional area. For thrombus with low attenuation, visible lumen contours were drawn behind the thrombus. For thrombus with high attenuation, lumen contours were extrapolated behind the thrombus when the lumen contour was visible in ≥ 3 quadrants. Stent cross-sectional area was measured by joining the middle points of the endoluminal signal-rich strut surface of the stent. For stents covered by thrombus with high signal attenuation, stent cross-sectional area was delineated only if at least 1 strut was clearly visible in every quadrant.⁷ A *malapposed* strut was defined as a strut that was detached from the vessel wall, as described previously,¹² and an uncovered strut was defined as

having a neointimal thickness of 0 μm .¹³ If the contour of the vascular wall or neointimal layer above the strut could not be detected because of attenuating thrombus, malapposition or coverage of the corresponding strut was not assessed. The region of interest was a thrombotic site with intracoronary thrombus on consecutive cross-sections and included the site of the minimum lumen cross-sectional area. For qualitative analysis, following OCT findings were analyzed within thrombotic segments. Neointimal rupture was a full-thickness break of the fibrous cap with underlying lipid, and neointimal erosion was a partial-thickness break of the endoluminal neointimal surface.^{14–16} Neoatherosclerosis was defined as lesions with lipid-laden neointima, neointima with calcification, thin-cap fibroatheroma-like neointima, or neointimal rupture.^{11,14} Stent underexpansion was defined as a minimum stent cross-sectional area $< 5.0 \text{ mm}^2$.^{14,17–19} Coronary evagination was defined as the presence of an outward-bulged lumen contour between apposed struts with a maximum bulge depth exceeding strut thickness.²⁰ Inter- and intraobserver agreement for various OCT findings in this core laboratory were

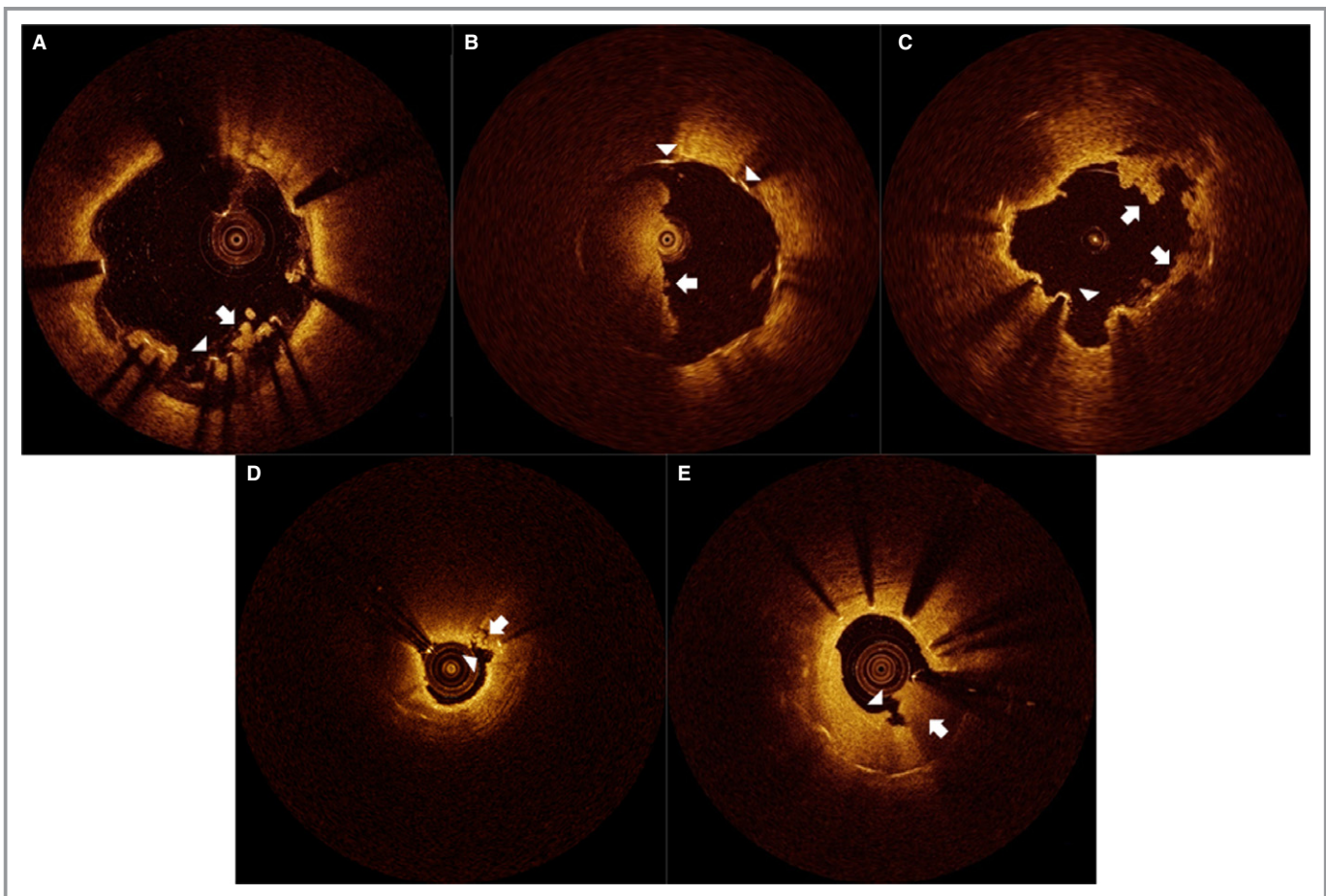


Figure 2. Representative images of very late drug-eluting stent thrombosis, evaluated by optical coherence tomography (OCT). Arrows denote intracoronary thrombus and arrowheads indicate OCT findings: stent malapposition (A), uncovered struts without stent malapposition or evagination (B), coronary evagination (C), ruptured neoatherosclerosis (D), and erosive neointima without neoatherosclerosis (E).

Table 1. Clinical Characteristics

	Onset of Very Late Stent Thrombosis			P Value
	All (n=98)	Earlier (n=49)	Delayed (n=49)	
Age, y	60.8±12.3	59.8±12.4	61.7±12.2	0.448
Men	84 (85.7)	40 (81.6)	44 (89.8)	0.248
Treated hypertension	58 (59.2)	27 (55.1)	31 (63.3)	0.411
Treated diabetes mellitus	30 (30.6)	16 (32.7)	14 (28.6)	0.661
Current smoking	30 (30.6)	12 (24.5)	18 (36.7)	0.188
Total cholesterol, mg/dL	152.0 (126.0–183.0)	143.5 (123.0–186.3)	155.0 (140.0–181.5)	0.262
HDL cholesterol, mg/dL	41.7 (35.0–48.0)	44.0 (36.8–51.1)	40.0 (34.0–47.4)	0.128
LDL cholesterol, mg/dL	86.0 (66.4–107.5)	79.5 (60.8–121.3)	87.5 (72.3–106.8)	0.249
Left ventricular ejection fraction, %	51.7±10.3	53.2±10.7	50.4±9.8	0.185
Clinical diagnosis				0.225
Non-STEMI	48 (49.0)	27 (55.1)	21 (42.9)	
STEMI	50 (51.0)	22 (44.9)	28 (57.1)	
Medications				
Aspirin	83 (84.7)	41 (83.7)	42 (85.7)	0.779
Clopidogrel	23 (23.5)	15 (30.6)	8 (16.3)	0.095
Both aspirin and clopidogrel	21 (21.4)	15 (30.6)	6 (12.2)	0.027
Statin	70 (71.4)	35 (71.4)	35 (71.4)	1.000

Data are presented as number (percentage), mean±SD, or median (interquartile range). HDL indicates high-density lipoprotein; LDL, low-density lipoprotein; STEMI, ST-segment elevation myocardial infarction.

reported previously.^{21,22} For observed OCT findings, the leading mechanism of VLST was determined by consensus.

Statistical Analyses

Statistical analyses were performed using SPSS (version 23; IBM Corp). Data were expressed as number (percentage), mean±SD, or median (interquartile range). Normality of continuous variable distributions was assessed by the Kolmogorov–Smirnov test. Categorical variables were compared using the χ^2 or Fisher exact test, and continuous variables were analyzed with the Student *t* test or Mann–Whitney *U* test.⁷ All reported *P* values were 2-sided, and *P*<0.05 was considered statistically significant.

Results

Mechanisms Causing Very Late DES Thrombosis

The frequency of causative OCT findings for VLST is shown in Figure 1. Representative images of OCT findings are shown in Figure 2. The mechanisms derived from OCT findings were as follows, in descending order: neoatherosclerosis (34.7%), stent malapposition (33.7%), uncovered struts without stent

malapposition or evagination (24.5%), erosive neointima without neoatherosclerosis (4.1%), and evagination (3.1%). Stent underexpansion (18 of 98, 18.4%) was concurrently observed in patients with stent malapposition (n=4), uncovered stents (n=3), and neoatherosclerosis (n=11).

Earlier Versus Delayed Very Late DES Thrombosis

The median time interval between DES implantation and VLST onset (ie, stent age) was 55.1 months (interquartile range 34.4–74.0 months). The annual frequency of patients with VLST is presented in Figure S1. Based on the median onset time of VLST, patients were divided into 2 groups of earlier versus delayed onset of VLST. Clinical characteristics are shown in Table 1. Fewer patients with delayed VLST took both aspirin and clopidogrel compared with those with earlier VLST (12.2% versus 30.6%, *P*=0.027). However, the frequency of VLST mechanisms did not depend on whether both aspirin and clopidogrel were administered (Table S1). Lesional characteristics are presented in Table 2. Types of thrombosed DES differed, with more first-generation DESs in patients with delayed VLST. Detailed OCT findings are shown in Table 3. At sites with thrombosis, the frequency of stent malapposition did not differ between the earlier and delayed VLST groups.

Table 2. Lesional Characteristics

	Onset of Very Late Stent Thrombosis			P Value
	All (n=98)	Earlier (n=49)	Delayed (n=49)	
Reasons for previous stenting				0.209
Stable angina	23 (23.5)	8 (16.3)	15 (30.6)	
Unstable angina	26 (26.5)	13 (26.5)	13 (26.5)	
Acute myocardial infarction	49 (50.0)	28 (57.1)	21 (42.9)	
Lesion location				0.909
Left anterior descending	60 (61.2)	31 (63.3)	29 (59.2)	
Left circumflex	9 (9.2)	4 (8.2)	5 (10.2)	
Right	29 (29.6)	14 (28.6)	15 (30.6)	
Drug-eluting stents				<0.001
First-generation	71 (72.4)	26 (53.1)	45 (91.8)	
Sirolimus	57	21	36	
Paclitaxel	14	5	9	
Next-generation	27 (27.6)	23 (46.9)	4 (8.2)	
Zotarolimus	12	9	3	
Everolimus	10	9	1	
Biolimus	5	5	0	
Stent age, months	55.1 (34.4, 74.0)	35.2 (22.9, 41.3)	73.7 (62.3, 84.2)	<0.001
Stent diameter, mm	3.3 (3.0, 3.5)	3.3 (3.0, 3.5)	3.2 (3.0, 3.5)	0.890
Stent length, mm	28.0 (23.0, 33.0)	31.5 (18.5, 35.8)	28.0 (23.0, 33.0)	0.671
Overlapped stents	21 (21.4)	11 (22.4)	10 (20.4)	0.806
Bifurcation lesions	3 (3.1)	2 (4.1)	1 (2.0)	1.000
TIMI flow				0.384
Grade 0	72 (73.5)	34 (69.4)	38 (77.6)	
Grade 1	4 (4.1)	2 (4.1)	2 (4.1)	
Grade 2	6 (6.1)	2 (4.1)	4 (8.2)	
Grade 3	16 (16.3)	11 (22.4)	5 (10.2)	

Data are presented as number (percentage) or median (interquartile range). TIMI indicates thrombolysis in myocardial infarction.

However, the frequency of uncovered struts without stent malapposition or evagination was lower in patients with delayed VLST (14.3% versus 34.7% in earlier VLST, $P=0.019$). In contrast to results for uncovered struts, neoatherosclerosis was more frequently observed in patients with delayed VLST (44.9% versus 24.5% in earlier VLST, $P=0.034$). The cumulative incidence of these OCT features relative to VLST onset time is shown in Figure 3. Uncovered struts were common in patients with earlier phase VLST ($P=0.002$), whereas neoatherosclerosis was common in patients with delayed-phase VLST ($P=0.031$). Stent malapposition or evagination occurred in one-third of VLST cases in both groups. The frequency of stent malapposition, evagination, and uncovered struts was still half of delayed VLST. For patients with earlier VLST, the frequency of VLST mechanisms was not different

between those treated with first- and next-generation DESs ($P=0.733$) (Figure 4). Patients with VLST were successfully treated with balloon angioplasty ($n=60$) and another DES implantation ($n=38$) during hospitalization.

Discussion

This OCT study had several main findings. First, neoatherosclerosis, stent malapposition, and uncovered struts without stent malapposition or evagination were the main morphological mechanisms for very late DES thrombosis. Second, the frequency of these mechanisms differed depending on VLST onset time, with uncovered struts having earlier onset and neoatherosclerosis having later onset. Third, malapposition was consistently observed regardless of VLST

Table 3. Optical Coherence Tomographic Findings

	Onset of VLST			P Value
	All (n=98)	Earlier (n=49)	Delayed (n=49)	
Full stent length				
Analyzed frames	26.0 (20.0–32.3)	26.0 (20.5–33.0)	26.0 (20.0–32.0)	0.939
Analyzed struts	172.5 (126.5–241.3)	183.0 (142.0–246.0)	163.0 (110.5–221.5)	0.309
Stent CSA, mm ²	7.5 (6.0–8.4)	6.9 (5.5–8.2)	7.8 (6.2–8.5)	0.073
Lumen CSA, mm ²	4.1 (3.0–5.3)	4.4 (3.3–5.8)	4.0 (2.7–4.9)	0.124
Malapposed struts (%)	1.2 (0–5.0)	1.3 (0–5.2)	1.2 (0–4.9)	0.692
Uncovered struts (%)	5.0 (0.9–5.2)	5.0 (2.8–9.9)	2.6 (0–5.1)	0.033
Thrombosed regions				
Analyzed frames	4.0 (3.0–6.0)	3.0 (2.3–5.8)	4.0 (3.0–6.0)	0.484
Analyzed struts	17.0 (11.0–32.3)	18.0 (11.0–34.8)	17.0 (11.0–32.0)	0.588
Stent CSA, mm ²	7.6 (6.1–8.6)	7.2 (6.0–8.4)	7.8 (6.1–8.8)	0.222
Lumen CSA, mm ²	2.5 (1.4–5.4)	2.1 (1.4–5.4)	2.5 (1.5–5.4)	0.736
Minimum stent CSA, mm ²	7.1 (5.5–8.1)	6.5 (5.1–7.7)	7.4 (5.7–8.2)	0.147
Stent underexpansion	18 (18.4)	11 (22.4)	7 (14.3)	0.297
Minimum lumen CSA, mm ²	1.5 (0.9–3.8)	1.4 (0.9–4.4)	1.7 (0.8–3.6)	0.949
Malapposed struts (%)	25.0 (15.0–37.3)	28.0 (14.5–37.3)	20.1 (14.9–38.4)	0.957
Maximal distance of malapposed struts, μm*	710.0 (465.0–1175.0)	890.0 (555.0–1200.0)	520.0 (410.0–1055.0)	0.191
Uncovered struts (%)	14.6 (0–35.0)	33.3 (0–35.1)	0 (0–35.4)	0.057
Primary cause of VLST				
Stent malapposition	33 (33.7)	17 (34.7)	16 (32.7)	0.831
Evagination	3 (3.1)	0 (0)	3 (6.1)	0.242
Uncovered struts without stent malapposition or evagination	24 (24.5)	17 (34.7)	7 (14.3)	0.019
Neoatherosclerosis	34 (34.7)	12 (24.5)	22 (44.9)	0.034
Neointimal erosion without neoatherosclerosis	4 (4.1)	3 (6.1)	1 (2.0)	0.617

Data are presented as number (percentage) or median (interquartile range). CSA indicates cross-sectional area; VLST, very late stent thrombosis.

*Compared within patients having malapposed struts.

onset time and accounted for about one-third of cases. Fourth, the mechanisms for VLST did not differ between first- and next-generation DESs with similar implant duration.

Taniwaki et al reported that the mechanisms for VLST in 58 patients receiving DES (20 next- and 38 first-generation) were malapposition (34.5%), neoatherosclerosis (27.6%), uncovered struts (12.1%), and stent underexpansion (6.9%).⁸ Three other OCT studies also investigated the mechanisms of stent thrombosis but also included bare metal stent thrombosis or late DES thrombosis that might act as confounders.^{6,7,9} These studies were not performed exclusively with patients with very late DES thrombosis. The results of our study differed slightly from those of Taniwaki et al⁸ in the types and frequencies of VLST mechanisms. Different clinical and procedural settings at the time of the index procedure and medical therapy during follow-up may be associated with this discrepancy. It also matters when OCT images were

acquired (median 4.0 days after deocclusion in 69% of the PESTO registry)⁷ or whether traumatic interventions that confound interpretation of the acquired OCT images were performed before OCT evaluation (balloon dilatation in 25.9% of patients in the study by Taniwaki et al⁸). However, OCT examinations in our study were performed at the time of VLST onset, and patients who underwent balloon angioplasty before OCT evaluation were excluded.

Of note, this study identified that uncovered struts and neoatherosclerosis had different contributions to VLST occurrence. According to previous intravascular imaging studies, the neointima of DESs proliferates continuously.^{13,23} With progressive growth of neointimal tissue, a serial OCT study showed that the percentage of uncovered struts in patients receiving DES decreased from 4.4% to 2.3% between 9 months and 2 years of follow-up.¹³ In contrast to uncovered struts, the incidence of thin-cap neoatheroma increased

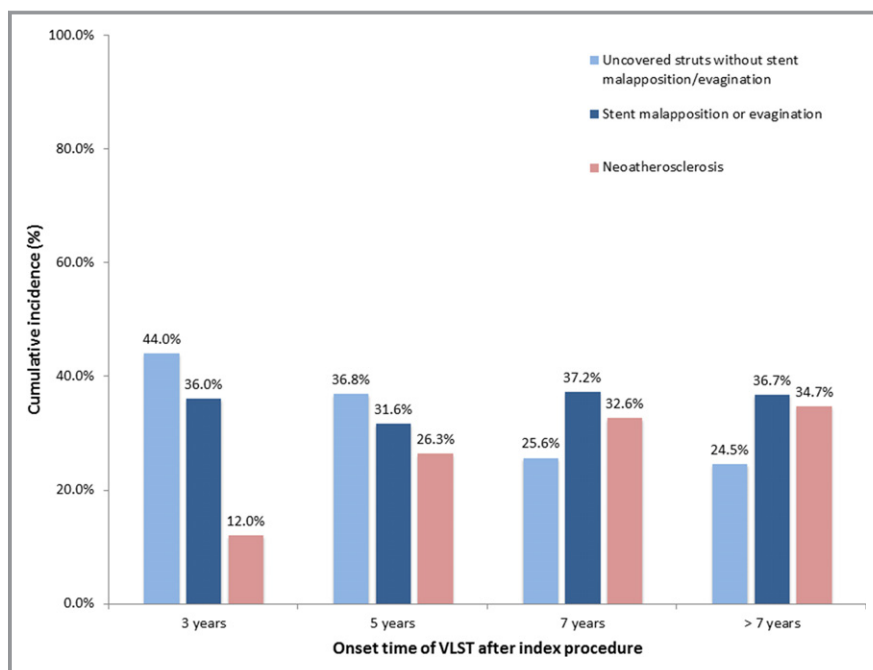


Figure 3. Time-dependent changes in optical coherence tomographic mechanisms causing very late stent thrombosis (VLST). Uncovered struts without stent malapposition or evagination common in early phase VLST, whereas neoatherosclerosis was frequently observed over time. The incidence of stent malapposition or evagination remained constant.

from 3.9% to 13.2%.¹³ These time-dependent changes in neointimal tissue were also observed in patients with very late DES thrombosis. The consistent contribution of stent

malapposition to VLST occurrences in this study was similar to observations in a previous study.⁷ According to the national French PESTO registry, the frequency of stent malapposition

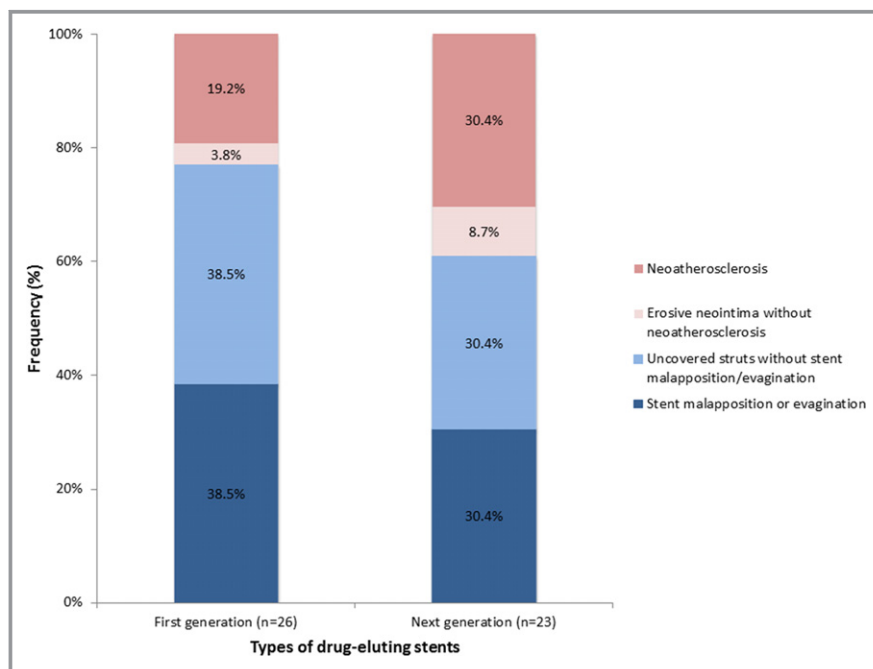


Figure 4. Comparisons between first- and next-generation drug-eluting stents in patients with early phase of very late stent thrombosis. Optical coherence tomographic mechanisms did not differ between types of drug-eluting stents ($P=0.733$).

was 30% to 60% and did not differ among acute, subacute, and late stent thrombosis and VLST.⁷ Our study extended this observation to delayed-phase VLST with a median stent age of 73.7 months. When all our findings are considered, the mechanisms related to delayed neointimal healing (stent malapposition, evagination, and uncovered struts) still represented half of VLST occurrences >4.5 years (55-month median time of VLST onset) after DES implantation.²⁴

Compared with first-generation DESs, next-generation DESs have better strut coverage and apposition on follow-up^{21,25} and are widely used.²⁶ This improvement may be related to thinner struts and upgraded polymers of next-generation DESs. We showed, however, that the underlying mechanisms did not differ in patients with earlier VLST between first- and next-generation DESs, consistent with a previous study.⁸ Based on these results, we assumed that even novel stents shared common DES characteristics that influence the pathological mechanisms of VLST. Nevertheless, this assumption is confined to VLST occurring within 4.5 years of stent implantation, and larger studies are required to generalize the present observation.

This study had several limitations. First, our results may be biased by patient selection and may not reflect true VLST. We assumed that not all patients who presented with VLST underwent OCT imaging. Second, comparisons between first- and next-generation DESs in patients with delayed VLST could not be performed because of the small number of patients treated with next-generation DESs. Therefore, interpretation between DES types should be limited to patients with earlier VLST. Third, intravascular ultrasound assessment as a complementary device was not available,²⁷ thus other causative features such as positive vessel remodeling cannot be evaluated. The study patients were arbitrarily divided into 2 groups based on median VLST onset time. The optical attenuation by thrombus may be a potential source of bias. Finally, although it would be important to interpret the present findings from an overall cohort perspective including early and late stent thrombosis, it was beyond our observations.

In conclusion, the common mechanisms of very late DES thrombosis identified by OCT were neoatherosclerosis, stent malapposition, and uncovered struts without stent malapposition or evagination. Although uncovered struts were associated with early phase VLST, neoatherosclerosis was related to late-phase VLST. In contrast to these findings, stent malapposition consistently remained a significant correlate of VLST over time.

Sources of Funding

This study was supported by a grant from the Korea Healthcare Technology Research and Development Project,

Ministry for Health and Welfare, Republic of Korea (A085136 and HI15C1277); the National Research Foundation of Korea (NRF) grant funded by the Korea government (MEST), Republic of Korea (2015R1A2A2A01002731); and the Cardiovascular Research Center, Seoul, Korea.

Disclosures

None.

References

- Byrne RA, Joner M, Kastrati A. Stent thrombosis and restenosis: what have we learned and where are we going? The Andreas Gruntzig Lecture ESC 2014. *Eur Heart J*. 2015;36:3320–3331.
- Räber L, Magro M, Stefanini G, Kalesan B, van Domburg RT, Onuma Y, Wenaweser P, Daemen J, Meier B, Jüni P, Serruys PW, Windecker S. Very late coronary stent thrombosis of a newer-generation everolimus-eluting stent compared with early-generation drug-eluting stents: a prospective cohort study. *Circulation*. 2012;125:1110–1121.
- Tada T, Byrne RA, Simunovic I, King LA, Cassese S, Joner M, Fusaro M, Schneider S, Schulz S, Ibrahim T, Ott I, Massberg S, Laugwitz KL, Kastrati A. Risk of stent thrombosis among bare-metal stents, first-generation drug-eluting stents, and second-generation drug-eluting stents: results from a registry of 18,334 patients. *JACC Cardiovasc Interv*. 2013;6:1267–1274.
- Levine GN, Bates ER, Blankenship JC, Bailey SR, Bittl JA, Cercek B, Chambers CE, Ellis SG, Guyton RA, Hollenberg SM, Khot UN, Lange RA, Mauri L, Mehran R, Moussa ID, Mukherjee D, Nallamothu BK, Ting HH. 2011 ACCF/AHA/SCAI guideline for percutaneous coronary intervention. A report of the American College of Cardiology Foundation/American Heart Association Task Force on Practice Guidelines and the Society for Cardiovascular Angiography and Interventions. *J Am Coll Cardiol*. 2011;58:44–122.
- Levine GN, Bates ER, Bittl JA, Brindis RG, Fihn SD, Fleisher LA, Granger CB, Lange RA, Mack MJ, Mauri L, Mehran R, Mukherjee D, Newby LK, O’Gara PT, Sabatine MS, Smith PK, Smith SC. 2016 ACC/AHA guideline focused update on duration of dual antiplatelet therapy in patients with coronary artery disease. *Circulation*. 2016;134:e123–e155.
- Guagliumi G, Sirbu V, Musumeci G, Gerber R, Biondi-Zoccai G, Ikejima H, Ladich E, Lortkipanidze N, Matiashvili A, Valsecchi O, Virmani R, Stone GW. Examination of the in vivo mechanisms of late drug-eluting stent thrombosis: findings from optical coherence tomography and intravascular ultrasound imaging. *JACC Cardiovasc Interv*. 2012;5:12–20.
- Souteyrand G, Amabile N, Mangin L, Chabin X, Meneveau N, Cayla G, Vanzetto G, Barnay P, Trouillet C, Rioufol G, Range G, Teiger E, Delaunay R, Dubreuil O, Lhermusier T, Mulliez A, Levesque S, Belle L, Caussin C, Motreff P. Mechanisms of stent thrombosis analysed by optical coherence tomography: insights from the national PESTO French registry. *Eur Heart J*. 2016;37:1208–1216.
- Taniwaki M, Radu MD, Zaugg S, Amabile N, Garcia-Garcia HM, Yamaji K, Jorgensen E, Kelbaek H, Pilgrim T, Caussin C, Zanchin T, Veugeois A, Abildgaard U, Juni P, Cook S, Koskinas KC, Windecker S, Raber L. Mechanisms of very late drug-eluting stent thrombosis assessed by optical coherence tomography. *Circulation*. 2016;133:650–660.
- Nakamura D, Attizzani GF, Toma C, Sheth T, Wang W, Soud M, Aoun R, Tummala R, Leygerman M, Fares A, Mehanna E, Nishino S, Fung A, Costa MA, Bezerra HG. Failure mechanisms and neoatherosclerosis patterns in very late drug-eluting and bare-metal stent thrombosis. *Circ Cardiovasc Interv*. 2016;9:e003785.
- Cutlip DE, Windecker S, Mehran R, Boam A, Cohen DJ, van Es GA, Steg PG, Morel MA, Mauri L, Vranckx P, McFadden E, Lansky A, Hamon M, Krucoff MW, Serruys PW. Clinical end points in coronary stent trials: a case for standardized definitions. *Circulation*. 2007;115:2344–2351.
- Lee SY, Hur SH, Lee SG, Kim SW, Shin DH, Kim JS, Kim BK, Ko YG, Choi D, Jang Y, Hong MK. Optical coherence tomographic observation of in-stent neoatherosclerosis in lesions with more than 50% neointimal area stenosis after second-generation drug-eluting stent implantation. *Circ Cardiovasc Interv*. 2015;8:e001878.
- Im E, Kim BK, Ko YG, Shin DH, Kim JS, Choi D, Jang Y, Hong MK. Incidences, predictors, and clinical outcomes of acute and late stent malapposition detected by optical coherence tomography after drug-eluting stent implantation. *Circ Cardiovasc Interv*. 2014;7:88–96.

13. Kim JS, Hong MK, Shin DH, Kim BK, Ko YG, Choi D, Jang Y. Quantitative and qualitative changes in DES-related neointimal tissue based on serial OCT. *JACC Cardiovasc Imaging*. 2012;5:1147–1155.
14. Kang SJ, Mintz GS, Akasaka T, Park DW, Lee JY, Kim WJ, Lee SW, Kim YH, Lee CW, Park SW, Park SJ. Optical coherence tomographic analysis of in-stent neointimal changes after drug-eluting stent implantation. *Circulation*. 2011;123:2954–2963.
15. Otsuka F, Vorpahl M, Nakano M, Foerst J, Newell JB, Sakakura K, Kutys R, Ladich E, Finn AV, Kolodgie FD, Virmani R. Pathology of second-generation everolimus-eluting stents versus first-generation sirolimus- and paclitaxel-eluting stents in humans. *Circulation*. 2014;129:211–223.
16. Otsuka F, Byrne RA, Yahagi K, Mori H, Ladich E, Fowler DR, Kutys R, Xhepa E, Kastrati A, Virmani R, Joner M. Neointimal changes: overview of histopathologic findings and implications for intravascular imaging assessment. *Eur Heart J*. 2015;36:2147–2159.
17. Sonoda S, Morino Y, Ako J, Terashima M, Hassan AH, Bonneau HN, Leon MB, Moses JW, Yock PG, Honda Y, Kuntz RE, Fitzgerald PJ. Impact of final stent dimensions on long-term results following sirolimus-eluting stent implantation: serial intravascular ultrasound analysis from the SIRIUS trial. *J Am Coll Cardiol*. 2004;43:1959–1963.
18. Kang S, Mintz GS, Park D, Lee S, Kim Y, Whan Lee C, Han K, Kim J, Park S. Mechanisms of in-stent restenosis after drug-eluting stent implantation: intravascular ultrasound analysis. *Circ Cardiovasc Interv*. 2011;4:9–14.
19. Prati F, Romagnoli E, Burzotta F, Limbruno U, Gatto L, La Manna A, Versaci F, Marco V, Di Vito L, Imola F, Paoletti G, Trani C, Tamburino C, Tavazzi L, Mintz GS. Clinical impact of OCT findings during PCI: the CLI-OPCI II study. *JACC Cardiovasc Imaging*. 2015;8:1297–1305.
20. Radu MD, Raber L, Kalesan B, Muramatsu T, Kelbaek H, Heo J, Jorgensen E, Helqvist S, Farooq V, Brugaletta S, Garcia-Garcia HM, Juni P, Saunamaki K, Windecker S, Serruys PW. Coronary evaginations are associated with positive vessel remodelling and are nearly absent following implantation of newer-generation drug-eluting stents: an optical coherence tomography and intravascular ultrasound study. *Eur Heart J*. 2014;35:795–807.
21. Kim JS, Jang IK, Kim JS, Kim TH, Takano M, Kume T, Hur NW, Ko YG, Choi D, Hong MK, Jang Y. Optical coherence tomography evaluation of zotarolimus-eluting stents at 9-month follow-up: comparison with sirolimus-eluting stents. *Heart*. 2009;95:1907–1912.
22. Kwon SW, Kim BK, Kim TH, Kim JS, Ko YG, Choi D, Jang Y, Hong MK. Qualitative assessment of neointimal tissue after drug-eluting stent implantation: comparison between follow-up optical coherence tomography and intravascular ultrasound. *Am Heart J*. 2011;161:367–372.
23. Kang S, Park D, Mintz GS, Lee S, Kim Y, Lee CW, Han K, Kim J, Park S. Long-term vascular changes after drug-eluting stent implantation assessed by serial volumetric intravascular ultrasound analysis. *Am J Cardiol*. 2010;105:1402–1408.
24. Gutierrez-Chico JL, Regar E, Nesch E, Okamura T, Wykrzykowska J, di Mario C, Windecker S, van Es G, Gobbens P, Jni P, Serruys PW. Delayed coverage in malapposed and side-branch struts with respect to well-apposed struts in drug-eluting stents: in vivo assessment with optical coherence tomography. *Circulation*. 2011;124:612–623.
25. Li S, Wang Y, Gai L, Yang T, Liu H, Wang Z, Bai Q, Xu X, Chen Y. Evaluation of neointimal coverage and apposition with various drug-eluting stents over 12 months after implantation by optical coherence tomography. *Int J Cardiol*. 2013;162:166–171.
26. Choi YJ, Kim JB, Cho SJ, Cho J, Sohn J, Cho SK, Ha KH, Kim C. Changes in the practice of coronary revascularization between 2006 and 2010 in the Republic of Korea. *Yonsei Med J*. 2015;56:895–903.
27. Cho YK, Hur SH. Practical application of coronary imaging devices in cardiovascular intervention. *Korean Circ J*. 2015;45:87–95.

SUPPLEMENTAL MATERIAL

Table S1. Frequency of mechanisms of very late drug-eluting stent thrombosis, grouped by the usage of dual antiplatelet therapy (DAPT)

	DAPT at the time of stent thrombosis		p
	Yes (n=21)	No (n=77)	
Mechanisms			0.729
Stent malapposition or evagination	9 (42.9)	27 (35.1)	
Uncovered struts without stent malapposition/evagination	6 (28.6)	18 (23.4)	
Neoatherosclerosis	6 (28.6)	28 (36.4)	
Erosive neointima without neoatherosclerosis	0 (0)	4 (5.2)	

Data are presented as number (%).

Figure S1. The annual frequency of patients with very late drug-eluting stent (DES) thrombosis

