

Mast cells density in fibrotic capsule of enchondroma and well-differentiated chondrosarcoma: a method for histopathologic differentiation

Noushin Jalayer Naderi¹, Shams Shariat Tarabghan², Mohsen Merati³
Mahdi Ashouri⁴, Ali Majidi⁵, Mohammad Javad Kharazi Fard⁶

Oral and Maxillofacial Pathology Dept, Faculty of Dentistry, Shahed University, Tehran, Iran.

Received: 27 June 2011

Revised: 26 September 2011

Accepted: 12 December 2011

Abstract

Background: An enchondroma is a benign and a well-differentiated chondrosarcoma is an invasive chondroid tumor with high recurrence potential. In spite of biologic differences, these two tumors have very similar histopathologic appearance. It has been shown that the biologic nature of the connective tissue around benign and malignant tumors varies in the number of mast cells. The aim of this study was to study the histopathologic distinction of enchondroma and well-differentiated chondrosarcoma using the density of the mast cells in fibrotic capsule.

Methods: Twelve enchondroma and 15 well-differentiated chondrosarcoma were collected from Pathology department of Cancer Institute and Central Pathology department of Imam Khomeini Hospital in Tehran. 3 micron paraffin embedded tissue sections were stained by toluidine blue for mast cells counting. Mast cells were counted in fibrous capsule of all cases. Mast cells counts were accomplished in 10 high power fields. The average number of mast cells in 10HPF was determined as an index for each lesion. Mann-Whitney U test was used for statistical analysis.

Results: Mean index in enchondroma and well-differentiated chondrosarcoma groups were 0.1 ± 0.12 and 0.31 ± 0.33 respectively, showing a significant difference between number of mast cells in the fibrotic capsule in these two lesions ($p=0.028$). Comparison of the corresponding points in ROC curve, showed a cut-off point = 0.15, with positive predictive value of 61%, negative predictive value 71%, specificity of 33.3% and sensitivity of 66.7%, ($p=0.025$).

Conclusion: Average density of the mast cells in the surrounding fibrotic capsules of enchondroma and well-differentiated chondrosarcoma along with other criterions, could be a beneficial factor for histologically differentiation between these two lesions.

Keywords: Enchondroma, Well-differentiated Chondrosarcoma, Mast cell, Toluidine blue staining.

Introduction

An enchondroma is a benign chondroid tumor formed by mature hyaline cartilage and often involves medullary bone. Most of tumors are small with less than 3 cm in

greatest dimension and with limited growth potential. Asymptomatic and small lesions do not need any treatment except periodic follow up (1).

A chondrosarcoma is a slow growing malignant tumor. It is locally invasive and has

1. (Corresponding author) Assistant Professor, Oral and Maxillofacial Pathology Dept, Faculty of Dentistry, Shahed University, Tehran, Iran. noushin_jly85@yahoo.com

2. Professor, Pathology Dept, Institute Cancer, Tehran, Iran

3. Orthodontist, Dental researches center, Faculty of Dentistry, Mashhad University of Medical sciences, Mashhad, Iran. mohsenmerati@gmail.com

4. Oral and Maxillofacial pathologist. m_ashouri86@yahoo.com

5. Graduate of Faculty of Dentistry, Shahed University, Tehran, Iran. alimajidi2008a@yahoo.com

6. Research Advisor, Dental Research Center. Tehran University of Medical Sciences, Tehran, Iran. mj_khf@yahoo.com

high recurrence potential. This tumor can extend to adjacent tissues and may result in limiting the range of joints motion. Surgery is the primary treatment for chondrosarcoma with radical surgical excision being the most effective mode of therapy (1).

Despite biologic differences, these two tumors have the same histologic appearances. The exact distinction between enchondroma and well-differentiated chondrosarcoma is a major problem in bone pathology.

In histologic evaluation, both lesions contain a mass of mature hyaline cartilage with a lobular pattern and small chondrocytes in lacunar spaces. Small to large foci of calcification may be seen (1-3). Because of this similarity, distinction between these two tumors on the basis of pathologic features is not feasible, and differentiation is achieved by clinical, pathologic, radiographic features, and complementary immune histochemical staining (3-7).

These diagnostic methods sometimes have false results and cause problems in diagnosis and treatment procedures. Because of the difference between biologic nature of these two lesions, a distinguishing method for differentiation is necessary for proper identification.

Mast cells are members of the hematologic system that secrete various mediators. These cells play an important role in pathologic, immunologic and physiologic events (8).

The effect of these mediators on tumors includes angiogenesis, suppression of the immune system, destruction of the extracellular matrix, proliferation and apoptosis (9).

It has been reported that mast cells are involved in gastric carcinoma and skin tumors, lung adenocarcinoma, and breast cancer (10-13). These cells often accumulate in the margin of the solid tumors within

stroma of the fibrous tissue that surrounding benign and malignant tumors (14).

According to investigations, the biologic nature of the connective tissue of benign and malignant tumors differs in the pattern of presence of mast cells (13-15-16).

Since the biologic nature of benign and malignant tumors bears an association with the density of mast cells, it seems that we can use this index to distinguish these two tumor. The aim of this study was to explore the difference between mast cells densities within fibrotic capsule surrounding enchondroma and well-differentiated chondrosarcoma.

Methods

The study was a descriptive-analytic, retrospective. Sample cases were collected from archives of Pathology Department of Cancer Institute and Central Pathology Department of Imam Khomeini Hospital between 1999 and 2008. In all cases diagnosed as chondroma, enchondroma, poorly differentiated chondrosarcoma, well differentiated chondrosarcoma and grade I chondrosarcoma were selected.

Proper histopathologic slides with enough capsular tissue were chosen. 12 enchondroma and 15 well-differentiated chondrosarcoma were selected for this study. Toluidine blue was used for mast cells staining. The slides were dried in oven, dipped in alcohol for a few seconds, and then put in Xylol (Xylene) solution for 2 seconds, then the sections were once more dipped in alcohol for a few seconds, and stained by 1% aqueous toluidine blue for 30 seconds. To complete the staining process, the specimens were washed in distilled water, dried, passed through alcohol, and placed in Xylol and mounted one slides.

Table1. The index of mast cells counting in enchondroma and well-differentiated chondrosarcoma groups

<i>Lesion</i>	<i>cases</i>															
Enchondroma	0.3	0.3	0	0	0.1	0	0.2	0.1	0	0	0	0.2				
Well-differentiated chondrosarcoma	0.2	0.2	0.5	0.2	0.1	0	0.1	0.3	0.3	0.7	1.3	0.1	0.3	0.4	0	

Mast cells were counted by light microscopy (Zeiss, Germany) at $\times 1000$ magnification. Mast cells of capsules were counted in 10 high power fields. The average number of mast cells in 10 high power fields was evaluated and determined as an index for each corresponding lesion. Each lesion counts twice and counting was performed blindly.

Statistical Analysis

We calculated the mean of the number of mast cells in 10HPF as an index for each sample and also mean and standard deviation of mast cell index for each lesion. Mann-Whitney test was used to examine the results. All the results were expressed in mean \pm SD. Sensitivity, specificity, positive and negative predictive values were determined. We also conducted receiver operating characteristic (ROC) analysis to measure the effectiveness of mast cells density parameter in differentiating enchondroma and well-differentiated chondrosarcoma. The ROC curve and area under curve were also determined using SPSS (version 15.0, Chicago, US) software. Area under the ROC curve was used as a summary index of diagnostic effectiveness. $P < 0.05$ was considered statistically significant.

Results

With toluidine blue staining, mast cells were blue and contained purple granules (fig 1 and 2).

The minimum average number of mast cells in both enchondroma and well-differentiated chondrosarcoma was 0. The maximum average number of mast cells in enchondroma and well-differentiated chondrosarcoma were 0.3 and 1.3, respectively. The index of mast cells counting in two groups is shown in Table 1.

The average index for enchondroma was 0.1 ± 0.12 and for well-differentiated chondrosarcoma was 0.13 ± 0.33 , which showed a significant difference in the number of mast cells in the fibrous capsule of two lesions ($p = 0.028$).

The area under ROC curve was 0.75

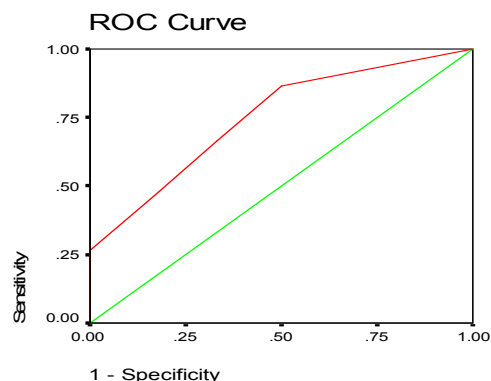


Chart 1. The area under the ROC curve was 0.75. Comparison of the corresponding points in ROC curve, depict a cut-off point = 0.15, with positive predictive value 61%, negative predictive value 71%, specificity of 33.3% and sensitivity of 66.7%, achieved.

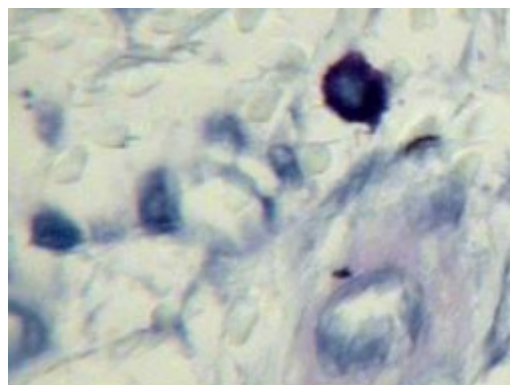


Fig 1. Mast cell within fibrous capsule (Toluidine blue staining, $\times 1000$).

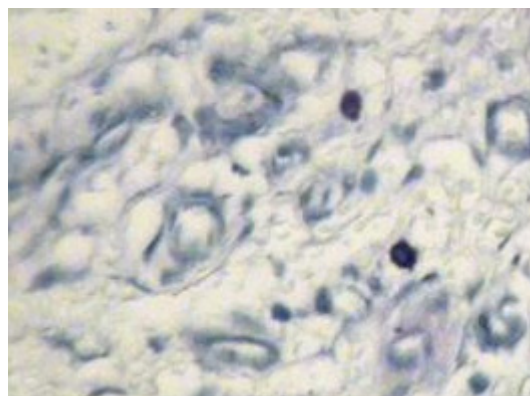


Fig 2. Two mast cells between blood vessels (Toluidine blue staining, $\times 400$).

(Chart 1). Comparison of the corresponding points in ROC curve, revealed a cut-off point = 0.15, with positive predictive value 61%, negative predictive value 71%, specificity of 33.3% and sensitivity of 66.7%, achieved ($p = 0.025$). As a result, if the aver-

age density of mast cells in the fibrous capsule surrounding the lesions was 0.15 or higher, the lesion could be a well-differentiated chondrosarcoma with a probability of 61% and if it was lower than it could be 0.15 could be a enchondroma with probability of 71% (positive predictive value 61% and negative predictive value 71%,).

Discussion

In this study, density of mast cells in fibrous capsule of enchondroma and well-differentiated chondrosarcoma were different. Mast cells density in chondrosarcoma was more than in enchondroma and this difference was statistically significant ($p=0.028$). We found that if the average number of mast cells was 0.15 or higher the lesion should be a well-differentiated chondrosarcoma with the probability of 61%, and if it was less than 0.15 an enchondroma with a probability of 71%.

Previous studies have shown that the mast cells numbers will be increased as a lesion undergoes malignant transformation (17-20).

By increasing the degree of malignancy, mast cells migration will be more and their presence will be more remarkable (13-15-16-21). Previous evidence on increased number of mast cells in malignant lesions versus benign ones is in harmony with findings of the current study which showed an increase in number of mast cells in chondrosarcoma (12,13).

A greater number of mast cells within the capsule of chondrosarcoma could also be an indicative of presence of absorptive cytokines emanating from tumoral tissue. With the biologic activity of tumor, cytokines attract mast cells and by increasing the tumor extent, mast cells attraction will be increased further.

Kessler et al. showed that implantation of tumoral cells within the human fetus causes a 40 folds increase of mast cells density around the implantation site in comparison to normal tissue (17).

In another study, Poole et al, showed that

mast cells migrate towards factors that released from various types of tumors (22).

Release of some chemical materials such as IL-1, IL-3, FGF-2, and SCF from tumor cells and formation of a paracrine loop cause migration of mast cells. The level of these chemical materials in the stroma surrounding the tumors is related to degree of progression, invasion and tumor grade (23-25).

Presence of mast cells in connective tissue around tumors suggests two theories, either, the presence of these cells is induced by tumor and play an active role in carcinogenesis and its intensity, or helps the immune system with its inhibitory activity to arrest the extension of the tumor.

It has been shown that secretory heparin produced by mast cells in the presence of fibroblasts is a powerful inhibitor of growth for tumoral cells. This finding indicates the inhibitory role of mast cells in carcinogenesis (20).

It has been shown that injection of mast cells suspension to animal models causes acceleration of tumor growth, but decreasing the number of mast cells could inhibit tumor growth (26).

Now, this raises a question: 'where do these cells have an inhibitory role and where have a stimulating effect on tumor cells?' Samoszuk et al, found the answer of this question in 2005. They explained the mast cells double role in carcinogenesis: first, mast cells granules contain various active biologic compounds such as heparin, histamine, tryptase and chymase. Some of these mediators have stimulatory effects and some like heparin have inhibitory and stimulatory effects at the same time. There are also other mediators such as fibroblasts and endothelial cells of blood vessels that produced by stromal cells adjacent to mast cells. This mediators affect on tumor growth. Thus, the net effect on tumor growth is a result of numerous and complex interplay of various components of mast cells granules and composition of other cells like fibroblast and vessels endothelium. Second, secretion manner of mast cells

changes on the basis of the environment in which they are located. Different compositions have various roles in different environment (20).

On the basis of mast cells role, it is obvious that these cells have an essential role in pathogenesis of tumors. Hence, it seems that we can control tumor growth using the medications affecting mast cells secretions. It has been shown that inhibition of degranulation of mast cells in animals by disodium cromoglycate (cromolyn) obviously suppresses tumor growth (27).

This study showed that mast cells density within fibrotic capsule of well differentiated chondrosarcoma is more than enchondroma and this difference is statistically significant. As a result, mast cells counting along other criteria can be a useful method in histopathologic differentiating of enchondroma from well-differentiated chondrosarcoma. Arriving at more confident results would be possible by utilizing more cases and study of specific mediators.

Conclusion

Average density of the mast cells in the surrounding fibrotic capsules of enchondroma and well-differentiated chondrosarcoma along with other criterions, could be a beneficial factor for histologically differentiation between these two lesions.

Acknowledgment

This research was completed by financial support of shahed university. We thank Dr S. Nazanin Bashardoost at research center of Mashhad dental school, for her kindly assistance in translation.

References

1. Dorfman HD, Czerniak B. Bone tumors. St. Louis: Mosby; 1998; 253-285, 353-435.
2. Neville BW, Damm DD, Allen CM, Bouquot JE. Oral and maxillofacial pathology. 2th ed. Philadelphia: Saunders. 2002; 571-580.
3. Mirra JM, Gold R, Downs J, Eckardt JJ. A new histologic approach to the differentiation of enchondroma and chondrosarcoma of the bones. A clinicopathologic analysis of 51 cases. Clin Orthop

Relat Res 1985 Dec; 201 :214-237.

4. Flemming DJ, Murphey MD. Enchondroma and chondrosarcoma. Semin Musculoskelet Radiol 2000;4(1):59-71.

5. Gajewski DA, Burnette JB, Murphey MD, Temple HT. Differentiating clinical and radiographic features of enchondroma and secondary chondrosarcoma in the foot. Foot Ankle Int 2006 Apr;27(4):240-244.

6. Amling M, Pösl M, Hentz MW, Priemel M, Delling G. PTHrP and Bcl-2: essential regulatory molecules in chondrocyte differentiation and chondrogenic tumors. Verh Dtsch Ges Pathol 1998;82:160-169.

7. Hameetman L, Kok P, Eilers PH, Cleton-Jansen AM, Hogendoorn PC, Bovée JV. The use of Bcl-2 and PTHLH immunohistochemistry in the diagnosis of peripheral chondrosarcoma in a clinicopathological setting. Virchows Arch 2005 Apr;446(4):430-437. Epub 2005 Mar 3.

8. Church MK, Levi-Schaffer F. The human mast cell. J Allergy Clin Immunol 1997 Feb;99(2): 155-160.

9. Ch'ng S, Wallis RA, Yuan L, Davis PF, Tan ST. Mast cells and cutaneous malignancies. Mod Pathol 2006 Jan;19(1):149-59.

10. Ribatti D, Guidolin D, Marzullo A, Nico B, Annese T, Benaglio V, Crivellato E. Mast cells and angiogenesis in gastric carcinoma. Int J Exp Pathol 2010 Apr 20.

11. Coussens LM, Tinkle CL, Hanahan D, Werb Z. MMP-9 supplied by bone marrow-derived cells contributes to skin carcinogenesis. Cell 2000 Oct 27;103(3):481-490.

12. Takanami I, Takeuchi K, Naruke M. Mast cell density is associated with angiogenesis and poor prognosis in pulmonary adenocarcinoma. Cancer 2000 Jun 15;88(12):2686-2692.

13. Kankkunen JP, Harvima IT, Naukkarinen A. Quantitative analysis of tryptase and chymase containing mast cells in benign and malignant breast lesions. Int J Cancer 1997 Jul 29;72(3):385-388.

14. Fisher ER, Fisher B. Role of mast cells in tumor growth. Arch Pathol 1965 Feb;79:185-191.

15. Aoki M, Pawankar R, Niimi Y, Kawana S. Mast cells in basal cell carcinoma express VEGF, IL-8 and RANTES. Int Arch Allergy Immunol 2003 Mar;130(3):216-223.

16. Ribatti D, Ennas MG, Vacca A, Ferrel F, Nico B, Orru S, Sirigu P. Tumor vascularity and tryptase-positive mast cells correlate with a poor prognosis in melanoma. Eur J Clin Invest 2003 May; 33(5):420-425.

17. Kessler DA, Langer RS, Pless NA, Folkman J. Mast cells and tumor angiogenesis. Int J Cancer 1976 Nov 15;18(5):703-709.

18. Glowacki J, Mulliken JB. Mast cells in hemangiomas and vascular malformations. Pediatrics 1982 Jul;70(1):48-51.

19. Dethlefsen SM, Matsuura N, Zetter BR. Mast

cell accumulation at sites of murine tumor implantation: implications for angiogenesis and tumor metastasis. *Invasion Metastasis* 1994-1995; 14(1-6):395-408.

20. Samoszuk M, Kanakubo E, Chan JK. Degranulating mast cells in fibrotic regions of human tumors and evidence that mast cell heparin interferes with the growth of tumor cells through a mechanism involving fibroblasts. *BMC Cancer* 2005 Sep 21;5:121.

21. Cabanillas-Saez A, Schalper JA, Nicovani SM, Rudolph MI. Characterization of mast cells according to their content of tryptase and chymase in normal and neoplastic human uterine cervix. *Int J Gynecol Cancer* 2002 Jan-Feb;12(1):92-98.

22. Poole TJ, Zetter BR. Stimulation of rat peritoneal mast cell migration by tumor-derived peptides. *Cancer Res* 1983 Dec; 43(12 Pt 1):5857-5861.

23. Reed JA, McNutt NS, Bogdany JK, Albino

AP. Expression of the mast cell growth factor interleukin-3 in melanocytic lesions correlates with an increased number of mast cells in the perilesional stroma: implications for melanoma progression. *J Cutan Pathol* 1996 Dec; 23(6):495-505.

24. Erkiliç S, Erbağcı Z. The significance of mast cells associated with basal cell carcinoma. *J Dermatol* 2001 Jun; 28(6):312-315.

25. Theoharides TC. Mast cells and pancreatic cancer. *The New England Journal of Medicine* 2008, 24; 358(17):1860-1861.

26. Roche WR. The nature and significance of tumour-associated mast cells. *J Pathol* 1986 Feb;148(2):175-182.

27. Ionov ID. Inhibition of mast cell activity as a new approach to anti-cancer therapy. *Int J Radiat Biol* 1991 Jul-Aug;60(1-2):287-291.