

Mechanically retained functional prosthetic rehabilitation of partial lip necrosis: A rare clinical report

Neetu Singh, Saumyendra Vikram Singh, Deeksha Arya

Department of Prosthodontics, King George Medical University, Lucknow, Uttar Pradesh, India

Abstract

Prosthetic rehabilitation plays a crucial role in restoring patients with facial defects to normalcy. Although comprising a small proportion, lip defect plays a pivotal role in drastically diminishing the quality of life of the patient, both functionally and socially, with dwindling confidence and self-esteem. Patients may experience speech impairment, uncontrolled drooling, and unesthetic appearance. In addition, constant exposure of tissues to air leads to drying and crusting of lips. This rare case report of a patient with partial lip necrosis describes her functional, mechanically retained prosthetic rehabilitation, which improved phonetics, esthetics, and function without the need of additional retentive features, increasing convenience and ease of use by the patient and at the same time cutting down cost.

Keywords: Functional rehabilitation, lip necrosis, mechanically retained, silicone

Address for correspondence: Dr. Saumyendra Vikram Singh, 2/273, Viram Khand, Gomti Nagar, Lucknow - 226 010, Uttar Pradesh, India.

E-mail: saumyendravsingh@rediffmail.com

Submitted: 21-Aug-2019, **Revised:** 23-Sep-2019, **Accepted:** 05-Dec-2019, **Publication:** 07-Apr-2020

INTRODUCTION

Prosthetic rehabilitation plays a crucial role in restoring patients with facial defects to normalcy. Although comprising a small proportion, lip defect plays a pivotal role in drastically diminishing the quality of life of patients, both functionally and socially, with dwindling confidence and self-esteem. Lip defects could be of congenital, surgical, or traumatic etiology. Lip cancers constitute 1.4% of oral cancers.^[1] Cases of loss of lip due to necrosis are hardly reported. Normally, surgical reconstruction is the primary treatment rendered for lip defects. Vascularized pedicle flaps from the iliac crest, scapula, fibula, radial forearm, and temporalis are utilized for reconstruction.^[2,3] Surgical rehabilitations, though desirable, are not always feasible for reasons such as compromised tissue bed and risk of

tumor recurrence. In such cases, prosthetic rehabilitation plays a fundamental role in rehabilitation.^[4]

Importance of lower lip defects in speech disarticulation has been elucidated by Robinson and Niiranin.^[5] Other problems experienced include uncontrolled drooling, unesthetic appearance, and constant exposure of tissues to air, leading to drying and crusting. As lips play a fundamental role in consonant phonemic production, reduction in speech intelligibility occurs, especially with bilabial and labiodental phonemes.^[6] Comparatively favorable prosthetic outcome is impeded by tissue resiliency, continuous lip movement, limitations of fabrication material, paucity and inadequacy of anatomical undercuts, and variable patient compliance. Various modes of retention include use of adhesives,

Access this article online	
Quick Response Code:	Website: www.j-ips.org
	DOI: 10.4103/jips.jips_301_19

This is an open access journal, and articles are distributed under the terms of the Creative Commons Attribution-NonCommercial-ShareAlike 4.0 License, which allows others to remix, tweak, and build upon the work non-commercially, as long as appropriate credit is given and the new creations are licensed under the identical terms.

For reprints contact: reprints@medknow.com

How to cite this article: Singh N, Singh SV, Arya D. Mechanically retained functional prosthetic rehabilitation of partial lip necrosis: A rare clinical report. J Indian Prosthodont Soc 2020;20:214-8.

implants, or intraoral prosthetic attachment with magnets. This report discusses the fabrication of mechanically retained silicone inferior lip prosthesis.

CASE REPORT

A 35-year-old female patient was diagnosed with central hemangioma of the mandible about a year back [Figure 1], for which, sodium tetradecyl sulfate was injected into the lesion thrice. Although the lesion subsided, posttreatment necrosis developed involving the right part of the lower lip with some involvement of the upper lip extending up to the ala of the nose. Surgical reconstruction was not immediately advisable because of questionable vascularity of recipient site, and the patient was referred to the department of prosthodontics for prosthetic management. The chief complaint of the patient was unesthetic appearance and drooling of saliva due to partially absent lower lip [Figure 2].

A preliminary combined intraoral and lower lip impression was made with irreversible hydrocolloid impression material (Zelgan; Dentsply, Gurgaon, Haryana, India)

and poured in type III stone (Keldent; Kalabhai, Mumbai, Maharashtra, India), taking care to record the lip without distortion or displacement. This was achieved by increasing the flowability of alginate and loosely confining the lip part of the impression. This was followed by fabrication of a custom tray in acrylic resin (Pyrax; Pyrax Polymars, Roorkee, Uttarakhand, India) with a double spacer. This tray was used for secondary intraoral impression [Figure 3] in addition silicone (Elite HD; Zhermack, Badia Palesine, Italy) and poured in white die stone (Orthokal, Kalabhai, Mumbai, Maharashtra, India) [Figure 4]. One-millimeter thick polyvinyl chloride (PVC) thermoplastic sheet (Soft-tray sheets; Ultradent, South Jordan, Utah) was adapted on the remnant lower lip model to aid in the retention of the trial pattern, which was sculpted in wax on the model and evaluated on the patient in subsequent appointments. The PVC thermoplastic sheet was extended over the entire lower lip till the commissures on either side, till the shadow of mentolabial sulcus externally, and upto the labial vestibule internally, to aid in mechanical retention. This would also facilitate camouflage of future prosthesis margin in areas which are less remarkable.

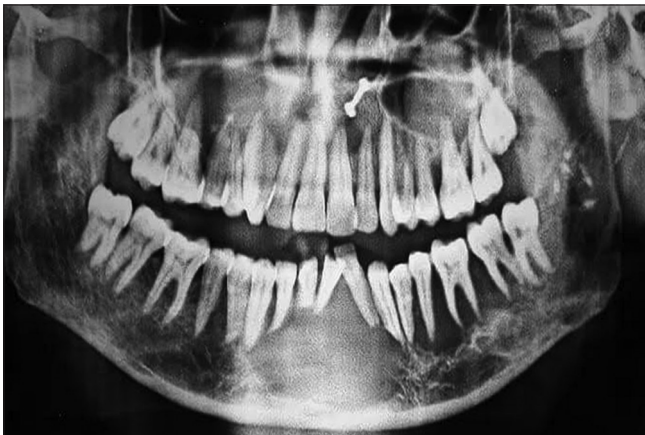


Figure 1: Central hemangioma of the mandible

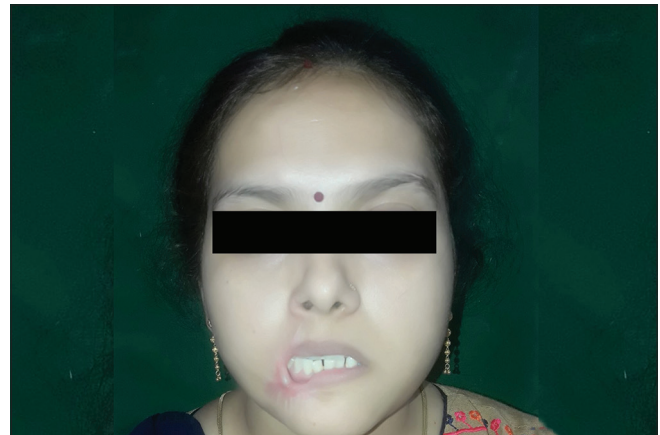

Figure 2: Postoperative view after lower lip necrosis

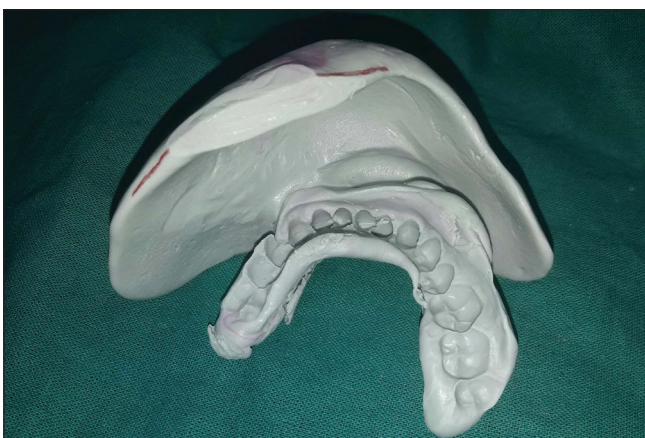

Figure 3: Combined intra- and extraoral secondary impression

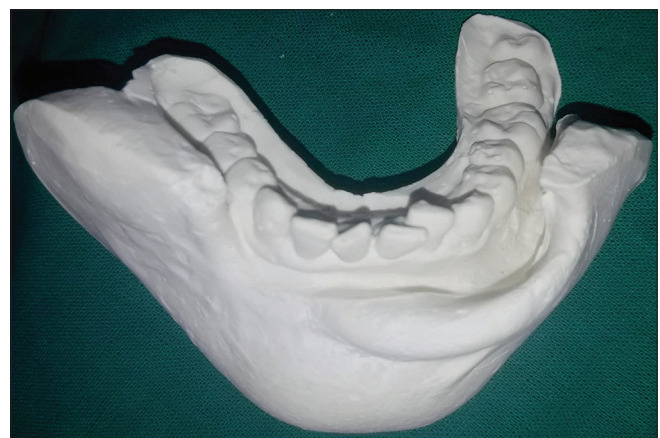

Figure 4: Model of lip defect

The wax pattern was modified to develop profile, shape and merge margins of prosthesis with natural tissue, and imitate wrinkles, skin creases, etc. [Figure 5]. To further improve the adaptation and retention, a wash impression was made in light body addition silicone (Elite HD; Zhermack, Badia Palesine, Italy) on the wax pattern itself. This relined wax pattern was again poured in white die stone (Orthokal, Kalabhai, Mumbai, Maharashtra, India) followed by marginal sealing, thinning, and merging with adjacent tissues [Figure 6]. This pour formed the first part of the mold into which keys were made for indexing. A three-part mold was necessary to achieve better characterization of different lip parts and removal of prosthesis without tearing. The second and third pours were preceded by careful application of separating media. For second pour, the boxed 1st part of mold was poured up to the inner lip line; keys were again made in this pour, followed by the third pour which was made to cover both previous pours. Dewaxing was carried out at 100°C for 5 min. The mold was cleaned properly [Figure 7]. Shade matching was done with the help of a digital spectrophotometer (Orthokal, Kalabhai, Mumbai, Maharashtra, India), and an appropriately colored

matched silicone (Technovent M511; Technovent Ltd.) was placed on to the different parts of the mold after applying a silicone-releasing agent (Orthokal, Kalabhai, Mumbai, Maharashtra, India) and polymerized as per instructions. Prosthesis was removed from investment [Figure 8] and finished and extrinsic staining was done, where required. Prosthesis was delivered to the patient 18 months back [Figure 9], who was satisfied by improved esthetics, lessened drooling, and enhanced speech intelligibility and retention, as recorded on the 3-monthly recall appointments. However, interruption of seal between prosthesis and movable soft tissues of the lip and cheek, sometimes resulted in margin show-through. Furthermore, extension of the prosthesis over the entire lip slightly increased the contour of the remaining natural portion of the lower lip.

DISCUSSION

Lip is a tactile organ which contributes not only to the process of articulation but also in creating oral seal. Its importance in attractiveness, identification of an individual,

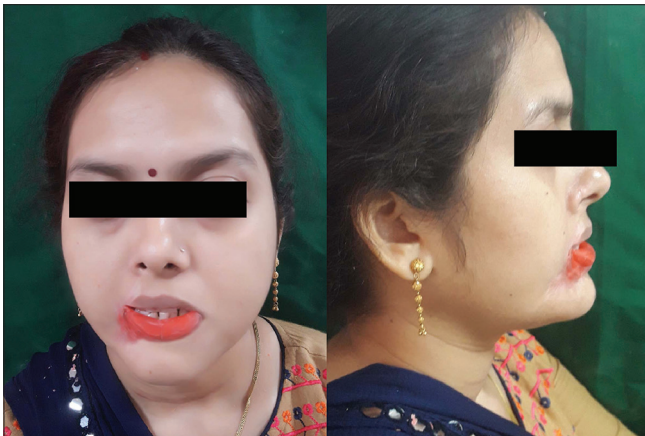

Figure 5: Pattern: frontal and profile views

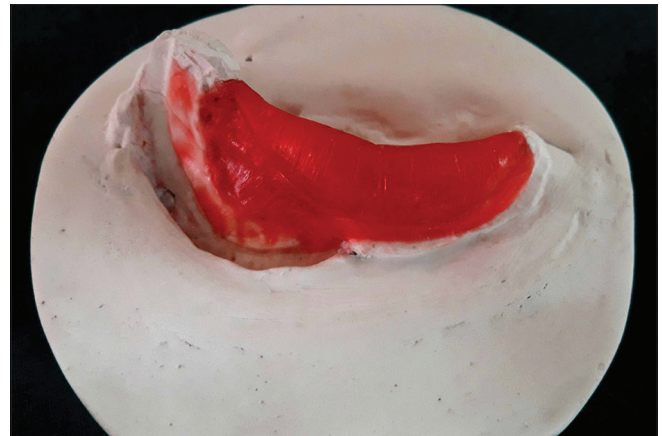


Figure 6: First part of the mold

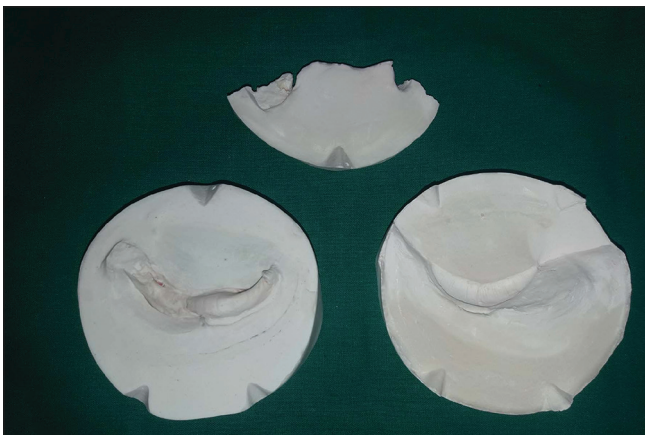

Figure 7: Three-piece mold

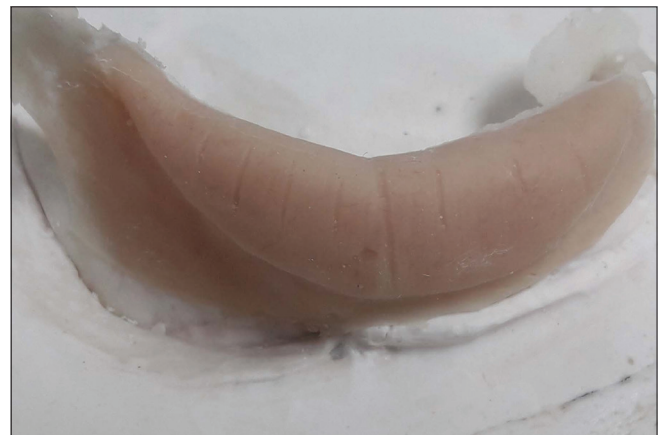

Figure 8: Retrieved prosthesis from the mold

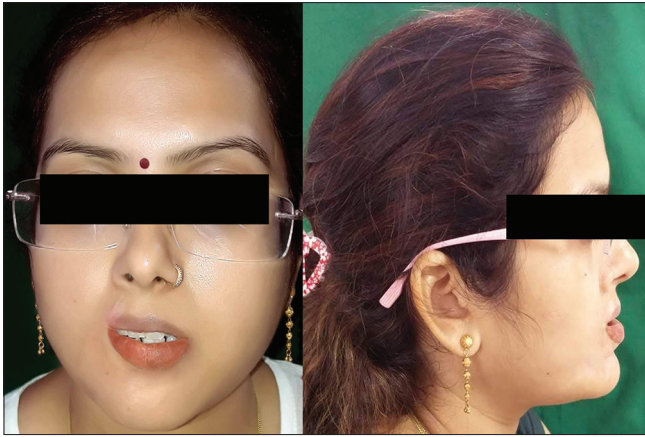

Figure 9: Final prosthesis after extrinsic coloring: frontal and profile views

and communication is undeniable. Any lip deficiency naturally leads to speech impairment and drooling of food and saliva.^[6] The prominent location makes it impossible to be missed by the eye. Therefore, a meticulous and swift correction of the defect is imperative to the patient's psychological well-being.

Restoration of such a defect poses a challenge in obtaining proper coloration, texture, and masking the margins of the prosthesis. Mobility of the tissues neighboring the defect compounds the problem. Engaging anatomical undercuts is not always feasible. Possible methods to mask margins include extending border beyond the midline, placement of margins in natural depressions, and thinning the margin. As described earlier, this prosthesis covered the entire lower lip to use the commissures and mentolabial sulcus for margin masking, increasing the retention of the prosthesis. However, the risk of making a bulky lip with this technique cannot be denied.

Another possible complication is salivary influx, breaking prosthetic seal, as well as causing show-through of margin while speaking, sucking, and smiling. Some methods utilized for retention of lip prosthesis include resin-retentive elements bonded to anterior mandibular teeth – Cheng *et al.*,^[7] placement of ball attachments on obturator's labial surface for retaining the upper lip – Oki *et al.*,^[8] and use of magnets and micro extracoronary resilient attachment (ERA) attachments – Zeno *et al.*^[4,9] Mukohyama *et al.*^[10] used lip plumper-like intraoral devices to correct mandibular lip posture skewed by marginal mandibulectomy.

Use of attachments is justifiable when no other retentive mean remains as these would have their own set of complications on the hard tissue to which the lip is anchored, make insertion and use complicated, and be

more feasible for the upper lip which is less mobile than the lower one. Gaining retention by increasing prosthesis surface area to intraoral sulcus and mentolabial sulci and extending coverage over the entire lip can be explored. Any deficiencies in retention experienced due to tissue mobility and salivary ingress may be supplemented by adhesives, though this was not done here, as a matter of patient preference (she wanted to avoid the added expenditure involved).^[11] However, such prosthesis can only be possible if about half of the lower lip is present.

CONCLUSION

Prosthetic rehabilitation plays a crucial role in the correction of lip defects where surgical reconstruction is not feasible, particularly in the rare case of necrosis described in this report. The prosthesis enhanced esthetics and aided functional and psychological recovery of the patient. This clinical report describes step-wise fabrication of the prosthesis, which was solely mechanically retained, was convenient to use, was economical, and was easy to fabricate.

Acknowledgement

We would like to express our sincere gratitude to Dr. Shefali Goel (Senior Resident, Prosthodontics Department, MAMC, New Delhi) for support in prosthesis fabrication, Prof. Pooran Chand (Prosthodontics Department, KGMU UP, Lucknow) for inputs in manuscript writing, Prof. Arun Kumar Singh (Head, Plastic Surgery Department, KGMU UP, Lucknow) and Dr. Madan Mishra (Reader, OMFS Department, Sardar Patel Dental College, Lucknow) for expert opinion on treatment modalities and management of the case.

Financial support and sponsorship

Nil.

Conflicts of interest

There are no conflicts of interest.

REFERENCES

1. Beumer II, Marunick M, Esposito S. Maxillofacial Rehabilitation: Prosthodontic and Surgical Management of Cancer-Related, Acquired, and Congenital Defects of the Head and Neck. 3rd ed. Chicago: Quintessence; 2011. p. 465-8.
2. Yamauchi M, Yotsuyanagi T, Yokoi K, Urushidate S, Yamashita K, Higuma Y. One-stage reconstruction of a large defect of the lower lip and oral commissure. *Br J Plast Surg* 2005;58:614-8.
3. Kornevs E, Skagers A, Tars J, Bigestans A, Lauskis G, Libermanis O. 5 year experience with lower lip cancer. *Stomatologija* 2005;7:95-8.
4. Zeno HA, Sternberger SS, Tuminelli FJ, Billotte M, Kurtz KS. Combination lower lip prosthesis retained by an intraoral component.

- J Prosthodont 2013;22:397-401.
5. Robinson JE, Niranin VJ. Maxillofacial Prosthetics. Washington, DC: Public Health Service; 1966. p. 95.
 6. Beumer J, Curtis T, Marunick M. Maxillofacial Rehabilitation: Prosthodontic and Surgical Considerations. St Louis: Ishiyaku Euro America; 1996. p. 511-30.
 7. Cheng AC, Morrison D, Maxymiw WG, Archibald D. 1997 Judson C. Hickey scientific writing awards. Lip prosthesis retained with resin-bonded retentive elements as an option for the restoration of labial defects: A clinical report. J Prosthet Dent 1998;80:143-7.
 8. Oki M, Ozawa S, Taniguchi H. A maxillary lip prosthesis retained by an obturator with attachments: A clinical report. J Prosthet Dent 2002;88:135-8.
 9. Rao SB, Gurram SK, Mishra SK, Chowdhary R. Magnet retained lip prosthesis in a geriatric patient. J Indian Prosthodont Soc 2015;15:187-90.
 10. Mukohyama H, Kadota C, Ohyama T, Taniguchi H. Lip plumper prosthesis for a patient with a marginal mandibulectomy: A clinical report. J Prosthet Dent 2004;92:23-6.
 11. Shrivastava KJ, Shrivastava S, Agarwal S, Bhoyar A. Prosthetic rehabilitation of large mid-facial defect with magnet-retained silicone prosthesis. J Indian Prosthodont Soc 2015;15:276-80.