



CLINICAL CASE

Efficacy and safety of rituximab in peripheral ulcerative keratitis associated with rheumatoid arthritis

Isabelle Bonnet ¹, Antoine Rousseau,^{2,3} Pierre Duraffour,⁴ Jacques Pouchot,⁵ Chi Duc Nguyen,⁶ Eric Gabison,^{7,8} Raphaele Seror,^{1,3} Hubert Marotte ^{9,10}, Xavier Mariette,^{1,3} Gaetane Nocturne^{1,3}

To cite: Bonnet I, Rousseau A, Duraffour P, *et al.* Efficacy and safety of rituximab in peripheral ulcerative keratitis associated with rheumatoid arthritis. *RMD Open* 2021;**7**:e001472. doi:10.1136/rmdopen-2020-001472

Received 14 October 2020
Revised 20 December 2020
Accepted 28 December 2020

ABSTRACT

Objective Peripheral ulcerative keratitis (PUK) is a rare but severe ocular complication of rheumatoid arthritis (RA). It can be considered as an ocular manifestation of rheumatoid vasculitis (RV). Our case series aimed to evaluate the efficacy of rituximab (RTX) for PUK occurring in patients with RA.

Methods Study population were patients with RA-associated PUK treated with RTX 1000 mg on days 1 and 15 at least once after the diagnosis. We identified patients referred to the rheumatology and ophthalmology departments of our hospital between February 2014 and June 2020. We also included patients referred by their specialist after being contacted through the Club Rhumatismes et Inflammation. Demographic data and clinical and biological features were retrospectively collected.

Results We included seven patients (three men and four women, median age 58 years). All but one had a long-standing RA with a median disease duration of 13.9 years (IQR 0–30.2). RA was erosive in six out of seven patients. All patients had rheumatoid factors and anticitrullinated peptides antibodies were positive in six of them. PUK was complicated by corneal perforation in three patients and required surgery. After a median follow-up of 29.8 months (IQR 5–75), corneal inflammation was controlled in all patients. PUK recurred in one patient, 8 months after a single infusion of RTX. 71% of the patients presented a good articular response. No patient developed other manifestations of RV. No serious adverse event related to RTX was observed.

Conclusion RTX appears to be an efficient and safe therapeutic option in the treatment of RA-associated PUK.

INTRODUCTION

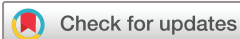Rheumatoid arthritis (RA) has long been considered as a pure rheumatic disease. However, it is now well established that RA is a systemic disease characterised by several extra-articular manifestations such as interstitial lung disease or scleritis. Peripheral ulcerative keratitis (PUK) is a rare but severe ocular complication of RA. This inflammation of the peripheral cornea may lead to rapid corneal

Key messages

- ▶ Peripheral ulcerative keratitis (PUK) is a rare and severe complication of rheumatoid arthritis (RA) occurring in long-standing disease.
- ▶ PUK's treatment has to associate local and systemic treatment, but the choice of the molecule is not straightforward.
- ▶ We report the largest series of patients with RA-associated PUK treated with rituximab (RTX) as first-line therapy.
- ▶ RTX appears to be an efficient and safe therapeutic option for PUK complicating RA.

ulceration, perforation and complete loss of vision. The majority of non-infectious PUK are related to autoimmune disease, among which RA is the most common, accounting for 34% of the cases.¹ When occurring during the course of an autoimmune disease, it can be considered as a manifestation of systemic vasculitis and is associated with a decreased life expectancy.²

The treatment of PUK relies on local and systemic treatment, including systemic immunosuppression.^{2,3} However, the choice of the immunosuppressive agent is not straightforward and is essentially based on case reports or retrospective studies. Cyclophosphamide (CYC) has long been used in this indication. However, CYC is poorly efficient in RA and is associated with poor safety profile compared with biological disease-modifying antirheumatic drugs (bDMARDs) available in RA.⁴ The rationale for using rituximab (RTX) in RA-associated PUK is strong since on one hand PUK is considered as a vasculitis and RTX is efficient in several vasculitis including rheumatoid vasculitis (RV),⁵ and on the other hand, RTX is an efficient treatment of RA with good safety profile.⁶



© Author(s) (or their employer(s)) 2021. Re-use permitted under CC BY-NC. No commercial re-use. See rights and permissions. Published by BMJ.

For numbered affiliations see end of article.

Correspondence to

Dr Isabelle Bonnet;
bonnetdesplanisabelle@gmail.com

Table 1 Patients' characteristics at the onset of the PUK

| Case number | Sex, age (years) | Ocular dryness | History of extra-articular manifestations | Duration of RA (years) | Erosions | Anti-CCP | RF | ANA | Previous lines of bDMARD (n) | IS treatment at onset of PUK | CS (mg/day) | DAS-28 CRP |
|-------------|------------------|----------------|--|------------------------|----------|----------|-----|-------|------------------------------|------------------------------|-------------|------------|
| 1 | M, 61 | Yes | None | 12.7 | Yes | 288 | 240 | 1/160 | 4 | TCZ | 5 | 1.6 |
| 2 | M, 46 | Yes | None | 9.7 | Yes | 268 | 183 | No | 5 | TCZ | 0 | 5.2 |
| 3 | M, 55 | Yes | None | 9.6 | Yes | No | 31 | 1/160 | 3 | TCZ | NA | NA |
| 4 | F, 64 | No | None | 30.2 | Yes | 664 | 188 | No | 0 | MTX | 0 | 2.6 |
| 5 | F, 55 | Yes | Nodular scleritis 7 years before, scleritis concomitant with PUK | 21.3 | Yes | 164 | 47 | 1/160 | 2 | ETCPT+MTX | 0 | 2.2 |
| 6 | F, 60 | No | None | 14.1 | Yes | Yes | Yes | 1/320 | 1 | ETCPT+MTX | 0 | 2.1 |
| 7 | F, 65 | Yes | Purpura | 0 | No | >1000 | 348 | 1/320 | 0 | 0 | 0 | 4.5 |

ANA, antinuclear antibody; b-DMARD, biological disease-modifying antirheumatic drug; CCP, anticitrullinated peptide; CRP, C reactive protein; CS, corticosteroid; DAS-28, Disease Activity Score using 28 joint counts; ETCPT, etanercept; F, female; IS, immunosuppressive; M, male; MTX, methotrexate; NA, not applicable; PUK, peripheral ulcerative keratitis; RA, rheumatoid arthritis; RF, rheumatoid factor; TCZ, tocilizumab.

Here, we report seven patients with RA-associated PUK treated with RTX and analyse ophthalmological and rheumatological responses to treatment.

METHODS

Case ascertainment

We carried out a retrospective survey to identify cases of RA-associated PUK. Cases were patients with RA fulfilling the American College of Rheumatology–EULAR 2010 criteria, who developed a PUK and were treated with RTX concomitantly to the diagnosis of PUK. Two strategies were used to identify these patients. First, patients referred to the rheumatology and ophthalmology departments of Bicêtre Hospital, a tertiary centre for systemic autoimmune diseases, between February 2014 and June 2020 were included. Second, all French rheumatology and internal medicine practitioners registered to the Club Rhumatismes et Inflammation (CRI) were contacted by electronic newsletters to collect additional cases. The CRI is a subset of the French Society of Rheumatology, including a network of more than 2000 physicians from different medical specialties and involved in the treatment of inflammatory diseases. All patients were informed that their clinical data could be used anonymously for research and gave their consent for the use of their data unless they provided an opposition to it, which none of the patients provided.

Data collection

Demographic data and clinical and biological features were retrospectively collected. Concerning RA, the following items were collected: date of diagnosis, presence of rheumatoid factor (RF) and anticitrullinated peptide antibodies (CCP), presence of erosions, previous use of conventional synthetic DMARDs or bDMARDs, extra-articular manifestations, vasculitis manifestations, control of RA at the onset of PUK based on the Disease Activity Score using 28 joint counts (DAS-28) C reactive protein (CRP) score and control after change of systemic treatment for RTX. Concerning PUK, the following items were collected: date of diagnosis, location, perforation, unilateral or bilateral involvement, initial and final best-corrected visual acuity (BCVA), surgical procedures, local treatments and recurrence. Lastly, we also collected data concerning reaction after infusion and hospitalised infection occurring under RTX.

Descriptive analysis

Categorical variables are reported as numbers (percentages). Quantitative variables are reported as median (IQR) unless otherwise specified.

RESULTS

We collected a total of seven patients, four from Bicêtre Hospital and three reported by the CRI. The baseline demographic and clinical characteristics of the patients are summarised in [table 1](#). Median age at diagnosis of

PUK was 58 years (IQR 46–65 years). All but one had a long-standing RA with a median duration of 13.9 years (IQR 0–30.2 years). For one patient, PUK was inaugural and RA was diagnosed 2 months after the onset of PUK. RA was erosive in six patients. All but one were positive for anti-CCP with high titres (median 346 U/mL, IQR 164–>1000), and all of them were positive for RF. Six were positive for antinuclear antibody, among which one had anti-Sicca syndrome A (anti-SSA). Only one had Sjogren's syndrome and none had another autoimmune disease associated with RA, but five underwent treatment for ocular dryness. One patient (case 5) had a previous history of nodular scleritis of the left eye 7 years before, which occurred while she was treated with adalimumab. In this patient, PUK was associated with a scleritis. No other patient had a history of previous extra-articular manifestations. Most of the patients had received at least one previous bDMARD and three had received at least three lines of bDMARDs before the onset of the PUK.

At the onset of the PUK, four patients were in remission of RA (DAS-28 score ≤ 2.6); one had a moderately active disease (3.2 < DAS-28 score ≤ 5.1); one had a high active disease (DAS-28 score > 5.1); and data were missing for one. The mean CRP level was 11.1 mg/L.

Corneal perforation occurred in three patients and required surgery that consisted in inlay amniotic membrane graft in two of them and lamellar corneal patch graft in the third one. No patients had received topical non-steroidal anti-inflammatory drugs.

All patients received a treatment with 1 g of RTX on days 1 and 15, associated with intravenous methylprednisolone 100 mg before the infusion. None of them were previously treated with CYC. Four patients also underwent a systemic treatment with oral prednisone at a dose of 1 mg/kg; two of them also received intravenous methylprednisolone in addition to the cycle of RTX. Five out of seven patients had at least another infusion of RTX 1000 mg on days 1 and 15 6 months after the first one.

The treatment and outcome measures of patients are summarised in [table 2](#). After a median follow-up of 29.8 months (IQR 5–75), six out of the seven patients were reassessed and all of them had a good ocular response as assessed by the ophthalmologist. None presented a decline in BCVA. For the remaining patient (patient 7), it was too soon to assess her visual outcome since RTX was administrated 3 months prior to this report. Patient 5, who had a history of nodular scleritis and who presented a scleritis associated with PUK, presented a recurrence of PUK in the same eye 8 months after the first infusion of RTX. RTX was restarted and led to a good ocular response. Infusions of RTX every 6 months were then performed until now. Her BCVA remained at 20/20 after the recurrence, but she presented sequelae at ocular examination with peripheral corneal thinning and stromal opacities.

Concerning articular response, one patient discontinued RTX after two cycles because of a prolonged remission and was maintained on methotrexate alone.

Table 2 Ocular and articular response after RTX therapy

| Case number | Initial perforation | Topical treatment | Systemic treatment other than RTX | Initial BCVA | Final BCVA | Loss of vision | Recurrence | Treatment of recurrence | Ocular inflammation control | Ocular complication | Change of systemic treatment during FUP | Side effect of RTX | Duration of FUP (m) |
|-------------|---------------------|-------------------|-----------------------------------|----------------------|----------------------|----------------|---------------|-------------------------|-----------------------------|------------------------------------|---|--------------------|---------------------|
| | | | | | | | | | | | | | |
| 1 | Yes | DXM+CP+TS | DXC | 20/32 | 20/20 | No | No | - | Yes | - | No | 0 | 27 |
| 2 | No | DXM+TS | DXC | 20/20 | 20/20 | No | No | - | Yes | - | TCZ, baricitinib | 0 | 75 |
| 3 | No | CP+rimexolone+TS | DXC | L: 20/32 R: 20/20 | L: 20/20 R: 20/20 | No | No | - | Yes | Corneal thinning | Baricitinib | 0 | 40 |
| 4 | No | DXM+TS | No | 20/25 | 20/25 | No | No | - | Yes | Ocular hypertension | Stop RTX | 0 | 22 |
| 5 | No | NA | NA | 20/20 | 20/20 | No | 8 m after RTX | Restart RTX | Yes | Corneal thinning/stromal opacities | No | 0 | 32 |
| 6 | Yes | DXM+TS+CP | NA | NA | 20/32 | NA | No | - | Yes | NA | No | 0 | 8 |
| 7 | Yes | DXM+TS+atropine | MTX | 20/63 | NA | NA | No | - | NA | NA | No | 0 | 5 |

BCVA, best-corrected visual acuity; CP, ciclosporine; DXC, doxycycline; DXM, dexamethasone; FUP, follow-up; MTX, methotrexate; NA, not applicable; RTX, rituximab; TCZ, tocilizumab; TS, tear substitute.

Two patients were non-responders leading to a switch of therapeutics after two cycles of RTX, as indicated in [table 2](#). Four patients presented a good response and are still receiving RTX, associated with methotrexate in one case. Infusions have been spaced out for one patient. No patient died during the follow-up and none developed other manifestations of RV.

No side effects of RTX were reported.

DISCUSSION

We report here the largest series of patients with RA-associated PUK treated with RTX as first-line therapy. Our results suggest that RTX may be effective and safe in PUK complicating RA as 100% and 71% of the patients presented good ocular and articular responses, respectively, and as no serious adverse event was observed.

The characteristics of our seven patients were concordant with the published literature. They were mostly positive for RF and anti-CCP antibodies.³ They had a long-standing and erosive disease.³ Of note, four of the seven patients, even if they had seropositive and erosive RA, were in remission at the time of PUK occurrence. This had already been observed in previous studies.⁷

Before the systematic use of systemic immunosuppression or biological agent in this indication, the occurrence of a PUK was associated with a major mortality, reaching up to 50% at 1 year.² Use of immunosuppressive therapy became systematic, and up to now, treatment with CYC was historically used in this indication. It demonstrated its ocular efficacy in several case series.⁷ However, while CYC is efficient in treating PUK, it is poorly useful to control rheumatic symptoms of RA.⁴ RTX has been proven to be efficient in RA and is approved in patients with RA after failure of MTX and at least one anti-TNF.⁶ In our study, we report good ocular and articular responses in patients treated with RTX. In previous studies, the rate of perforation complicating a PUK was evaluated between 13% and 65%.^{8,9} Those perforations were associated with a poor ocular and general outcome. Timlin *et al*¹⁰ studied a cohort of patients with perforative PUK and reported that 65% of living patients at 1 year had a BCVA under 1/10. The mortality rate was 24% at 1 year. In our series, we observed a high rate of perforation (42%), confirming the fact that we have treated patients with severe PUK. Despite that, none of the patients died during the follow-up, and all conserved their initial BCVA. The literature review also reported a rate of recurrence of PUK, an idiopathic and complicating autoimmune disease, of 44%.³ In our case series, we documented only one recurrence (14%), and this occurred after discontinuation of RTX. This suggests the necessity of maintenance therapy. We also report good general response since no patients developed manifestations of vasculitis, which was described as the main cause of death by Foster *et al*² in a historic cohort.

The rationale for using RTX as treatment for PUK is strong. Indeed, there are several lines of evidence

supporting that PUK in patients with RA is a manifestation of RV. First, corneal biopsy from patients with PUK found signs of vasculitis, such as fibrinoid necrosis with microangiopathy and complement and immune complexes deposits.¹¹ Those histological findings are similar to those observed in patients with RV. Second, there is a strong association between the presence of RF/anti-CCP antibodies and the onset of PUK,¹¹ which underlines the role of lymphocytes B in this complication. Last, manifestations of RV are frequent in patients with RA suffering from a PUK as demonstrated by Foster *et al*,² who described 41% of manifestation of RV in a cohort of 34 patients with RA having a PUK. Among these patients, 9 died from RV manifestation. RTX is approved in the treatment of vasculitis associated with auto-antibodies such as ANCA-vasculitis⁵ and has shown its efficacy in systemic RV.⁵ In a recent study, RTX was used for severe and refractory PUK associated with several systemic diseases with a good efficacy.¹² Efficacy in PUK associated with granulomatosis with polyangiitis has also been reported.¹³ In the literature, data concerning the use of RTX as a treatment for RA-associated PUK are scarce and discordant. Albert *et al*¹⁴ and Hardy *et al*¹⁵ reported two cases each of successful treatment by RTX. Conversely, cases of PUK development after the initiation of RTX were also reported.¹⁶

Of note, in our seven cases, we found no other manifestations of RV. This low incidence is concordant with recent studies confirming that prevalence of RV in patients with RA has declined since the 2000s.⁵ It is hypothesised that this decline is in link with the advent of biotherapy and a better control of the disease.

In our study, we did not observe any serious adverse events associated with RTX. It is concordant with the literature since RTX has been shown to be relatively safe.⁶ This is an important point since CYC is associated with a poorer safety profile that limits its use.⁴

Our study has several limitations. Four patients received steroids in addition to RTX, which may have overestimated the initial effect of RTX. The limited number of patients limits the extrapolation of the results. Besides, the flaws inherent to retrospective studies include a lack of completeness and of uniformity in record keeping and data acquisition. Given the low incidence of PUK, it would have been difficult to conduct a prospective study.

CONCLUSION

Our series confirm previously published reports and suggest that RTX could be a safe and efficient therapeutic option in the treatment of PUK complicating RA. Further studies with larger cohorts are needed to confirm these findings.

Author affiliations

¹Department of Rheumatology, AP-HP, Paris-Sud University Hospitals, Le Kremlin Bicêtre Hospital, Le Kremlin-Bicêtre, France

²Ophthalmology, Hospital Bicêtre, Le Kremlin-Bicêtre, Île-de-France, France

³Immunology of Viral Infections and Autoimmune, Hematological and Bacterial Diseases, Inserm U1184, Le Kremlin-Bicetre, Île-de-France, France

⁴Ophthalmology, Hospital Cochin, Paris, Île-de-France, France

⁵Internat Medicine, Hopital Europeen Georges Pompidou, Paris, Île-de-France, France

⁶Rheumatology, Hospital Centre Bethune, Bethune, Nord-Pas de Calais, France

⁷Ophthalmology, Hôpital Bichat Claude-Bernard, Paris, Île-de-France, France

⁸Centre de Référence pour les Maladies Ren Ophthalmologie (OPHTARA), Fondation Rothschild, Paris, Île-de-France, France

⁹Rhumatologie, CHU Saint-Etienne, Saint-Etienne, France

¹⁰SAINBIOSE, INSERM U1059, University of Lyon, Saint-Etienne, France, University of Lyon, Saint-Etienne, France

Contributors All authors have contributed to the submitted article.

Funding The authors have not declared a specific grant for this research from any funding agency in the public, commercial or not-for-profit sectors.

Competing interests None declared.

Patient consent for publication Not required.

Provenance and peer review Not commissioned; externally peer reviewed.

Open access This is an open access article distributed in accordance with the Creative Commons Attribution Non Commercial (CC BY-NC 4.0) license, which permits others to distribute, remix, adapt, build upon this work non-commercially, and license their derivative works on different terms, provided the original work is properly cited, appropriate credit is given, any changes made indicated, and the use is non-commercial. See: <http://creativecommons.org/licenses/by-nc/4.0/>.

ORCID iDs

Isabelle Bonnet <http://orcid.org/0000-0002-0943-4118>

Hubert Marotte <http://orcid.org/0000-0003-1177-9497>

REFERENCES

- 1 Tauber J, Sainz de la Maza M, Hoang-Xuan T, *et al*. An analysis of therapeutic decision making regarding immunosuppressive chemotherapy for peripheral ulcerative keratitis. *Cornea* 1990;9:66–73.
- 2 Foster CS, Forstot SL, Wilson LA. Mortality rate in rheumatoid arthritis patients developing necrotizing scleritis or peripheral ulcerative keratitis. Effects of systemic immunosuppression. *Ophthalmology* 1984;91:1253–63.
- 3 Ogra S, Sims JL, McGhee CNJ, *et al*. Ocular complications and mortality in peripheral ulcerative keratitis and necrotizing scleritis: the role of systemic immunosuppression. *Clin Exp Ophthalmol* 2020;48:434–41.
- 4 Suarez-Almazor ME, Belseck E, Shea B, *et al*. Cyclophosphamide for treating rheumatoid arthritis. *Cochrane Database Syst Rev* 2000;4:CD001157.
- 5 Puéchal X, Gottenberg JE, Berthelot JM, *et al*. Rituximab therapy for systemic vasculitis associated with rheumatoid arthritis: results from the autoimmunity and rituximab registry. *Arthritis Care Res* 2012;64:331–9.
- 6 Cohen SB, Emery P, Greenwald MW, *et al*. Rituximab for rheumatoid arthritis refractory to anti-tumor necrosis factor therapy: results of a multicenter, randomized, double-blind, placebo-controlled, phase III trial evaluating primary efficacy and safety at twenty-four weeks. *Arthritis Rheum* 2006;54:2793–806.
- 7 Jifi-Bahlool H, Saadeh C, O'Conner J. Peripheral ulcerative keratitis in the setting of rheumatoid arthritis: treatment with immunosuppressive therapy. *Semin Arthritis Rheum* 1995;25:67–73.
- 8 Malik R, Culinane AB, Tole DM, *et al*. Rheumatoid Keratolysis: a series of 40 eyes. *Eur J Ophthalmol* 2006;16:791–7.
- 9 Knox Cartwright NE, Tole DM, Georgoudis P, *et al*. Peripheral ulcerative keratitis and corneal melt: a 10-year single center review with historical comparison. *Cornea* 2014;33:27–31.
- 10 Timlin HM, Hall HN, Foot B, *et al*. Corneal perforation from peripheral ulcerative keratopathy in patients with rheumatoid arthritis: epidemiological findings of the British Ophthalmological surveillance unit. *Br J Ophthalmol* 2018;102:1298–302.
- 11 Messmer EM, Foster CS. Destructive corneal and scleral disease associated with rheumatoid arthritis. Medical and surgical management. *Cornea* 1995;14:408–17.
- 12 Dominguez-Casas LC, Sánchez-Bilbao L, Calvo-Río V, *et al*. Biologic therapy in severe and refractory peripheral ulcerative keratitis (PUK). Multicenter study of 34 patients. *Semin Arthritis Rheum* 2020;50:608–15.
- 13 Ebrahimiadib N, Modjtahedi BS, Roohipoor R, *et al*. Successful treatment strategies in granulomatosis with Polyangiitis-Associated peripheral ulcerative keratitis. *Cornea* 2016;35:1459–65.
- 14 Albert M, Beltrán E, Martínez-Costa L. Rituximab in rheumatoid arthritis-associated peripheral ulcerative keratitis. *Arch Soc Esp Ophthalmol Engl Ed* 2011;86:118–20.
- 15 Hardy S, Hashemi K, Catanese M, *et al*. Necrotising scleritis and peripheral ulcerative keratitis associated with rheumatoid arthritis treated with rituximab. *Klin Monbl Augenheilkd* 2017;234:567–70.
- 16 Goodisson L-A, Bourne JT, Maharajan S. A case of bilateral peripheral ulcerative keratitis following treatment with rituximab. *Rheumatology* 2010;49:609–10.