

## Case Report

# A rare complication of endobronchial ultrasound-guided transbronchial needle aspiration: Pericardial empyema

Muhammet Sayan, Huseyin Arpag<sup>1</sup>

Department of Thoracic Surgery, Gazi University, School of Medicine, Ankara, <sup>1</sup>Department of Chest Diseases, Kahramanmaraş Sutcu Imam University, School of Medicine, Kahramanmaraş, Turkey

## ABSTRACT

Endobronchial ultrasound (EBUS)-guided transbronchial biopsy procedure is widely used for the diagnosis of mediastinal lymphadenopathy. It is a safe method and the complication rate of procedure is <1%. Rarely, the fatal complications may develop after the intervention. Here, we present a case of pericardial empyema occurred as a complication of EBUS-guided transbronchial biopsy procedure

**KEY WORDS:** Endobronchial ultrasound-guided transbronchial needle aspiration, pericardial empyema, tamponade

**Address for correspondence:** Dr. Muhammet Sayan, Department of Thoracic Surgery, Gazi University, School of Medicine, Besevler, 06500 Ankara, Turkey. E-mail: drsayann@gmail.com

## INTRODUCTION

The endobronchial ultrasound-guided transbronchial needle aspiration (EBUS-TBNA) method is being used increasingly in the diagnosis of mediastinal lymph node diseases due to it is less invasiveness and has less complication compared with mediastinoscopy.<sup>[1]</sup> Although EBUS-TBNA is a safely and minimally complicated procedure, these complications can be serious or even fatal. Here, we aimed to present a case of pericardial empyema occurred as a complication of EBUS-TBNA procedure.

## CASE REPORT

A 53-year-old, male, a farmer patient admitted to emergency service with complaints of cough, dyspnea, and orthopnea. His medical history included the EBUS-TBNA performed for mediastinal paratracheal lymphadenopathy detected on thorax computed tomography 2 days ago in another clinic [Figure 1]. In emergency services, echocardiography was performed because of cardiomegaly detected in the chest

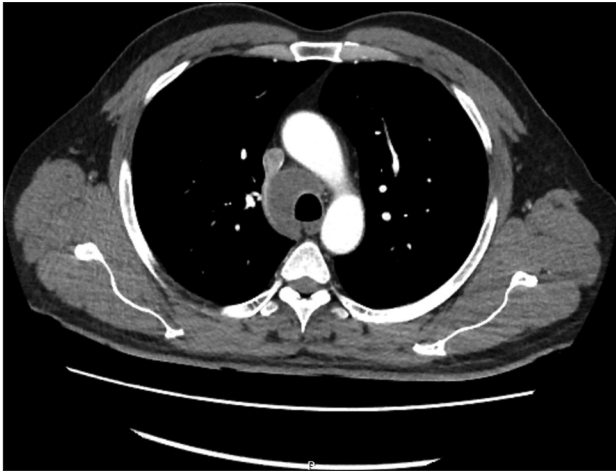
X-ray and thorax computed tomography, and pericardial effusion was detected and the patient was interned in the Intensive Care Unit [Figures 2 and 3]. Pericardial tamponade occurred in the follow-up of the patients, and therapeutic pericardiocentesis was performed. The features of aspirated fluid were purulent and malodorous, and wide-spectrum antibiotic treatment was started to the patient with pericardial empyema diagnosis. *Streptococcus pyogenes* strains were detected in pericardial fluid culture, and *Eikenella corrodens* and methicillin-resistant *Staphylococcus* strains were detected in the peripheral blood culture. Culturally appropriate intravenous antibiotic treatment was started. A decrease in the amount of pericardial fluid was detected on the control echocardiography of the patient. EBUS-TBNA biopsy reported as nonnecrotizing granulomatous inflammation. The medical condition and infection parameters of the patient improved and he was discharged with the recommendations. Written informed consent regarding the publication was obtained from the patient who participated in this case.

This is an open access journal, and articles are distributed under the terms of the Creative Commons Attribution-NonCommercial-ShareAlike 4.0 License, which allows others to remix, tweak, and build upon the work non-commercially, as long as appropriate credit is given and the new creations are licensed under the identical terms.

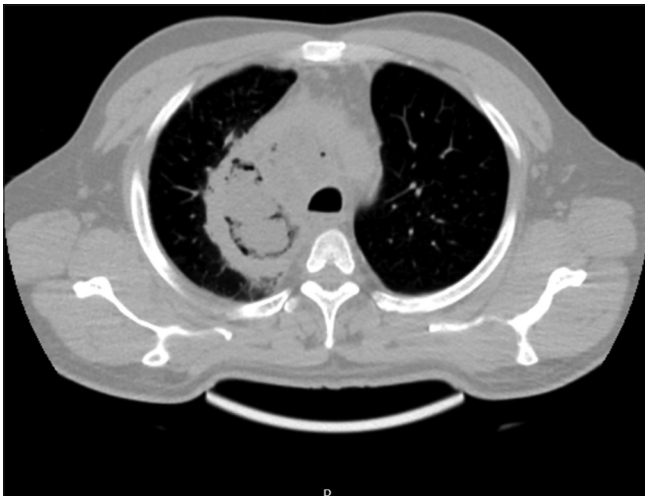**For reprints contact:** reprints@medknow.com

**How to cite this article:** Sayan M, Arpag H. A rare complication of endobronchial ultrasound-guided transbronchial needle aspiration: Pericardial empyema. Lung India 2019;36:154-6.

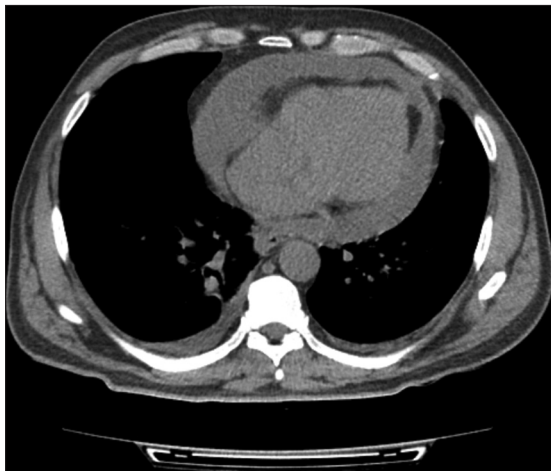Access this article online	
<b>Quick Response Code:</b> 	<b>Website:</b> www.lungindia.com
	<b>DOI:</b> 10.4103/lungindia.lungindia_262_18



**Figure 1:** Right tracheal lymph node enlargement was seen in mediastinal phase of contrast-enhanced thorax computed tomography



**Figure 2:** A suspicious abscess appearance was observed in the right paratracheal mediastinal region where biopsies taken place previously



**Figure 3:** The excess pericardial and minimally right pleural fluid was detected on thorax computed tomography

## DISCUSSION

The EBUS-TBNA method is being used increasingly in the diagnosis of mediastinal lymphadenopathy and it is expected that the reports related to the complications are increasing.<sup>[1,2]</sup> When the related studies are reviewed, it is stated that the EBUS-TBNA method widely used for the evaluation of mediastinal lesions such as lymphadenopathy and mass is a safe method and the complication rate is <1%. The most common complications after EBUS-TBNA in the literature are minor bleeding, pneumothorax, pneumomediastinum, and mediastinitis.<sup>[3]</sup> Wong *et al.* reported that in their study carried out on 110 patients undergoing EBUS-TBNA, bleeding occurred in 2 patients, bronchospasm in 1 patient, and fever in 1 patient.<sup>[4]</sup> Huang *et al.* published a case of empyema, mediastinal abscess, and lung abscess occurred after EBUS-TBNA procedure treated with broad-spectrum antibiotic and surgical debridement and they stated that infection was caused by inoculation of the oral flora to aspiration site with repetitive manipulations of the EBUS-TBNA needle.<sup>[1]</sup> Steinfort *et al.* detected the 3 patients with clinically insignificant bacteremia in their study composed of 43 patients undergoing EBUS-TBNA and they notified that the majority of them belong to oral flora.<sup>[5]</sup> Similarly, in our case, *E. corrodens*, an oral cavity bacterium, was detected in blood culture. The risk of mediastinitis and pericarditis after EBUS-TBNA has been linked to the necrotic and infectious nature of the aspirating lymph node.<sup>[6]</sup> However, in our case, there was neither radiological nor histologic necrosis/infection in the lymphoid tissue sample taken by EBUS-TBNA. Access to the pericardium through EBUS-TBNA is a well-known and probable condition and it can be entered into pericardial space by punctures made from anterior wall of the lower trachea and left lower lobe bronchus during the procedure.<sup>[7]</sup>

Haas published a case of infected pericardial effusion and pericardial tamponade following EBUS-TBNA intervention and he isolated an *Actinomyces* strain in the pericardial fluid.<sup>[6]</sup> Similarly, our case presented with pericardial effusion. Pericardiocentesis was performed, the purulent liquid was aspirated, and *S. pyogenes* strains were detected in pericardial fluid culture. Patients were treated with medical therapies such as pericardial drainage, broad-spectrum antibiotherapy, intravenous fluid resuscitation, and parenteral and enteral nutrition.

In this case report, we aimed to emphasize that pericardial empyema may develop after EBUS-TBNA and pericardial empyema should be considered in patients who develop fever, orthopnea, and dyspnea on the following days after the procedure.

## Declaration of patient consent

The authors certify that they have obtained all appropriate patient consent forms. In the form the patient(s) has/have

given his/her/their consent for his/her/their images and other clinical information to be reported in the journal. The patients understand that their names and initials will not be published and due efforts will be made to conceal their identity, but anonymity cannot be guaranteed.

#### **Financial support and sponsorship**

Nil.

#### **Conflicts of interest**

There are no conflicts of interest.

#### **REFERENCES**

1. Huang CT, Chen CY, Ho CC, Yu CJ. A rare constellation of empyema, lung abscess, and mediastinal abscess as a complication of endobronchial ultrasound-guided transbronchial needle aspiration. *Eur J Cardiothorac Surg* 2011;40:264-5.
2. Gu Y, Shi H, Su C, Chen X, Zhang S, Li W, *et al*. The role of endobronchial ultrasound elastography in the diagnosis of mediastinal and hilar lymph nodes. *Oncotarget* 2017;8:89194-202.
3. Sánchez-Font A, Álvarez L, Ledesma G, Curull V. Localized subcarinal adenitis following endobronchial ultrasound-guided transbronchial needle aspiration. *Respiration* 2015;90:329-31.
4. Wong KY, Ng LY, HN Tse HN, Yee WKS. Complications and diagnostic outcome of endobronchial ultrasound (EBUS) guided transbronchial needle aspiration (TBNA) of mediastinal lymph nodes. *Eur Respir J Suppl* 2012;40:284.
5. Steinfurt DP, Johnson DF, Irving LB. Incidence of bacteraemia following endobronchial ultrasound-guided transbronchial needle aspiration. *Eur Respir J* 2010;36:28-32.
6. Matsuoka K, Ito A, Murata Y, Sakane T, Watanabe R, Imanishi N, *et al*. Severe mediastinitis and pericarditis after transbronchial needle aspiration. *Ann Thorac Surg* 2015;100:1881-3.
7. Gross A, Diacon AH. Cardiac tamponade following transbronchial needle aspiration. *Respiration* 2011;82:56-9.
8. Haas AR. Infectious complications from full extension endobronchial ultrasound transbronchial needle aspiration. *Eur Respir J* 2009;33:935-8.