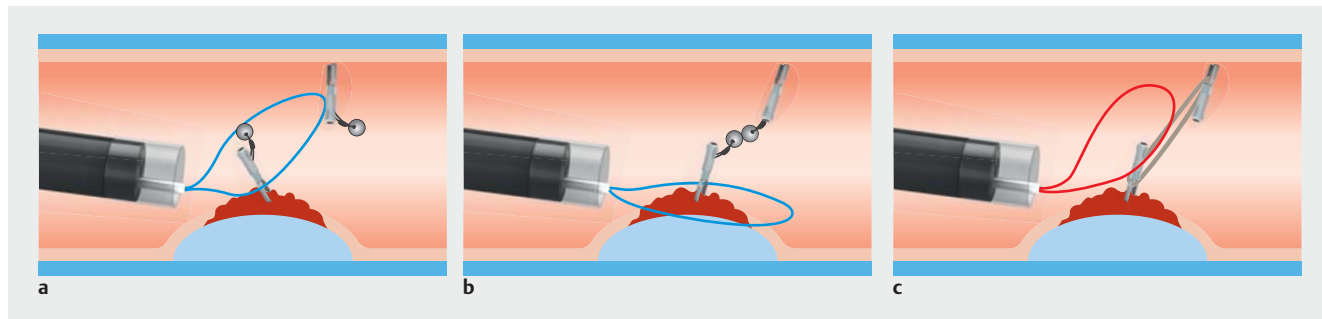


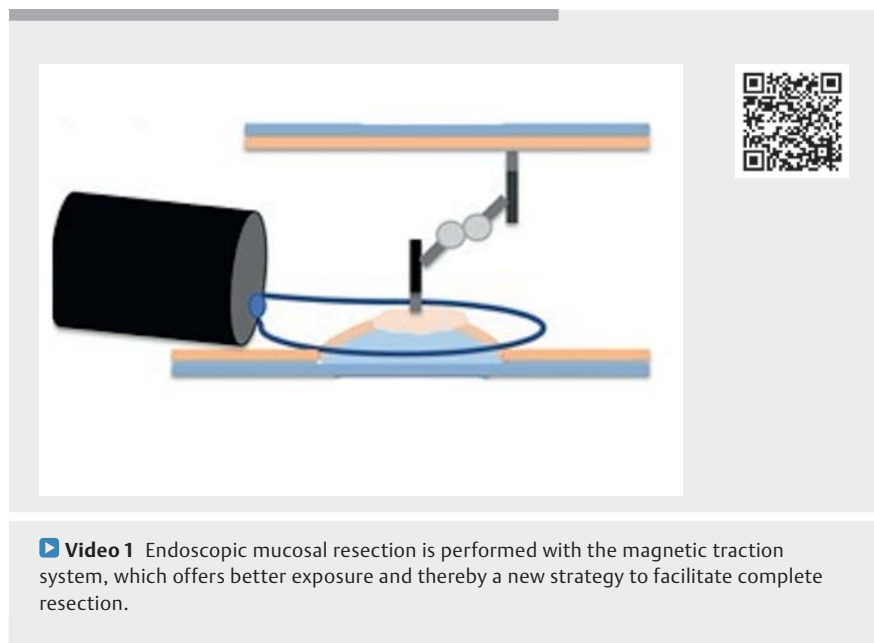
Endoscopic mucosal resection with a magnetic traction system: a new strategy to facilitate complete resection



► **Fig. 1** Schematic representation of traction-assisted endoscopic mucosal resection: **a, b** using the magnetic clip traction method; and **c** showing why the classic traction method (double clip and rubber band) is not applicable.

En bloc endoscopic mucosal resection (EMR) with a snare is the standard resection technique for adenomas <25 mm [1]. One limitation of this technique is, when gravity is not helping, the lack of good exposure of the lesion margins before cutting to ensure successful complete excision [2]. An independent traction system with clip and rubber band, as described for endoscopic submucosal dissection procedures [2], is not currently applicable for EMR because the snare cannot be placed around the lesion after placement of the traction system (► **Fig. 1**; ► **Video 1**). A new traction strategy using traction magnetic clips (ProdiGI; Medtronic), initially developed for traction-assisted ESD to improve exposure of the submucosal layer, could be the awaited solution to overcome this limitation.

We report the case of a 77-year-old man, who presented with a cecal adenoma of 12 mm. In order to achieve better visualization of all the margins and ensure a complete resection, we opted to use a traction magnetic clip kit. We started by placing the first magnetic clip on the opposite colonic wall (at a 90° angle). After submucosal injection of the lesion had been performed and the colon was maximally insufflated, a second magnetic clip was placed at the top of the lesion. A 25-mm snare was then placed around



the lesion. This was followed by colonic exsufflation in order to allow the two opposing magnets to pair. Afterwards, the colon was re-insufflated, resulting in traction of the lesion, which allowed optimal placement of the snare with direct visualization of all the margins. The lesion was then resected en bloc. Up until now, there has never been a traction technique that could be applied during EMR; however, using those magnets, we have demonstrated that trac-

tion can be performed during EMR and may add extra value by ensuring a complete resection.

Endoscopy_UCTN_Code_TTT_1AQ_2AD

Competing interests

The authors declare that they have no conflict of interest.

The authors

Mariana Figueiredo¹, Clara Yzet¹, Pierre Lafeuille¹, Thierry Ponchon¹, Jérémie Jacques², Jérôme Rivory¹, Mathieu Pioche¹

- 1 Gastroenterology and Endoscopy Unit, Pavillon L, Hôpital Edouard Herriot, Lyon, France
- 2 Gastroenterology and Endoscopy Unit, Hôpital Dupuytren, Limoges, France

Corresponding author

Mariana Figueiredo, MD

Service hépato-gastroentérologie,
Hôpital Edouard Herriot, 5 place d'Arsonval,
69003 Lyon, France
mariana.figueiredo.pro@gmail.com

References

- [1] Ferlitsch M, Moss A, Hassan C et al. Colorectal polypectomy and endoscopic mucosal resection (EMR): European Society of Gastrointestinal Endoscopy (ESGE) Clinical Guideline. *Endoscopy* 2017; 49: 270–297
- [2] Bordillon P, Pioche M, Wallenhorst T et al. Double-clip traction for colonic endoscopic submucosal dissection: a multicenter study of 599 consecutive cases (with video). *Gastrointest Endosc* 2021. doi:10.1016/j.gie.2021.01.036

Bibliography

Endoscopy 2022; 54: E820–E821

DOI 10.1055/a-1826-2394

ISSN 0013-726X

published online 13.5.2022

© 2022. The Author(s).

This is an open access article published by Thieme under the terms of the Creative Commons Attribution-NonDerivative-NonCommercial License, permitting copying and reproduction so long as the original work is given appropriate credit. Contents may not be used for commercial purposes, or adapted, remixed, transformed or built upon. (<https://creativecommons.org/licenses/by-nc-nd/4.0/>)

Georg Thieme Verlag KG, Rüdigerstraße 14,
70469 Stuttgart, Germany



ENDOSCOPY E-VIDEOS

<https://eref.thieme.de/e-videos>



Endoscopy E-Videos is an open access online section, reporting on interesting cases and new techniques in gastroenterological endoscopy. All papers include a high quality video and all contributions are freely accessible online. Processing charges apply (currently EUR 375), discounts and waivers acc. to HINARI are available.

This section has its own submission website at

<https://mc.manuscriptcentral.com/e-videos>