



Contents lists available at ScienceDirect

International Journal of Surgery Case Reports

journal homepage: www.casereports.com

Extragenital malignant mixed mesodermal tumor: A case report



Mauro Del Papa^a, Gabriele D'Amata^{a,*}, Fulvio Manzi^a, Luca Musmeci^a, Marco Crovaro^a, Carlo Buonocore^a, Gaetano Florio^a, Andrea Giannetti^b

^a Department of General Surgery, Ospedale "Leopoldo Parodi Delfino", Colleferro, Italy

^b Department of Pathology, Ospedale "Leopoldo Parodi Delfino", Colleferro, Italy

ARTICLE INFO

Article history:

Received 2 November 2017

Accepted 5 November 2017

Available online 9 November 2017

Keywords:

Carcinosarcoma

Mixed mesodermal tumor

Primary peritoneal carcinosarcoma

Malignant mixed müllerian tumor

Case report

ABSTRACT

INTRODUCTION: Primary malignant mixed mesodermal tumor (MMMt, also called malignant mixed Müllerian tumor and designated in the WHO classification of female genital tract neoplasms as carcinosarcoma) is an infrequent tumor that develops usually in the uterus and more rarely in the ovary. Extragenital tumor, including primary peritoneal MMMt, is an extremely rare and aggressive neoplasm with only few case reported in the literature.

PRESENTATION OF CASE: We report a case of a 70-year's old female who presented with nausea and abdominal discomfort for 6 months. Workup revealed an abdominal mass. Patient was treated with surgical removal in a general hospital.

DISCUSSION: Most peritoneal carcinosarcomas originate in the pelvic peritoneum, followed by decreasing frequency in the serosal surface of the colon, retroperitoneum, anterolateral abdominal peritoneum, and omentum. Surgical excision is the most effective treatment in carcinosarcomas. A complete cytoreduction, with resection of cancer to a status of no evidence of disease by the surgeon's unaided eye should be attempted.

CONCLUSION: Owing to the rarity of the disease, limited data regarding the management of peritoneal MMMT exists. Recommendations for the treatment of MMMT are based on individual cases only. In our case, the patient is alive with a follow-up of 15 months and she did not receive any cycle of chemotherapy.

© 2017 The Author(s). Published by Elsevier Ltd on behalf of IJS Publishing Group Ltd. This is an open access article under the CC BY-NC-ND license (<http://creativecommons.org/licenses/by-nc-nd/4.0/>).

1. Introduction

Primary malignant mixed mesodermal tumor (MMMt, also called malignant mixed Müllerian tumor and designated in the WHO classification of female genital tract neoplasms as carcinosarcoma) is an infrequent tumor that develops usually in the uterus and more rarely in the ovary. Extragenital tumor, including primary peritoneal MMMt, is an extremely rare and aggressive neoplasm with only few case reported in the literature [1]. The neoplastic elements of extragenital MMMT presumably arise directly from the mesothelium or submesothelial stroma and hence parallel the biphasic pattern of the genital (uterine or ovarian) counterpart. Since the first report in 1955 by Ober and Black [2], to our knowledge there have been only 30 well documented reports of extragenital malignant mixed Müllerian tumors [3]. Pelvic peritoneum seems to be the most common site for extragenital MMMTs. Extragenital MMMTs have also been shown to arise in other sites such as the serosal surface of the

colon, retroperitoneum, cul-de-sac, rectal peritoneum, anterolateral abdominal peritoneum, diaphragm peritoneum, and omentum [4,5]. We report a case of a 70-year's old female who presented with nausea and abdominal discomfort for 6 months. Workup revealed an abdominal mass. Patient was treated with surgical removal. The following case has been reported in line with the SCARE criteria [6].

2. Case presentation

A 70-year's old woman presented for episodes of abdominal pain and nausea for 3 months. The patient's body mass index was 25 kg/m². Her past medical history was unremarkable. Abdominal examination revealed a large palpable, relatively mobile, non-tender mass in the right flank and mesogastrium. She had lost 4 kg of weight in 3 months. Computer tomography of her abdomen showed an abnormal mass with areas of necrosis below the transverse mesocolon, measuring approximately 17 cm × 11,5 cm × 9,5 cm (Fig. 1). The mass was adherent to the right rectum muscle and was strictly involving some loops of the small intestine. The patient underwent subsequent exploratory midline laparotomy. The mass was resected en bloc with the small intestine loops involved and an ileocolic anastomosis was performed (Fig. 2). The rest of the abdominal cavity, including ovaries,

* Corresponding author at: Ospedale "Leopoldo Parodi Delfino", Piazza Aldo Moro 1, 00034 Colleferro, RM, Italy.

E-mail address: gabridamata@gmail.com (G. D'Amata).

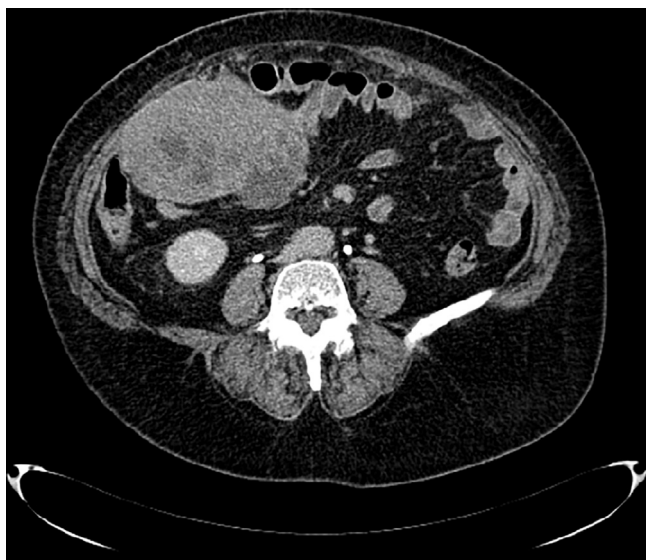

Fig. 1. Computer tomography of her abdomen showed an abnormal mass with areas of necrosis below the transverse mesocolon, measuring approximately 17 cm × 11,5 cm × 9.5 cm.

fallopian tubes and uterine corpus was normal. The postoperative course was unremarkable. The patient did not receive any cycle of chemotherapy and was alive with a follow up of 15 months. The histopathology revealed findings consistent with a malignant mixed mesodermal tumor, measuring cm 12. The radial, proximal and distal margins were negative. No metastasis in 2 lymph

nodes was noted. Immunohistochemical analysis was performed to identify the immune profile of the tumor cells. Monoclonal mouse antihuman antibodies against cytokeratin (clone AE1/AE3), Calretinin, C-kit/Cd117, desmin (clone D33), miogenin (clone F5D) were used. The tumor cells arranged in a solid and vague papillary pattern (presumably epithelial element) showed strong reactivity for epithelial markers (cytokeratin and epithelial membrane antigen). Alternatively, the neoplastic cells arranged singly (presumably mesenchymal element) showed strong reactivity for miogenin and desmin. These cells (presumably sarcomatous element) showed negative reactivity for the epithelial markers (cytokeratin and epithelial membrane antigen). This combined morphology was of a carcinosarcoma, with aspects of heterologous osteocondroblastic and rabdomiosarcomatous differentiation (Fig. 3).

3. Discussion

Carcinosarcoma comprises coexisting carcinoma and sarcoma. Based on pathological diagnosis, 2 or more malignant components are required for carcinoma diagnosis. The carcinoma tests positive for epithelial tissue markers cytokeratin (such as cytokeratins 7,8,18,19, and pan-cytokeratin AE1/AE3) and the sarcoma component is positive for mesenchymal tissue marker vimentin, desmin and miogenine. Primary peritoneal neoplasms composed of both malignant epithelial and stromal elements have been referred to as extragenital malignant mixed mesodermal tumors [7], malignant mixed müllerian tumors [8], carcinosarcomas [9] and mixed tumors of müllerian type [10].

The mechanism of carcinosarcoma is unclear. The peritoneal surfaces are host to a range of benign and malignant lesions commonly encountered in the müllerian duct derivatives of the female

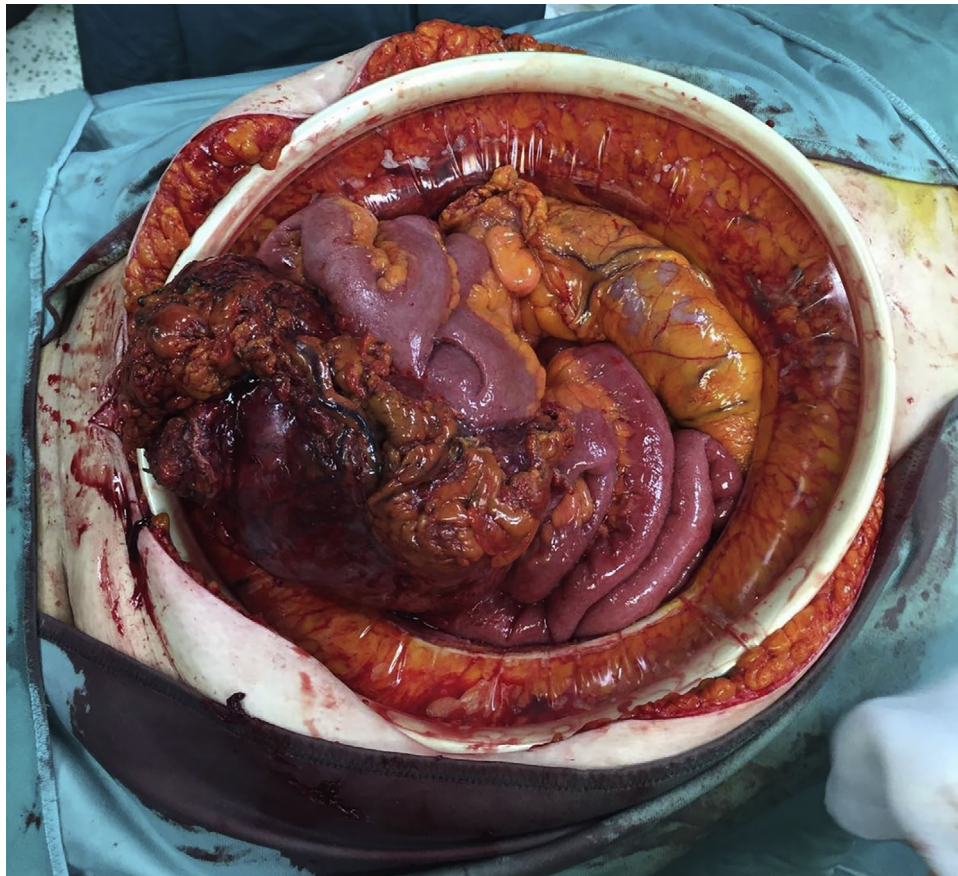


Fig. 2. Intraoperative finding: en bloc resection of the mass with small intestine loops involved.

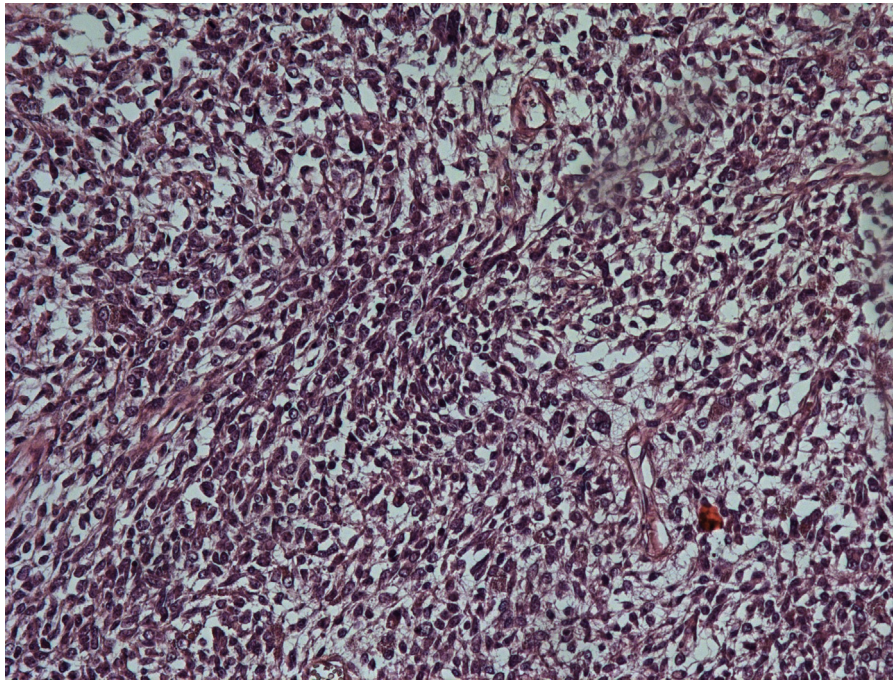


Fig. 3. Malignant mixed müllerian tumor, heterologous variety. Foci of chondrosarcoma and rhabdomyosarcoma elements.

genital tract [11]. Several theories have emerged in the attempt to explain the biphasic appearance of the tumor, the most important of which are the “collision”, “conversion” and the “combination” theory [12].

Histogenetically, primary peritoneal MMMT is thought to originate from the secondary Müllerian system. Histologically, MMMT is composed of both carcinomatous and sarcomatous components. The prominence of epithelial elements quite often leads to the erroneous diagnosis of undifferentiated carcinoma [13]. In the uterus, if the tumor shows only components derived from endometrium or myometrium, it belongs to the homologous type. When components foreign to the uterus, including cartilage and bone, are observed, the tumor belongs to the heterologous type. Müllerian carcinocarcinomas may be categorized as homologous or heterologous, depending on the histologic characteristics of the sarcomatous elements. Homologous neoplasms show no differentiated sarcomatous elements, nor differentiation. Anatomically, the secondary müllerian system consisting of the abdominal and pelvic peritoneum and its underlying mesenchymal tissue is derived from the coelomic epithelium. As a derivative of coelomic epithelium, it retains its potential to differentiate into müllerian tissue. These müllerian type tumors may therefore originate directly from totipotential cells or from the transformation of neoplastic epithelial cells into sarcomatous cells [14]. The heterologous elements consisted most often of chondrosarcoma or rhabdomyosarcoma. MMMTs were traditionally regarded as a subtype of uterine sarcomas or a mixture of true carcinoma and sarcoma, however several reports suggested a monoclonal origin of these tumors [15]. Interestingly, molecular data published by Wada et al. [16] suggested that although most carcinosarcomas are combination tumors, some develop as collision tumors.

Malignant mixed müllerian tumors of the peritoneum are aggressive tumors. Most patients die within one year, with median postoperative survival time of 14 months, and a range of 7 days–73 months [17,18].

Most peritoneal carcinosarcomas originate in the pelvic peritoneum, followed by decreasing frequency in the serosal surface of

the colon, retroperitoneum, anterolateral abdominal peritoneum, and omentum [19]. They generally occur in the elderly postmenopausal women, and usually present with abdominal pain, abdominal distention or pelvic mass [20,21].

4. Conclusion

Owing to the rarity of the disease, limited data regarding the management of peritoneal MMMT exists. Recommendations for the treatment of MMMT are based on individual cases only [14].

Surgical excision is the most effective treatment in carcinosarcomas. A complete cytoreduction, with resection of cancer to a status of no evidence of disease by the surgeon’s unaided eye should be attempted. Ifosfamide and Cisplatin combination therapy may play a role in the management of both advanced and localized disease [8,22]. Except for the report of Ohno et al. [4] most of the patients receiving chemotherapy for extragenital MMMT died of their disease within 1 year, whatever the tumor stage. Adjuvant radiotherapy after surgery in combination with chemotherapy may be considered for patients who have small residual disease after cytoreduction [17].

Ko et al. reported on a patient that was treated with optimal tumor debulking and a combination of chemotherapy with Ifosfamide and Cisplatin, followed by pelvic irradiation. There were no signs of recurrence for 48 months and was the case with the longest disease-free survival in the reported literature [23].

Conflicts of interest

All authors declare no conflicts of interest relevant to this report.

Funding

This research did not receive any specific grant from funding agencies in the public, commercial, or not-for-profit sectors.

Ethical approval

Given that this is a case report with no identifiable information included in the manuscript, ethical approval was not obtained.

Consent

Written informed consent was obtained from the patient for the publication of this case report and its accompanying images. A copy of the written consent form is available for review for the Editor-in-Chief of this journal.

Author contribution

Contribution Gabriele D'Amata writing the paper, final decision to publish, data collection and analysis.

Mauro Del Papa, Fulvio Manzi, Luca Musmeci, Marco Crovaro, Carlo Buonocore, Gaetano Florio participated in the clinical treatment and data collection. Andrea Giannetti performed the pathological studies. All authors read and approved the final version of the manuscript.

Guarantor

Dr. Gabriele D'Amata, M. D.

References

- [1] K. Cokelaere, P. Michielsen, R. De Vos, R. Sciot, Primary mesenteric malignant mixed mesodermal (müllerian) tumor with neuroendocrine differentiation, *Mod. Pathol.* 14 (2001) 515–520.
- [2] W.B. Ober, M.B. Black, Neoplasms of the subcoelomic mesenchyme: report of two cases, *Arch. Pathol.* 59 (1955) 698–705.
- [3] F.I. Kurshumliu, H. Rung-Hansen, V.R. Skovlund, L. Gashi-Luci, T. Horn, Primary malignant mixed müllerian tumor of the peritoneum a case report with review of the literature, *World J. Surg. Oncol.* 4 (February (9)) (2011) 17, <http://dx.doi.org/10.1186/1477-7819-9-17>.
- [4] S. Ohno, H. Kuwano, M. Mori, H. Sakata, A. Mori, K. Shinohara, Malignant mixed mesodermal tumour of the peritoneum with a complete response to cyclophosphamide, *Eur. J. Surg. Oncol.* 15 (3) (1989) 287–291.
- [5] J.R. Garde, M.A. Jones, R. McAfee, H.M. Tarraza, Extragenital malignant mixed müllerian tumor: review of the literature, *Gynecol. Oncol.* 43 (2) (1991) 186–190.
- [6] R.A. Agha, A.J. Fowler, A. Saeta, I. Barai, S. Rajmohan, D.P. Orgill, et al., The SCARE statement: consensus-based surgical case report guidelines, *Int. J. Surg.* 34 (2016) 180–196.
- [7] G.K. Nguyen, R.C. Berendt, Aspiration biopsy cytology of metastatic endometrial stromal sarcoma and extragenital mixed mesodermal tumor, *Diagn. Cytopathol.* 2 (1986) 256–260.
- [8] P.G. Rose, M. Rodriguez, F.W. Abdul-Karim, Malignant mixed müllerian tumor of the female peritoneum: treatment and outcome of three cases, *Gynecol. Oncol.* 65 (1997) 523–525.
- [9] M. Campins, J. Madrenas, M. Biosca, A. Salas, N. Tallada, F. Garcia-Bragado, Extra-uterine müllerian carcinosarcoma, *Acta Obstet. Gynecol. Scand.* 65 (1986) 811–812.
- [10] E. George, J.C. Manivel, L.P. Dehner, M.R. Wick, Malignant mixed müllerian tumors: an immunohistochemical study of 47 cases, with histogenetic considerations and clinical correlation, *Hum. Pathol.* 22 (1992) 215–223.
- [11] H. Fox, Primary neoplasia of the female peritoneum, *Histopathology* 23 (1993) 103–110.
- [12] W.G. McCluggage, Malignant biphasic uterine tumours: carcinosarcomas or metaplastic carcinomas, *J. Clin. Pathol.* 55 (2002) 321–325.
- [13] G. Vermes, N. Acs, I. Szabo, Z. Langmar, B. Jaray, F. Banhidly, Simultaneous bilateral occurrence of a mixed mesodermal tumor and cystadenocarcinoma in the ovary, *Pathol. Oncol. Res.* 10 (2004) 117–120.
- [14] J.L. Mira, C.M. Fenoglio-Preiser, N. Husseinzadeh, Malignant mixed müllerian tumor of the extraovarian secondary müllerian system. Report of two cases and review of English literature, *Arch. Pathol. Lab. Med.* 119 (1995) 1044–1049.
- [15] W.G. McCluggage, Malignant biphasic uterine tumours: carcinosarcomas or metaplastic carcinomas, *J. Clin. Pathol.* 55 (2002) 321–325.
- [16] H. Wada, T. Enomoto, M. Fujita, K. Yoshino, R. Nakashima, H. Kurachi, T. Haba, K. Wakasa, K.R. Shroyer, M. Tsujimoto, T. Hongyo, T. Nomura, Y. Murata, Molecular evidence that most but not all carcinosarcomas of the uterus are combination tumors, *Cancer Res.* 57 (1997) 5379–5385.
- [17] E. Garamvoelgyi, L. Guillou, S. Gebhard, M. Salmeron, R.J. Seematter, M.H. Hadji, Primary malignant mixed müllerian tumor (metaplastic carcinoma) of the female peritoneum. A clinical, pathologic, and immunohistochemical study of three cases and a review of literature, *Cancer* 74 (1994) 854–863.
- [18] V.P. Sumathi, M. Murnaghan, P. Dobbs, W.G. McCluggage, Extragenital 'müllerian carcinosarcoma arising from the peritoneum: report of two cases, *Int. J. Gynecol. Cancer* 12 (2002) 164–167.
- [19] D.H. Shen, U.S. Khoo, W.C. Xue, H.Y. Ngan, J.L. Wang, V.W. Liu, et al., Primary peritoneal malignant mixed müllerian tumors. A clinicopathologic, immunohistochemical and genetic study, *Cancer* 91 (2001) 1052–1060.
- [20] A.D. Dincer, P. Timmins, D. Pietrocola, H. Fisher, R.A. Ambros, Primary peritoneal müllerian adenocarcinoma with sarcomatous overgrowth associated with endometriosis: a case report, *Int. J. Gynecol. Pathol.* 21 (2001) 65–68.
- [21] L. Wei, J. Wang, X. Zhang, H. Cui, D. Shen, H. Qian, Primary omental malignant mixed müllerian tumor in a 67-year-old woman, *Chin. Med. J.* 115 (2002) 138–140.
- [22] E. Topuz, A. Eralp, A. Aydinler, P. Saip, F. Tas, E. Yavuz, et al., The role of chemotherapy in malignant mixed tumors of the female genital tract, *Eur. J. Gynecol. Oncol.* 22 (2001) 469–472.
- [23] M.L. Ko, C.J. Jeng, S.H. Huang, J. Shen, C.R. Tzeng, S.C. Chen, Primary peritoneal carcinosarcoma (malignant mixed müllerian tumor): report of a case with five-year disease free survival after surgery and chemoradiation and a review of literature, *Acta Oncol.* 44 (7) (2005) 756–760.

Open Access

This article is published Open Access at sciedirect.com. It is distributed under the [IJSCR Supplemental terms and conditions](#), which permits unrestricted non commercial use, distribution, and reproduction in any medium, provided the original authors and source are credited.