

# Long-term consumption of energy drinks induces biochemical and ultrastructural alterations in the heart muscle

Camelia Munteanu, Corina Rosioru, Corneliu Tarba, Camelia Lang

Department of Molecular Biology and Biotechnology, Babes-Bolyai University, Cluj-Napoca-Romania

## ABSTRACT

**Objective:** Energy drinks (EDs) target young and active individuals and they are being marketed as enhancers of energy, concentration, and physical and cognitive performance. Their long-term consumption raises serious health concerns related to cardiovascular events. Here we investigate the effects of long-term Red Bull® consumption and its combination with alcohol on certain biochemical parameters and the ultrastructure of the myocardium.

**Methods:** Male Wistar rats were categorized into four groups and given different treatments via oral administration. The Control (C) group received tap water, the Red Bull (RB) group received 1.5 ml/100 g body weight of Red Bull, the ethanol group (E) received 0.486 mg/100 g body weight of ethanol, and the Red Bull and ethanol (RBE) received a combination of the two beverages for 30 days. In the last 6 days of the experiment, the animals were tested for their physical performance by conducting a weight-loaded forced swim test. Immediately after swimming exhaustion, the animals were sacrificed under anesthesia and samples of the heart muscle were harvested for ultrastructural and biochemical analyses.

**Results:** Our results showed a significant increase in the heart glucose and glycogen concentrations in the RB and RBE groups. Total cholesterol concentration significantly decreased in the RBE and RB groups. Total protein concentration and ALT and AST activities increased in all groups. The biochemical changes were accompanied by ultrastructural alterations.

**Conclusion:** Based on these results, we recommend that athletes and active persons should avoid the long-term consumption of the Red Bull ED and, particularly, its combination with alcohol. (*Anatol J Cardiol* 2018; 19: 326-33)

**Keywords:** energy drinks, Red Bull, ethanol, heart muscle

## Introduction

Energy drinks (EDs) target young and physically active individuals. They contain large quantities of active components such as caffeine, taurine, and niacin. EDs are branded as agents or enhancers of energy, concentration capacity, and physical and mental performance (1). However, the consumption of EDs, particularly in large quantities, is associated with the occurrence of cardiovascular events such as cardiac arrhythmias, chest pain, hypertension, and even sudden cardiac death (2). As such, the safety of the long-term consumption of EDs is questionable.

The explosive increase in the consumption of EDs over the past years has led the scientific community to investigate the influence of such products on human health and to identify the reasons for their consumption. Additionally, the past years have

witnessed an increase in the incidence of negative effects associated with the consumption of EDs, the most common adverse effects noticed being the nervous, cardiovascular, and gastrointestinal effects.

The risks are even higher if EDs are combined with alcohol. Several studies have investigated the effect of EDs in combination with alcohol and have shown that EDs significantly reduce the immediate effects of ethylic intoxication, which may lead to an increased consumption of alcoholic drinks (3). Ferreira et al. (4) have shown that, when combined with alcohol, Red Bull attenuates the perception of alcoholic intoxication.

In general, the short- and long-term effects of the consumption of EDs are controversial. Several studies have addressed the short-term effects of EDs, targeting specific components of EDs and not EDs in their entirety, and have reported positive

**Address for correspondence:** Camelia Lang, MD, Department of Molecular Biology and Biotechnology, Babes-Bolyai University, 5-7 Clinicilor Street, Cluj-Napoca-Romania

Phone: +40 264 595 739 ext. 117 E-mail: camelia.lang@ubbcluj.ro

**Accepted Date:** 30.03.2018 **Available Online Date:** 02.05.2018

©Copyright 2018 by Turkish Society of Cardiology - Available online at [www.anatoljcardiol.com](http://www.anatoljcardiol.com)  
DOI:10.14744/AnatolJCardiol.2018.90094



short-term effects induced by these specific components. For instance, it has been shown that caffeine activates AMP-activated protein kinase (AMPK), which is a key enzyme that coordinates several signaling pathways that are involved in maintaining cellular energy homeostasis (5). Additionally, caffeine causes sympathomimetic effects, intensifying heart activity and increasing blood pressure (6).

It has also been proven that taurine is an indirect regulator of oxidative stress in the myocardium, stabilizing the cellular membranes by directly interacting with phospholipids. It exhibits various biological activities such as a positive influence on the calcium kinetics as well as the protection of the cardiac function and is a modulator of protein kinases and phosphatases in cardiomyocytes. Further, it maintains the normal contractile function of the heart muscle (7) and reduces arterial pressure (8).

Some EDs (5-hour ENERGY shots, Monster, Rockstar Energy, and Red Bull) contain niacin (vitamin B3) in doses above the daily recommended intake. Niacin has positive effects in restoring a healthy lipid profile and delaying the progression of atherosclerosis (9). It has been used for more than half a century in the treatment of lipid disorders, such as abnormally elevated concentrations of LDL, non-HDL cholesterol, triglycerides, and lipoproteins and low concentrations of HDL (9, 10).

In fact, most studies have shown that a moderate consumption of EDs over a short period of time improves the cognitive and psychomotor capacities (11). However, some studies have also highlighted the occurrence of negative effects by the consumption of EDs, such as an increase in the heart rate, and systolic and diastolic pressures and a decrease in the cerebral blood flow (12, 13).

Finally, the long-term effects of the consumption of EDs on different systems have been insufficiently studied, and those of such drinks on the cardiovascular system are unknown. However, based on known information (see the preceding paragraph), our hypothesis is that the consumption of EDs represents a serious cardiac risk factor. The aim of this study was to investigate the effects of the chronic consumption of an ED (Red Bull) and of its combination with alcohol and to highlight their influence on certain biochemical parameters and the ultrastructure of the myocardium.

## Methods

### Chemicals

All reagents used in this study were of analytical grade and were purchased from Sigma-Aldrich Chemie GmbH, Germany. The Red Bull ED was bought from a local market.

### Animals and treatments

The study was conducted on male Wistar rats, which were kept under standard conditions and had free access to water

and food. Experiments were performed according to the national regulations and were approved by the Institutional Ethics Committee (Registration no. 17928/2017).

Twenty-eight albino male Wistar rats, weighing  $182.11 \pm 4.7$  g, were divided into the following four groups, each with seven animals: the Control (C), Red Bull (RB), ethanol (E), and Red Bull and ethanol (RBE). All animals received a standard diet. The C group had *ad libitum* access to tap water, the RB group were orally administered with 1.5 ml/100 g body weight of Red Bull in drinking water daily, for 30 days, and the E group received 0.486 mg/100 g body weight of ethanol daily. The RBE group received both Red Bull and ethanol in equivalent concentrations with each of the other two treated groups.

In the last 6 days of the experiment, the animals were tested for their physical performance by conducting a weight-loaded forced swim test. The animals were forced to swim to exhaustion with a load of 10% of their body weight attached to their tails. Each rat was considered to have reached exhaustion when it remained submerged for  $\geq 5$  s. Water temperature varied between 28°C and 30°C, and none of the animals were affected by hypothermia.

After 30 days of treatment, immediately after exhaustion, the animals were killed by exsanguination under anesthesia. Samples of serum and heart muscle were harvested for biochemical and ultrastructural analyses, including the measurements of total heart glucose, glycogen, cholesterol and protein concentrations; in addition, serum and heart muscle ALT and AST activities were measured.

### Biochemical analyses

The total glucose concentration was determined using the Somogy Nelson colorimetric assay (14, 15). Glycogen concentration was determined using the Montgomery method (16) modified by Lo et al. (17). Total cholesterol was assayed using ferric chloride (18). Total protein concentration was determined using the Bradford colorimetric assay (19) with the Bradford "ready-to-use" reagent. AST and ALT activities were analyzed using the Reitman and Frankel photocolometric assay (20).

### Ultrastructural analyses

For electron microscopy analyses, the myocardium specimens were fixed in 2.7% glutaraldehyde and 2% osmium tetroxide, successively washed in phosphate buffer, and dehydrated in increasing concentrations of acetone. They were then embedded in Epon, and slices were cut at 50-90 nm using a Leica UC6 Ultra microtome on a glass knife. The sections were contrasted and visualized at 80 kV using a TEM JEOL JEM-1010. Images were obtained with a Mega View III camera (21).

### Statistical analysis

All data are presented as mean  $\pm$  standard deviation (SD). For statistical analysis of the effects of different treatments, a one-

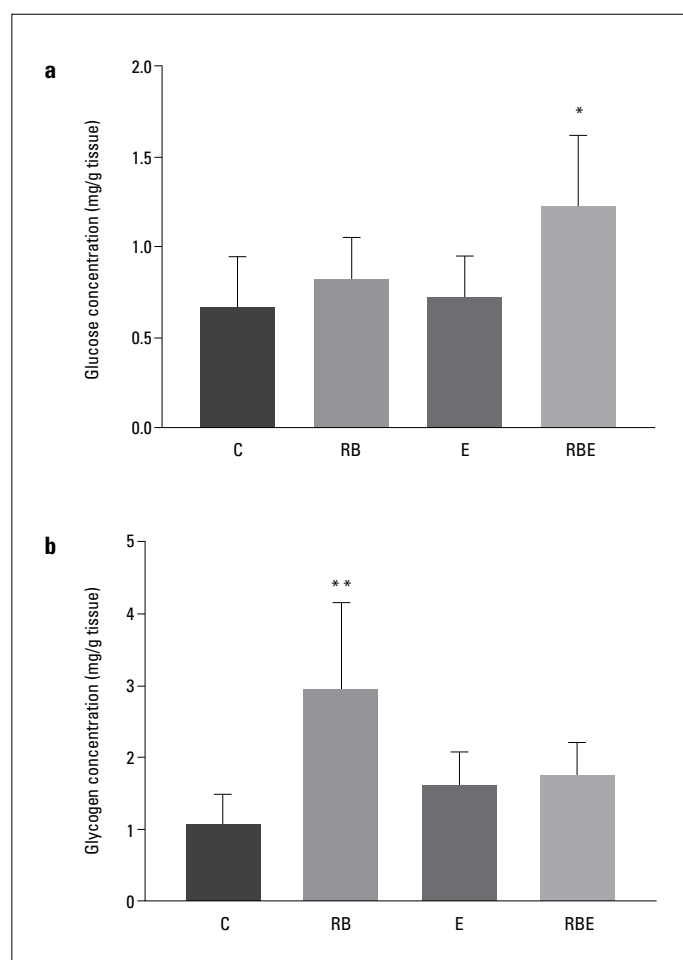
way analysis of variance with Dunnett's test was conducted. All data were analysed using GraphPad Prism version 6 for Windows (GraphPad Software Inc., La Jolla, CA, USA). Significance was considered at values of  $p < 0.05$ .

## Results

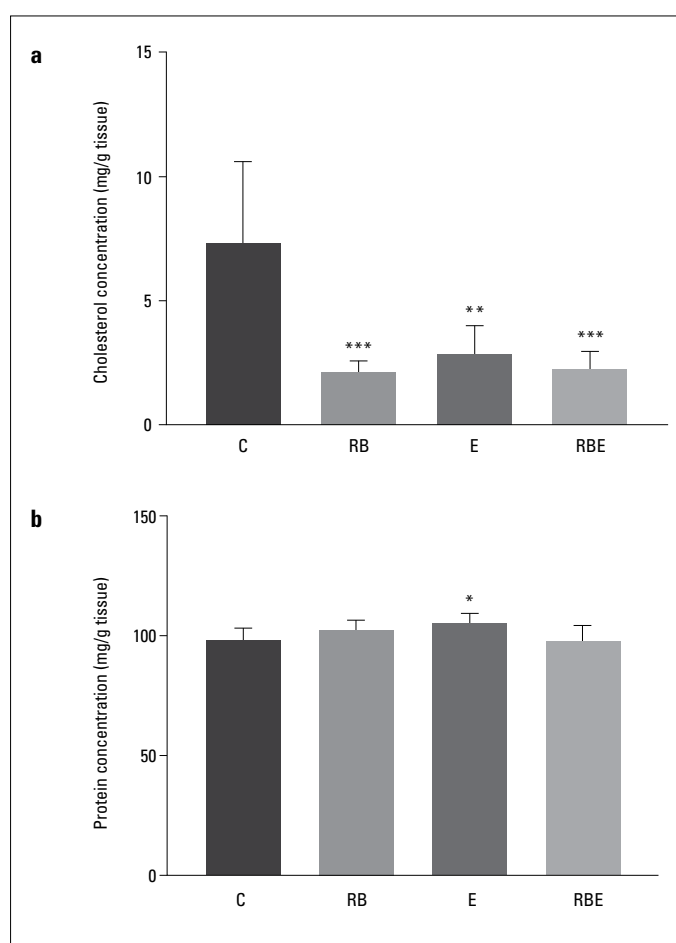
### Biochemical results

The effects of Red Bull, ethanol, and their combination on glucose and glycogen concentrations in the heart muscle are shown in Figure 1. These results revealed that glucose concentration increased in all treated groups, but this was significant only in the RBE group (RBE,  $1.233 \pm 0.3867$  vs. C,  $0.6699 \pm 0.2759$ ;  $p = 0.0217^*$ ) (Fig. 1a). A clear increase in the glycogen concentration (Fig. 1b) occurred in the RB group (RB  $2.946 \pm 1.2$  vs. C,  $1.077 \pm 0.4033$ ;  $p = 0.0019^{**}$ ).

The concentration of cholesterol was significantly decreased in all treated groups (RB,  $2.144 \pm 0.3724$  vs. C  $7.365 \pm 3.224$ ;



**Figure 1.** Changes induced by the combined physical effort (swimming test) and consumption of Red Bull and/or ethanol on (a) glucose and (b) glycogen concentrations in the myocardium. The results are presented as mean  $\pm$  SD.  $P < 0.05^*$  and  $P < 0.01^{**}$  vs. C. C - control; RB - Red Bull; E - ethanol, RBE - Red Bull and ethanol.  $n = 7$  in all groups



**Figure 2.** Variations in (a) total cholesterol and (b) protein concentrations in the myocardium after physical effort (swimming test) and consumption of Red Bull and/or ethanol. The results are presented as mean  $\pm$  SD.  $P < 0.05^*$ ,  $P < 0.01^{**}$  and  $P < 0.01^{***}$  vs. C. C - control; RB - Red Bull; E - ethanol; RBE - Red Bull and ethanol.  $n = 7$  in all groups

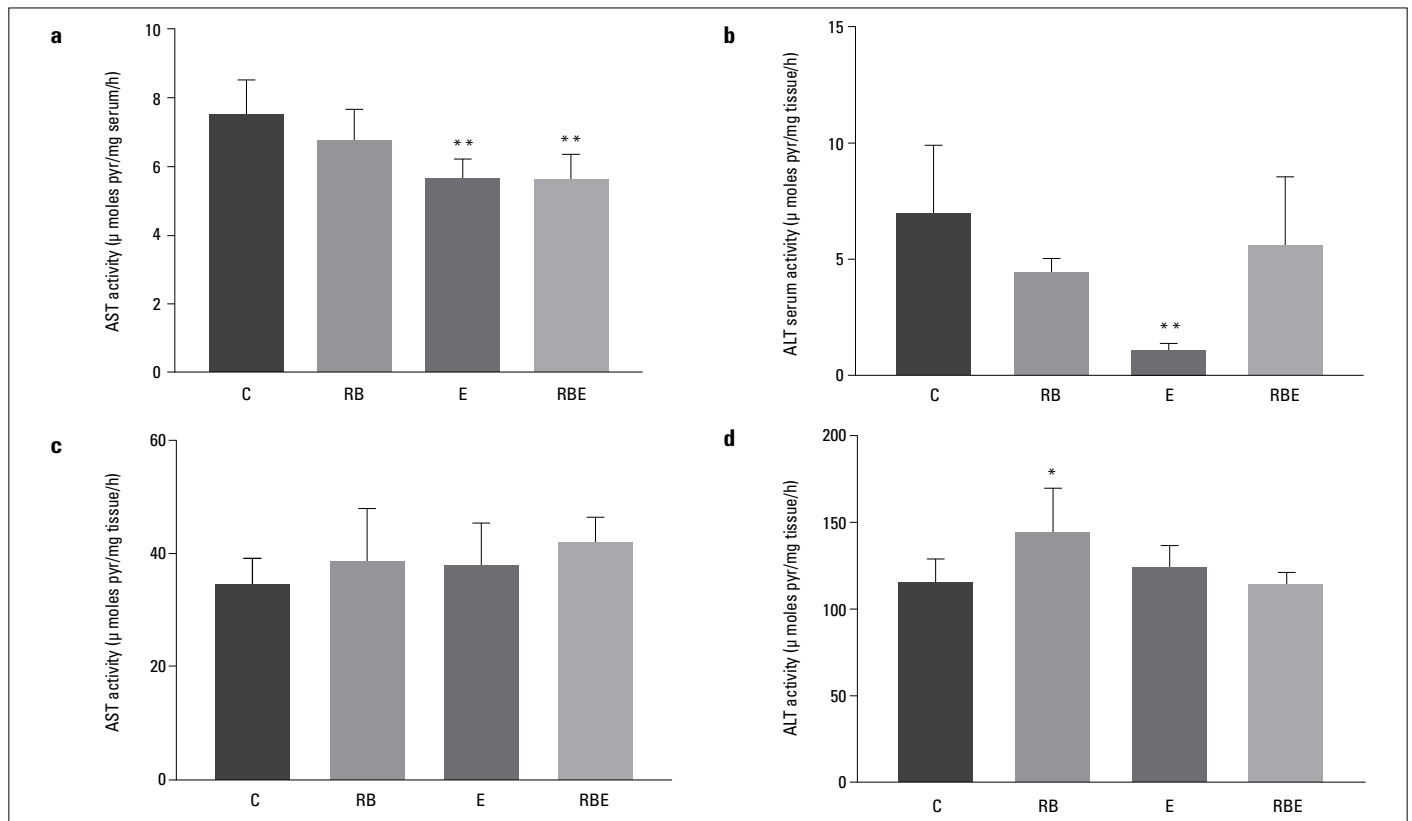
$p = 0.0004^{***}$ ; E,  $2.874 \pm 1.071$  vs. C  $7.365 \pm 3.224$ ;  $p = 0.0017^{**}$ ; RBE,  $2.264 \pm 0.6763$  vs. C,  $7.365 \pm 3.224$ ;  $p = 0.0004^{***}$ ; Fig. 2a).

Our results showed a slight increase in the myocardial protein concentration in all treated groups, being significant in the E group (E,  $105.3 \pm 3.883$  vs. C,  $98.23 \pm 4.852$ ;  $p = 0.0475^*$ ) (Fig. 2b).

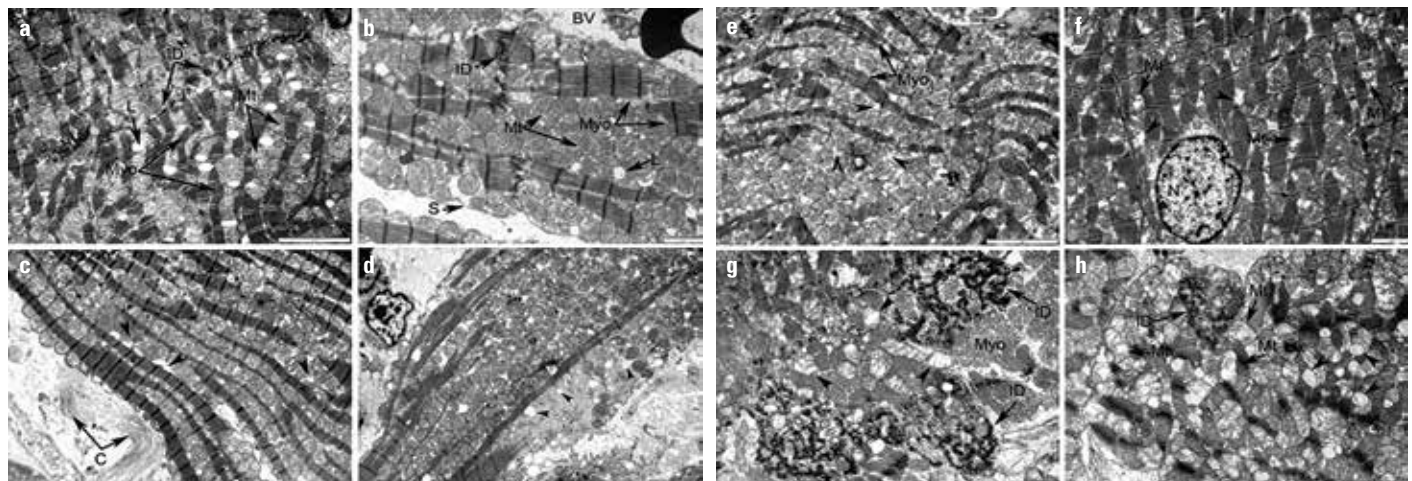
AST and ALT activities increased in the myocardium and decreased in the serum in all groups (Fig. 3). The increase in the ALT activity in the myocardium was significant only in the RB group (RB,  $144.5 \pm 25.06$  vs. C,  $115.1 \pm 13.43$ ;  $p = 0.0203^*$ ).

### Ultrastructural alterations

The most serious ultrastructural modifications observed in the heart tissue of rats in the E group (Fig. 4a-4d) were those that indicated the onset of alcoholic cardiomyopathy (a loose arrangement of myofibrils, and large spaces between myocytes occupied by several swollen mitochondria with dilated cristae). The morphological alterations induced in the heart muscle by EDs were very similar to those induced by ethanol (Fig. 4e and 4f).



**Figure 3.** The combined effects of physical effort (swimming test) and consumption of Red Bull and ethanol on (a) serum AST, (b) serum ALT, (c) myocardium AST, and (d) myocardium ALT activities. The results are presented as mean±SD.  $P<0.05^*$  and  $P<0.01^{**}$  vs. C. C - control; RB - Red Bull; E - ethanol; RBE - Red Bull and ethanol.  $n=7$  in all groups



**Figure 4.** Ultrastructure of the ventricular myocardium. (a) Control group: tightly packed intermyofibrillar mitochondria (Mt) surrounded by parallel bands of myofibrils (Myo), with contractile filaments organized in sarcomeres. Numerous lipid droplets (L) are visible in the proximity of mitochondria. Intercalated disks (ID) are visible at the limit between two adjacent cells. Bar, 2 µm. (b) Control group: tightly packed intermyofibrillar and subsarcolemmal mitochondria (Mt) with visible cristae are surrounded by parallel bands of myofibrils (Myo), with contractile filaments organized in sarcomeres. Lipid droplets (L) are visible in the proximity of mitochondria. Intercalated disks (ID) are visible at the limit between two adjacent cells. BV, blood vessel; PM, plasma membrane. Bar, 2 µm. (c) Ethanol-treated group: collagen fibers (C) are abundant in the intercellular space; lysis areas (arrowheads) are visible in the spaces occupied by mitochondria; some mitochondria have altered cristae. Bar, 5 µm. (d) Ethanol-treated group: enlarged spaces between myofibrils are occupied by numerous mitochondria, some showing altered cristae; in contrast, subsarcolemmal mitochondria population is reduced, and lysis areas (arrowheads) are visible. Bar, 5 µm. (e) Red Bull-treated group: the intermyofibrillar spaces are enlarged, with numerous lysis areas (arrowheads); numerous mitochondria have altered cristae. Bar, 5 µm. (f) Red Bull-treated group: numerous lysis areas (arrowheads) are present in the intermyofibrillar spaces; several mitochondria show disrupted cristae. Bar, 5 µm. (g) Red Bull and ethanol-treated group: disorganized intercalated disks (ID); numerous mitochondria with disrupted cristae (arrowheads). Bar, 2 µm. (h) Red Bull and ethanol-treated group: numerous vesicles that seem to be filled with glycogen (arrowheads) in the intermyofibrillar spaces, mitochondria having destroyed cristae (Mt), and disorganized intercalated disks (ID). Bar, 5 µm



## Discussion

This study shows, for the first time, that the long-term consumption of EDs, individually or in combination with ethanol, causes biochemical and ultrastructural alterations in the heart muscles.

Our results revealed that both Red Bull and ethanol increased glucose and glycogen concentrations in the myocardium. In the RB group, the increase in the glucose and glycogen concentrations was caused by two ingredients of ED, caffeine and taurine. Normally, caffeine causes calcium release from the intracytoplasmic stores (22) and activates AMPK via calcium/Calmodulin-dependent protein kinase kinase- $\beta$  (CaMKK) (23). AMPK promotes the uptake and use of glucose in the cardiomyocytes (24). Besides, AMPK either inhibits glycogen synthesis via the phosphorylation of glycogen synthase or activates glycogen degradation via the phosphorylation of glycogen phosphorylase (25). However, the chronic activation of AMPK, as probably happened in our study, may increase glycogen synthesis by increasing the glucose uptake and the formation of glucose-6-phosphate. This induces the allosteric activation of glycogen synthase that can overcome inhibitory phosphorylation by AMPK (26). Moreover, it has been reported that taurine increases glucose uptake, glycolysis, and glycogen synthesis in the heart of adult rats (27).

In our study, ethanol led to a slight increase in glucose and glycogen concentrations. Ethanol decreases the sensitivity to insulin, which is mediated in the heart muscle by tumour necrosis factor- $\alpha$  (TNF $\alpha$ ) and/or interleukin-6 (IL-6), inducing the activation of Jun N-terminal kinases, which inhibits the Akt-AS160-GLUT4 signaling pathway (28). As such, the glucose concentration should have decreased. We cannot provide an explanation of these results, and there is no study on this topic in the literature. However, ultrastructural modifications shown in Figure 4 led us to consider that the Krebs cycle was not correctly functioning and, consequently, the glucose metabolism in the myocardium was affected.

The combined administration of Red Bull and ethanol produced a significant increase in the glucose concentration, which was expected because the independent administration of each of these components increased the glucose concentration in the myocardium.

Glycogen is a vital molecule for the normal functioning of the myocardium. It is necessary for the ontogenetic development of the heart, because it supplies the necessary energy for the growth and development of the organ (29). In the mature organ, glycogen is found in small quantities, furnishing energy to the excito-conductor system. A large quantity of glycogen is beneficial only under ischemic conditions (30). Glycogen accumulation in the myocardium favours the incidence of pre-excitation syndrome (31). Several studies have reported an association of the EDs and/or alcohol with the occurrence of negative effects at the cardiovascular level (palpitations, cardiac arrhythmias, hypertension and even sudden cardiac death) (2, 32); therefore,

we cannot exclude the possibility that these effects were connected to glycogen accumulation in the myocardium.

Cholesterol concentration significantly decreased in all groups. This effect can in turn be a cause of the myocardial dysfunctions reported in the chronic consumption of EDs and alcohol. A role of cholesterol is to stiffen the cellular membranes and maintain the shape of cells by forming "bridges" (lipid rafts) in the regions where the membrane proteins are expressed (33). Additionally, cholesterol controls the membrane fluidity, and, consequently, plays an important role in the the cholesterol to phospholipid ratio (34). The molar ratio of cholesterol to phospholipids in plasma membranes is usually maintained just below unity (35). Therefore, reducing the cholesterol concentration may lead to membrane destabilization, which may in turn affect cellular metabolism in the myocardium.

The decrease in the cholesterol concentration induced by Red Bull might have been due to the elevated content of taurine and/or niacin present in the ED. This change is somewhat expected because both taurine and niacin are used in the prevention and cure of atherosclerosis (36, 37). More precisely, taurine reduces serum cholesterol (38) and niacin reduces serum cholesterol and triglycerides and increases HDL concentration (39).

Decreased cholesterol in the myocardium following chronic ethanol treatment has also been reported by Godfrey et al. (40) and Hu et al. (41), but no one has ever explained these results and the physiological significance of the phenomenon is unknown.

The combined administration of Red Bull and ethanol induced an even higher reduction of cholesterol in the myocardium than the independent administration of the two components.

Our results show a slight increase in the myocardial protein concentration in all treated groups, being significant in the E group. The slight increase in the protein concentration observed after the administration of Red Bull could be due to the high content of vitamin B6. A dose of Red Bull sold in Romania contains 250% of the recommended B6 daily dose. Vitamin B6 is an essential cofactor in the functioning of over 140 enzymes required for the synthesis, degradation, and interconversion of amino acids (42).

The formation of protein adducts could be an explanation for the significant increase in the protein concentration in the E group observed in our study. Research has shown that alcohol causes the accumulation of protein adducts in the hepatic, nervous, and muscular tissues, aggravating the ethanol-induced toxicity in these tissues (43). In a study by Worrall et al. (44), increased amounts of reduced acetaldehyde protein adducts, unreduced-acetaldehyde, and malondialdehyde-acetaldehyde were found in the cardiac tissue of rats after 6 weeks of alcohol treatment. Furthermore, a previous study has shown that adducts formed by acetaldehyde with proteins stimulate the formation of mRNA responsible for the synthesis of collagen and expression of connective tissue proteins (45).

AST and ALT activities increased in the myocardium and decreased in the serum following all treatments. According to the

ultrastructural alterations caused by Red Bull and ethanol, the activities of these membrane integrity markers were expected to be increased in the serum. However, our results are consistent with those of Mihailovic et al. (46), who reported an increase in the AST activity with unchanged ALT activity in the heart muscle after a 10-day treatment with ethanol. Our results show that Red Bull had the same detrimental effects as ethanol, at least in the heart muscle. Furthermore, the combination of Red Bull and ethanol had synergistic and/or complementary effects on AST activity.

The most serious ultrastructural alterations observed in the heart tissue of rats treated with ethanol (Fig. 4c and 4d) are those that indicate the onset of alcoholic cardiomyopathy. As pointed out by De Leiris et al. (47), human subjects and animal models exposed to chronic ethanol consumption undergo functional and structural alterations in the heart tissue. Oxidative stress induces lipid peroxidation, protein oxidation, reduces the GSH content of mitochondria, and disturbs calcium homeostasis, impairing the contractile capacity of the heart muscle. The organelles also show modified structures with disorganized cristae, resulting in altered oxidative metabolism. An excellent work of Tsiplenkova et al. (48) gives a detailed inventory of the damages caused by ethanol in alcoholic cardiomyopathy, such as the alteration of mitochondrial membranes including organelle swelling and loss of cristae. These authors also noticed an increase in the number of mitochondria with myocytes, in which the space occupied by mitochondria was larger than that occupied by myofibrils. This is consistent with our observation of enlarged intermyofibrillar spaces filled with mitochondria. Interestingly, we also found that the subsarcolemal mitochondria population was reduced, while numerous lysis areas were present.

In addition, we noticed collagen deposits in the intercellular space, which has also been reported by Urbano-Marquez and Fernandez-Sola (49) in human patients with alcoholic cardiomyopathy.

Whether such altered cardiomyocytes may end in apoptosis or in necrosis remains unclear; however, apoptosis, or even a combination of apoptosis and necrosis, seems to produce myocyte loss in alcoholic cardiomyopathy (50).

While cardiomyocyte alterations induced by alcohol consumption are well documented, there is very little evidence, if any, concerning ultrastructural alterations induced by EDs in the heart muscle. In some myocytes of the RB group, the myofibril arrangement showed a loose structure and the space between them was occupied by several large (swollen) mitochondria displaying a rarefied matrix and dilated cristae, which led to the assumption that oxidative metabolism was affected. All these morphological alterations correlated with measured biochemical alterations in glucose, glycogen, and cholesterol concentrations and AST and ALT activities reported in our study. The exaggerated proliferation of mitochondria ("mitochondriosis") in-between narrowed myofibrils was also reported by Tsiplenkova et al. (48), as a feature of alcoholic cardiomyopathy.

In the myocytes of the RBE group, the cumulated effects of ED and ethanol were even more dramatic, with an increase in the lysis areas, majority of myofibrils without a regular (parallel) arrangement, myofibrils with a part of them fragmented, and several mitochondria with rarefied structures and dilated cristae. Numerous vesicles were present in the intermyofibrillar spaces, probably filled with glycogen, as has been previously reported (49) in alcoholic cardiomyopathy. These structural alterations also support the biochemical changes measured in our study. Several myocytes had hypochromic nuclei with irregular borders, and the intercalated disks were fragmented and dehiscent.

### Study limitations

Our experimental groups were relatively small but allowed for the statistical processing of results. Further, the duration of further experiments should be extended to provide better insights in the long-term effects of using EDs, and to highlight possible adaptive mechanisms to their components. In addition, we used only one ED. Therefore, we consider that additional studies are needed using several such drinks, particularly because they have different compositions.

### Conclusion

Our results explain, to a certain extent, the symptoms described in the literature for those who consume EDs in large quantities or for a long period of time. We particularly refer to glycogen accumulation in the myocardium, which can disrupt the cardiac activity and may favor the occurrence of tachycardia, palpitations, cardiac arrhythmias, hypertension, and even death (2). The lowering of cholesterol concentration may, in turn, be a cause of myocardial dysfunctions reported in the literature following the chronic consumption of EDs and alcohol. Athletes, as well as active individuals, should avoid both the consumption of EDs and their consumption in combination with alcohol. Our results showed that EDs produce morphological changes in the heart muscle similar to those produced by ethanol. Further research, on different EDs as a whole and on separate components is necessary to deeply understand their detrimental effects and the mechanisms by which they are produced.

**Conflict of interest:** None declared.

**Peer-review:** Externally peer-reviewed.

**Authorship contributions:** Concept – C.M., C.L.; Design – C.M., C.R., C.L.; Supervision – C.L.; Fundings – Internal resources of Faculty of Biology and Geology; Materials – C.R., C.L.; Data collection &/or processing – C.M., C.L.; Analysis &/or interpretation – C.M., C.R., C.T., C.L.; Literature search – C.M., C.L.; Writing – C.M., C.R., C.T., C.L.; Critical review – C.M., C.R., C.T., C.L.

## References

1. Enriquez A, Frankel DS. Arrhythmogenic effects of energy drinks. *J Cardiovasc Electrophysiol* 2017; 28: 711-7.
2. De Sanctis V, Soliman N, Soliman AT, Elsedfy H, Di Maio S, El Kholy M, et al. Caffeinated energy drink consumption among adolescents and potential health consequences associated with their use: a significant public health hazard. *Acta Biomed* 2017; 88: 222-31.
3. Verster JC, Aufricht C, Alford C. Energy drinks mixed with alcohol: misconceptions, myths, and facts. *Int J Gen Med* 2012; 5: 187-98.
4. Ferreira SE, de Mello MT, Pompéia S, de Souza-Formigoni ML. Effects of energy drink ingestion on alcohol intoxication. *Alcohol Clin Exp Res* 2006; 30: 598-605.
5. Zheng G, Qiu Y, Zhang QF, Li D. Chlorogenic acid and caffeine in combination inhibit fat accumulation by regulating hepatic lipid metabolism-related enzymes in mice. *Br J Nutr* 2014; 112: 1034-40.
6. Higgins JP, Tuttle TD, Higgins CL. Energy beverages: content and safety. *Mayo Clin Proc* 2010; 85: 1033-41.
7. Schaffer SW, Jong CJ, Ramila KC, Azuma J. Physiological roles of taurine in heart and muscle. *J Biomed Sci* 2010; 17 (Suppl 1): S2.
8. El Idrissi A, Okeke E, Yan X, Sidime F, Neuwirth LS. Taurine regulation of blood pressure and vasoactivity. *Adv Exp Med Biol* 2013; 775: 407-25.
9. Julius U. Niacin as antidyslipidemic drug. *Can J Physiol Pharmacol* 2015; 93: 1043-54.
10. Garg A, Sharma A, Krishnamoorthy P, Garg J, Virmani D, Sharma T6, et al. Role of niacin in current clinical practice: a systematic review. *Am J Med* 2017; 130: 173-87.
11. Duncan MJ, Hankey J. The effect of a caffeinated energy drink on various psychological measures during submaximal cycling. *Physiol Behav* 2013; 116-117: 60-5.
12. Grasser EK, Dulloo AG, Montani JP. Cardiovascular and cerebrovascular effects in response to Red Bull consumption combined with mental stress. *Am J Cardiol* 2015; 115: 183-9.
13. Elitok A, Oz F, Panc C, Jarikaya R, Sezikli S, Pala Y, et al. Acute effects of Red Bull energy drink on ventricular repolarization in healthy young volunteers: a prospective study. *Anatol J Cardiol* 2015; 15: 919-22.
14. Nelson N. A photometric adaptation of the Somogy method for the determination of glucose. *J Biol Chem* 1944; 153: 375-80.
15. Somogyi M. A new reagent for determination of sugars. *J Biol Chem* 1945; 160: 61-8.
16. Montgomery R. Determination glycogen. *Arch Bioch Biophys* 1957; 67: 378-86.
17. Lo S, Russel JC, Taylor AW. Determination of glycogen in small tissue samples. *J Appl Physiol* 1970; 28: 234-6.
18. Zlatkis A, Zak B, Boyle AJ. A new method for the direct determination of serum cholesterol. *J Lab Clin Med* 1953; 41: 486-92.
19. Bradford MM. A rapid and sensitive method for the quantitation of microgram quantities of protein utilizing the principle of protein-dye binding. *Anal Biochem* 1976; 72: 248-54.
20. Reitman S, Frankel S. A colorimetric method for the determination of serum glutamic oxalacetic and glutamic pyruvic transaminases. *Am J Clin Pathol* 1957; 28: 56-63.
21. Kuo J. *Electron Microscopy Methods and Protocols*. Crawley: Humana Press 2007, p.19-35, 67-107.
22. Kong H, Jones PP, Koop A, Zhang L, Duff HJ, Chen SR. Caffeine induces Ca<sup>2+</sup> release by reducing the threshold for luminal Ca<sup>2+</sup> activation of the ryanodine receptor. *Biochem J* 2008; 414: 441-52.
23. Fogarty S, Hawley SA, Green KA, Saner N, Mustard KJ, Hardie DG. Calmodulin-dependent protein kinase kinase- $\beta$  activates AMPK without forming a stable complex: synergistic effects of Ca<sup>2+</sup> and AMP. *Biochem J* 2010; 426: 109-18.
24. Daskalopoulos EP, Dufey C, Beauloye C, Bertrand L. AMP-activated Protein Kinase. In: Cordero MD, Viollet B, editors. *AMPK In Cardiovascular Diseases*. Switzerland: Springer International Publishing; 2016. p.179-201.
25. Jeon SM. Regulation and function of AMPK in physiology and diseases. *Exp Mol Med* 2016; 48: e245.
26. Hunter RW, Treebak JT, Wojtaszewski JFP, Sakamoto K. Molecular Mechanism by Which AMP-Activated Protein Kinase Activation Promotes Glycogen Accumulation in Muscle. *Diabetes* 2011; 60: 766-74.
27. Lampson WG, Kramer JH, Schaffer SW. Potentiation of the actions of insulin by taurine. *Can J Physiol Pharmacol* 1983; 61: 457-63.
28. Lang CH, Derdak Z, Wands JR. Strain-dependent differences for suppression of insulin-stimulated glucose uptake in skeletal and cardiac muscle by ethanol. *Alcohol Clin Exp Res* 2014; 38: 897-910.
29. Pederson BA, Chen H, Schroeder JM, Shou W, DePaoli-Roach AA, Roach PJ. Abnormal Cardiac Development in the Absence of Heart Glycogen. *Mol Cell Biol* 2004; 24: 7179-87.
30. Depre C, Vanoverschelde JL, Taegtmeyer H. Glucose for the heart. *Circulation* 1999; 99: 578-88.
31. Kishnani PS, Chen YT. Disorders of Carbohydrate Metabolism. In: Rimoin DL, Pyeritz RE, Korf BR, editors. *Emery and Rimoin's Principles and Practice of Medical Genetics*. 6th ed. Academic Press 2013; p.1-35.
32. Rotstein J, Barber J, Strowbridge C, Hayward S, Huang R, Godefroy SB. Energy Drinks: An Assessment of the Potential Health Risks in the Canadian Context. *Int Food Risk Anal J* 2013; 3: 1-29.
33. Van Meer G, Voelker DR, Feigenson GW. Membrane lipids: where they are and how they behave. *Nat Rev Mol Cell Biol* 2008; 9: 112-24.
34. Lange Y, Ye J, Steck TL. How cholesterol homeostasis is regulated by plasma membrane cholesterol in excess of phospholipids. *Proc Natl Acad Sci USA* 2004; 101: 11664-7.
35. Lange Y, Swaisgood MH, Ramos BV, Steck TL. Plasma membranes contain half the phospholipid and 90% of the cholesterol and sphingomyelin in cultured human fibroblasts. *J Biol Chem* 1989; 264: 3786-93.
36. Xu YJ, Arneja AS, Tappia PS, Dhalla NS. The potential health benefits of taurine in cardiovascular disease. *Exp Clin Cardiol* 2008; 13: 57-65.
37. Chen W, Guo JX, Chang P. The effect of taurine on cholesterol metabolism. *Mol Nutr Food Res* 2012; 56: 681-90.
38. Ruparelia N, Digby JE, Choudhury RP. Effects of niacin on atherosclerosis and vascular function. *Curr Opin Cardiol* 2011; 26: 66-70.
39. Barter PJ. The Causes and Consequences of Low Levels of High Density Lipoproteins in Patients with Diabetes. *Diabetes Metab J* 2011; 35: 101-6.
40. Godfrey J, Jeanguenin L, Castro N, Olney JJ, Dudley J, Pipkin J, et al. Chronic voluntary ethanol consumption induces favourable ceramide profiles in selectively bred alcohol-preferring (P) rats. *PLoS One* 2015; 10: e0139012.
41. Hu C, Ge F, Hyodo E, Arai K, Iwata S, Lobdell H 4th, et al. Chronic ethanol consumption increases cardiomyocyte fatty acid uptake and decreases ventricular contractile function in C57BL/6J mice. *J Mol Cell Cardiol* 2013; 59: 30-40.
42. Dakshinamurti S, Dakshinamurti K. Vitamin B6. In: Zempleni J, Sut-

- tie JW, Gregory JF III et al., editors. Handbook of Vitamins. 5th ed. Boca Raton FL USA: CRC Press, Taylor and Francis 2013; p.315-60.
43. Niemelä O. Distribution of ethanol-induced protein adducts in vivo: relationship to tissue injury. *Free Radic Biol Med* 2001; 31: 1533-8.
  44. Worrall S, Richardson PJ, Preedy VR. Experimental heart muscle damage in alcohol feeding is associated with increased amounts of reduced- and unreduced-acetaldehyde and malondialdehyde-acetaldehyde protein adducts. *Addict Biol* 2000; 5: 421-7.
  45. Ren J and Wold LE. Mechanisms of alcoholic heart disease. *Ther Adv Cardiovasc Dis* 2008; 2: 497-506.
  46. Mihailovic D, Nikolic J, Bjelakovic BB, Stankovic BN, Bjelakovic G. Morphometric and biochemical characteristics of short-term effects of ethanol on rat cardiac muscle. *Exp Toxicol Pathol* 1999; 51: 545-7.
  47. De Leiris J, De Lorgelir M, Boucher F. Ethanol and cardiac function. *Am J Physiol Heart Circ Physiol* 2006; 291: H1027-8.
  48. Tsiplenkova VG, Vikhert AM, Cherpachenko NM. Ultrastructural and histochemical observations in human and experimental alcoholic cardiomyopathy. *J Am Coll Cardiol* 1986; 8(1 Suppl A): 22A-32A.
  49. Urbano-Márquez A, Fernández-Solà J. Effects of alcohol on skeletal and cardiac muscle. *Muscle Nerve* 2004; 30: 689-707.
  50. Piano MR. Alcoholic cardiomyopathy: incidence, clinical characteristics, and pathophysiology. *Chest* 2002; 121: 1638-50.