

# A New Onset of Systemic Lupus Erythematosus Developed After Bee Venom Therapy

Young Hee Rho, Jin-Hyun Woo, Seong Jae Choi, Young Ho Lee, Jong Dae Ji, and Gwan Gyu Song

Division of Rheumatology, Department of Internal Medicine, Korea University College of Medicine, Seoul, Korea

Lupus is a systemic autoimmune disease of an unknown origin, and systemic lupus erythematosus (SLE) can be triggered by numerous stimuli. Bee venom therapy is an alternative therapy that is believed to be effective for various kinds of arthritis. We present here a case of a 49-year-old female who experienced a new onset lupus after undergoing bee venom therapy, and this looked like a case of angioedema. The patient was successfully treated with high dose steroids and antimalarial drugs. We discuss the possibility of bee venom contributing to the development of SLE, and we suggest that such treatment should be avoided in patients with lupus. (**Korean J Intern Med 2009;24:283-285**)

**Keywords:** Lupus erythematosus, systemic ; Bee venoms; Angioedema

## INTRODUCTION

Lupus is a systemic autoimmune disease of an unknown origin, and systemic lupus erythematosus (SLE) is known to be under the immunological influence of Th2 [1]. Bee venom therapy is an alternative therapy that is believed to be effective for various kinds of arthritis [2]. We present here a case of a new onset SLE after the patient underwent bee venom therapy, and the clinical picture resembled that of angioedema.

## CASE REPORT

During November 2004, a 49-year-old female patient visited the rheumatology clinic at Korea University Medical Center. She complained of diffuse muscle pain and weakness, with arthralgia on her hands, feet, elbows and knees that had persisted for 6 months. She had equivocal morning stiffness and physical findings. With the possibility of autoimmune disease, she was offered laboratory evaluation along with analgesic treatment, but she declined. One

month later, the patient was admitted to the infectious diseases division with the chief complaint of dysuria and fever. She was evaluated and treated under the impression of having a urinary tract infection, but treatment was ineffective and any microbial evidence could not be found. She was then referred to the Division of Rheumatology for assessment of her fever and pan-cytopenia. She was found to have undergone a trial of bee venom therapy on her knees 10 days before the admission, which did relieve her arthralgia. Her fever was reported to have begun shortly after the treatment.

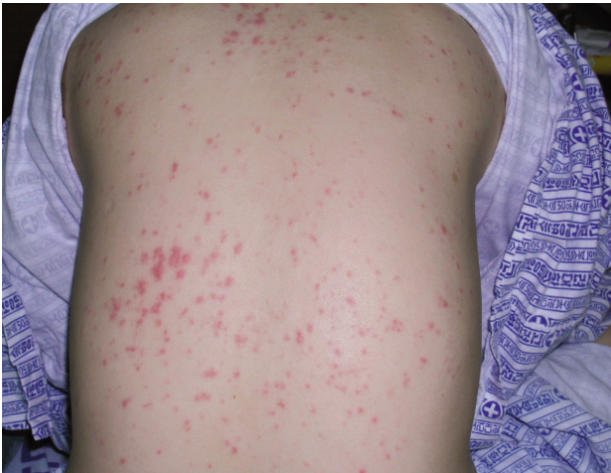On inspection, the patient was ill looking and had an edematous, puffy face with swollen eyelids, giving the impression of angioedema. She also had a generalized erythematous papular rash, especially on the trunk (Fig. 1.) There was only a subtle local reaction on the bee venom injection site. Oral thrush was also found, which was later confirmed to be oral candidiasis. Her vital signs were a body temperature of 38.9°C, a blood pressure of 160/90 mmHg, a heart rate of 96/minutes and a respiration rate of 20/minutes. Suspicious crackles were heard on both lower lungs. She was initially found to have mild costover-

Received: January 3, 2007

Accepted: June 22, 2007

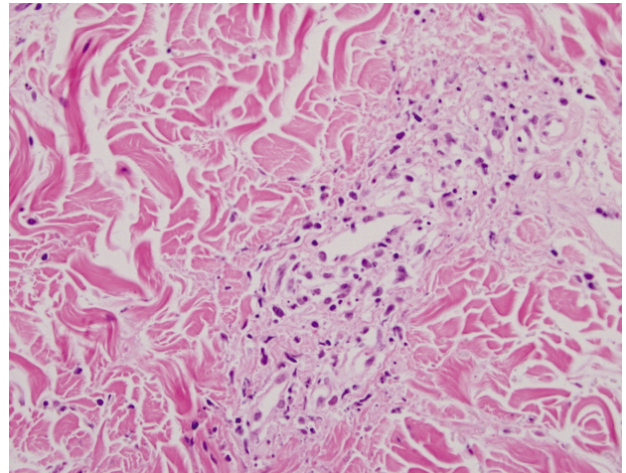
Correspondence to Gwan Gyu Song, M.D., Ph.D.

Division of Rheumatology, Department of Internal Medicine, Korea University Guro Hospital, 97 Gurodong-gil, Guro-gu, Seoul 152-703, Korea  
Tel: 82-2-818-6667, Fax: 82-2-2626-1137, E-mail: gsong@kumc.or.kr



**Figure 1.** Rash on the back of the patient. Diffuse erythematous papular lesions are noted.

tebral tenderness, but this disappeared later. Her laboratory findings were a white blood cell count of  $2,340/\mu\text{L}$  (lymphocytes 10%, stab neutrophils 78%, neutrophils 8%, monocytes 1%, eosinophils/basophils 0%, myelocytes 3%), a hemoglobin level of 8.0 g/dL and a platelet count of  $177,000/\mu\text{L}$ . The erythrocyte sedimentation rate (ESR) was 57 mm/hours (reference, 0-20 mm/hours) and the C-reactive protein was 11.1 mg/dL (reference, 0-0.6 mg/dL). The hepatic transaminase levels were elevated (AST 128 IU/L and ALT 41 IU/L). The renal function tests were normal and neither sediments nor protein were found on spot urine analysis. Three days after admission the WBC and platelet counts fell to  $1,240/\mu\text{L}$  and  $70,000/\mu\text{L}$ , respectively, and antinuclear antibody tests revealed an 1:1280 homogenous pattern with the presence of extractable nuclear antigens (ENA) like anti-Ro (3+), La (1+), RNP (3+), nucleosomes (3+), Sm (+/-) and histone (-), according to the immunoblot method. Her anti-ds-DNA titer was 73 IU/mL (reference, 0-5.3 IU/mL) and the complement levels were C3: 34.7/C4: 13.6 mg/dL (reference, 88-201/ 16-47 mg/dL). Hypergammaglobulinemia was also noted. Interestingly, the IgE levels was elevated (1,364 IU/mL [reference, 0-20 IU/mL]), but radioallergosorbent tests (RAST) for honeybee, yellow hornet and common wasp allergens were negative (class 0). Other autoantibodies like rheumatoid factor, ANCA, and anti-phospholipid antibodies were not detected. Her chest X-ray showed infiltrations in the right lower lung region suggestive of bronchitis, but she did not produce sputum. Abdominal sonograms revealed only a mild to moderate fatty liver, without splenomegaly. Pathologic examination of the skin lesions revealed leukocytoclastic



**Figure 2.** Microscopic view of the skin biopsy specimen (H-E stain,  $\times 400$ ). Leukocytoclastic vasculitis is noted.

vasculitis (Fig. 2).

With the findings of facial rash, pancytopenia and the presence of ANA and specific autoantibodies, the diagnosis of a new onset lupus was made, which seemed to be triggered by the bee venom therapy, and she was treated with intravenous pulse steroids (methylprednisolone 1 g for 1 day) and subsequent high dose oral steroids (prednisolone 1 mg/kg) with hydroxychloroquine (400 mg/day). Empirical antibiotics, with oral fluconazole for her oral candidiasis, were maintained during the treatment period. Prompt defervescence was noted and the rash subsided within a few days. She did suffer a complication of delirium during the treatment period, which was probably due to the high doses of steroids. However the pancytopenia along with her clinical state improved, and she was discharged 10 days after admission, relatively symptom-free. The chest radiographs improved during the treatment period. She was found to have complete cutaneous resolution at the first visit one week later, but she was lost to further follow-up.

## DISCUSSION

The idea of using bee venom as a treatment for arthritic symptoms is not a new one, and it is thought to have originated during ancient times [3]. Bee venom is effective in murine arthritic models [4,5] and it has also shown effectiveness in human trials [2]. Its effectiveness is thought to be mediated through inhibition of macrophages and lymphocytes, which leads to decreased IL-1/IL-2 production and inhibition of NF- $\kappa$ b [3]. In addition, bee

venom's anti-nociceptive effects were found to be mediated through alpha-2 adrenoceptors [6]. At the same time, it is also well known that bee venom can inflict severe complications such as anaphylaxis [7]. We cannot be entirely sure of the role of bee venom in our patient because rechallenge experiments could not be done. Also, the possibility of having an underlying infection as a precipitating factor cannot be totally refuted. However, considering the temporal sequence of the patient's clinical history, it is likely that a mild subclinical level of lupus activity must have been ongoing, and it seems very likely that the venom triggered the borderline disease into a full-blown onset of overt lupus. As there was no microbial evidence except oral candidiasis and no response to antimicrobial therapy, the influence of infection (if any) seems to be small. There are very few reports of lupus triggered by bee stings, with only one report of subacute cutaneous lupus that was triggered by a wasp sting [8]. Our case is noteworthy for this as well.

It should be noted that the patient's IgE levels were high. As mentioned above, lupus is traditionally thought to be related to Th2 immunity, which is also associated with allergic diseases. There is evidence that the IgE levels correlate with lupus activity [9], so it may be postulated that the bee venom induced an immune response that most likely involved Th2, and this tipped the balance to the full development of lupus. Since no venom-specific antibodies were detected, the precise mechanism could not be clearly defined.

In conclusion, although bee venom therapy may be effective, taking a careful pre-treatment history and clinical evaluation must be done before starting treatment. It also should be noted that bee venom therapy may cause a flare-up of lupus, and this can happen in previously diagnosed patients, so prudence is needed before treating such patients.

## REFERENCES

1. Arend WP, Gabay C. Cytokines in the rheumatic diseases. *Rheum Dis Clin North Am* 2004;30:41-67, v-vi.
2. Lee JD, Park HJ, Chae Y, Lim S. An Overview of Bee Venom Acupuncture in the Treatment of Arthritis. *Evid Based Complement Alternat Med* 2005;2:79-84.
3. Panush RS. Honeybees and arthritis: sharpening perspective on a sticky issue. *J Rheumatol* 1988;15:1461-1462.
4. Kwon YB, Lee JD, Lee HJ, et al. Bee venom injection into an acupuncture point reduces arthritis associated edema and nociceptive responses. *Pain* 2001;90:271-280.
5. Park HJ, Lee SH, Son DJ, et al. Antiarthritic effect of bee venom: inhibition of inflammation mediator generation by suppression of NF-kappaB through interaction with the p50 subunit. *Arthritis Rheum* 2004;50:3504-3515.
6. Baek YH, Huh JE, Lee JD, Choi do Y, Park DS. Antinociceptive effect and the mechanism of bee venom acupuncture (Apipuncture) on inflammatory pain in the rat model of collagen-induced arthritis: Mediation by alpha2-Adrenoceptors. *Brain Res* 2006;1073-1074:305-310.
7. Song HJ, Suh YJ, Yang YM, et al. Two cases of anaphylaxis due to bee venom acupuncture. *J Asthma Allergy Clin Immunol* 2002; 22:481-486.
8. Boehm I, Bieber T. Wasp-sting-triggered LE. *Allergy* 2001;56:87-88.
9. Sekigawa I, Yoshiike T, Iida N, Hashimoto H, Ogawa H. Allergic diseases in systemic lupus erythematosus: prevalence and immunological considerations. *Clin Exp Rheumatol* 2003;21:117-121.