

MINI-FOCUS ISSUE: ELECTROPHYSIOLOGY

INTERMEDIATE

CASE REPORT: CLINICAL CASE SERIES

Severe Heart Failure Associated With Tachycardia-Induced Cardiomyopathy Due to Incessant Atrioventricular Re-Entrant Tachycardia



Thibaut Moulin, MD, Rosanna Landes, MD, Victoria Ouazana, MD, Guillaume Abehsira, MD, Pascal Lim, MD, PhD, Raphaele Hugué, MD, Thibaud Damy, MD, PhD, Emmanuel Teiger, MD, PhD, Nicolas Lellouche, MD, PhD, David Hamon, MD

ABSTRACT

Short RP interval atrioventricular re-entrant tachycardias do not typically present as an incessant form. We present 2 cases of incessant atrioventricular re-entrant tachycardias leading to tachycardia-induced cardiomyopathy with severe heart failure presentation in middle-aged adults. Both underwent accessory pathway ablation and recovered normal left ventricle function before hospital discharge. (**Level of Difficulty: Intermediate.**) (J Am Coll Cardiol Case Rep 2021;3:479–83) © 2021 Published by Elsevier on behalf of the American College of Cardiology Foundation. This is an open access article under the CC BY-NC-ND license (<http://creativecommons.org/licenses/by-nc-nd/4.0/>).

INTRODUCTION

Tachycardia-induced cardiomyopathy (TCM) is defined as left ventricle (LV) dysfunction due to

persistent tachycardia, recovering after eradication of the arrhythmia or heart rate control (1,2). Among supraventricular tachycardias, TCM has been well described with atrial fibrillation (3), atrial tachycardias (4), and permanent junctional reciprocating tachycardias using a concealed, slowly conducting, and mainly septal accessory pathway (AP) (5).

Typical orthodromic atrioventricular re-entrant tachycardias (AVRTs) due to nondecremental AP seldom present as an incessant form. Therefore, TCM secondary to these arrhythmias is rare and poorly described.

We present here 2 consecutive cases of incessant AVRT using left lateral AP leading to TCM and severe heart failure in middle-aged adults. Both were referred to our cardiology department.

LEARNING OBJECTIVES

- To highlight that AVRT using non-decremental AP may present as an incessant form and lead to TCM with heart failure syndrome rather than palpitations.
- To emphasize the necessity of an early AP ablation in this setting given the severity and the inefficiency of antiarrhythmic drugs.
- To be aware of this potentially rare but severe evolution in patients with paroxysmal and mildly symptomatic AVRT in whom ablation is not immediately considered.

From the Assistance Publique-Hôpitaux de Paris, Henri Mondor Hospital, Cardiology Department, Créteil, France. The authors attest they are in compliance with human studies committees and animal welfare regulations of the authors' institutions and Food and Drug Administration guidelines, including patient consent where appropriate. For more information, visit the [Author Center](#).

Manuscript received September 29, 2020; revised manuscript received October 26, 2020, accepted November 9, 2020.

ABBREVIATIONS AND ACRONYMS

AP = accessory pathway

AVRT = atrioventricular reentrant tachycardia

ECG = electrocardiogram

LV = left ventricle

LVEF = left ventricle ejection fraction

TCM = tachycardia-induced cardiomyopathy

TTE = transthoracic echocardiography

CASE SERIES

PATIENT 1. A 53-year-old woman with a history of depressive disorder presented to our emergency department for asthenia, shortness of breath, nausea, and continuous palpitations evolving for 2 months. She had no cardiac history.

At admission, she was normotensive and tachycardic with a regular heart rate of 180 beats/min. She was in New York Heart Association functional class IV with mild congestive heart failure signs (**Table 1**).

Electrocardiogram (ECG) revealed a regular 1:1 narrow QRS complex tachycardia with short RP interval ($RP < PR$) and $RP > 90$ ms compatible with AVRT, atypical atrioventricular nodal reentrant tachycardia, or atrial tachycardia (**Figure 1A**).

Blood tests showed a significant increase in N-terminal pro-B-type natriuretic peptide, aminotransferases, and cholestatic enzymes (**Table 1**). Chest radiography showed bilateral venous congestion and alveolar edema (**Figure 1C**).

A transthoracic echocardiography (TTE) performed during the tachycardia revealed a global hypokinesia with left ventricle ejection fraction (LVEF) reduced to 20% (**Video 1**).

Vagal maneuvers and 2 adenosine rapid injections failed to permanently stop the tachycardia due to incessant recurrent onset after terminations (**Figure 1B**). Finally, the tachycardia was stopped with a 300 mg Amiodarone injection. There was no pre-excitation on baseline ECG.

The patient was admitted to our cardiology unit. She was treated with intravenous Furosemide allowing rapid clinical and biological improvement.

A control TTE was performed after 3 days of permanent sinus rhythm and revealed a normalization of LVEF (65%) (**Video 2**) with a moderately dilated LV (**Table 1**).

An electrophysiological study was performed the same day. The narrow QRS complex tachycardia was easily induced without isoproterenol administration allowing the diagnosis of an orthodromic AVRT using a left lateral AP, successfully ablated. Intravenous amiodarone infusion was necessary to perform the electrophysiological study because of substantial atrial vulnerability leading to atrial fibrillation conversion during AVRT or even slow pacing maneuvers.

The patient was discharged the next day. She was then asymptomatic and biological parameters were normalizing (**Table 1**).

A control TTE was performed 4 months after discharge and showed a nondilated LV with normal LVEF (67%).

PATIENT 2. A 59-year-old man without any cardiac history was admitted to our emergency unit for dyspnea, asthenia, and right hypochondrium pain for several weeks. His medical history was a hemorrhagic rectocolitis treated with corticosteroid.

At admission, the patient was normotensive and tachycardic. He presented congestive heart failure signs with pulmonary edema, lower limbs edema, and hepatojugular reflux (**Table 1**). ECG also revealed a 1:1 narrow QRS complex tachycardia (170 beats/min) with $PR > RP > 90$ ms (**Figure 2A**).

Tachycardia was incessant, sometimes resumed with vagal maneuvers or adenosine injection, but with spontaneous recurrence as an orthodromic or antidromic form (prompted by vagal depressive effect on nodal conduction) after a few seconds or minutes despite a 900 mg Amiodarone injection. The morphology of pre-excitation strongly suggested the presence of a left anterolateral AP (**Figure 2B**).

Blood tests also showed a significant increase in N-terminal pro-B-type natriuretic peptide, aminotransferases, and cholestatic enzymes (**Table 1**).

The patient was admitted to our unit and treated with intravenous Furosemide. Orthodromic tachycardia was incessant despite the continuation of Amiodarone administration.

A TTE performed the first day during the few minutes in sinus rhythm revealed a discretely dilated LV with a severely depressed LV function (30% LVEF) and mild mitral regurgitation (**Videos 3 and 4, Table 1**). Coronary angiography results were normal.

An electrophysiological study was performed 3 days after admission, which confirmed the diagnosis of AVRT using a left anterolateral AP. The AP ablation definitely stopped the tachycardia and restored a normal sinus rhythm.

Two days after ablation, a control TTE showed a normalization of LVEF (56%) (**Video 5, Table 1**). At discharge, congestive heart failure signs had disappeared, and biological parameters were continuously improving (**Table 1**). The patient had no recurrence of supraventricular tachycardia or heart failure.

DISCUSSION

We describe here 2 cases of tachycardia-induced cardiomyopathy due to incessant orthodromic AVRT with heart failure presentation.

Although permanent junctional reciprocating tachycardias are commonly incessant and associated

TABLE 1 Patient Characteristics, Clinical, Biological, and Echocardiographic Data

	Patient 1		Patient 2	
Age, yrs	53		59	
Sex	Female		Male	
Body mass index, kg/m ²	26.7		20.1	
Accessory pathway	Left lateral		Left anterolateral	
Physical examination at admission	Rales at pulmonary bases, nausea, palpitations		Rales up to one-half lung fields, peripheral edema, hepatojugular reflux, right hypochondrium pain	
Heart rate, beats/min	180		170	
Blood pressure, mm Hg	120/70		105/83	
SpO ₂ , %	98		97	
Temperature, °C	37.2		37.1	
Blood test	Day 1	Discharge (Day 4)	Day 1	Discharge (Day 10)
NT-proBNP, ng/ml	4,199	744	2,188	202
T-Troponin, ng/l	17	-	24	15
AST (N <35 U/l)	99	24	63	24
ALT (N <35 U/l)	318	120	117	54
GGT (N <40 U/l)	449	304	270	252
ALP (N <105 U/l)	188	138	132	112
Bilirubin, μmol/l	23	12	41	8
Creatinine, μmol/l	95	81	83	77
Lactate, mmol/l	1.5	-	1.7	-
TSH, mU/l	0.58	-	2.67	-
Hemoglobin, g/dl	14	-	12	-
TTE	Day 1	Day 3	Day 1	Day 5
Rhythm	Tachycardia 180 beats/min	Sinus rhythm	Sinus rhythm	Sinus rhythm
LVEDD, mm (LVEDDi, mm/m ²)	50 (26)	56 (29)	57 (32)	58 (32)
LVEDV, ml (LVEDVi, ml/m ²)	-	120 (62)	141 (77)	150 (83)
LVEF, %*	20	65	30	56
Left atrium volume, ml/m ²	-	51	-	44
sPAP, mm Hg	-	35	50	30
Valvular heart disease	-	Mild MR	Mild MR	Mild MR

*With Simpson biplane method.
 ALT = alanine aminotransferase; ALP = alkaline phosphatase; AST = aspartate aminotransferase; GGT = gamma-glutamyltransferase; LVEDD = left ventricle end-diastolic diameter; LVEDDi = indexed left ventricle end-diastolic diameter; LVEDV = left ventricle end-diastolic volume; LVEDVi = indexed left ventricle end-diastolic volume; LVEF = left ventricle ejection fraction; MR = mitral regurgitations; NT-proBNP = N-terminal pro-B-type natriuretic peptide; sPAP = systolic pulmonary artery pressure; TSH = thyroid stimulating hormone; TTE = transthoracic echocardiography.

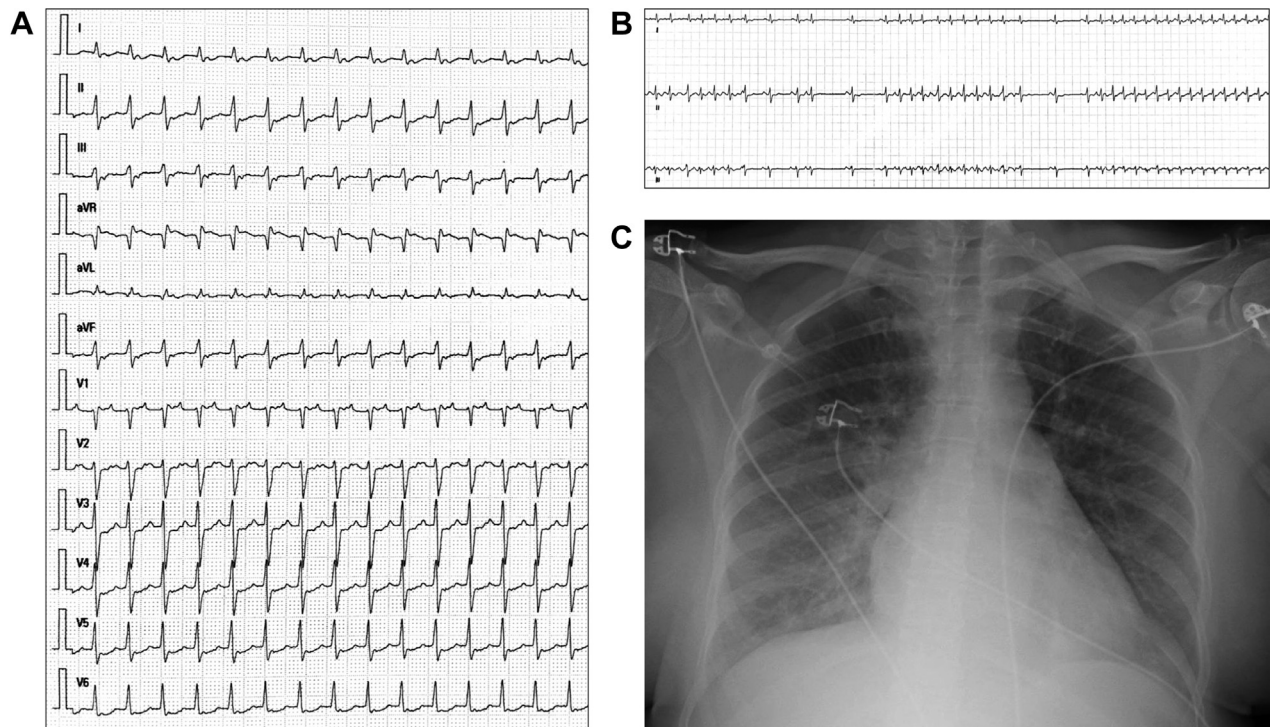
with TCM (5), incessant forms of lateral AP-related AVRT with short RP interval (RP<PR) are unusual. This may be the consequence, in these two 50-year-old patients, of a progressive change in electrophysiological characteristics occurring in the atrioventricular node or the AP over time (6). However, this spontaneous evolution occurs rather exceptionally.

Among supraventricular tachycardias, incessant form and slower ventricular rate have been shown to be associated with the development of TCM (7). Patients with rapid and paroxysmal tachycardias are indeed more symptomatic and are diagnosed earlier. In these 2 cases, both the incessant presentation as well as a delay in diagnosis led to heart failure. Diagnosis delay may derive from various reasons. Patient 1 was diagnosed with “spasmophilia” since childhood and later developed depression and anxiety disorders. Therefore, these “crisis” had always

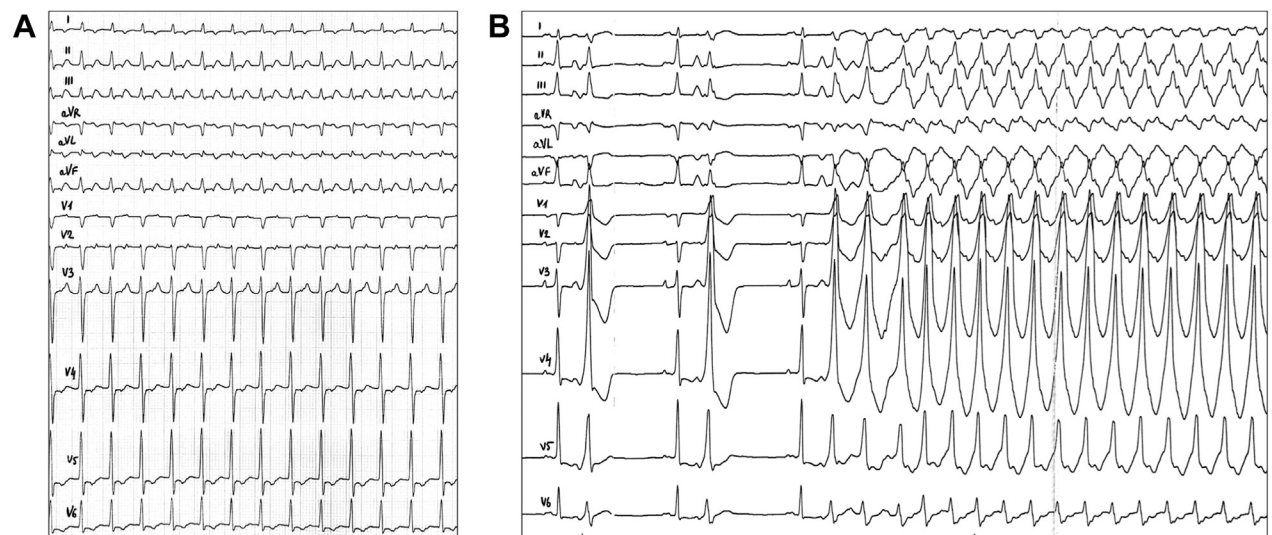
been attributed to anxiety by caregivers and the patient herself. For the first time we could correlate her symptoms with tachycardia. On the other hand, Patient 2 never experienced palpitations and was referred because of dyspnea and asthenia for a couple of months as well as abnormal liver blood test prescribed by his family doctor.

Medical antiarrhythmic treatment failed to permanently stop the arrhythmia in these patients because of incessant recurrence. Therefore, rapid catheter ablation was the only therapeutic option.

Both patients presented typical heart failure signs, initial deep LV dysfunction and signs of hepatic congestion. It is also interesting to note the rapid recovery of LV function after successful arrhythmia management contrasting with the severity of initial presentations. To confirm the diagnosis of TCM, efforts were made to exclude other potential causes of

FIGURE 1 Patient 1 Electrocardiograms and Chest Radiography

(A) Initial electrocardiogram: regular narrow QRS complex tachycardia (180 beats/min) with short RP interval (RP < PR) and RP > 90 ms. (B) Recurrent onset of the tachycardia after termination by adenosine injection. (C) Chest radiography: bilateral venous congestion and alveolar edema.

FIGURE 2 Patient 2 Electrocardiograms

(A) Initial electrocardiogram: regular narrow QRS tachycardia (170 beats/min) with short RP interval (RP < PR) and RP > 90 ms. (B) Tachycardia restarted in an antidromic form after adenosine injection. Positive V₁, negative D1-aVL, and positive inferior leads suggest a left anterolateral accessory pathway.

heart failure (2). For patient 1, noninvasive criteria, such as absence of risk factors for cardiovascular disease, normal T-troponin level, and normal LV wall motion at day 3 echocardiography, allowed us to reasonably rule out associated ischemic cardiomyopathy. Coronary angiography was normal for Patient 2. In addition, 2-dimensional echocardiographies did not reveal any valvular heart disease, LV hypertrophy, or argument for infiltrative heart disease. Blood pressure monitoring was normal during both hospitalizations. Rapid improvement of LVEF and barely dilated LV dimensions usually suggest the absence of underlying dilated cardiomyopathy (7), but a long-term follow-up is necessary to ensure the absence of early hidden cardiac disease.

This case series highlights that incessant AVRTs, like other supraventricular tachycardias, can lead to tachycardia-induced cardiomyopathy with severe

heart failure presentation. Therefore, cardiologists should always strive to document arrhythmias when at an early, paroxysmal stage with all existing means. Furthermore, mildly symptomatic patients known to experience paroxysmal AVRTs, when an ablation is not immediately considered, should be informed about a potentially rare but severe evolution and followed up closely.

FUNDING SUPPORT AND AUTHOR DISCLOSURES

All authors have reported that they have no relationships relevant to the contents of this paper to disclose.

ADDRESS FOR CORRESPONDENCE: Dr. David Hamon, Hôpital Henri Mondor, Service de Cardiologie, 51 avenue du Maréchal de Lattre de Tassigny, 94010 Créteil, France. E-mail: david.a.hamon@gmail.com.

REFERENCES

1. Huizar JF, Ellenbogen KA, Tan AY, Kaszala K. Arrhythmia-induced cardiomyopathy. *J Am Coll Cardiol* 2019;73:2328-44.
2. Brugada J, Katritsis DG, Arbelo E, et al. 2019 ESC Guidelines for the management of patients with supraventricular tachycardia: the Task Force for the management of patients with supraventricular tachycardia of the European Society of Cardiology (ESC). *Eur Heart J* 2020;41:655-720.
3. Gentlesk PJ, Sauer WH, Gerstenfeld EP, et al. Reversal of left ventricular dysfunction following ablation of atrial fibrillation. *J Cardiovasc Electrophysiol* 2007;18:9-14.
4. Medi C, Kalman JM, Haqqani H, et al. Tachycardia-mediated cardiomyopathy secondary to focal atrial tachycardia. *J Am Coll Cardiol* 2009;53:1791-7.
5. Kang KT, Potts JE, Radbill AE, et al. Permanent junctional reciprocating tachycardia in children: a multicenter experience. *Heart Rhythm* 2014;11:1426-32.
6. Li C-H, Hu Y-F, Lin Y-J, et al. The impact of age on the electrophysiological characteristics and different arrhythmia patterns in patients with Wolff-Parkinson-White Syndrome. *J Cardiovasc Electrophysiol* 2011;22:274-9.
7. Lishmanov A, Chockalingam P, Senthilkumar A, Chockalingam A. Tachycardia-induced cardiomyopathy: evaluation and therapeutic options. *Congest Heart Fail* 2010;16:122-6.

KEY WORDS accessory pathway, arrhythmia-induced cardiomyopathy, orthodromic re-entrant tachycardia, palpitation, supraventricular tachycardia, Wolff-Parkinson-White

APPENDIX For supplemental videos, please see the online version of this paper.