

# Copper deficiency-induced pancytopenia after taking an excessive amount of zinc formulation during maintenance hemodialysis

Atsushi Marumo, Takuya Yamamura, Taro Mizuki, Sakae Tanosaki, Ken Suzuki

Department of Hematology, The Fraternity Memorial Hospital, Tokyo, Japan

Erythropoiesis-stimulating agent (ESA) has been recognized as an effective way in the treatment of anemia due to chronic kidney disease, but we sometimes see intractable hemodialysis (HD) patients. The causes of ESA-resistant anemia in HD patients include deficiency of trace elements. We report the case of an 89-year-old male who developed pancytopenia after taking an excessive amount of zinc formulation for ESA-resistant anemia during maintenance dialysis. He was prescribed zinc acetate hydrate formulation about 6 months before his presentation. He was found to have pancytopenia 1 month before his presentation, at which point he was introduced to our hospital. We suspected a copper deficiency at the first visit and stopped zinc and added copper, and his condition subsequently improved without being handicapped. Zinc antagonizes copper, so we must take care to diagnose patients ingesting zinc supplements.

**Key words:** Copper deficiency, hemodialysis, pancytopenia, zinc

**How to cite this article:** Marumo A, Yamamura T, Mizuki T, Tanosaki S, Suzuki K. Copper deficiency-induced pancytopenia after taking an excessive amount of zinc formulation during maintenance hemodialysis. *J Res Med Sci* 2021;26:42.

## INTRODUCTION

Erythropoiesis-stimulating agent (ESA) has been recognized as an effective way in the treatment of anemia due to chronic kidney disease (CKD), but we sometimes see intractable hemodialysis (HD) patients.<sup>[1]</sup> The causes of ESA-resistant anemia in HD patients include iron deficiency, chronic inflammatory, appearance of anti-erythropoietin antibody, and deficiency of trace elements (copper and zinc).<sup>[2,3]</sup> HD patients easily suffer from deficiencies in magnesium, selenium, and zinc while developing excessive levels of cadmium, chromium, nickel, vanadium, copper, and lead; we must, therefore, carefully monitor these patients.<sup>[4]</sup>

The human body contains about 80 mg of copper, about 50% of which is distributed in the muscle or bone and about 10% in the liver. The amount of copper

is maintained through a balance of absorption and excretion. Copper plays a vital role as a catalytic cofactor for a variety of metalloenzymes, including superoxide dismutase (for protection against free radicals), cytochrome c oxidase (mitochondrial electron transport chain), tyrosinase (pigmentation), peptidylglycine alpha-amidating mono-oxygenase (neuropeptide and peptide hormone processing), and lysyl oxidase (collagen maturation).<sup>[5]</sup> Copper deficiency causes anemia, leukopenia, bone abnormalities, and neuropathy, among other issues. Copper is absorbed through either of two pathways: (1) through the absorption of  $\text{Cu}^{2+}$  by direct combination with divalent metal transporter 1 and competition with  $\text{Fe}^{2+}$  and  $\text{Zn}^{2+}$ ;<sup>[6,7]</sup> and (2) through the reduction of  $\text{Cu}^{1+}$  in the duodenum and subsequent absorption through combining specifically with copper transporter 1, which is present in the brush border membrane of microvilli in small intestine epithelial cells.<sup>[6-8]</sup>

### Access this article online

Quick Response Code:



Website:  
[www.jmsjournal.net](http://www.jmsjournal.net)

DOI:  
10.4103/jrms.JRMS\_25\_19

This is an open access journal, and articles are distributed under the terms of the Creative Commons Attribution-NonCommercial-ShareAlike 4.0 License, which allows others to remix, tweak, and build upon the work non-commercially, as long as appropriate credit is given and the new creations are licensed under the identical terms.

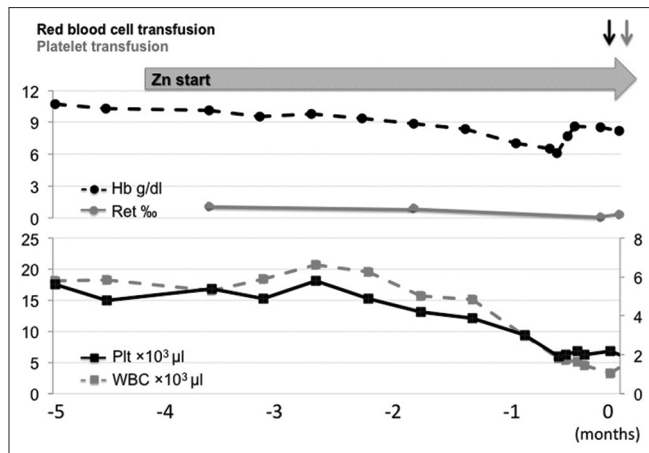
**For reprints contact:** [WKHLRPMedknow\\_reprints@wolterskluwer.com](mailto:WKHLRPMedknow_reprints@wolterskluwer.com)

**Address for correspondence:** Dr. Atsushi Marumo, Department of Hematology, The Fraternity Memorial Hospital, 2-1-11 Yokoami, Sumida-Ku, Tokyo, 130-8587, Japan. E-mail: [a.agassi2112@gmail.com](mailto:a.agassi2112@gmail.com)

**Received:** 23-Feb-2019; **Revised:** 10-Jul-2019; **Accepted:** 22-Aug-2019; **Published:** 30-Jun-2021

**Table 1. Laboratory findings**

WBC, TP, PA-IgG in this way	TP 6.7 g/dl	ng/107 cells→ng/10 <sup>7</sup> cells
(Band 6.0%, Seg 46.5%, Eosino 3.0%, Baso 2.0%, Mono 15.0%, Lympho 27.5%)	Alb 3.5 g/dl	Helicobacter pylori antibody negative
<b>RBC 2.7×10<sup>6</sup> g/dl</b>	BUN 48.1 mg/dl	Anti platelet antibody negative
<b>HB 9.6 g/dl</b>	Creat 6.41mg/dl	Vitamin B12 303 pg/ml
<b>Hct 24.5%</b>	T-bil 0.34 mg/dl	Folic acid 8.7 ng/ml
MCV 90.7 fl	AST 30 IU/L	Zn 264 µg/dl
MCH 31.2 pg	ALT 61 IU/L	<b>Cu&lt;2 µg/dl</b>
MCHC 34.4 g/dl	LDH 217 IU/L	<b>Ceruloplasmin 4 mg/dl</b>
<b>Plt 4.1×10<sup>4</sup>/µl</b>	Na 136 mEq/L	
<b>Reticulocytes 1 %</b>	K 3.6 mEq/L	
	Cl 99 mEq/L	
	CRP 0.95 mg/dl	
APTT 38.3 sec	C3 91.6 mg/dl	
PT-INR 1.0	C4 33.8 mg/dl	
<b>Fibrinogen 407 mg/dl</b>	RF<3 IU/mlW	
<b>D-D 3.9 µg/ml</b>	Antinuclear antibody negative	



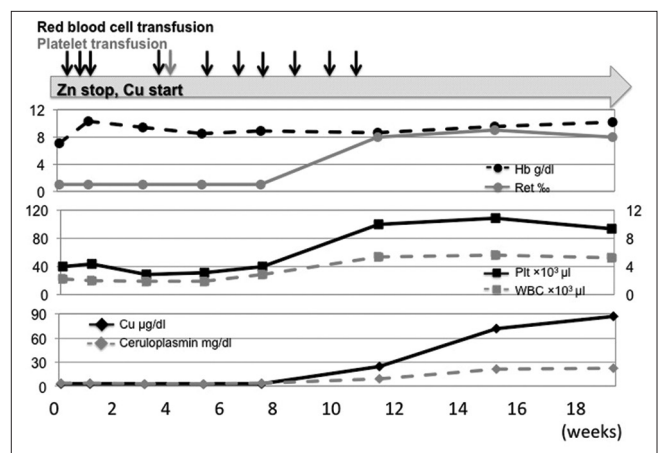
**Figure 1:** Clinical course before his presentation. Zn = Zinc; Hb = Hemoglobin; Ret = Reticulocytes; Plt = Platelets; WBC = White blood cells

We encountered a patient who developed pancytopenia after taking an excessive amount of zinc formulation for ESA-resistant anemia during maintenance dialysis. The pancytopenia improved rapidly by the administration of a copper supplement. We, herein, report this case with a discussion of the relevant literature.

**CASE REPORT**

An 89-year-old male had been receiving HD therapy for 5 years. He had ESA-resistant anemia and was prescribed zinc acetate hydrate formulation (NOBELZIN) 50 mg three times a day after meals about 6 months before his presentation. He was found to have pancytopenia 1 month before his presentation, at which point, he was introduced to our hospital [Figure 1].

He had a history of CKD, hypertension, diabetes, heart failure, arteriosclerosis obliterans, colon cancer, and abdominal aortic aneurysm with no allergies. On a physical



**Figure 2:** Clinical course after stopping Zn and starting Cu. Zn = Zinc; Cu = Copper; Hb = Hemoglobin; Ret = Reticulocytes; Plt = Platelets; WBC = White blood cells

examination, his conjunctiva was pale, but he did not have any neurologic symptoms. After consultation, we performed a blood test, and his results revealed severe pancytopenia: white blood cells 2000/µl (BAND 6.0%, SEG 46.5%, EOSINO 3.0%, BASO 2.0%, MONO 15.0%, and LYMPHO 27.5%), red blood cells 2.70 × 10<sup>6</sup>/µl, hemoglobin (Hb) 9.6 g/dl, MCV 90.7 fl, and platelets (Plt) 41 × 10<sup>3</sup>/µl. There were no blast cells or atypical cells in a peripheral blood smear. Vitamin B12, folic acid, and antinuclear antibody levels were normal, and he requested not to undergo bone marrow aspiration. We suspected him of having a copper deficiency due to taking zinc acetate hydrate formulation, and indeed, his blood test revealed zinc excess and copper deficiency (Zn 264 µg/dl [normal range: 65–110 µg/dl], Cu <2 µg/dl [normal range: 68–128 µg/dl], ceruloplasmin 4 mg/dl [normal range: 21–37 mg/dl]) [Table 1]. Upper gastrointestinal endoscopy revealed no abnormalities.

We stopped the zinc acetate hydrate formulation and added copper orally. We also performed red blood cell transfusion and platelet transfusion to maintain his Hb level >8.0 mg/dl and Plt level >10–20 × 10<sup>3</sup>/μl. His copper serum and ceruloplasmin levels recovered within 2 months, and his pancytopenia improved [Figure 2].

## DISCUSSION

Copper-deficiency anemia is a relatively rare disease, but central venous nutrition, inflammatory bowel disease, gastrectomy, celiac disease, and excessive zinc ingestion sometimes cause copper-deficiency anemia according to several case reports.<sup>[9]</sup> Zinc is an essential trace element that plays important roles in taste, wound healing, and immunity. Previous reports have shown that zinc deficiency increases the risk of dengue fever.<sup>[10]</sup> We should take care to avoid excessive zinc ingestion.

Anemia and leukopenia often occur due to copper deficiency, but 10% of copper deficiency patients present with thrombocytopenia.<sup>[11]</sup> It is difficult to distinguish between copper-deficiency anemia and myelodysplastic anemia because copper-deficiency anemia is characterized by dysplasia, such as the presence of ring sideroblasts.<sup>[11]</sup> Its treatment is copper supplementation, and copper-deficiency anemia recovers within 4–12 weeks after the addition of copper.<sup>[12]</sup> One study showed that 93% of hematological abnormalities were completely improved with copper supplementation, but only 25% of neurological symptoms were improved.<sup>[8]</sup> The median time to the diagnosis of copper-deficiency anemia from the initial presentation with either neurology or hematology is 1.1 years, ranging from 10 weeks to 23 years in several reviews; this suggests that efforts to diagnose copper deficiency earlier should be made.<sup>[11]</sup>

The present patient had pancytopenia and was suspected of having a hematological disease, so he was introduced to our hospital. We suspected a copper deficiency at the first visit and started our treatment, and his condition subsequently improved without being handicapped. Zinc antagonizes copper, so we must take care to diagnose patients ingesting zinc supplements.

## Declaration of patient consent

The authors certify that they have obtained all appropriate patient consent forms. In the form the patient (s) has/have given his/her/their consent for his/her/their images and other clinical information to be reported in the journal. The patients understand that their names and initials will not be published and due efforts will be made to conceal their identity, but anonymity cannot be guaranteed.

## Financial support and sponsorship

Nil.

## Conflicts of interest

There are no conflicts of interest.

## REFERENCES

1. Drüeke T. Hyporesponsiveness to recombinant human erythropoietin. *Nephrol Dial Transplant* 2001;16 Suppl 7:25-8.
2. Tsubakihara Y, Nishi S, Akiba T, Hirakata H, Iseki K, Kubota M, *et al.* 2008 Japanese society for dialysis therapy: Guidelines for renal anemia in chronic kidney disease. *Ther Apher Dial* 2010;14:240-75.
3. Kadoya H, Uchida A, Kashihara N. A case of copper deficiency-induced pancytopenia with maintenance hemodialysis outpatient treated with polaprezinc. *Ther Apher Dial* 2016;20:422-3.
4. Tonelli M, Wiebe N, Hemmelgarn B, Klarenbach S, Field C, Manns B, *et al.* Trace elements in hemodialysis patients: A systematic review and meta-analysis. *BMC Med* 2009;7:25.
5. Balamurugan K, Schaffner W. Copper homeostasis in eukaryotes: Teetering on a tightrope. *Biochim Biophys Acta* 2006;1763:737-46.
6. Fosmire GJ. Zinc toxicity. *Am J Clin Nutr* 1990;51:225-7.
7. Arredondo M, Muñoz P, Mura CV, Nùñez MT. DMT1, a physiologically relevant apical cu1+transporter of intestinal cells. *Am J Physiol Cell Physiol* 2003;284:C1525-30.
8. Cobine PA, Pierrel F, Winge DR. Copper trafficking to the mitochondrion and assembly of copper metalloenzymes. *Biochim Biophys Acta* 2006;1763:759-72.
9. Williams DM. Copper deficiency in humans. *Semin Hematol* 1983;20:118-28.
10. Rerksuppaphol S, Rerksuppaphol L. A randomized controlled trial of zinc supplementation as adjuvant therapy for dengue viral infection in Thai children. *Int J Prev Med* 2018;9:88.
11. Halfdanarson TR, Kumar N, Li CY, Phyllyk RL, Hogan WJ. Hematological manifestations of copper deficiency: A retrospective review. *Eur J Haematol* 2008;80:523-31.
12. Gabreyes AA, Abbasi HN, Forbes KP, McQuaker G, Duncan A, Morrison I. Hypocupremia associated cytopenia and myelopathy: A national retrospective review. *Eur J Haematol* 2013;90:1-9.