



Contents lists available at ScienceDirect

International Journal of Surgery Case Reports

journal homepage: www.casereports.com

Single-site multiport combined splenectomy and cholecystectomy with conventional laparoscopic instruments: Case series and review of literature

Ibrahim Ali Ozemir^{a,*}, Baris Bayraktar^a, Onur Bayraktar^b, Salih Tosun^a, Cagri Bilgic^a, Gokhan Demiral^a, Erman Ozturk^c, Rafet Yigitbasi^a, Orhan Alimoglu^a

^a Istanbul Medeniyet University, Faculty of Medicine, Goztepe Education and Research Hospital, Department of General Surgery, Istanbul, Turkey

^b Acibadem University, Faculty of Medicine, Department of General Surgery, Istanbul, Turkey

^c Istanbul Medeniyet University, Göztepe Education and Research Hospital, Department of Hematology, Istanbul, Turkey

ARTICLE INFO

Article history:

Received 28 October 2015

Accepted 12 December 2015

Available online 17 December 2015

Keywords:

Minimal invasive surgery

Splenectomy

Cholecystectomy

ABSTRACT

INTRODUCTION: Conventional laparoscopic procedures have been used for splenic diseases and concomitant gallbladder stones, frequently in patients with hereditary spherocytosis since 1990's. The aim of this study is to evaluate the feasibility of single-site surgery with conventional instruments in combined procedures.

PRESENTATION OF CASE SERIES: Six consecutive patients who scheduled for combined cholecystectomy and splenectomy because of hereditary spherocytosis or autoimmune hemolytic anemia were included this study. Both procedures were performed via trans-umbilical single-site multiport approach using conventional instruments. All procedures completed successfully without conversion to open surgery or conventional laparoscopic surgery. An additional trocar was required for only one patient. The mean operation time was 190 min (150–275 min). The mean blood loss was 185 ml (70–300 ml). Median post-operative hospital stay was two days. No perioperative mortality or major complications occurred in our series. Recurrent anemia, hernia formation or wound infection was not observed during the follow-up period.

DISCUSSION: Nowadays, publications are arising about laparoscopic or single site surgery for combined diseases. Surgery for combined diseases has some difficulties owing to the placement of organs and position of the patient during laparoscopic surgery. Single site laparoscopic surgery has been proposed to have better cosmetic outcome, less postoperative pain, greater patient satisfaction and faster recovery compared to standard laparoscopy.

CONCLUSION: We consider that single-site multiport laparoscopic approach for combined splenectomy and cholecystectomy is a safe and feasible technique, after gaining enough experience on single site surgery.

© 2015 The Authors. Published by Elsevier Ltd. on behalf of IJS Publishing Group Ltd. This is an open access article under the CC BY-NC-ND license (<http://creativecommons.org/licenses/by-nc-nd/4.0/>).

1. Introduction

Since 1990s, conventional laparoscopic procedures have been used for splenic diseases and concomitant gallbladder stones, frequently in patients with hereditary spherocytosis. After the evolution of single-incision laparoscopic surgery (SILS), cholecystectomy became one of the most commonly described SILS procedures [1,2]. More recently, successful splenectomies by SILS

technique have also been reported in both adult and pediatric patients [3,4].

Single site laparoscopic surgery promises to be a thriving alternative to conventional laparoscopy by providing better cosmetic outcome, less postoperative pain, patient satisfaction and faster recovery [4]. SILS has more benefits especially in combined procedures, which may increase the additional trocar requirement and extension of the incision. Combine diseases have some difficulties regarding to intra-abdominal placements of organs and position of the patient during laparoscopic surgery. Popularity of SILS has led to develop novel instruments to facilitate single-site procedures, which may offer advantages, but are not absolutely necessary due to the higher costs [5–8].

Abbreviation: SILS, single-incision laparoscopic surgery.

* Corresponding author at: Küçüksu Mah., Asma Sok., Eston Kandilli Evleri Sitesi, A/12 Blok, D:8, Üsküdar, İstanbul, Turkey. Fax: +90 216 3297224.

E-mail address: draliozemir@hotmail.com (I.A. Ozemir).

<http://dx.doi.org/10.1016/j.ijscr.2015.12.018>

2210-2612/© 2015 The Authors. Published by Elsevier Ltd. on behalf of IJS Publishing Group Ltd. This is an open access article under the CC BY-NC-ND license (<http://creativecommons.org/licenses/by-nc-nd/4.0/>).

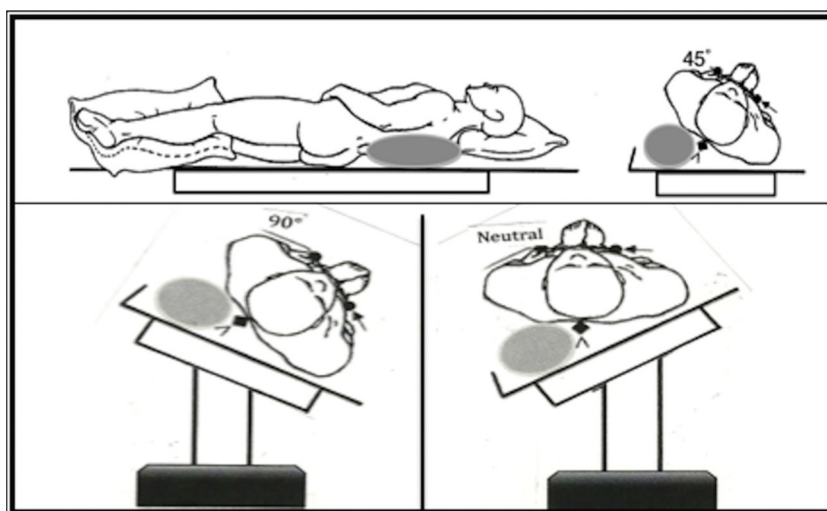


Fig. 1. (a) Initial position of the patient (left side of the patient elevated on a gel cushion about 45°). (b) Position for splenectomy ensured by turning the table to the right side. (c) Position for cholecystectomy ensured by turning the table to the left side.

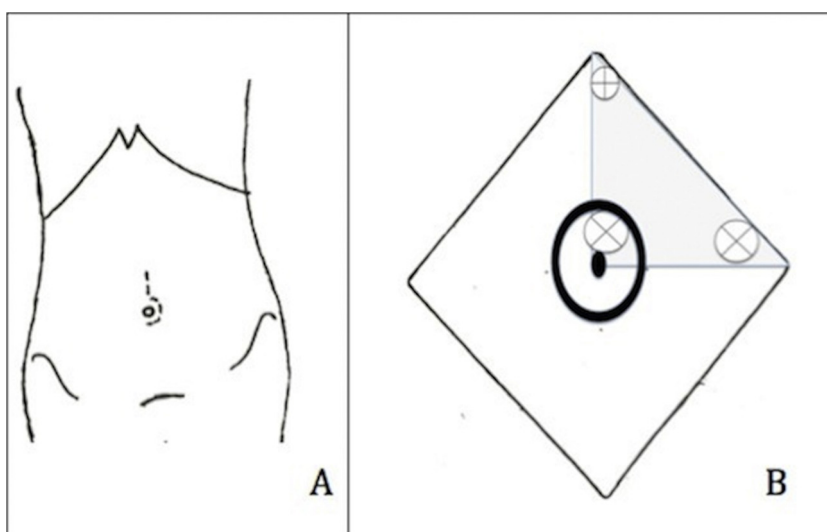


Fig. 2. (a) Shape of the incision. (b) Skin flap and detached fat tissue area (colored gray) and trocar placements (⊗: 10 mm trocar, ⊕: 5 mm trocar).

We aimed to evaluate the feasibility of single-site surgery with conventional instruments at patients who were scheduled for combined splenectomy and cholecystectomy.

2. Materials and methods

2.1. Patient selection

Single-site laparoscopic combined splenectomy and cholecystectomy with conventional instruments were performed on 6 patients between September 2012 and December 2013. All patients were preoperatively assessed by abdominal ultrasonography, spleen scintigraphy and computerized tomography for accessory spleens. The diagnosis was hereditary spherocytosis in five patients and autoimmune hemolytic anemia in one. All patients were combined with cholelithiasis. The mean age was 44 years (range, 28–65 years), and the mean body mass index was 29 (range, 24–37). There were one male and five females. Pneumococcus (Pneumovax 23, Merck & Co., Inc., Whitehouse Station, NJ, USA) and Haemophilus influenzae type B (Hiberix, GlaxoSmithKline) vaccines were administered two weeks before the operations.

2.2. Operative technique

All procedures were performed by two attending surgeons. For the operation, patients were placed on right decubitus position with the left flank elevated 45° on a gel cushion (Fig. 1a). Operation table was tilted to the right site completely to obtain 80–90° right lateral decubitus position (Fig. 1b).

A left periumbilical semilunar skin incision was performed on the left side of the umbilicus (Fig. 2a). Then a skin flap about 4 × 2 cm in diameter was created under the upper and left side of the umbilicus by detaching subcutaneous fat tissue (Fig. 3a). Pneumoperitoneum was established to 12 mmHg via Veress needle. Subsequently, 10 mm trocar was introduced at the superior border of the umbilicus. One more 10 mm trocar was introduced at 2 cm lateral to the former. Finally, a 5 mm trocar was inserted 3 cm superior to the umbilicus on the midline (Figs. 2 b and 3 a,b). Through this trocar placement, instruments are redirected to the relevant organ from created working triangle, unlike using classic SILS port. Also it reduces the possibility of clashing between the hands and instruments of surgeon and assistant. The splenocolic ligament was dissected to liberate the lower pole of spleen.

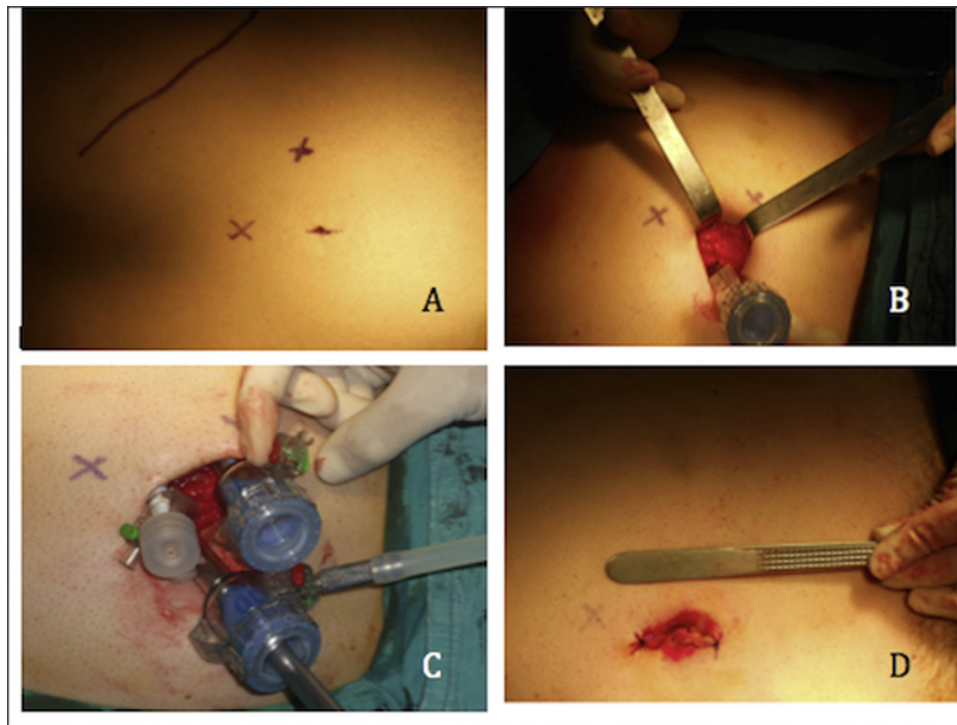


Fig. 3. (a) Trocar placements, (b) skin flap, (c) trocar positions during operation, (d) wound appearance after the operation.

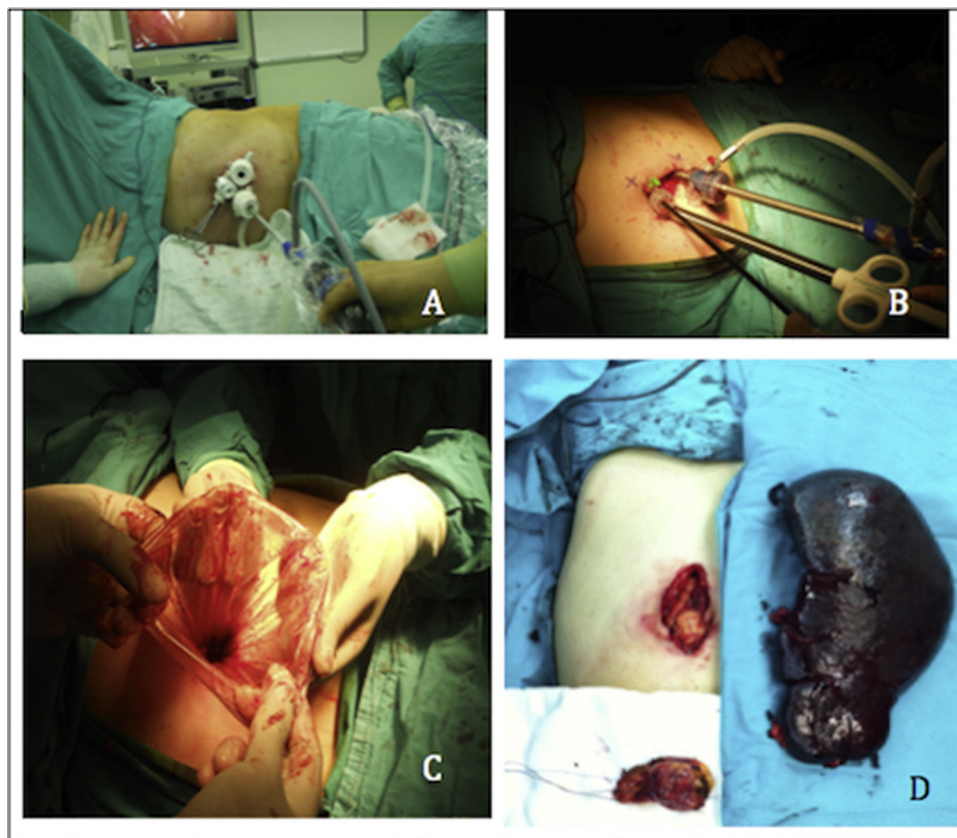


Fig. 4. (a) Normal scope position during operation, (b) placement of retrieval bag, (c) morcellation, (d) patient with giant spleen. Incision was extended because the spleen did not fit in the retrieval bag.

Table 1
Preoperative, perioperative and postoperative data of the patients.

Age/sex	BMI	HD	Operative time (min)	Blood loss (ml)	Operation notes	Follow-up (month)	Complication
34/F	29	AHA	275	300	Bleeding from the gallbladder fossa of the liver Additional trocar was required	27	–
28/F	28	HS	191	270	Bleeding due to splenic capsule rupture from the lower pole of the spleen	25	–
40/F	25	HS	164	120	–	20	–
36/F	24	HS	150	70	–	17	–
61/F	37	HS	185	250	Venous back-flow bleeding from ligated splenic hilum	15	–
65/M	31	HS	175	100	Incision was extended because of the giant spleen	12	Wound hematoma

BMI: body mass index, HD: hematological disease, F: female, M: male, AHA: autoimmune hemolytic anemia, HS: hereditary spherocytosis.

Table 2
Comparison of our series with published single-incision laparoscopic combined splenectomy and cholecystectomy procedures.

Authors	SILS SP +CHO (number)	Mean operative time (min)	Operation notes
Dutta [17]	2	165	Performed with articulating instruments
Tam et al. [1,18]	5	320	1 conversion to conventional laparoscopy
Colon et al. [19]	1	216	–
Garey et al. [20]	1	116	–
Bell et al. [21]	4	167	–
Cingel et al. [12]	1	–	–
Ozemir et al.	6	190	1 additional trocar used in one patient

SILS: single-incision laparoscopic surgery, SP: splenectomy, CHO: cholecystectomy.

Then it was retracted medially to separate the lateral peritoneal and diaphragmatic attachments from the lower to upper pole of the spleen by using LigaSure® Vessel Sealing System (Valleylab, Boulder, Co., USA) and/or harmonic scalpel (Harmonic Ace, Ethicon Endo-Surgery). The superior attachments were left uncut to keep the spleen hanged up. Afterwards, spleen was hanged and retracted laterally to explore the hilum. The splenic artery and vein were dissected, ligated and transected by using LigaSure®. The ligation of the short gastric vessels and gastro-splenic ligament was performed with harmonic scalpel due to narrow plane between the stomach and spleen. After complete splenic mobilization, table tilted to the left side to provide the neutral position for cholecystectomy (Fig. 1c). An intra-corporeal suture with 2-0 polyglactin by straight needle was placed on the body of the gallbladder to retract the gallbladder on the cephalic direction to explore the Calot’s triangle. Cholecystectomy was completed with the standard dissection methods. Then scope was moved into left lateral trocar, and umbilical trocar was substituted with a 15 mm retrieval bag (Endocatch II, Covidien, Mansfield, MA) (Fig. 4a,b). The gallbladder and spleen were placed into the retrieval bag. Then, the spleen was morcellated carefully through the umbilical incision, and the retrieval bag was extracted (Fig. 4c). The skin wound was sutured and pressure dressing applied (Fig. 3d).

3. Results

Five female and one male, six patients underwent combined splenectomy and cholecystectomy with conventional instruments. Perioperative data of the patients are presented in Table 1. The mean splenic weight was 380 g (range, 300–610 g). The mean operation time was 190 min (range, 150–275 min). The mean operative blood loss was 185 ml (range, 70–300 ml). Blood loss was over the 200 ml in 3 of 6 cases. The causes of the blood loss were detected as back-flow venous bleeding from the ligated splenic hilum, splenic capsule rupture and the gallbladder fossa of the liver (Table 1). Perioperative blood transfusion required at only first patient. All procedures completed successfully without conversion to open surgery or conventional laparoscopic surgery. But one additional

trocar was required because of insufficient retraction of gallbladder at first patient. Advanced splenomegali was detected at last patient so it did not fit into retrieval bag. We extended the incision and the spleen removed as whole (Fig. 4). Subcutaneous wound hematoma developed in the same case but it resolved spontaneously within 5 days. Accessory spleen was not detected either pre-operative or intraoperative assessments. The average length of hospitalization was two (1–3) days. Recurrent anemia, hernia formation or wound infection was not observed in patients during the follow-up period (mean, 19.3 month).

4. Discussion

Minimal invasive approaches have proven themselves to be superior compared with the open surgery in many aspects. Laparoscopic surgery has become the gold standard surgical approach for diseases of spleen and gallbladder. Over the years, there has been a trend to reduce the invasiveness of laparoscopic surgery, due to the cosmetic expectations of patients. Thus, single-site laparoscopic splenectomy and cholecystectomy procedures were emerged. After the first report of Navarra et al. [2] many similar SILS studies proving feasibility of this technique were published [9–11]. Tam et al. reported their experience on single-incision laparoscopic combined cholecystectomy and splenectomy using conventional instruments in children patients [1]. This article is evaluating the feasibility of single-site multiport surgery in combined procedures with conventional instruments in adults. This method provides less scar formation, less postoperative pain and more patient satisfaction compared to classical multiport laparoscopic surgery [5].

Costs, efficacy, safety, availability of new instruments and steepness of the learning curve, are important factors to determine the acceptance of a new instruments. Classical SILS that performed with special ports contain some difficulties because all instruments move from one direction to the relevant organ [12]. Podolsky et al. [13] reported their experience with more than 100 SILS procedures. They concluded that articulating instruments reduce the operative time for SILS procedures. In contrast, Tam et al. [1] declared that

costly special instruments were not strictly required for SILS. Joshi et al. [14] reported that they used longer length telescope to solve this problem. And, Hansen et al. [15] presented that the trocars should be introduced to the abdomen at different depths, so collision of the instruments is minimized while SILS. They also proposed that using the camera and other instruments in different lengths reduce the clash of surgeon's and assistant's hands. This technique also requires excellent coordination and full cooperation between the surgeon and assistant, so all procedures performed by the same surgical team to ensure compatible operation.

Fan et al. [16] reviewed 29 studies with 105 patients undergoing SILS splenectomy. They presented that ranges of operative times and blood losses were 28–420 min and 0–350 ml, respectively. In our series, mean blood loss and mean operative time was 185 ml and 190 min, respectively. There are only few studies exits in the literature about SILS splenectomy removed concomitant with gallbladder (Table 2).

In this study, we used conventional laparoscopic instruments to perform trans-umbilical single-site multiport surgery, which made the technique cost-comparable with the conventional laparoscopy. That also eliminated the need of training curve for novel articulating or curved laparoscopic instruments. This technique also provides to introduce the instruments to the abdomen from an adequate working triangle not from a single point as classic SILS. This working triangle has reduced the possibility of the clash of instruments. Also three separate small trocar incisions on the fascia can avoid weakening of the resistance of fascia instead of a larger SILS port incision.

Actually, single-site multiport access with conventional instruments maintains the advantages of the classical laparoscopic instruments, especially in overcoming the difficulties of SILS like loss of triangulation and also collision of the instruments. Moreover, this technique is less expensive than novel single-site laparoscopic instruments.

5. Conclusion

Single-site multiport surgery is a good alternative to conventional laparoscopy, especially for combined procedures. Although articulating instruments and laparoscopes may offer advantages, they are not necessary for performing single site surgery in this technique. Despite the small number of case reports in the literature, we consider that single-site laparoscopic approach for combined splenectomy and cholecystectomy is a safe and feasible technique, after gaining enough experience on single site surgery.

Informed consent

Written informed consent was obtained from patients who participated in this study.

Conflicts of interest

Ibrahim Ali Ozemir and other co-authors declared no conflict of interest.

Funding

This is a retrospective analysis of patients, so no source did not use for funding.

Ethical approval

This study was approved by local ethic committee of Istanbul Medeniyet University.

Consent

Written informed consent was obtained from patients who participated in this study.

Authors contribution

Study concept or design I.A.O., B.B, S.T.
Data collection I.A.O., O.B., C.B., G.D., E.O.
Data analysis or interpretation IAO, B.B., R.Y., O.A.
Writing the paper I.A.O., B.B., O.B., G.D.

Guarantor

Prof. Dr Orhan Alimoglu.

Authorship declaration

All authors are in agreement with the content of the manuscript.

References

- [1] Y.H. Tam, K.H. Lee, K.W. Chan, J.D. Sihoe, S.T. Cheung, K.K. Pang, Technical report on the initial cases of single-incision laparoscopic combined cholecystectomy and splenectomy in children, using conventional instruments, *Surg. Innov.* 17 (2010) 264–268.
- [2] G. Navarra, E. Pozza, S. Occhionorelli, P. Carcoforo, I. Donini, One-wound laparoscopic cholecystectomy, *Br. J. Surg.* 234 (1997) 695.
- [3] T.A. Ponsky, J. Diluciano, W. Chwals, R. Parry, S. Boulanger, Early experience with single-port laparoscopic surgery in children, *J. Laparoendosc. Adv. Surg. Tech. A* 19 (2009) 551–553.
- [4] E.M. Targarona, M.B. Lima, C. Balague, et al., Single-port splenectomy: current update and controversies, *J. Minim. Access Surg.* 7 (2011) 61–64.
- [5] S.J. Rottman, E.R. Podolsky, E. Kim, et al., Single port access (SPA) splenectomy, *JLS* 14 (2010) 48–52.
- [6] T.E. Langwieler, T. Nimmesgern, M. Back, Single-port access in laparoscopic cholecystectomy, *Surg. Endosc.* 23 (5) (2009) 1138–1141.
- [7] A. Chow, S. Purkayastha, O. Aziz, et al., Single-incision laparoscopic surgery for cholecystectomy: an evolving technique, *Surg. Endosc.* 24 (3) (2010) 709–714.
- [8] T.H. Hong, Y.K. You, K.H. Lee, Transumbilical single-port laparoscopic cholecystectomy: scarless cholecystectomy, *Surg. Endosc.* 23 (6) (2009) 1393–1397.
- [9] P. Prashanth, P. Pradeep, B. Sonali, Single-incision laparoscopic surgery—current status and controversies, *J. Minim. Access Surg.* 7 (2011) 6–16.
- [10] M. Phillips, J. Marks, K. Roberts, et al., Intermediate results of a prospective randomized controlled trial of traditional fourport laparoscopic cholecystectomy versus single-incision laparoscopic cholecystectomy, *Surg. Endosc.* 26 (2012) 1296–1303.
- [11] E. Lai, G. Yang, C. Tang, et al., Prospective randomized comparative study of single incision laparoscopic cholecystectomy versus conventional four-port laparoscopic cholecystectomy, *Am. J. Surg.* 202 (2011) 254–258.
- [12] V. Cingel, L. Zabojsnikova, P. Kurucova, I. Varga, First experience with single incision laparoscopic surgery in Slovakia: concomitant cholecystectomy and splenectomy in an 11-year-old girl with hereditary spherocytosis, *Biomed. Pap. Med. Fac. Univ. Palacky Olomouc Czech Repub.* (2013), <http://dx.doi.org/10.5507/bp.2013.058>.
- [13] E.R. Podolsky, P.G. Curcillo II, Single port access (SPA) surgery—a 24-month experience, *J. Gastrointest. Surg.* 14 (2010) 759–767.
- [14] M. Joshi, S. Kurhade, M.S. Peethambaram, S. Kalghatgi, M. Narsimhan, R. Ardhanari, Single-incision laparoscopic splenectomy, *J. Min. Access Surg.* 7 (2011) 65–67.
- [15] E.N. Hansen, O.J. Muensterer, Single-incision laparoscopic splenectomy in a 5-year-old with hereditary spherocytosis, *JLS* 14 (2010) 286–288.
- [16] Y. Fan, S.D. Wu, J. Kong, Y. Su, Y. Tian, H. Yu, Feasibility and safety of single-incision laparoscopic splenectomy: a systematic review, *J. Surg. Res.* 186 (2014) 354–362.
- [17] S. Dutta, Early experience with single incision laparoscopic surgery: eliminating the scar from abdominal operations, *J. Pediatr. Surg.* 44 (2009) 1741–1745.

- [18] Y.H. Tam, K.H. Lee, J.D. Sihoe, K.W. Chan, S.T. Cheung, K.K. Pang, Initial experience in children using conventional laparoscopic instruments in single-incision laparoscopic surgery, *J. Pediatr. Surg.* 45 (12) (2010) 2381–2385.
- [19] M.J. Colon, D. Telem, E. Chan, P. Midulla, C. Divino, E.H. Chin, Laparoendoscopic single site (LESS) splenectomy with a conventional laparoscope and instruments, *JSL* 15 (3) (2011) 384–386.
- [20] C.L. Garey, C.A. Laituri, D.J. Ostlie, C.L. Snyder, W.S. Andrews, G.W.S. Holcomb, S.D. Peter St., Single-incision laparoscopic surgery in children: initial single-center experience, *J. Pediatr. Surg.* 46 (5) (2011) 904–907.
- [21] R. Bell, T. Boswell, T. Hui, W. Su, Single-incision laparoscopic splenectomy in children, *J. Pediatr. Surg.* 47 (5) (2012) 898–903.

Open Access

This article is published Open Access at scimedirect.com. It is distributed under the [IJSCR Supplemental terms and conditions](#), which permits unrestricted non commercial use, distribution, and reproduction in any medium, provided the original authors and source are credited.