

Ultrasound guidance of uncommon nerve blocks

Ahmed Thallaj

Department of Anesthesia,
College of Medicine,
King Saud University, Riyadh, KSA

Address for correspondence:

Dr. Ahmed Thallaj,
Department of Anesthesia, College
of Medicine, King Saud University,
Riyadh, Kingdom of Saudi Arabia.
E-mail: athallaj@ksu.edu.sa

ABSTRACT

In the past nerve stimulation was considered the standard tool for anesthesiologists to locate the peripheral nerve for nerve blocks. However, with the recent introduction of ultrasound (US) technology for regional anesthesia, the use of nerve stimulation has become a rarity nowadays. There is a growing interest by most anesthesiologists in using US for nerve blocks because of its simplicity and accuracy. US is now available in most hospitals practicing regional anesthesia and is a popular tool for performance of nerve blocks. Although nerve stimulation became a rarity, however the use of it is now limited to identify small nerve structures, such as greater auricular nerve and medial antebrachial cutaneous nerve of the forearm. However, in this review article we discuss the role of ultrasonography for greater auricular and antebrachial cutaneous nerve blocks, which could replace nerve stimulation technique. We look at the available literature on the role of US for the performance of uncommon nerve blocks and its benefits.

Key words: *Greater auricular nerve, medial antebrachial nerve, small nerves, ultrasound*

INTRODUCTION

In recent years, ultrasound (US) has been used to localize nerves and guide needles toward a target nerve under real-time guidance. US machines with broad band high resolution probes has led to better isolation of small peripheral nerves, including ilio-inguinal/ilio-hypogastric and sural nerves visually from the surrounding structures.^[1-3] In this review, we describe the sono-anatomy and US-guided blockade technique of two uncommon nerve blocks, namely, the greater auricular nerve (GAN) and the medial antebrachial cutaneous nerve of the forearm (MACN). GAN block is useful for surgery involving the outer ear, area over the mastoid, and the mandibular angle.^[4-6] MACN block can be used as a sole anesthetic technique for superficial surgery involving the medial side of the forearm or to supplement patchy brachial plexus anesthesia, which is associated with patient discomfort and unnecessary conversion to general anesthesia.^[7,8] These blocks when properly conducted are very effective and safe.

GAN ANATOMY

GAN is the largest sensory branch of the cervical plexus. It arises mainly from the third cervical nerve (C3) with irregular contribution from C2. The first part of its course is deep to the sterno-cleidomastoid muscle (SCM). It then winds around the posterior border of SCM to reach the lateral surface of the muscle. Prior to bifurcation into anterior and posterior branches the nerve ascends almost vertically toward the auricle. With the exception of the concha and tragus of the auricle, the GAN provides sensory innervations for both surfaces of the external ear in varying extension, the skin over the mastoid process, small areas behind and above the auricle, and most of the skin covering the parotid gland.^[9,10]

US-GUIDED GAN SCANNING AND BLOCK TECHNIQUE

With subjects in supine position and head turned 45 degrees to the contralateral side, 6-13 MHz probe is placed on the skin in a transverse plane above the SCM at the level of the cricoids cartilage. After initial placement, the US probe has to be adjusted in a slightly oblique manner for clear identification of the GAN course [Figure 1]. We identify the GAN deep to the posterior border of the SCM, on axial view which appears as a solitary, hypoechoic rounded bobble-shaped structure with hyperechoic border deep to the posterior border of the SCM with a diameter of

Access this article online	
Quick Response Code:	Website: www.saudija.org
	DOI: 10.4103/1658-354X.87269

1.68±0.2mm.^[11] When moving the US probe cephalad, the GAN winds around the lateral border of SCM to become anteriorly, at this site a 22G 50-mm cannula with a facet tip introduced parallel to the long axis of the US probe (in plane technique) and 2 mL bupivacaine 0.5% is injected [Figures 2 and 3].

MACN ANATOMY

MACN of the forearm arises from the medial cord of the brachial plexus with fibers from the 8th cervical and 1st thoracic roots. Initially it is located medial to the axillary artery and gives off, near the axilla, a ramus that pierces the fascia and supplies the skin over the biceps brachii muscle, almost as far as the elbow. The nerve descends to the ulnar side of the arm, where it is located ulnar to the brachial artery, pierces the brachial fascia with the basilic vein at the basilic hiatus. Leaving the hiatus the MACN is often already divided into anterior (volar) and posterior (ulnar) branches. The anterior branch is adjacent to the

anterior (or occasionally posterior) circumference of the median cubital vein, and descends on the front of the ulnar side of the forearm. The posterior branch descends obliquely on the medial aspect of the basilic vein to the back of the forearm. Skin supply of the distal branches of the MACN includes the ulnar aspect of the forearm down to the wrist.^[12,13]

US-GUIDED MACN SCANNING AND BLOCK TECHNIQUE

With the subject in supine position, the arm is 90 degrees abducted and externally rotated. We use 6-13 MHz linear US probe to scan the medial aspect of the arm. The US probe is adjusted over the skin perpendicular to all planes. Short axis view of the mid-arm region will show the biceps brachii muscle, brachialis muscle, brachial artery, basilic vein, and median and ulnar nerves. After identifying these structures, we move the US probe proximally to view the nerve. The MACN is embedded within two fascial layers. These fascial layers together with the MACN give a characteristic “EYE” sign [Figures 4 and 5]. MACN diameter is 2.5±0.4 mm

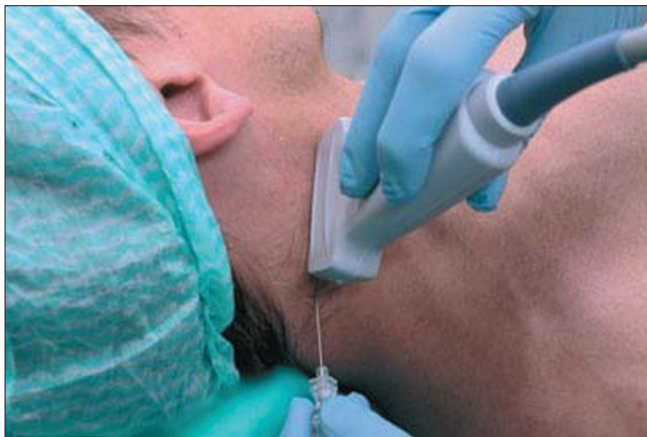

Figure 1: Ultrasound probe and needle position to scan and block the greater auricular nerve

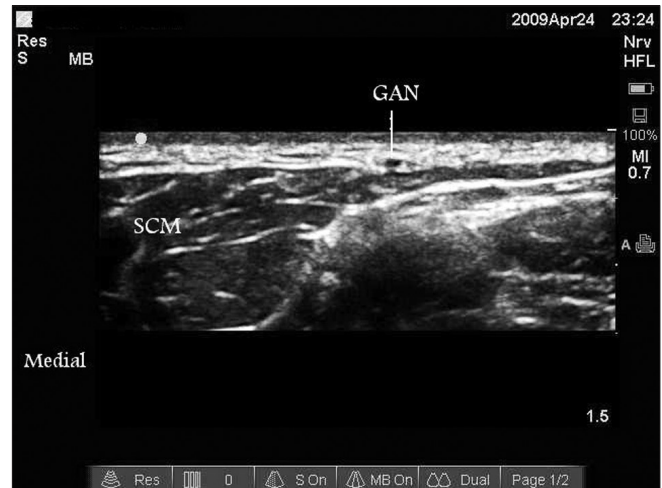


Figure 2: Sonography cross-section view at the neck. (GAN: Greater auricular nerve; SCM: Sterno-cleidomastoid muscle)

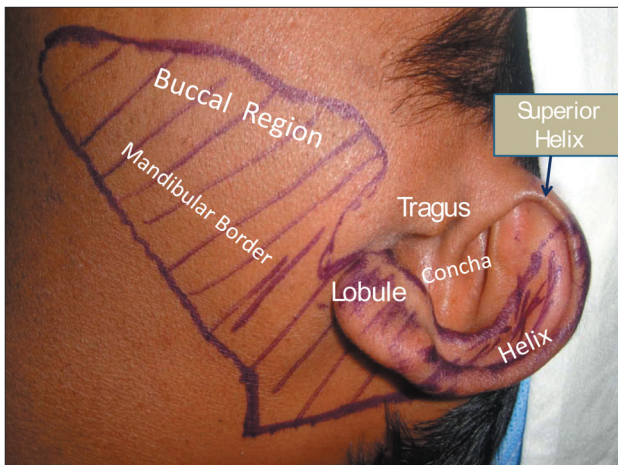


Figure 3: The blue ink map out the sensory area of the greater auricular nerve

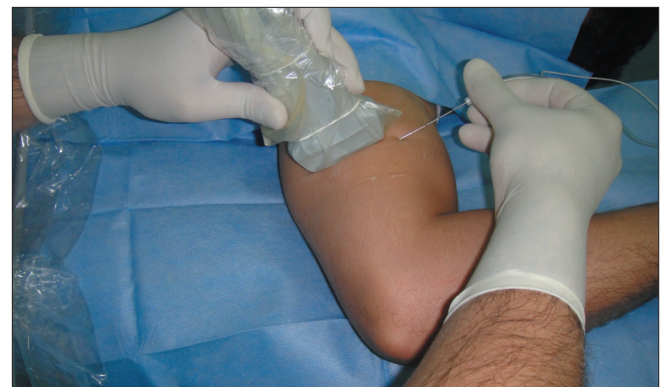

Figure 4: US probe and needle position to scan and block the medial antebrachial cutaneous nerve

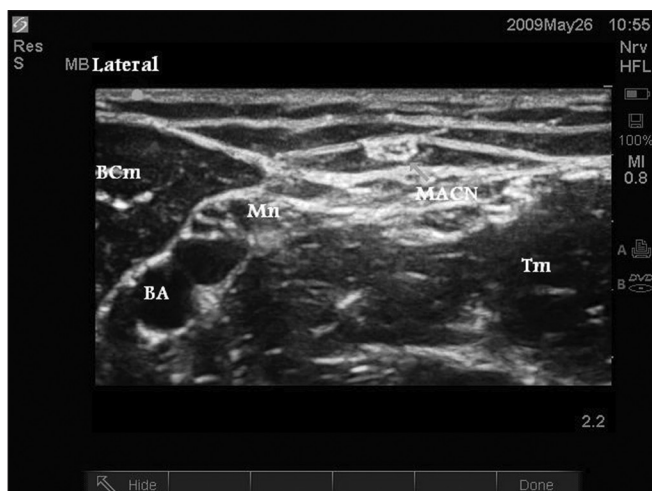

Figure 5: Sonography cross-section view at mid-arm level. MACN, medial antebrachial cutaneous nerve of the forearm; BCm, biceps muscle; Tm, triceps muscle; Br, brachial artery; Mn, median nerve

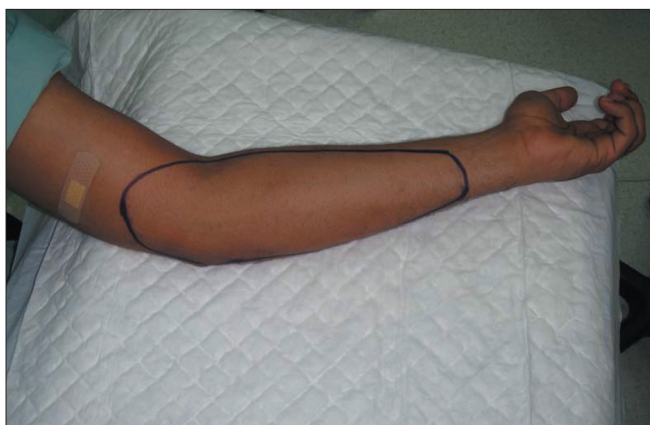

Figure 6: The blue ink map out the sensory area of the MACN

(2-3.5 mm). After skin antiseptic preparation a 22G 50 mm facet tip needle introduced in-plane from the lateral side of the US probe and 2 mL bupivacaine 0.5% is injected. Blocked areas are as follows: Distal part of the anteromedial arm, medial side of the antecubital fossa, area over the olecranon, anterior and posterior ulnar side of the forearm extended distally to 2.9 ± 0.6 cm (2-4 cm) proximal to the ulnar styloid process [Figure 6].^[14]

In conclusion, US-guided small nerves block requires technical skills and thorough understanding of sensory and motor innervations relevant to the surgical site. These blocks are safe and the concern of local anesthetic systemic

toxic reaction is negligible as the volume of local anesthetic is small.

REFERENCES

1. Willschke H, Marhofer P, Bosenberg A, Johnsten S, Wanzel O, Cox SG. Ultrasonography for ilioinguinal/iliohypogastric nerve blocks. *Brit J Anaesth* 2005;95:226-30.
2. Eichenberger U, Greher M, Kirchmair L, Curatolo M, Moriggl B. Ultrasound-guided blocks of the ilioinguinal and iliohypogastric nerve: Accuracy of a selective new technique confirmed by anatomical dissection. *Br J Anaesth* 2006;97:238-43.
3. Redborg KE, Site BD, Chinn CD, Gallagher JD, Ball PA, Antonakakis JG. Ultrasound improves the success rate of a sural nerve block at the ankle. *Reg Anesth Pain Med* 2008;34:256-60.
4. Suresh S, Barcelona SL, Young NM. Postoperative pain relief in children undergoing tympanomastoid surgery: Is a regional block better than opioids? *Anesth Analg* 2002;94:859-62.
5. Burtles R. Analgesia for 'bat ear' surgery. *Ann R Coll Surg Engl* 1989;71:332.
6. Cregg N, Conway F, Casey W. Analgesia after otoplasty: Regional nerve blockade vs local anesthetic infiltration of the ear. *Can J Anaesth* 1996;43:141-7.
7. Viscomi CM, Reese J, Rathmell JP. Medial and lateral antebrachial cutaneous nerve blocks: An easily learned regional anesthetic for forearm arteriovenous fistula surgery. *Reg Anesth Pain Med* 1996;21:2-5.
8. Lanz E, Theiss D, Jankoic D. The extent of blockade following various techniques of brachial plexus block. *Anesth Analg* 1983;62:55-8.
9. Almand J, Boydell CL, Parry SW, Izquierdo R. The greater auricular nerve revisited: Pertinent anatomy for SMAS-Platysma rhytidectomy. *Ann Plast Surg* 1990;27:44-8.
10. Peuker ET, Filler TJ. The nerve supply of the human auricle. *Clin Anat* 2002;15:35-7.
11. Thallaj A, Marhofer P, Moriggl B, Delvi BM, Kettner SC, Almajed M. Great auricular nerve blockade using high resolution ultrasound: A volunteer study. *Anaesthesia* 2010;65:836-40.
12. Neal JM. Cutaneous blocks for the upper extremity. In: Hadzic A, editor. *Modern Regional Anesthesia*. New York: McGraw Hill; 2006.
13. Masear VR, Meyer RD, Pichora DR. Surgical anatomy of medial antebrachial cutaneous nerve. *J Hand Surg* 1989;14:267-71.
14. Thallaj A, Marhofer P, Kettner SC, Al-Majed M, Al-Ahaideb A, Moriggl B. High-resolution ultrasound accurately identifies the medial antebrachial cutaneous nerve at the mid arm level: A clinical anatomic study. *Reg Anesth Pain Med* 2011;36:499-501.

How to cite this article: Thallaj A. Ultrasound guidance of uncommon nerve blocks. *Saudi J Anaesth* 2011;5:392-4.

Source of Support: Nil, **Conflict of Interest:** None declared.