



Rarity in conspicuity—Ultrasound diagnosis of sliding left inguinal hernia through canal of Nuck with uterus, fallopian tubes and ovaries

Sreekumar Muthiyal^{a,*}, Vishwanatha Kini^a, Avin Kounsai^a, Ashraf Abdelhamid Ibrahim^b

^a Dept. of Radiology, Hamad General Hospital, Doha, Qatar

^b Dept. of Paediatric Surgery, Hamad General Hospital, Doha, Qatar

ARTICLE INFO

Article history:

Received 18 December 2015

Received in revised form 18 January 2016

Accepted 20 January 2016

Available online 10 February 2016

Keywords:

Sliding inguinal hernia

Canal of Nuck

Uterus

Ovaries fallopian tube

ABSTRACT

We present a case of a one month old female infant who presented with left inguinal swelling. She was prematurely born at 32 weeks of gestational age. Preoperative ultrasound showed features of sliding indirect inguinal hernia with both ovaries, fallopian tubes and uterus; which were also evident per operatively. Patient underwent successful hernia repair and uneventful post-operative period. Patient is on follow up currently. In conclusion, we attempt to highlight the exiguous prevalence of inguinal hernia with uterus, fallopian tubes and ovaries; which has been sparsely reported in the literature and also the importance of preoperative of sonography.

© 2016 The Authors. Published by Elsevier Ltd. This is an open access article under the CC BY-NC-ND license (<http://creativecommons.org/licenses/by-nc-nd/4.0/>).

1. Introduction

Inguinal hernias are the most common causes of inguinal masses in infants, with incidence rates of 0.8–4.4%. Inguinal hernias occur, even as many as 6 times, more often in male than in female infants. Prematurity increases the incidence of inguinal hernias from 7% to 17%. Inguinal hernias are right sided in approximately 60% of cases, left sided in 30%, and bilateral in 10% [3,5]. A female infant with an inguinal hernia should be thoroughly evaluated to determine whether contents are having ovaries or not because the ovaries are at increased risk of incarceration and subsequent infarction. Ultrasonography with a high-frequency transducer is the imaging modality of choice for evaluating the inguinal lesion because it clearly has the ability to evaluate, characterize, and differentiate these conditions. [2,5]. We describe such a case to demonstrate the sonological characteristics and emphasize the relevance of knowledge about the exiguous prevalence of this condition in the premature infant; which are essential for timely detection and prompt management.

2. Case report

A 1-month-old female infant was referred to the pediatric surgery clinic for left inguinal swelling. Clinical examination showed a partially reducible, mobile mass in her left groin that appeared larger while crying or straining. There was no history of persistent irritability or vomiting. She is one of the twins; prematurely born at 31 weeks 6 days of gestational age; having low birth weight. Because an inguinal sliding hernia was suspected, sonography was performed using a high frequency (10 MHz) linear transducer. Ultrasonography exquisitely demonstrated a left inguinal hernia which contained uterus, fallopian tubes and ovaries Figs. 1 and 2. On color Doppler, there was preserved vascularity in the ovaries Fig. 3. No features of herniation of bowel loops was seen.

Patient underwent surgical exploration at 1 month of age. It confirmed the preoperative diagnosis of a sliding inguinal hernia containing a healthy-appearing uterus, fallopian tube and ovaries. The hernial contents could be easily reduced, and high ligation of the hernia sac was performed. Post-operative period was uneventful and currently she is on follow up.

3. Discussion

The processus vaginalis arises as an evagination of parietal peritoneum at around the sixth month after conception [1]. The female counterpart of the processus vaginalis is relatively small and commonly disappears by 8 months of gestation, although patency may persist into postnatal life. Failed obliteration is a cause of hydrocele

* Corresponding author at: Dept. of Radiology, Hamad General Hospital, P.O. Box 3050, Doha, Qatar.

E-mail addresses: kumardr6@hotmail.com, drkumar68@yahoo.co.in (S. Muthiyal), drmvkini@gmail.com (V. Kini), avin1587@hotmail.com (A. Kounsai), aibrahim@hamad.qa (A.A. Ibrahim).

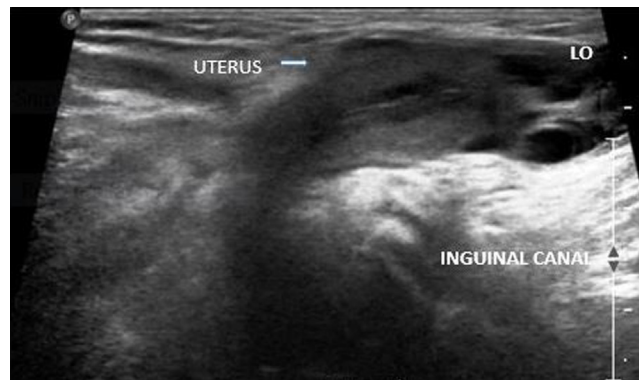


Fig. 1. Ultrasonography of the left groin reveals herniation of uterus into the inguinal canal.

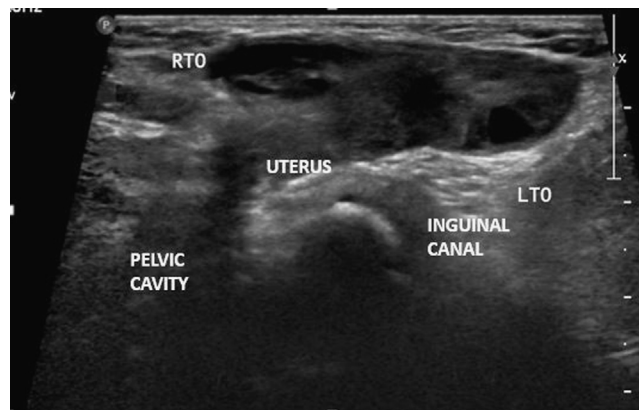


Fig. 2. Ultrasonography of the left groin reveals herniation of ovaries into the inguinal canal.

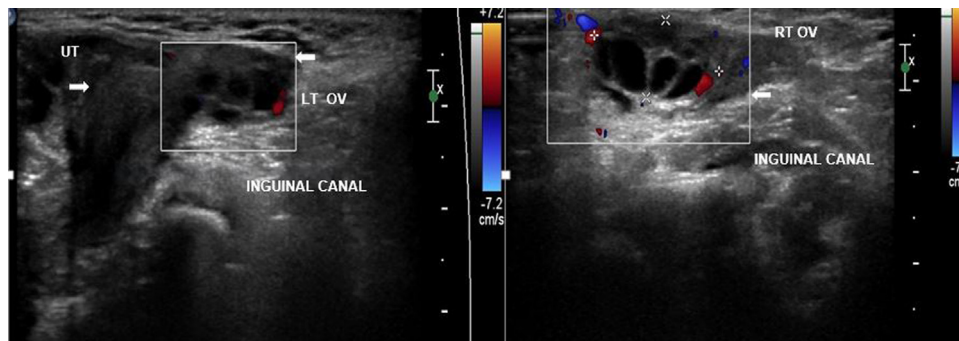


Fig. 3. On color Doppler ultrasonography vascularity is seen in both ovaries.

or hernia [1]. If patency persists, the patent processus is termed the canal of Nuck [1,3]. Because of patency of the processus vaginalis, this condition is more likely to occur in a premature infant or in the neonatal period in female infants [2]. Inguinal hernias are more common on the right side, occurring in approximately 60% of cases, with 30% on the left side, and 10% bilateral [3,5]. In our study it was on the left side.

It has been reported to contain the ovary with or without portions of the fallopian tube in 15–20% of the time [2]. However, a hernia in female infant containing the uterus is very rare [1–6].

Embryologically, there is no good explanation why the uterus should herniate in girls, unless there is an anatomic abnormality of the ligaments that suspends the uterus. One previous report offered the hypothesis that if there is failure of fusion of the Mullerian ducts leading to excessive mobility of the ovaries plus non fusion of the

uterine cornuae, the chance of herniation of the ovary and uterus into the inguinal canal is increased [1,4].

Early diagnosis is important when the hernia contains an ovary, because incarceration of the ovary is common. Incarceration of the ovary is common and has been reported in up to 43% of cases [2,3].

Bowel hernia, lymphadenopathy, hydrocele in the canal of Nuck, cystic lymphangioma, epidermal inclusion cyst, or a malignant tumor (e.g., rhabdomyosarcoma or metastasis) should be considered in the differential diagnosis of a pathologic groin mass in a female infant [2,5].

Sonography should be used as the imaging modality of choice in these patients because it clearly has the ability to evaluate, characterize, and differentiate among these conditions. Preoperative US using a high-frequency transducer is therefore very helpful in reaching a diagnosis with an efficacy considered to be almost 100% [2,4]. Color and pulsed Doppler evaluation is also complementary

to exclude strangulation. This will facilitate early effective management and avoid trivial complication like ovarian incarceration and infarction.

4. Conclusion

Inguinal hernial sac containing uterus, fallopian tube, and ovary in the female is very rare. The lesions can be diagnosed by the characteristic sonographic appearance. By presenting this case we attempt to highlight the exiguous prevalence of this clinical entity and potential of ultrasonography in early detection which will explicitly contribute to clinical decision making and further management.

Appendix A. Supplementary data

Supplementary data associated with this article can be found, in the online version, at <http://dx.doi.org/10.1016/j.ejro.2016.01.001>.

References

- [1] Y.C. Ming, C.C. Luo, H.C. Chao, S.M. Chu, Inguinal hernia containing uterus and uterine adnexa in female infants: report of two cases, *Paediatr. Neonatol.* 52 (April (2)) (2011) 103–105.
- [2] Faye C. Laing, Brent A. Townsend, J. Ruben Rodriguez, Ovary-containing hernia in a premature infant sonographic diagnosis, *J. Ultrasound Med.* 26 (2007) 985–987.
- [3] Dal Mo Yang, Hyun Cheol Kim, Sang Won Kim, Sung Jig Lim, Seung Jin Park, Joo Won Lim, Ultrasonographic diagnosis of ovary-containing hernias of the canal of Nuck, *Ultrasonography* 33 (2014) 178–183.
- [4] Kivulcim Karadeniz Cerit, Rabia Ergelen, Emel Colak, Tolga E. Dagli, Inguinal hernia containing uterus, fallopian tube and ovary in a premature new born, *J. Case Rep. Paediatr.* 2015 (2015) 3, Article ID 807309.
- [5] Hakan Artas, Nilifer Gurbuzer, Inguinal hernia containing both ovaries and the uterus in an infant, *J. Ultrasound Med.* 31 (2012) 1137–1139.
- [6] Elvira K. George, Anne Marie Oudesluys-Murphy, Gerard C. Madern, Pieter Cleyndert, Joost G.A.M. Blomjous, Inguinal hernias containing the uterus, fallopian tube, and ovary in premature female infants, *J. Pediatr.* 136 (May (5)) (2000) 696–698.