

Available online at [www.sciencedirect.com](http://www.sciencedirect.com)

ScienceDirect

journal homepage: [www.elsevier.com/locate/radcr](http://www.elsevier.com/locate/radcr)

## Case Report

# Calcified Sister Mary Joseph nodule as the presenting complaint of advanced low-grade serous ovarian cancer <sup>☆</sup>

Luhe Yang, MD, CM<sup>a</sup>, Marilyn Kinloch, MD, FRCPC<sup>b</sup>, Vickie Martin, MD, FRCPC<sup>c</sup>, Farid Rashidi, MD FRCPC<sup>a,\*</sup>

<sup>a</sup> Department of Medical Imaging, Royal University Hospital, University of Saskatchewan; Room 1566, 103 Hospital Drive, Saskatoon, SK, Canada, S7N 0W8

<sup>b</sup> Department of Pathology and Laboratory Medicine, Royal University Hospital, University of Saskatchewan, Room 2841, 103 Hospital Drive, Saskatoon, SK, Canada, S7N 0W8

<sup>c</sup> Division of Oncology, Department of Gynecology, Royal University Hospital, University of Saskatchewan, Room 4544, 103 Hospital Drive, Saskatoon, SK, Canada, S7N 0W8

## ARTICLE INFO

## Article history:

Received 13 February 2020

Revised 3 June 2020

Accepted 3 June 2020

## Keywords:

Sister Mary Joseph nodule

Umbilical mass

Serous ovarian cancer

Umbilical lymphadenopathy

Calcified umbilical mass

Metastatic cancer

## ABSTRACT

A healthy 38-year-old woman presented with a hard umbilical mass that has been growing for a few months in duration with no other significant symptoms and signs. Computed tomography images identified a lobulated densely calcified umbilical mass, left ovarian cysts, a subcentimeter calcified omental nodule, and nonspecific punctate pelvic calcifications. Histopathology of the mass revealed low-grade serous carcinoma with postsurgical diagnosis of International Federation of Gynecology and Obstetrics (FIGO) stage IV ovarian cancer. This case presentation emphasizes the importance of increased awareness of interpreting radiologists of a seemingly benign appearing imaging finding such as umbilical calcification on CT as a sign of intra-abdominal/pelvic malignancies.

Crown Copyright © 2020 Published by Elsevier Inc. on behalf of University of Washington.

This is an open access article under the CC BY-NC-ND license.

(<http://creativecommons.org/licenses/by-nc-nd/4.0/>)

## Case summary

A 38-year-old woman presented with a hard umbilical mass that has been growing for a few months in duration. Initially, this finding was not considered concerning by the patient given its painless nature and slow growth. However,

some weeks before presentation, the umbilical mass started to spontaneously secrete foul-smelling discharge, prompting the patient to seek medical attention. She was otherwise asymptomatic, and a review of systems was negative. Past medical history was negative for other medical conditions. She was on no medication with no history of drug allergies. She underwent menarche at age of 15 and denied any

<sup>☆</sup> Competing interests: The author(s) received no financial support for the research, authorship, and/or publication of this article.

\* Corresponding author.

E-mail address: [farid.rashidi@saskhealthauthority.ca](mailto:farid.rashidi@saskhealthauthority.ca) (F. Rashidi).

<https://doi.org/10.1016/j.radcr.2020.06.033>

1930-0433/Crown Copyright © 2020 Published by Elsevier Inc. on behalf of University of Washington. This is an open access article under the CC BY-NC-ND license. (<http://creativecommons.org/licenses/by-nc-nd/4.0/>)

abnormal menstrual symptoms. Her gravida para abortus status was G4 P3 A1. Surgical history included a cesarean section and dilatation and curettage and no other abdominal surgeries. Family history was significant for Hodgkin's lymphoma in her mother, and lung cancer in her maternal grandfather. Social history was positive for smoking half a pack of cigarettes per day since adulthood. She works as a salesperson with occasional heavy lifting as part of work.

Physical examination revealed a well-appearing woman. The abdominal exam showed a scaphoid abdomen with an approximately 2 cm × 3 cm superficially ulcerated, firm and flattened mass protruding through the umbilicus. The umbilical mass was oozing serous fluid. There was no evidence of hernia. The remaining physical examination, including a pelvic-rectal examination, was noncontributory.

Biochemical investigations included normal complete blood count and electrolytes. Her CA-125 level was within normal range.

---

### Imaging findings and diagnosis

The patient underwent computed tomography (CT) scan of the abdomen and pelvis which confirmed a lobulated calcified mass within the umbilicus, measuring 2.7 cm × 3 cm with no additional cystic or solid component (Figs. 1A-D). There was no intra-abdominal lymphadenopathy or aggressive appearing bony lesions. A well-defined 0.9 cm calcification was noted along the lower aspect of the greater omentum with no soft tissue component (Fig. 1E). Right and left ovaries were grossly unremarkable aside from left ovarian cysts (given limitations of CT) with the largest measuring 3.6 cm. There were punctate calcifications within and adjacent to the ovaries (Figs. 1E and F). Punctate calcifications were also noted in the pelvis, some with appearance similar to that of phleboliths. Non-specific tiny calcifications were noted in posterior cul-de-sac (Fig. 1G). Based on the imaging findings, this case was primarily reported as an omphalolith of a nonconcerning origin.

The patient initially underwent a local excision of the umbilical mass, which was found to be continuous with the umbilicus. Histopathology of the umbilical mass (Fig. 2) showed low-grade serous adenocarcinoma in the subepithelial fibrous tissue characterized by monomorphic nuclei and abundant dark purple, psammomatous calcifications, indicative of metastatic low-grade serous carcinoma of ovarian origin. This promptly led to an uncomplicated total abdominal hysterectomy and bilateral salpingo-oophorectomy for staging and adjuvant therapy planning. Intraoperative findings particularly noted small ovaries (<4 cm) with endosalpingiosis, suspicious appearing nodules in the omentum (5 mm) and bladder serosa (8 mm), and multiple (approximately 25) nodules of the rectosigmoid mesentery and proper, with some that were deeply embedded in the retro-uterine cul-de-sac. There was no evidence of peritoneal carcinomatosis. Four nodules, less than 3 mm each, could not be removed due to their intimate association with the bowel. On pathological analysis of the surgical specimens, low-grade serous carcinoma was identified in both ovaries, the bladder peritoneum, the rectal sigmoid nodule, and the uterine cul-de-sac. The majority of the tumor

within the ovaries was “stuck on” to the surface. Final pTNM staging was determined to be pT3c for macroscopic peritoneal metastasis beyond the pelvis more than 2 cm in greatest dimension, pNX since regional lymph nodes cannot be assessed, and pM1 for the presence of distant metastasis. This overall corresponded to International Federation of Gynecology and Obstetrics (FIGO) stage IV ovarian cancer.

---

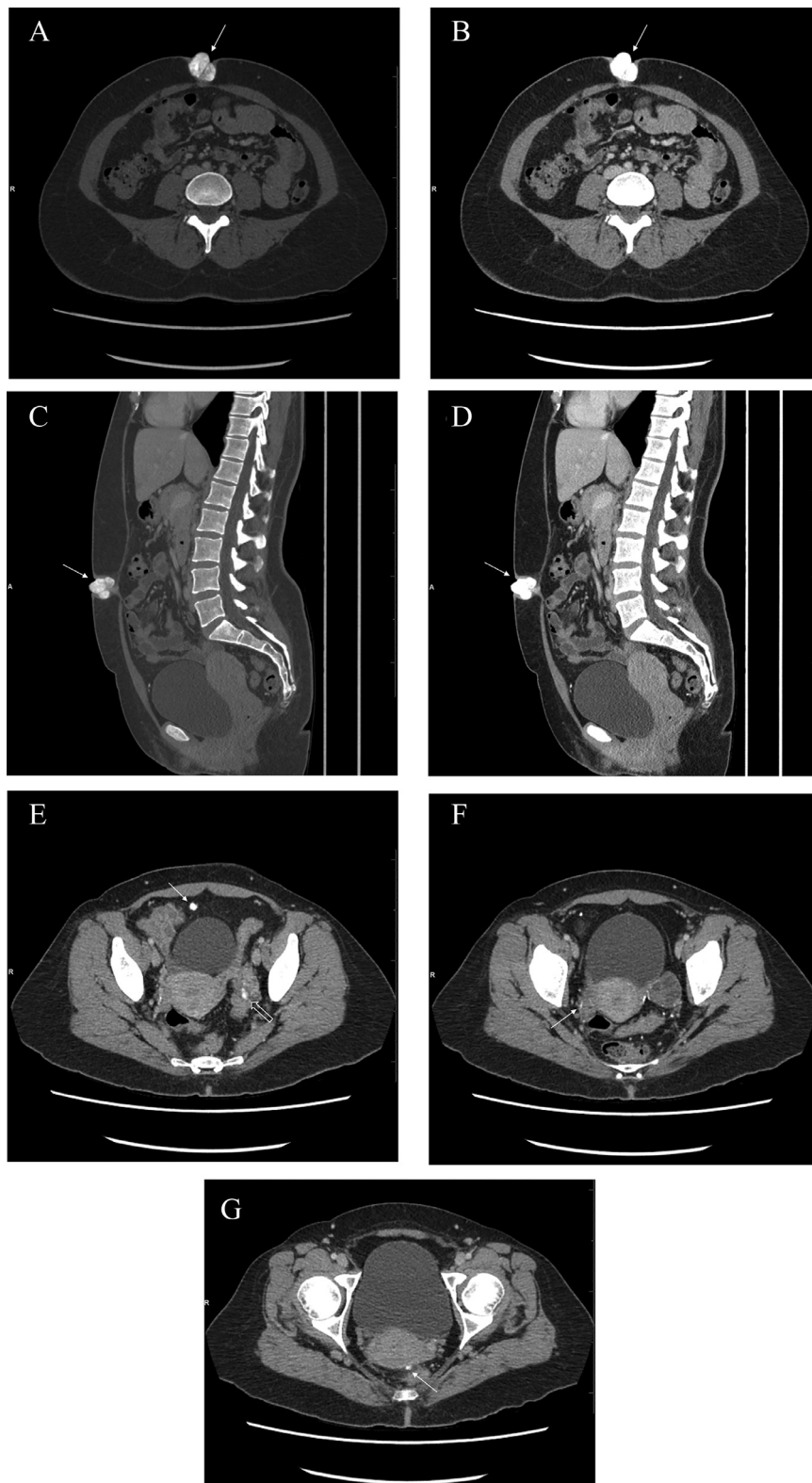
### Discussion

Umbilical masses could derive from benign and malignant etiologies. Benign umbilical nodules are called pseudo-SMJN and have been reported in nonmalignant lesions such as endometriosis, dermatofibroma, neurofibroma, papillomas, teratomas, myxoma, keloid, omphalolith, nevi, foreign body granulomas, and epidermoid cysts [1]. There has been a case report of abdominal tuberculosis with a pseudo-SMJN mimicking peritoneal carcinomatosis [2]. Previous reports have stated that approximately 60% of umbilical masses are benign, and as a result an umbilical nodule may be present for several months before the diagnosis of malignancy is established [3].

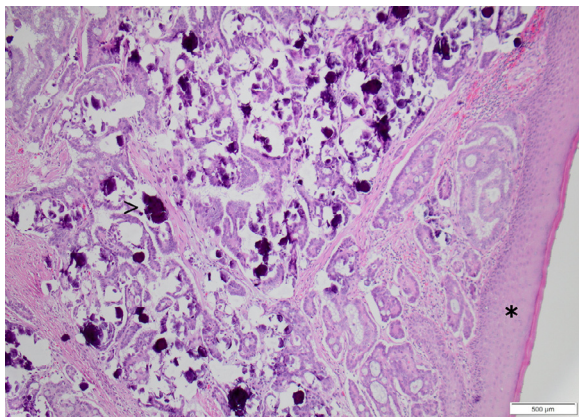
The malignant etiologies of umbilical masses have primary and secondary origins. Primary umbilical malignancies include basal cell carcinoma, melanoma, myosarcoma, as well as adenocarcinomas from embryologic remnants connected to the umbilicus, such as the omphalomesenteric duct or the urachus [4–6].

Sister Mary Joseph's nodule (SMJN) refers to secondary metastatic lesion of the umbilicus and indicates widespread intra-abdominal malignancy. SMJN is named after Sister Mary Joseph by Hamilton Bailey in 1949, she was the first person to draw attention of Dr. William Mayo to the presentation of a periumbilical nodule as a sign of an abdominal metastatic malignancy [6,7]. The mechanism of metastatic infiltration is suggested to arise from direct invasion of the peritoneum, lymphocytic or hematogenous spread, seeding from surgical/procedural intervention, or via embryonic remnants of the omphalomesenteric duct,—a structure that connects the yolk sac to the midgut lumen and becomes the Meckel's diverticulum, vitelline fistula or if persistent into adulthood, a connection between the gastrointestinal system and umbilicus [4,8]. The most common primary sites of secondary metastatic umbilical masses are the stomach (18%-28%), ovary (8%-24%), colon (10%-18%), and pancreas (7%-15%), with unknown primary in 15%-29% of cases [3,9]. Other rare etiologies for SMJN such as lymphoma [10–12], metastatic prostate cancer [13], and renal cell carcinoma [14] have also been reported. SMJN heralds advanced stages of intra-abdominal malignancy, with mean life expectancy from 2 to 11 months without treatment and only 17.6 to 21 months with aggressive treatments combining surgical excision, radiotherapy, and chemotherapy [15].

Although calcified umbilical masses in the case of serous ovarian cancer have been previously reported by authors such as Inanir and Oksuzoglu [16], and Evans et al. [17], our case differs in several important aspects. Inanir and Oksuzoglu report PET/CT images of multiple calcified paraumbilical masses in a patient with known metastatic high-grade serous adenocarcinoma postsurgical resection and undergoing chemotherapy.



**Fig. 1 – (A-G) Computed tomographic images of patient presenting with calcified Sister Mary Joseph nodule. Three-millimeter axial with sagittal reformatted images of the abdomen and pelvis were obtained after IV contrast administration in portal venous phase. Axial images in bone (A) and soft tissue (B) windows demonstrate a lobulated calcified mass within the umbilicus (arrows), measuring 2.7 × 3 cm. Sagittal reformatted images of lobulated umbilical calcified lesion (arrows) in bone (C) and soft tissue windows (D). 0.9 cm calcification in lower aspect of greater omentum (E, arrow) and punctate calcifications within and adjacent to the ovaries (E open arrow, F arrow). Punctate calcifications in posterior cul-de-sac (G, arrow).**



**Fig. 2 – Histopathology of subcutaneous low-grade serous carcinoma, H&E 10 $\times$ . Epithelium from the abdomen is indicated by the asterisk (\*). In the subepithelial fibrous tissue there is glandular adenocarcinoma characterized by monomorphic nuclei and abundant dark purple, psammomatous calcifications (arrowhead, >).**

Additionally, the masses appear to be deeper and situated at the level of the abdominal wall muscles/peritoneum and not clinically apparent. Instead of highlighting calcified umbilical masses as ancillary findings that may be found in the context of known metastatic ovarian cancer, our case features a large densely calcified umbilical mass as the initial presentation which led to the diagnosis of metastatic low-grade serous ovarian carcinoma.

Given the isolated finding of a protruding umbilical mass, although it was externally visible and clinically palpable in an otherwise healthy and asymptomatic young female, there was significant diagnostic delay which took more than 6 months from the time of mass appearance until the final diagnosis of malignancy was confirmed. This case emphasizes the importance of prompt recognition of suspicious umbilical calcifications on the initial CT workup so that undue delays in the therapeutic timeline can be prevented when the context is seemingly benign and level of clinical suspicion is low.

In comparison to the images provided by Evans et al. [17] which also featured a calcified SMJN from metastatic ovarian cystadenocarcinoma, the umbilical mass demonstrated scattered calcifications within a mass of predominantly soft tissue attenuation. Whereas the key feature of our case report—“a densely calcified umbilical “rock” as the presenting sign of low-grade serous ovarian carcinoma” has not been described in our review of the existing literature.

Given the additional calcified foci in the omentum and particularly the cul-de-sac on the CT images of this patient, which corresponded to the psammomatous calcification of the low-grade serous carcinoma on histopathology, ovarian carcinoma implants should have been considered in the differential diagnosis. Increased awareness of the interpreting radiologist and scrutinization of the CT images during interdisciplinary Gynecology-Oncology rounds retrospectively correlated the multiple punctate foci of abnormal calcifi-

cations scattered throughout the serosal surfaces of pelvic organs with intraoperative findings.

With the limitations of CT in assessment of pelvic structures, the ubiquity of nonspecific pelvic calcifications, and lack of ultrasound or PET/CT for correlation initially, it is plausible how omphalolith may have been considered as primary diagnosis at that time. Taking into consideration of biochemical markers, normal or low levels of CA-125 have been described in association with low-grade serous ovarian cancer [18]. Normal levels of CA-125, as showed in our patient, should not have dissuaded the radiologist from considering a possible malignant origin of an umbilical mass.

A densely calcified umbilical mass with no associated soft tissue component is atypical for a metastatic umbilical implant and has not been previously reported in the literature. Our patient presents a rare case of a completely calcified umbilical mass, which unfortunately has been determined to be metastatic ovarian cancer on final diagnosis. Our case highlights the importance and necessity to increase radiologists' awareness (specifically including general radiologists or radiologists working in community hospitals) in considering metastatic disease as a differential diagnosis in imaging findings of a densely calcified umbilical mass. This is crucial in avoiding delays of histological identification of the primary lesion, and in improving the outcome of our patients.

## Acknowledgements

We gratefully acknowledge our patient, our radiology department as well as gynecology-oncology and pathology departments involved in Gynecology oncology multidisciplinary rounds at our institution, without which the case report would not be possible.

## REFERENCES

- [1] Carvey MT, Beiu CV, Hage R. Case of a Sister Mary Joseph's nodule in a high grade serous carcinoma. *Cureus* 2018;10(12):e3757.
- [2] Awad A, Pampiglione T, Ullah Z. Abdominal tuberculosis with a Pseudo-Sister Mary Joseph nodule mimicking peritoneal carcinomatosis. *BMJ Case Rep* 2019;12(6):e229624.
- [3] Galvan VG. Sister Mary Joseph's Nodule. *Ann Intern Med* 1998;128(5):410.
- [4] Steck WD, Helwig EB. Tumors of the umbilicus. *Cancer* 1965;18(7):907–15.
- [5] Ross JE, Hill RB Jr. Primary umbilical adenocarcinoma. A case report and review of literature. *Arch Pathol* 1975;99(6):327–9.
- [6] Powell FC, Cooper AJ, Massa MC, Goellner JR, Su WD. Sister Mary Joseph's nodule: a clinical and histologic study. *J Am Acad Dermatol* 1984;10(4):610–15.
- [7] Bailey H. *Demonstrations of physical signs in clinical surgery*. 11th ed. Baltimore: Williams & Wilkins; 1949. 1949.
- [8] Tokai H, Matsuo S, Azuma T, Haraguchi M, Yamaguchi S, Kanematsu T. Pancreatic cancer with umbilical metastasis (Sister Mary Joseph's Nodule). *Acta Medica Nagasakiensia* 2005;50(3):123–6.
- [9] Amaro R, Goldstein JA, Cely CM, Rogers AI. Pseudo Sister Mary Joseph's nodule. *Am J Gastroenterol* 1999;94(7):1949–50.

- 
- [10] Kettani K, Chahid I. Sister Mary Joseph nodule. *Pan Afr Med J* 2019;33:228.
- [11] Vaughn JE, Gopal AK. Relapsed mantle cell lymphoma presenting as "Sister Mary Joseph Nodule". *Case Rep Med* 2010;2010:708348.
- [12] Hopton B, Wyatt J, Ambrose N. A case of Sister Mary Joseph nodule associated with primary gastric lymphoma. *Ann R Coll Surg Engl* 2005;87(5):W6.
- [13] Deb P, Rai RS, Rai R, Gupta E, Chander Y. Sister Mary Joseph nodule as the presenting sign of disseminated prostate carcinoma. *J Cancer Res Ther* 2009;5(2):127.
- [14] Chen P, Middlebrook MR, Goldman SM, Sandler CM. Sister Mary Joseph nodule from metastatic renal cell carcinoma. *J Comput Assist Tomogr* 1998;22(5):756–7.
- [15] Calongos G, Ogino M, Kinuta T, Hori M, Mori T. Sister Mary Joseph nodule as a first manifestation of a metastatic ovarian cancer. *Case Rep Obstetr Gynecol* 2016;2016:1–4.
- [16] Inanir S, Oksuzoglu K. FDG PET/CT imaging of calcified Sister Mary Joseph Nodule. *Clin Nucl Med* 2016;41(10):e458–9.
- [17] Evans JW, Dutton J, Ng C, Arends M. Calcified "Sister Mary Joseph" umbilical metastasis from ovarian cystadenocarcinoma seen on an MDP bone scintigram. *Clin Nucl Med* 2002;27(2):134–5.
- [18] Fader AN, Java J, Krivak TC, Bristow RE, Tergas AI, Bookman MA, et al. The prognostic significance of pre- and post-treatment CA-125 in grade 1 serous ovarian carcinoma: a Gynecologic Oncology Group study. *Gynecol Oncol* 2014;132(3):560–5.