

Stein's Double Cross-Lip Flaps Combined with Johanson's Step Technique for Subtotal Lower Lip Reconstruction

J. Camilo Roldán, MD, DMD,
PhD*†‡§
Wilhelm Schulte-Mattler,
MD†

Background: In a previous study, a single cross-lip flap (Abbe flap) combined with Johanson's step technique for repair of defects of more than 2/3 of the lower lip was superior, in terms of aesthetic and functional outcome, compared with Bernard Webster-related techniques (cheek advancement). Herewith, a double cross-lip flap (Stein procedure) is proposed for repair of subtotal lower lip defects. A systematic review of the Stein procedure is provided.

Methods: Two patients underwent a paramedian double cross-lip flap, preserving the aesthetic subunit philtrum column combined with the Johanson's step technique. The aesthetic and functional outcomes and the surgical steps are demonstrated in the videos. An electromyographic study was performed 6 months and 4 years after surgery. A PubMed and a Google Scholar search were performed for the Stein procedure published in 1848.

Results: Lip competence was achieved directly after sectioning of the cross-lip pedicles in both patients. Lips progressivity expanded in the first 6 months. No microstomia was observed. Electromyography showed successful reinnervation of the transplanted muscles at 6 months. Four years after surgery, the electromyographic findings were consolidated. Since 1975, 7 articles on the double cross-lip procedure have been published: 4 in English, 1 in French, and 2 in Japanese. None of those articles reported on any supplemental lower lip advancement or on any electromyographic study.

Conclusions: The rationale of using 2 cross-lip flaps and a lip-cheek advancement according to Johanson seems to achieve functionally and aesthetically superior results compared with other techniques described for subtotal lower lip reconstruction. (*Plast Reconstr Surg Glob Open* 2016;4:e615; doi: 10.1097/GOX.0000000000000555; Published online 10 February 2016.)

From the *Department of Cranio-Maxillofacial Plastic Surgery, University of Regensburg, Regensburg, Germany; †Division of Pediatric Facial Plastic Surgery and Craniofacial Anomalies, Catholic Children's Hospital Wilhelmstift, Hamburg, Germany; ‡Teaching Hospital of the University of Lübeck, Lübeck, Germany; §Adult Plastic Reconstructive and Aesthetic Surgery of the Face at Anaesthesia Center Hamburg at UKE, Hamburg, Germany; §Department of Neurology, University of Regensburg, Regensburg, Germany.
Received for publication February 13, 2015; accepted October 6, 2015.

Copyright © 2016 The Authors. Published by Wolters Kluwer Health, Inc. on behalf of The American Society of Plastic Surgeons. All rights reserved. This is an open-access article distributed under the terms of the Creative Commons Attribution-Non Commercial-No Derivatives License 4.0 (CCBY-NC-ND), where it is permissible to download and share the work provided it is properly cited. The work cannot be changed in any way or used commercially.

DOI: 10.1097/GOX.0000000000000555

THE EVOLUTION OF THE CROSS-LIP FLAP

Abbe¹ popularized the cross-lip flap after his first report on secondary bilateral cleft lip reconstruction using a pedicled median lower lip flap in 1898. This flap is based on the coronary artery of the lip, an ancient procedure that dates back more than 250 years, when the Swedish surgeon Hierzel described a lateral cross-lip flap from the lower lip based on the vermilion to reconstruct

Disclosure: The authors have no financial interest to declare in relation to the content of this article. The Article Processing Charge was paid for by the authors.

Supplemental digital content is available for this article. Clickable URL citations appear in the text.

the upper lip.² Moreover, the Italian surgeon Sabbatini reported in 1838 about a median cross-lip flap from the lower lip into the upper lip for major reconstruction combined with a forehead flap.³ Estlander,⁴ presumably without knowledge of Hierzel's lateral cross-lip flap, described in 1872 a lateral cross-lip flap from the upper lip to reconstruct the lower lip. The Abbe flap is a median or a paramedian cross-lip flap that preserves the commissure; the Estlander flap is a lateral cross-lip flap that creates a new commissure by rotating the pedicled vermilion. Both techniques are nowadays established procedures in lip reconstruction.^{5,6}

Stein⁷ from Copenhagen reported about paramedian double-cross lip flaps for a subtotal lower lip reconstruction after resection of lip cancer in 1848. The procedure is based on the preparation of 2 coronary flaps from the philtrum. This technique was forgotten over decades, until Fogh-Andersen,⁸ Fogh-Andersen and Sørensen,⁹ and Kazanjian and Roopenian¹⁰ called attention to this procedure. Kazanjian and Roopenian¹⁰ modified the original Stein procedure by preparing the cross-lip flaps on both sides of the philtrum column, preserving this aesthetic subunit, when they reported about the management of lip burn defects. Fogh-Andersen and Sørensen⁹ proposed the Stein procedure for the management of electric lip burns in children; 1 case was published in 1984 providing an encouraging result. Cannon and Murray^{11,12} of Boston gave reference to Stein–Estlander–Abbe flaps for corrective cleft surgery, providing refinements of the so-called split vermilion border lip flap. Bowers¹³ and Wexler and Dingman¹⁴ proposed again the Stein procedure preserving the philtrum (nevertheless compromising the philtrum column) for tumor cases with an involvement of 2/3 of the lip without compromise

of the commissures. Since 1975, the Stein procedure has been published 7 times: 4 of those articles are written in English,^{15–17} 1 in French,¹⁸ and 2 in Japanese^{19,20}; 1 Japanese article is not indexed in PubMed²⁰ (Table 1). The Stein procedure was also mentioned in textbooks in the 1980s as in *Plastic Surgery* (edited by McCarthy) by Zide,²¹ providing a drawing with reference to Wexler and Dingman,¹⁴ and in *Local Flaps in Facial Reconstruction* by Jackson,²² adding to the literature 1 case more as originally described by Stein, preparing flaps from the philtrum to repair a lower lip defect (Table 1).

Rationale for Double Cross-lip Flap (Stein Procedure) Combined with the Johanson's Step Technique for Subtotal Lower Lip Reconstruction

The major reconstructive surgery of the lower lip (defects >2/3 of the lip length) has been dominated after the first half of the 20th century by the Bernard Webster cheek advancement–related techniques.^{23–26} Roldán et al²⁷ reported about a poor functional and aesthetic outcome for Bernard Webster–related techniques in cases where the lip was involved more than 2/3 of the length compared with a single paramedian cross-lip flap combined with a step technique according to Johanson. Furthermore, the step technique alone was superior for the management of defects of up to 2/3 of the lip length compared with Bernard Webster–related techniques.²⁷ Advantages, as in the stretching of the remaining lower lip and the switched orbicular muscle (cross lip-flap) and in the preservation of the commissure (*modiolus*), have been keystones in maintaining the balance of the facial musculature and preservation of the regional aesthetic units of the face.²⁷

Interestingly, double cross-lip flaps have not been described combined with an advancement

Table 1. Articles that Reference a Double Cross-lip Flap from Both Sides of the Philtrum for Reconstruction of the Lower Lip from Wexler et al¹⁴ to January 2015

Authors	Language	Diagnosis	No. of Cases	Commissure Involvement	Preserve Subunit Philtrum Column	Supplementary Flaps	EMG
Spink et al ¹⁶	English	SCC	2	–	–	Fibula for <i>chin defect</i>	–
Rajaonarivelo-Gorochov et al ¹⁸	French	SCC	1	–	–	–	–
Kiyokawa et al ¹⁷	English	AVM	3	+	–	Cheek flap for <i>chin defect</i>	–
Nakayama et al ^{19*}	Japanese	SCC	2	–	+	–	–
Yoshida et al ¹⁵	English	–	–	–	–	–	–
Fogh-Andersen and Sørensen ⁹	English	Electric burn	1	–	–	–	–
Namba et al. 1976* (in the article by Fukuda ²⁰)	Japanese	SCC	2	–	+	–	–

Articles were assessed using PubMed, Google Scholar (key words: Double Cross Lip, Lip Switch Flap, Stein–Estlander–Abbe, Estlander–Abbe, Abbe–Estlander, Swing Lip Flap, Double Abbe, Stein–Abbe, Double Switch Flap, Abbe Flap), Google (for same key words in 10 pages), and supplementary search of secondary literature.

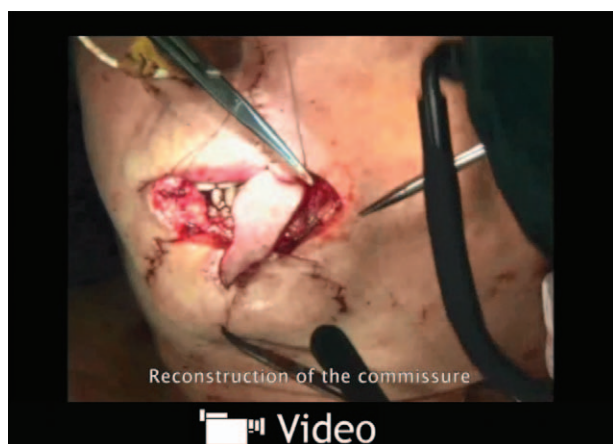EMG, electromyography; SCC, squamous cell carcinoma; AVM, Arteriovenous malformation.

*Nonindexed paper.


technique of the remaining lower lip to reduce the gap and take advantage of the lip expansibility (Table 1). Paramedian and median (Abbe flap) cross-lip flaps have not been used in cases where the commissure is involved; in those cases, an Estlander is often recommended.⁵ Furthermore, any electrophysiological analysis on paramedian or median double cross-lip flaps was unavailable in the literature; this is a critical issue, because the 2 flaps heal end to end.

The authors extended the indication of a single cross-lip flap for the management of defects $>2/3$ of the lower lip²⁷ to double paramedian cross-lip flaps (Stein procedure) for subtotal lower lip defects even with involvement of the commissure.

Herewith, the authors report about the feasibility of the mentioned extended approach step by step and about the functional, electromyographic, and aesthetic outcome based on the videos. (See Video 1, Supplemental Digital Content 1, which demonstrates a subtotal lower lip resection and reconstruction by means of Stein's double cross-lip flaps and a Johanson's *step technique*. This is available in the "Related Videos" section of the Full-Text article on PRSGlobalOpen.com or available at <http://links.lww.com/PRSGO/A165>; see Video 2, Supplemental Digital Content 2, which demonstrates a 1-year follow-up after subtotal lower lip resection and reconstruction by means of Stein's double cross-lip flaps and a Johanson's *step technique*. This is available in the "Related Videos" section of the Full-Text article on PRSGlobalOpen.com or available at <http://links.lww.com/PRSGO/A166>.)



Video 1. A subtotal lower lip resection and reconstruction by means of Stein's double cross-lip flaps and a Johanson's *step technique*. A 4-year follow-up and an electromyographic assessment are provided (case 1, Figs. 1–3), see under Refinements of the Stein Procedure for detailed description step by step. This is available in the "Related Videos" section of the Full-Text article on PRSGlobalOpen.com or available at <http://links.lww.com/PRSGO/A165>.



Video 2. A 1-year follow-up after subtotal lower lip resection and reconstruction by means of Stein's double cross-lip flaps and a Johanson's *step technique* (Case 2, Figs. 4 and 5), see under *Refinements of the Stein Procedure* for detailed description step by step. This is available in the "Related Videos" section of the Full-Text article on PRSGlobalOpen.com or available at <http://links.lww.com/PRSGO/A166>.

CASE STUDY

Two patients underwent Stein's double cross-lip flaps preserving the aesthetic subunit philtrum column combined with the Johanson's *step technique*. The procedures were performed under general anesthesia, and both patients had a primary temporary tracheotomy performed, justified in 1 case because of supplemented bilateral neck dissection and the other because of poor compliance with mental impairment.

Case 1

A 61-year-old man presented with an ulcerated carcinoma of the lower lip with a length of 7.5 cm (Fig. 1). A bilateral supraomohyoid neck dissection in the presence of enlarged lymph nodes was negative. A subtotal lower lip resection was performed preserving the right commissure and resecting the left commissure extended into the cheek. Lower lip advancement on the right side and cheek advancement on the left side were performed according to the Johanson's *step technique*²⁸ and modified according to Grimm.²⁷ Bilateral cross-lip flaps from the upper lip were performed (for the details of surgical techniques given under Surgical Procedure see Video 1, Supplemental Digital Content 1, which demonstrates a subtotal lower lip resection and reconstruction by means of Stein's double cross-lip flaps and a Johanson's *step technique*. This is available in the "Related Videos" section of the Full-Text article on PRSGlobalOpen.com or available at <http://links.lww.com/PRSGO/A165>). Lip competence was achieved directly after sectioning of the cross-lip pedicle 3 weeks after lip reconstruction. Lip function and the sensibility improved progressively in the first 12 months. No microstomia was observed. The advanced remaining lower lip and the cross-lip flaps stretched (expanded) progressively. The aesthetic units were preserved, whereas the modiolus on the left side, partially resected in the caudal area, remained spatially unchanged preserving the patient's habitual facial expression.

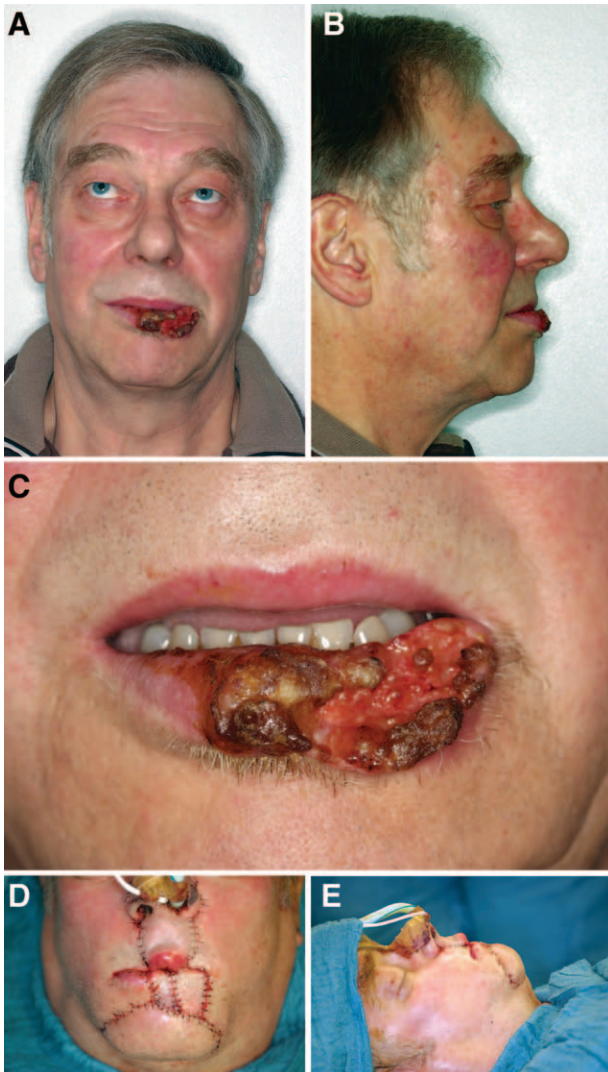

Fig. 1. Sixty-one-year-old man presented with an ulcerated carcinoma of the lower lip with involvement of the left commissure (A and C). The profile view is an important preoperative record to evaluate the postoperative result (B). Double cross-lip flap combined with the Johanson's step technique immediately after subtotal lower lip resection (D, E). The surgical procedure is presented step by step in Video 1 (Supplemental Digital Content 1, which demonstrates a subtotal lower lip resection and reconstruction by means of Stein's double cross-lip flaps and a Johanson's *step technique*. This is available in the "Related Videos" section of the Full-Text article on PRSGlobalOpen.com or available at <http://links.lww.com/PRSGO/A165> and see description under Refinements of the Stein Procedure).

Concentric needle electromyography was done 6 months and 4 years postoperatively (Fig. 2). The electromyography of the upper and lower lip on the left side and the upper lip on the right side showed slight pathological spontaneous activity (fibrillations, positive sharp waves), normal recruitment of many motor units, and motor unit action potentials (MUAPs) of normal size but with

an increased polyphasicity (Fig. 2). The lower lip on the right side showed slight pathological spontaneous activity, reduced recruitment of motor units, and MUAPs with increased polyphasicity, with some of them enlarged. The grafted lower lip did not show electrophysiological differences to the donor upper lip in the left side, and the right side showed a partial recovery; functionally no impairment was observed. The patient's functional and aesthetic satisfaction was high. Four years after surgery, the electromyographic findings were consolidated (Fig. 3).

Case 2

A 81-year-old man presented with an ulcerated *basal cell carcinoma* of the lower lip localized right sided between the vermilion border and the labiomental fold located on a childhood irradiated hemangioma (Fig. 4). The hemangioma compromised the whole lower lip, chin, and partially the right cheek. Regressive hemangioma on the cheek with a radiodermal component is clearly seen. Nearly total lower lip resection preserving both commissures was performed (Fig. 4; see the details of surgical techniques given under *Surgical Procedure*). The 1-year postoperative functional outcome is shown in Figure 5 and Video 2 (Supplemental Digital Content 2, which demonstrates a 1-year follow-up after subtotal lower lip resection and reconstruction by means of Stein's double cross-lip flaps and a Johanson's *step technique*. This is available in the "Related Videos" section of the Full-Text article on PRSGlobalOpen.com or available at <http://links.lww.com/PRSGO/A166>). The patient wore a total denture constructed before surgery; denture function was not disturbed. After surgery, no changes of the denture were needed. The patient has worn the prosthesis without any functional impairment. As in the first case, no microstomia was observed. Lip competence was achieved directly after sectioning of the cross-lip pedicles. The function improved progressively in the first year. Concentric needle electromyography of the upper lip on the right and left sides showed slight pathological spontaneous activity, normal recruitment, MUAPs with normal size but with increased polyphasicity. The right lower lip showed modest pathological spontaneous activity, reduced recruitment, and MUAPs with markedly increased polyphasicity. The electromyographic assessment of the left lower lip was refused by the patient, because he felt there was no functional deficit. The patient's functional and aesthetic satisfaction was high.

REFINEMENTS OF THE STEIN PROCEDURE

Stein's double cross-lip flaps and Johanson's *step technique* for subtotal lip reconstruction for the management of lip malignancies (Case 1, see Video 1, Supplemental Digital Content 1, which demonstrates a subtotal lower lip resection and reconstruction by means of Stein's double cross-lip flaps and a Johanson's *step technique*. This is available in the "Related Videos" section of the Full-Text article on

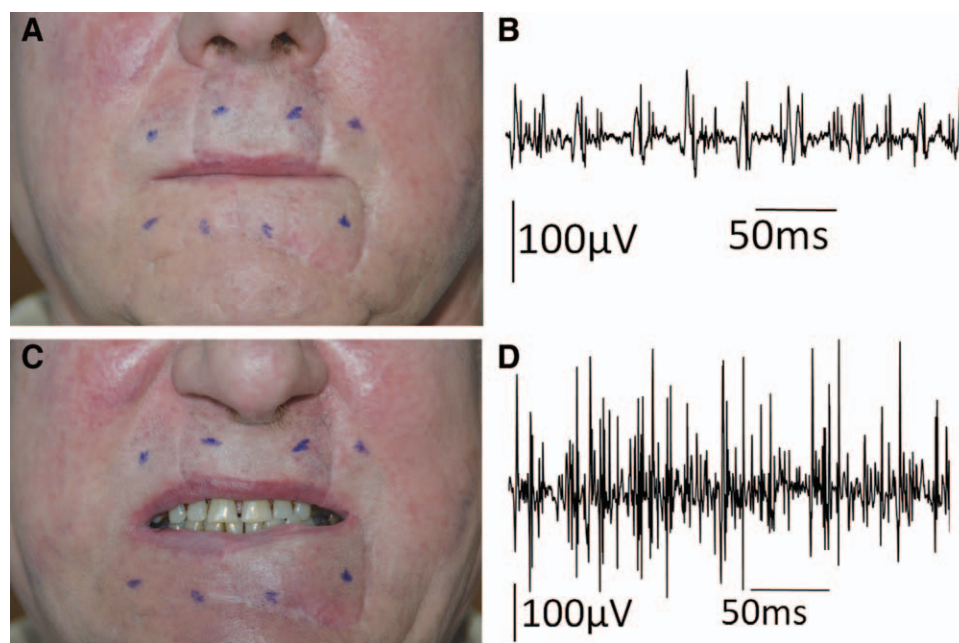


Fig. 2. Postoperative result 6 months after subtotal lower lip resection and reconstruction by means of double cross-lip flaps and a Johanson's step technique (A,C) (preoperative photographs in Fig. 1). Markings show area of placement of concentric needle electrodes for electromyographic (EMG) assessment of the upper lip as donor site and for the lower lip as receptor site. The EMG (B) shows motor unit action potentials (MUAPs) of normal size but with an increased polyphasicity and (D) normal recruitment of many motor units.

PRSGlobalOpen.com or available at <http://links.lww.com/PRSGO/A165>) are listed below:

1. *Rectangular lower lip resection* with a surgical margin of 5 mm (squamous cell carcinoma). Intraoperative frozen-section analysis is performed.²⁹
2. *Lip-cheek advancement* by means of the *step technique* according to Johanson³⁰ and modified by Johanson's group.³¹ The technique consists of a step cage skin excision above the labiomental fold preserving the underlying musculature. The subcutaneous excised skin cages (steps) allow a horizontal advancement of the remaining lip-cheek as a 45-degree W-plasty described by Borges.³² The straight step technique proposed by Johanson³⁰ is modified by a *curve step technique* as described by Grimm,²⁷ which follows the labiomental fold and extends the line of incision in major lip reconstruction into the submental area; otherwise, a *straight step* line would cross the cheek-lip fold destroying the boundary of the lower lip aesthetic unit into the cheek. The advanced lip sutured with tension stretches about 25% (tissue expansion).³¹
3. *Design of cross-lip flap:* The size of the lower lip defect after bilateral stepwise lip-cheek advancement defines the size of the cross-lip flap to be prepared to achieve a balanced and symmetric

upper and lower lip having the same length. The flap fully preserves the subunit philtrum column avoiding a flattened philtrum, which otherwise produces a bilateral (double-cleft) lip appearance. A crescentic peri-alar cheek excision³³ is included, by design, into the cross-lip flap allowing primary closure in the upper lip and providing enough tissue for the lower lip, if necessary. The coronary artery (labial artery) runs on the oral aspect of the vermilion; thus, for unrestricted flap rotation and to avoid pedicle strangulation, the cross-lip flap is extended crossing the vermilion border. To stretch the cross-flaps, they are better prepared narrower than the defect,¹² otherwise, double cross-lip flaps without tension heal as bulky flaps producing an unpleasant result.^{17,19}

In case of partial involvement of the commissure (inferior part), a paramedian cross-lip flap (Abbe flap) is preferred instead a lateral cross-lip flap (Estlander flap). A paramedian cross-lip flap preserves the midfacial muscle attachments to the modiolus (muscle risorius minor and muscle risorius major),³⁴ and a lateral cross-lip flap (Estlander) displaces the modiolus and destroys the attached midfacial musculature changing the patient's facial expression.

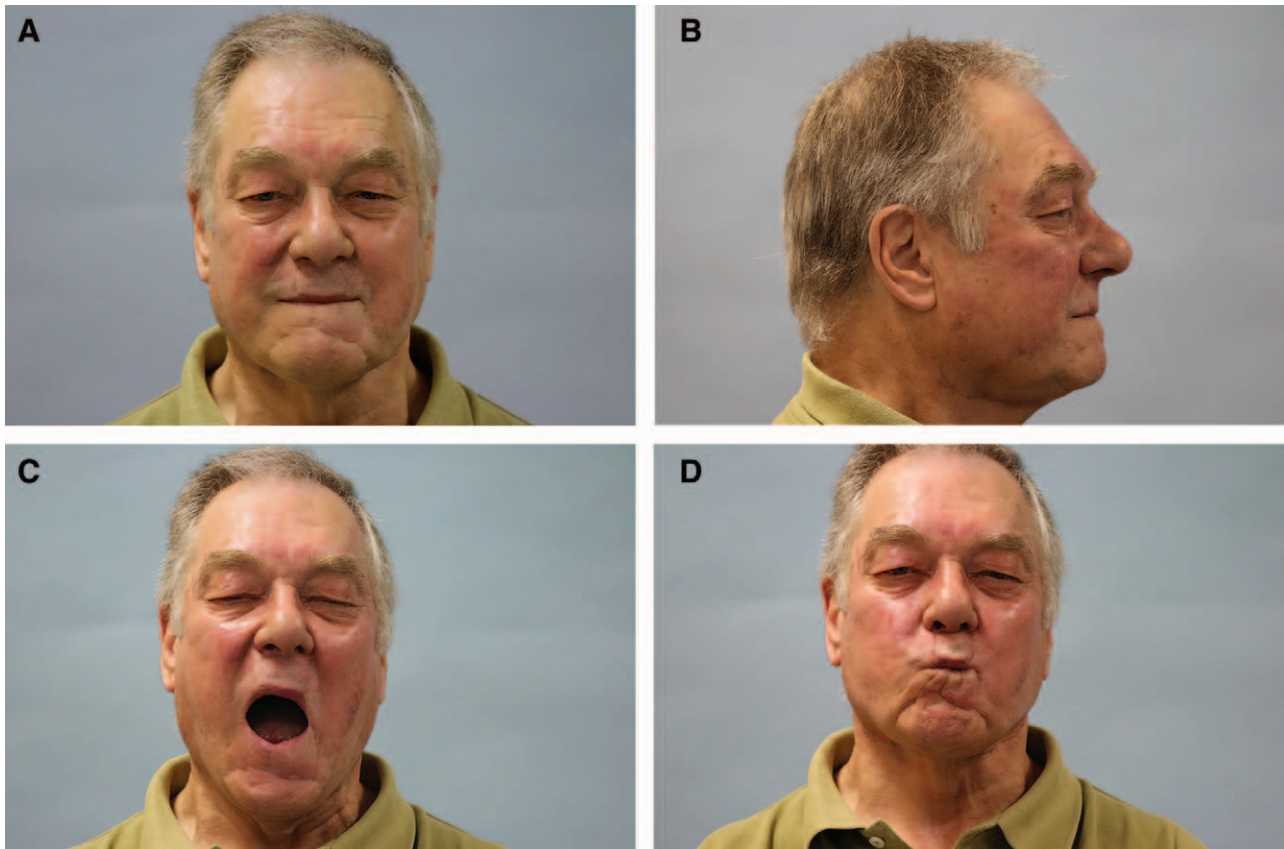

Fig. 3. Postoperative result 4 years after subtotal lower lip resection and reconstruction by means of double cross-lip flaps and a Johanson's *step technique* (preoperative photographs in Fig. 1). The mimic is almost not altered (A); upper and lower lip expansion is clearly appreciated when compared with the immediate result after surgery, whereas the upper and lower lip length is equal (Fig. 1D). The profile view (B) shows an unaltered lip high and harmonious anterior–posterior relation to the upper lip. Mouth opening is unrestricted (D). On pouting, a nearly normal muscular activity is appreciated (D).

4. *Switch the cross-lip flaps into the lower lip.* The stair-step lip and cheek advancement allows a horizontal advancement of the orbicularis oris muscle; moreover, the cross-lip flap is tailored to the rectangular defect. This allows an anatomical reconstruction of the orbicularis oral muscle without muscle distortion.²⁷
5. *Sectioning the cross-lip pedicles:* Three to four weeks after surgery, cross-lip flap pedicles are sectioned by a wedge excision into the vermilion. A gentle reopening of the vermilion is performed to reconstruct the vermilion by horizontal advancement avoiding muscle distortion.
6. *Functional outcome 1 year after surgery:* Facial expression is balanced without spatial change of the modiolus. The commissure is symmetric. Scars in the commissural area run down into the cheek–lip fold. Reconstructed orbicular muscle (upper and lower lip) stretches postoperatively. No microstomia is observed. In older patients (see Video 2, Supplemental Digital Content 2, which demonstrates an 1-year follow-up after

subtotal lower lip resection and reconstruction by means of Stein's double cross-lip flaps and a Johanson's *step technique*. This is available in the "Related Videos" section of the Full-Text article on PRSGlobalOpen.com or available at <http://links.lww.com/PRSGO/A166>), the stretched reconstructed lips have an effect as a "medial horizontal perioral lifting" refreshing the facial expression.

DISCUSSION

1. The reconstruction of a major lower lip defect with the opposite lip as "like" tissue seems to be, anatomically, the more logical way, as the opposite lip is a composite flap containing all lost structures needed as mucosa, orbicular muscle, vermilion, and skin. Furthermore, the stretching capacity of the lip is unique as demonstrated by ancient cultures in Africa and South America whose people stretch the lower lip as a beauty ideal by using lip plates.³⁵ The constitution of the cheek is not appropriate for lip reconstruction, because the stretching

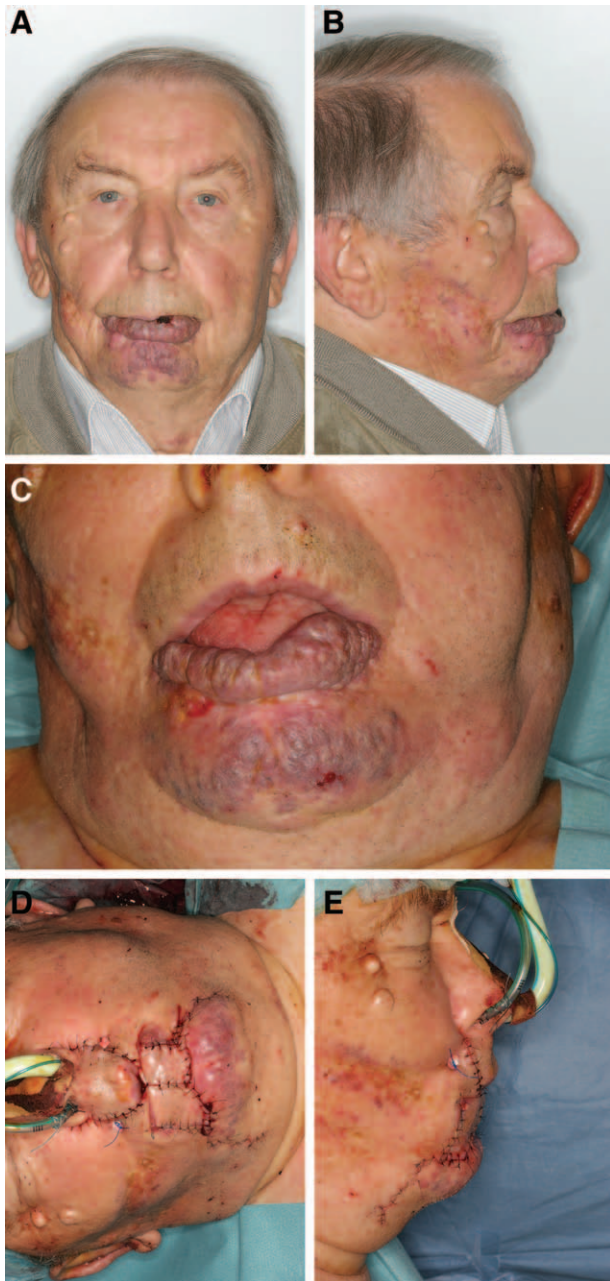


Fig. 4. Eighty-one-year-old man presented with an ulcerated *basal cell carcinoma* of the lower lip localized right sided between the vermilion border and the labiomental fold located on a childhood irradiated hemangioma (A–C). Double cross lip-flap switched into the lower lip and tailored into the rectangular defect preserving the labiomental fold (D–E).

capacity is limited. In major lower lip reconstruction by means of cheek advancement, or by using free flaps, the length of the upper lip is usually disproportionally long. The reconstruction of the lower lip with 2 flaps from the opposite lip shortens the length of the upper lip, even giving the illusion of rejuvenation; a very relaxed perioral soft tissue is “lifted” resulting in both lips with nearly equal

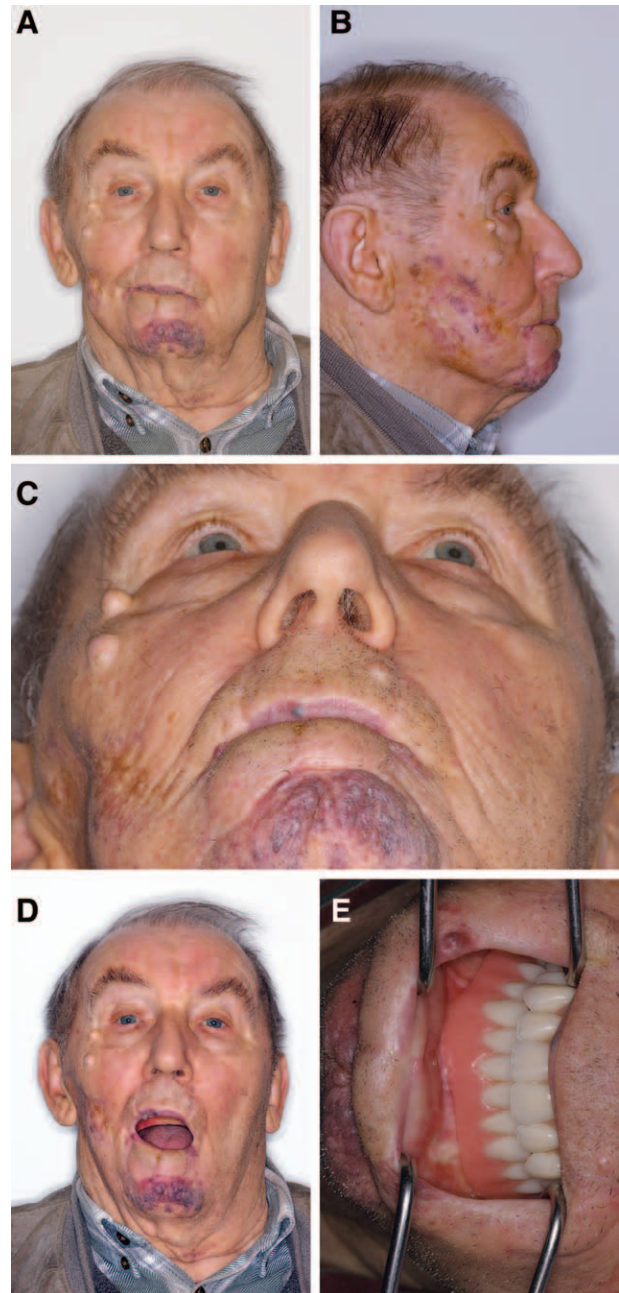


Fig. 5. Postoperative result 1 year after subtotal lower lip resection and reconstruction by means of double cross-lip flaps and a Johanson’s step technique (preoperative photographs in Fig. 4). The facial expression is unchanged (A). In profile, the lower lip high is unchanged (B). Mouth opening is unrestricted (C). The aesthetic units of the face are well preserved (the caudal view, D). Wearing of a dental prosthesis is unrestricted (E).

lengths. This also implies achievement of an equal medial advancement of the midface and lower lip muscles attached to the modiolus. The resulting effect improves on “hiding the art” to mimic a normal unaffected state.

2. Thanks to the reports by Kazanjian and Roopeian¹⁰ and Fogh-Andersen,⁸ the *Stein procedure* again gained attention. Nevertheless, and surprisingly, a systematic review on double-cross lip flaps found just 4 papers in the English literature since 1975. The literature contributions, even if limited, are very encouraging, because all the authors reported about positive results; notwithstanding, in some of those cases, a minimal microstomia was observed. It is interesting that all the double cross-lip cases published have not yet included any complementary advancement procedure of the remaining lower lip. The releasing and stepwise advancement of the remaining lip according to Johanson increases its length by stretching, producing an expansion considered up to 25% depending on the tissue laxity influenced by aging. We demonstrated earlier in our series that the *step technique* combined even with a single cross-lip flap is enough for the reconstruction of defects more than 2/3 of the lip; in this series, no microstomia was observed.²⁷ The introduction of the double cross-lip flap combined with a *step technique* according to Johanson also extends the indication to subtotal lip defects, even when the commissure is involved, or in total lip defects when the commissure is preserved. The double-cross lip flap should always be narrower than the defect to stretch it providing a constant strain dynamic, which creates real “lip-tissue” expansion. In the present series, no microstomia was observed. In the presented case where the commissure was involved in the inferior part (case 1), a cross-lip flap, instead of an Estlander flap, was favored. The rationale is to preserve the midfacial muscle group attached to the modiolus. This consideration improves the aesthetic outcome, as the facial expression remained almost unchanged compared with the disbalanced facial expression after an Estlander flap, where the mimic musculature is transected. The Estlander flap is almost not stretchable; in major lip reconstruction, a microstomia is often present.³⁶ Spink et al¹⁶ presented the extension of a paramedian double cross-lip with a fibula with skin paddle for chin reconstruction. The good result of this case underlined the importance of the reconstruction of the orbicular muscle and the preservation of the commissure. Electrophysiological studies for a single cross-lip flap showed neuromotor and sensorineural recovery in the first 6 to 12 months.³⁷ In this study, we describe the first electrophysiological assessment of a double cross-lip flap, which is a different situation because the two muscle transplants healed end to end. After 1 year, the electrophysiological result clearly showed successful reinnervation. Both patients claimed minimal functional discomfort in the first 6 months because of loss of sensibility. Twelve

months postoperatively, no functional impairment was reported. Both patients were highly satisfied with the aesthetic outcome.

CONCLUSIONS

Compared with other techniques described for subtotal lower lip reconstruction, the repair protocol reported using 2 cross-lip flaps and a lip-cheek advancement according to Johanson seems to be a superior approach both functionally and aesthetically.

Wilhelm Schulte-Mattler, MD

Department of Neurology

University of Regensburg

Universitätsstrasse 84

93053 Regensburg, Germany

E-mail: wilhelm.schulte-mattler@klinik.uni-regensburg.de

J. Camilo Roldán, MD, DMD, PhD

Department of Craniomaxillofacial Plastic Surgery

Franz-Josef-Strauss-Allee 11

93053 Regensburg, Germany

E-mail: jcamilo.roldan@yahoo.com

ACKNOWLEDGMENT

This article is dedicated to Ian T. Jackson, an extraordinary surgeon and person and a guardian of plastic surgery in progress since more than a half of a century, who always shared his knowledge and profoundly influenced generation of surgeons worldwide.

REFERENCES

1. Abbe R. A new plastic operation for the relief of deformity due to double harelip. *Plast Reconstr Surg.* 1968;42:481–483.
2. Vrebos J, Dupuis C, J. G. Hierzel: a lip-switch flap in 1756. *Plast Reconstr Surg.* 1994;93:201–204.
3. Mazzola RF, Hueston JT. A forgotten innovator in facial reconstruction: Pietro Sabattini. *Plast Reconstr Surg.* 1990;85:621–626.
4. Estlander JA. The classic Reprint: Estlander JA. A method of reconstructing loss of substance in one lip from the other lip. *Arch f Klin Chirg.* 14:622, 1872. *Plast Reconstr Surg.* 1968;42:360–365.
5. Yamauchi M, Yotsuyanagi T, Ezoe K, et al. Estlander flap combined with an extended upper lip flap technique for large defects of lower lip with oral commissure. *J Plast Reconstr Aesthet Surg.* 2009;62:997–1003.
6. Wu D, Song T, Li H, et al. An innovative cross-lip flap with a musculomucosal pedicle based on the vascular network of the lower lip. *Plast Reconstr Surg.* 2013;131:265–269.
7. Stein SA. The classic reprint: lip repair (cheiloplasty) performed by a new method, by S.A. Stein, in: *Hospitals-Meddelelser*, vol. 1, 212-6, 1848. *Plast Reconstr Surg.* 1974;53:332–337.
8. Fogh-Andersen P. Stein–Estlander–Abbe operation; a centenary in plastic surgery. *Plast Reconstr Surg (1946).* 1948;3:186–188.
9. Fogh-Andersen P, Sørensen B. Electric oral burns in Danish children with special reference to prevention. *Scand J Plast Reconstr Surg.* 1984;18:107–110.

10. Kazanjian VH, Roopenian A. The treatment of lip deformities resulting from electric burns. *Am J Surg.* 1954;88:884–890.
11. Cannon B. The split vermilion bordered lip flap. *Surg Gynecol Obstet.* 1941;73:95–97.
12. Cannon B, Murray JE. Further observations on the use of the split vermilion bordered flap. *Plast Reconstr Surg (1946).* 1953;11:497–501.
13. Bowers DG Jr. Double cross-lip flaps for lower lip reconstruction. *Plast Reconstr Surg.* 1971;47:209–214.
14. Wexler MR, Dingman RO. Reconstruction of the lower lip. *E J Plast Surg.* 1975;3:23–26.
15. Yoshida T, Sugihara T, Ohura T, et al. Double cross lip flaps for reconstruction of the lower lip. *J Dermatol.* 1993;20:351–357.
16. Spink MJ, Hirsch DL, Dierks EJ. Minimizing microstomia while maximizing esthetics in the reconstruction of acquired lip defects: the evolution of the bilateral paramedian cross-lip flap. *J Oral Maxillofac Surg.* 2008;66:2627–2632.
17. Kiyokawa K, Takagi M, Fukushima J, et al. Surgical treatment following huge arteriovenous malformation extending from the lower lip to the chin: combination of embolization, total resection, and a double cross lip flap. *J Craniofac Surg.* 2005;16:443–448.
18. Rajaonarivelo-Gorochoy N, Paraskevas A, Raulo Y, et al. [Total lower lip reconstruction with double cross-lip flaps. Case report]. *Ann Chir Plast Esthet.* 2006;51:531–535.
19. Nakayama T, Takahashi H, Yao K. Double cross lip flap for the reconstruction of lower lip in two Patients with carcinoma. *Head Neck Surg (Tokyo).* 2000;72:439–443.
20. Fukuda O. Comment on: Namba K, Horiuchi H, Tanabe M: Reconstruction of lower lip defect with double cross-lip flaps (Japanese), *Jap J Plast Reconstr Surg* 19:549, 1976. *Plast Reconstr Surg.* 1977;60:643.
21. Zide BM. Deformities of the lips and cheeks. In: McCarthy JG, ed. *Plastic Surgery.* Philadelphia: Plastic Surgery; 1990:2009–2056.
22. Jackson IT. Lip reconstruction. In: Jackson IT, ed. *Local Flaps in Head and Neck Reconstruction.* Philadelphia: C.V. Mosby; 2007:429–532.
23. Webster RC, Coffey RJ, Kelleher RE. Total and partial reconstruction of the lower lip with innervated musclebearing flaps. *Plast Reconstr Surg Transplant Bull.* 1960;25:360–371.
24. Fries R. Advantages of a basic concept in lip reconstruction after tumour resection. *J Maxillofac Surg.* 1973;1:13–18.
25. Westreich RR, Meisner JJ, Reino AA, Lawson WW. The use of combined Bernard-Webster and Karapandzic flaps for subtotal lower lip reconstruction. *Plast Reconstr Surg.* 2008;121:340e–341e.
26. Huguier V, Bertheuil N, Parry F, et al. [Post-traumatic reconstruction of the lower lip after total or subtotal amputation using the Webster's modification of the Bernard cheiloplasty—advantages, disadvantages and limitations: three cases]. *Ann Chir Plast Esthet.* 2013;58:166–174.
27. Roldán JC, Teschke M, Fritzer E, et al. Reconstruction of the lower lip: rationale to preserve the aesthetic units of the face. *Plast Reconstr Surg.* 2007;120:1231–1239.
28. Johanson B, Aspelund E, Breine U, et al. Surgical treatment of non-traumatic lower lip lesions with special reference to the step technique. A follow-up on 149 patients. *Scand J Plast Reconstr Surg.* 1974;8:232–240.
29. de Visscher JG, van den Elsaker K, Grond AJ, et al. Surgical treatment of squamous cell carcinoma of the lower lip: evaluation of long-term results and prognostic factors—a retrospective analysis of 184 patients. *J Oral Maxillofac Surg.* 1998;56:814–820; discussion 820.
30. Johanson B, Aspelund E, Breine U, et al. Surgical treatment of non-traumatic lower lip lesions with special reference to the step technique. A follow-up on 149 patients. *Scand J Plast Reconstr Surg.* 1974;8:232–240.
31. Blomgren II, Blomqvist GG, Lauritzen CC, et al. The step technique for the reconstruction of lower lip defects after cancer resection. A follow-up study of 165 cases. *Scand J Plast Reconstr Surg Hand Surg.* 1987;22:103–111.
32. Borges AF. The W-plastic versus the Z-plastic scar revision. *Plast Reconstr Surg.* 1969;44:58–62.
33. Webster JP. Crescentic peri-alar cheek excision for upper lip flap advancement with a short history of upper lip repair. *Plast Reconstr Surg (1946).* 1955;16:434–464.
34. Burget GC, Menick FJ. Aesthetic restoration of one-half the upper lip. *Plast Reconstr Surg.* 1986;78:583–593.
35. Goldstein MH. The elastic flap for lip repair. *Plast Reconstr Surg.* 1990;85:446–452.
36. Murray JF. Total reconstruction of a lower lip with bilateral estlander flaps. Case report. *Plast Reconstr Surg.* 1972;49:658–660.
37. Depalma AT, Leavitt LA, Hardy SB. Electromyography in full thickness flaps rotated between upper and lower lips. *Plast Reconstr Surg Transplant Bull.* 1958;21:448–452.