

Twelve-Year Experience With Nasofrontal Angle (Radix) Augmentation in Rhinoplasty

Ibrahim Alawadh, MD,* Ahmad Bogari, MD,† Reenad Bedaiwi, MD,‡ Hani Alanazi, MD,§ and Sameer Bafaqeeh, MD||

Abstract: The nasofrontal angle (radix) has a great impact on the rhinoplasty outcome. Minimal alterations in this area can give an unusual nasal appearance and midfacial length. Different management approaches have been described with regard to radix augmentation. This study aimed to describe the techniques of rhinoplasty, different materials used in the procedure, and results of at least 1 year of follow-up in our 12-year experience in this field. The authors retrospectively reviewed the data of patients who underwent rhino-plasty/septorhinoplasty with radix augmentation performed by 1 of the authors (a senior surgeon at our institution) using different graft materials, between January 2007 and December 2019. Patients younger than 18 years or who were followed up for less than 1 year were excluded from the study. In total, 387 patients (235 [60.7%] female; age range, 19–39 years) were included. Primary procedures were performed in 311 patients (80.5%), and revision procedures were performed in 76 patients (19.6%). Most patients (97%) were satisfied with the aesthetic result. There was no incidence of infection, displacement, or extrusion of the graft. The only complications observed were irregularities; 3% required revision surgery. It is important to consider the nasal radix when pursuing a balanced profile in rhinoplasty. Many graft materials can be used safely and can achieve good aesthetic outcomes. Proper anatomical analysis and patient selection are essential for successful graft placement.

From the *Otorhinolaryngology – Head and Neck Surgery, Ministry of Health & King Saud University; †Otorhinolaryngology – Head and Neck Surgery, Ministry of Health; ‡Otorhinolaryngology – Head and Neck Surgery, King Fahad Medical City, Ministry of Health, Riyadh; §Otorhinolaryngology – Head and Neck Surgery, College of Medicine, Majmaah University, Majmaah; and ||Otorhinolaryngology – Head and Neck Surgery, Facial Plastic Division, College of Medicine, King Saud University, Riyadh, Saudi Arabia.

Received October 7, 2021.

Accepted for publication December 14, 2021.

Address correspondence and reprint requests to Ibrahim Alawadh, MD, Otorhinolaryngology - Head and Neck Surgery, Ministry of Health & King Saud University, Riyadh 11411, Saudi Arabia; E-mail: ihalawadh@gmail.com

The authors report no conflicts of interest.

Supplemental digital contents are available for this article. Direct URL citations appear in the printed text and are provided in the HTML and PDF versions of this article on the journal's Web site (www.jcraniofacialsurgery.com).

Copyright © 2022 The Author(s). Published by Wolters Kluwer Health, Inc. on behalf of Mutaz B. Habal, MD. This is an open access article distributed under the terms of the Creative Commons Attribution-Non Commercial-No Derivatives License 4.0 (CCBY-NC-ND), where it is permissible to download and share the work provided it is properly cited. The work cannot be changed in any way or used commercially without permission from the journal.

ISSN: 1049-2275

DOI: 10.1097/SCS.00000000000008456

Key Words: Augmentation, nasofrontal angle, radix, rhinoplasty

(*J Craniofac Surg* 2022;33: 2019–2023)

The most obvious characteristic of the face is the nose, which contributes more than any other feature to its overall appearance. Rhinoplasty is a surgical method with a double function: reconstructing the shape of the nose, whereas maintaining or enhancing its airway function; thus, it is not merely a cosmetic procedure.¹ The most important first step in performing rhinoplasty is a good anatomical analysis, with more attention given to the radix area during reduction or augmentation procedures.²

The radix (nasofrontal angle) is considered the narrowest and most posterior nasal point at which the nose begins.^{3,4} It is the site at which the nasal bone fuses with the lower border of

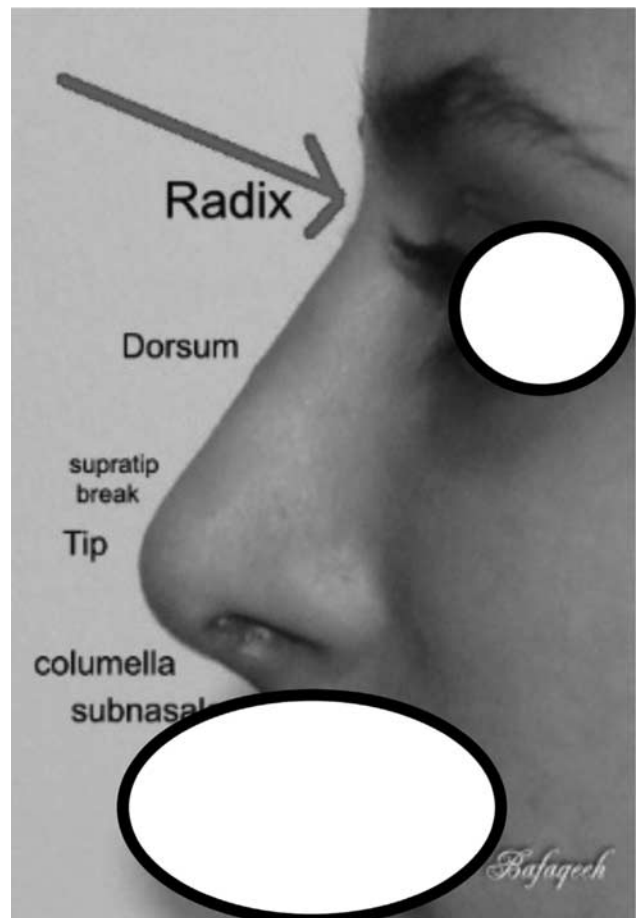


FIGURE 1. External nose anatomy showing the location of the radix.

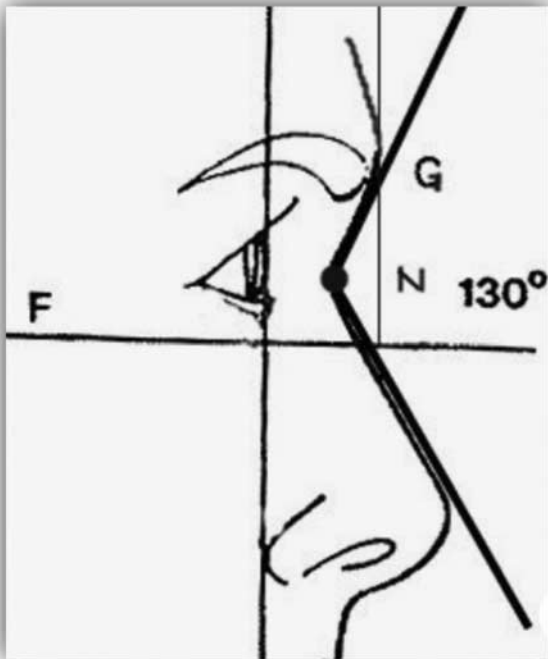


FIGURE 2. The nasofrontal angle measurement.

the frontal bone, located between the eyes³ (Fig. 1).

The nasofrontal angle follows a line from the nasal dorsum and another line from the glabella to the gnathion (Fig. 2). Visually pleasing nasofrontal angles are within 130° in men and 134° in women.⁵ Such angles combine the brow and nasal dorsum within a soft, concave curve. The top of the radix must be within the supratarsal fold and skin of the upper eyelid, when gazing horizontally.⁶

The radix is considered as a significant facial morphology determinant, as changes in this area can produce noticeable variations in the nose, particularly its length and projection.^{2,4} A low radix reduces the nose visually, generating a short nose and the delusion of a pseudohump.⁷ Conversely, in patients with a high radix, the profile of forehead continues into the nose in a straight line and the nose appears too long.²

The main techniques of radix augmentation described in the literature include the diced cartilage surgical technique, crushed cartilage grafting, autologous and synthetic grafting, and combined grafting (diced cartilage-fascia [DTF] graft).

The aim of this study was to describe the techniques of radix augmentation in rhinoplasty, different materials used in the procedure, and the results of at least 1 year of follow-up in our 12-year experience in this field.

METHODS AND MATERIALS

This is a retrospective review study conducted on patients who underwent open rhinoplasty at our institution from January 2007 to December 2019. The study participants included patients aged ≥ 19 years who underwent open septorhinoplasty with a low radix. Patients aged ≤ 19 years and those who had < 1 year of follow-up were excluded from the study. Written informed consent was obtained from all study participants.

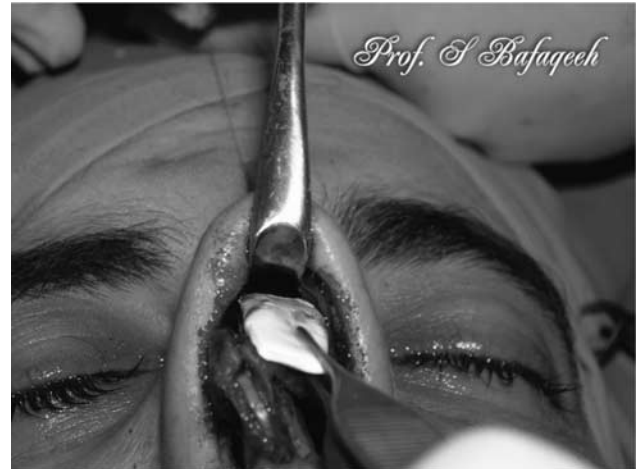

FIGURE 3. Gore-Tex grafting material; a 2- to 3-mm-thick patch was adequate for augmentation.

After obtaining clearance from the institutional ethical committee, a total of 387 medical records and professional photos of patients who had undergone rhinoplasty with radix augmentation by the senior author during the 12-year study period were reviewed. Photos were taken in frontal, profile, oblique, basal, and sky views. Moreover, we assessed the possible complications with each type of augmentation used.

Surgical Techniques

More conservative approaches were prioritized in the technique selection. We classified radix grafting as the augmentation of the defect and root of the nose above the level of the rhinion.

Various materials were used for the radix graft. Cartilage was used as the grafting material and harvested from either the cartilaginous nasal septum, auricle, or irradiated rib. Additionally, the temporalis fascia, fascia lata, and polytetrafluoroethylene (Gore-Tex) were used as grafting materials. Autologous cartilage was the first-choice material for augmentation because of its low infection rate. In cases of secondary septorhinoplasty or previous septoplasty, we used auricular cartilage as the grafting material. To smooth the transition of the radix, we used multilayer folded temporalis fascia.

After selection of the graft material, the size and shape were carefully determined to prevent overcorrection, visibility, and junctional step-offs. A No. 11 blade was used on cartilage or Gore-Tex to create a very sharply angled edge, continuing smoothly with the nasal dorsum. When using cartilage, we thinned the edges further with a scalpel and crushed the graft with a crusher to achieve a balanced contour. For cases in which Gore-Tex was used, a 2- to 3-mm-thick patch of Gore-Tex provided adequate size for augmentation (Fig. 3). Alternatively, for thick radix grafts, cartilage wrapped in temporalis fascia or fascia lata was used (Fig. 4). If the needed augmentation was minimal, we used the folded fascia lata only, with no cartilage.

For cases in which excised hump autografts were used, we resected and reshaped the excessive hump, displacing it superiorly to augment a deep nasal root.

For cases in which crushed cartilage was used, we diced the cartilage into several packed small particles (0.5–1 mm), then placed them inside the fascia. The graft was easily molded by finger pressure, providing a smooth surface. The diced cartilage was usually prepared from irradiated rib or septal or conchal

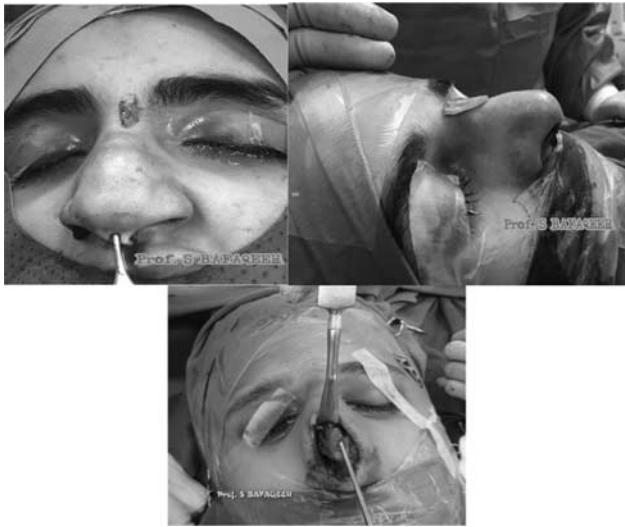

FIGURE 4. For thick radix grafts in 3 different patients, cartilage wrapped in temporalis fascia or fascia lata was used.

cartilage. In 7 patients, we soaked the diced cartilage particles in blood and wrapped them in Surgicel (Ethicon, Somerville, NJ).

For cases in which temporalis fascia grafts were used, we made a curvilinear incision in the posterior hairline and obtained complete access to the temporalis fascia by means of superior and forward dissection; we then harvested the intended amount of fascia and fixed it in the correct position within the radix using a temporary suture.

To place the graft, we used a retractor to expose the nasal bones and made a precise subperiosteal pocket exactly under the radix area with the defect to prevent dislocation (Fig. 5). The graft was positioned slightly above the desired position, and then sutured to the overlying skin to avoid activity from the procerus muscle, which tends to push it downward. We gently pulled up an absorbable 5-0 polydioxanone (PDS) suture to keep the graft in place. When we taped the nasal dorsum at the end of the surgery, we cut this absorbable suture, and then took it out when the cast was removed.

Follow-Up and Postoperative Care

We followed up all patients monthly for the first year and every 3 months for the second year to evaluate the outcome of the augmentation, contours, stability of the results, and possible complications. We used nasal palpation to identify irregularities or spicules in the radix area and documented patient complaints and dissatisfaction.

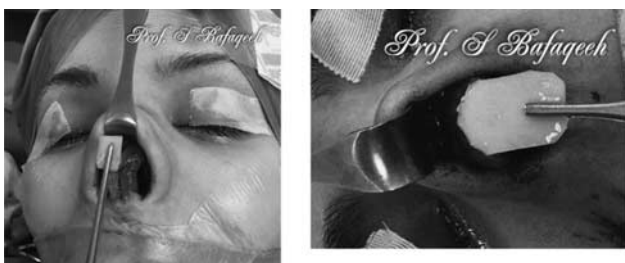

FIGURE 5. For graft placement, we used a retractor to expose the nasal bones and made a precise subperiosteal pocket exactly under the radix area with the defect to prevent dislocation.




FIGURE 6. Pre- and 14-month postoperative images of a female patient with a low radix. She underwent open septorhinoplasty with augmentation of the radix by sized and shaped irradiated rib cartilage wrapped in fascia lata.

RESULTS

Medical records and photographs were retrospectively reviewed to evaluate the postoperative results of various standard graft materials used to augment the nasofrontal angle (septal cartilage, conchal cartilage, rib cartilage, rib cartilage with fascia lata, crushed and diced cartilage wrapped in fascia lata, fascia lata folded layers, and Gore-Tex in fascia lata). Primary procedures were performed in 311 patients (80.5%), and revision procedures were performed in 76 patients (19.6%). In total, 235 patients (60.7%) were females aged 19 to 39 years. The follow-up duration ranged from 1 to 3 years. The graft materials used are summarized in Supplementary Digital Content 1, Table 1, <http://links.lww.com/SCS/D702>.

We used septal cartilage in 23 patients (5.9%), conchal cartilage in 13 patients (3.4%), irradiated rib cartilage alone in 33 patients (8.5%), irradiated rib cartilage wrapped in fascia lata in 141 patients (36.4%) (Fig. 6), excised hump as an autograft in 21 patients (5.4%), crushed cartilage covered or wrapped in fascia lata in 79 patients (20.4%), diced cartilages wrapped in fascia lata in 13 patients (3.4%), fascia lata folded in multilayers in 29 patients (7.5%), temporalis fascia folded in multilayers in

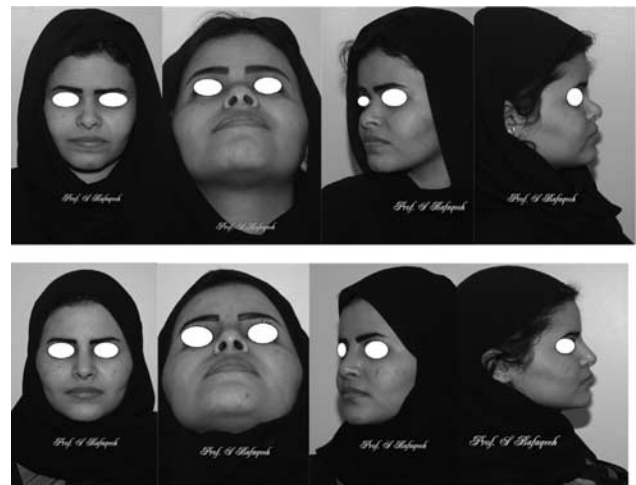


FIGURE 7. Figure shows a 25-year-old female patient with a low radix. Pre- and 18-month postoperative images show the effect of Gore-Tex wrapped in fascia lata as an augmentation graft material. Top: preoperative photos; Bottom: postoperative photos.

11 patients (2.8%), an expanded polytetrafluoroethylene patch (Gore-Tex) wrapped in fascia lata in 17 patients (4.4%) (Fig. 7), and diced cartilage particles soaked in blood and wrapped in Surgicel in 7 patients (1.8%).

Five patients in the crushed cartilage group exhibited irregularities during postoperative follow-up; 2 of them were admitted for secondary revisions. In patients in whom reshaped beveled septal or irradiated rib cartilage were used alone, without any fascia graft, visible sharp-edge irregularities developed early, which were palpable in 7 patients and visible in 2 patients. We subsequently revised these irregularities by removing the grafts and further thinning the edges before replacement; at 9 months, 2 patients developed a small invisible notch in the radix that was palpable, but deferred intervention.

No patient developed infection or had displacement or extrusion of the graft. We found no other complications related to the radix graft, with an overall complication rate of 3.6%.

On follow-up consultation, we assessed the appearance of the radix and asked patients about their dorsal profile in particular. The assessment findings were normal, and all patients, including 11 patients who underwent revision, reported satisfaction with the aesthetic results within 1 year.

DISCUSSION

In the present study, all autologous grafts, in addition to Gore-Tex wrapped in fascia lata, were acceptable graft materials that could be used in radix augmentation. Augmentation of the nasal radix is a common area of interest in rhinoplasty. Many materials and techniques have been introduced in the literature. Ideally, the augmentation material should have a smooth surface integrated with the remainder of the dorsal component.⁸ Bohluli et al⁸ reported the results of 4 techniques (excised hump as an autograft, crushed cartilage, temporalis fascia, and crushed cartilage wrapped in temporalis fascia) in 63 patients; their results, including the complication rate, were similar to those of the present study.⁸ An excised hump autograft, which we used in 21 patients to augment a shallow radix, showed excellent contours, as it easily integrates with the remaining parts of the dorsum. It is also considered as the easiest technique used in rhinoplasty. Furthermore, in 11 patients with thin skin, for whom graft edges or shadows would be visible, temporalis fascia grafts were used.

Yu et al⁹ conducted a study of radix augmentation using crushed cartilage with fibrin sealant in Asian rhinoplasty; they reported that this technique was reliable and suitable for radix augmentation, with a reasonable complication rate.⁹ In some cases, we used crushed cartilage wrapped in fascial lata, which showed good outcomes and acceptable results, with a low rate of complications (5 of 79 patients required revision corrective surgery). Crushed cartilage grafts are applied to cover anomalies and generate a softer nose, and they can also be applied to augment the radix. Crushed cartilage grafts can be arranged into many layers or accumulated to reach a suitable dimension and appearance, depending on the cartilage's thickness and the desired level of augmentation.⁹ Crushing of the cartilage can break down the inherent mechanical characteristics of cartilage grafts and limit postsurgical graft abnormalities.¹⁰ Nevertheless, problems associated with crushed cartilage grafts require the management of their position on the nasal dorsum and postsurgical balance of their site.⁹ Crushed cartilage alone cannot provide adequate structural stabilization.¹¹

Crushed cartilage covered with temporalis fascia and diced cartilage wrapped in fascia lata or temporalis fascia was used in 92 patients. Placing this compound graft in the radix, positioned so as to fill the defects, promoted adaptation and long-term

stability. The DTF grafts described by Daniel are broadly used for nasal dorsal and radix augmentation.¹² Cartilage collected from any relevant areas throughout surgery can be used. Without contamination, there is no immersion of the grafted cartilage, allowing the volume to be controlled. The DTF is able to protect the cartilage, maintained by the normal circulation of the blood.¹² This outcome is likely related to the role of the fascia in the neoperichondrium.¹³ Tasman and Suarez¹⁴ evaluated radix augmentation with diced cartilage glue grafts, and concluded that this technique is a good alternative for radix augmentation. Bullocks et al¹⁵ used autologous diced cartilage as a malleable construct for dorsal augmentation stabilized by an autologous tissue gel, using platelet-rich plasma (platelet gel) and platelet-poor plasma (fibrin glue) as the basis. They reported that autologous tissue gel with diced cartilage is safe and reliable for dorsal augmentation, providing growth factors and stabilization.¹⁵ In our experience, we used diced cartilage wrapped in fascial lata and diced cartilage soaked in blood and then wrapped with Surgicel, which produced excellent results and acceptable aesthetic outcomes, whereas avoiding postoperative complications. Additionally, there was no need for revision rhinoplasty in these 2 groups.

Expanded polytetrafluoroethylene, or Gore-Tex, is a synthetic alloplastic material that has long been used in many medical conditions for soft-tissue management. Gore-Tex was introduced in rhinoplasty in 1983 for augmentation purposes.¹⁶ Yap et al¹⁶ addressed the advantages and disadvantages of Gore-Tex in dorsal augmentation in 1054 Southeast Asian patients. They found Gore-Tex to be an excellent alloplastic material for dorsal augmentation, producing good aesthetic outcomes; the rate of unwanted outcomes was 2.28%, and implant deviation was the most common drawback of this material, in addition to visibility, infection, and satisfaction.¹⁶ Godin et al¹⁷ retrospectively reviewed 309 patients who received Gore-Tex during rhinoplasty; the infection rate was 3.2%, and most of these cases were in the revision rhinoplasty group. In the present study, we performed radix augmentation with Gore-Tex wrapped in fascia lata in 17 patients, and encountered no complications and obtained excellent satisfaction rates.

We also used septal and irradiated rib cartilage in the aforementioned technique and encountered unsatisfactory results in 7 patients who required revision surgery. Additionally, we used rib cartilage wrapped in fascia lata, multiple folded layers of temporalis fascia, and multiple folded layers of fascial lata, with excellent outcomes and no cases of complications or dissatisfaction. We used multilayer fascia lata grafts in 29 patients to address the radix deficiency; these grafts provided a smooth surface, with borders fading easily and completely into the normal donor site tissues. Most of the time, we consider folded fascia lata as the ideal material for radix augmentation.

In our experience, the complication rate was 3.6%, which included cases of irregularities and undesirable results. No infection, displacement, or extrusion of the graft occurred in our patients. Postoperatively, no graft displacement or absorption was seen, but a few patients early in the study period had visible septal-graft edges postoperatively. Moreover, we noted that cartilage grafts can be crushed to reduce the risk of irregularities during the healing process.

The limitation of our study includes the small sample size, along with its retrospective nature. Large randomized multicenter clinical trials are warranted to determine the best material to be used in radix augmentation.

In conclusion, it is important to consider the nasal radix when pursuing a balanced profile in rhinoplasty. From an aesthetic standpoint, altering the radix area can noticeably change the image of the nose, as well as its length and projection. Our experience with radix grafts indicates that the procedure can safely and effectively provide lasting results. Several different

reported techniques for radix augmentation were evaluated to help improve radix augmentation outcomes. In our experience, all evaluated autologous grafts are suitable for radix augmentation. Although Gore-Tex seems to minimize the risk of infection or extrusion in the radix area, whereas maintaining an intact mucosal layer, its potential complications include extrusion, foreign body reaction, infection, and displacement. Patient selection and careful anatomical analysis are integral for successful graft placement; thus, we recommend that clinicians perform computed tomography preoperatively to assist in decision making and to achieve patient satisfaction. In general, some women preferred a lower dorsal profile and refused radix augmentation; thus, more attention should be paid to the radix area during rhinoplasty in the selection of suitable techniques to achieve an excellent outcome, with a low complication rate.

REFERENCES

- Ishii LE, Tollefson TT, Basura GJ, et al. Clinical practice guideline: improving nasal form and function after rhinoplasty. *Otolaryngol Head Neck Surg* 2017;156:S1–S30
- Pousti S, Jalessi M, Asghari A. Management of nasofrontal angle in rhinoplasty. *Iranian Red Crescent Med J* 2010;12:7–11
- Suh MK. Surgical anatomy and physiology of the nose. *Atlas of Asian Rhinoplasty*. Singapore: Springer; 2018; 1–65
- Byrd HS, Hobar PC. Rhinoplasty: a practical guide for surgical planning. *Plast Reconstr Surg* 1993;91:642–654
- Janis JE, Rohrich RJ. Rhinoplasty. In: Persin J, Evans GRD, eds. *Soft-Tissue Surgery of the Craniofacial Region*. Boca Raton, FL: CRC Press; 2007:257–290
- Tezel E, Durmuş FN. A new instrument for achieving a natural nasofrontal angle. *J Plast Reconstr Aesthet Surg* 2009;62:e617–e619
- Cohen JC, Pearlman SJ. Radix grafts in cosmetic rhino-plasty: lessons from an 8-year review. *Arch Facial Plast Surg* 2012;14:456–461
- Bohluli B, Varedi P, Bagheri SC, et al. Nasal radix augmentation in rhinoplasty: suggestion of an algorithm. *Int J Oral Maxillofac Surg* 2017;46:41–45
- Yu MS, Kim BH, Kang SH, et al. Combined use of crushed cartilage and fibrin sealant for radix augmentation in Asian rhinoplasty. *Plast Reconstr Surg* 2015;135:293e–300e
- Cakmak O, Buyuklu F. Crushed cartilage grafts for concealing irregularities in rhinoplasty. *Arch Facial Plast Surg* 2007;9:352–357
- Besharatizadeh R, Ozkan BT, Tabrizi R. Complete or a partial sheet of deep temporal fascial graft as a radix graft for radix augmentation. *Eur Arch Otorhinolaryngol* 2011;268:1449–1453
- Daniel RK. Diced cartilage grafts in rhinoplasty surgery: current techniques and applications. *Plast Reconstr Surg* 2008;122:1883–1891
- Calvert JW, Brenner K, DaCosta-Iyer M, et al. Histological analysis of human diced cartilage grafts. *Plast Reconstr Surg* 2006;118:230–236
- Tasman AJ, Suárez GA. The diced cartilage glue graft for radix augmentation in rhinoplasty. *JAMA Facial Plast Surg* 2015;17:303–304
- Bullocks JM, Echo A, Guerra G, et al. A novel autologous scaffold for diced-cartilage grafts in dorsal augmentation rhinoplasty. *Aesthetic Plast Surg* 2011;35:569–579
- Yap EC, Abubakar SS, Olveda MB. Expanded polytetrafluoroethylene as dorsal augmentation material in rhinoplasty on Southeast Asian noses: three-year experience. *Arch Facial Plast Surg* 2011;13:234–238
- Godin MS, Waldman SR, Johnson CM Jr. Nasal augmentation using Gore-Tex. A 10-year experience. *Arch Facial Plast Surg* 1999;1:118–121