

 **Case Report** 

Thoracic Endovascular Aortic Repair for Pseudoaneurysm after Interrupted Aortic Arch Repair

Kanako Hayashi, MD, Naritaka Kimura, MD, Masatoshi Ohno, MD, Kentaro Yamashita, MD, Hiroaki Izumida, MD, Yu Inaba, MD, Tatsuo Takahashi, MD, Masataka Yamazaki, MD, Tsutomu Ito, MD, and Hideyuki Shimizu, MD

Here we describe the case of a 33-year-old woman who was diagnosed with interrupted aortic arch (IAA) type A and who underwent radical surgery in her infancy. She developed a 42-mm anastomotic pseudoaneurysm in the distal aortic arch. We decided to perform thoracic endovascular aortic repair because of the patient's special request to avoid open surgery. We selected a reversed taper-type leg stent graft for the iliac artery and successfully implanted it without problems. However, the long-term outcomes of the stent graft in young people remain unclear, and careful regular follow-up for a long period is mandatory.


Keywords: adult congenital heart disease, endovascular therapy, interrupted aortic arch

Introduction

The surgical outcomes of congenital heart disease have improved over the years. On the other hand, the number of reoperations during adulthood has also increased. We performed thoracic endovascular aortic repair (TEVAR) for an anastomotic pseudoaneurysm that developed following repair of an interrupted aortic arch (IAA) and achieved a good outcome.

Department of Cardiovascular Surgery, Keio University School of Medicine, Tokyo, Japan

Received: July 16, 2018; Accepted: August 15, 2018
Corresponding author: Naritaka Kimura, MD. Department of Cardiovascular Surgery, Keio University School of Medicine, 35 Shinanomachi, Shinjuku-ku, Tokyo 160-8582, Japan
Tel: +81-3-5363-3804, Fax: +81-3-5379-3034
E-mail: naritaku@keio.jp

 ©2018 The Editorial Committee of Annals of Vascular Diseases. This article is distributed under the terms of the Creative Commons Attribution License, which permits use, distribution, and reproduction in any medium, provided the credit of the original work, a link to the license, and indication of any change are properly given, and the original work is not used for commercial purposes. Remixed or transformed contributions must be distributed under the same license as the original.

Case Report

The case involved a 33-year-old woman who underwent TEVAR after IAA repair. As her medical history, in her infancy (at the age of 3 days), she was diagnosed with IAA type A, atrial septal defect, ventricular septal defect, and patent ductus arteriosus (PDA). At the age of 18 days, she underwent the Blalock–Park procedure, pulmonary artery banding, and PDA closure. At the age of 3 years, she underwent ventricular septal defect closure, pulmonary artery de-banding, and right ventricular outflow tract reconstruction. At the age of 5 years, an anastomotic stenosis with a pressure gradient of 90 mmHg was identified during follow-up and Dacron patch augmentation of the distal aortic arch and the descending aorta was performed, and the pressure gradient decreased to 20 mmHg. At the age of 20 years, she underwent replacement of the distal aortic arch and the descending aorta via left thoracotomy to treat a new saccular aneurysm that was found in the Dacron patch area. The aneurysm was successfully replaced with a Hemashield 16-mm tube graft, and she has been doing well after this surgery.

At the age of 33 years, she was admitted to the emergency department for severe back pain that continued for several days. Computed tomography (CT) scan revealed a 42-mm-diameter pseudoaneurysm at the distal aortic arch (Fig. 1). A great cause of concern was an impending rupture of the aneurysm; therefore, urgent surgical intervention was decided. We proposed treatment options (open surgery vs. TEVAR) and explained the potential risks and benefits associated with each of the treatment options. The patient made a strong request to avoid open surgery because she always had unbearable pain after prior surgeries, and thus, TEVAR was selected. The aneurysm was localized, and no abnormal findings in the access route were detected. In addition, we measured the aneurysm by CT scan and confirmed that TEVAR was appropriate (proximal neck diameter, 14.7×10 mm; landing length, 34 mm; distribution neck diameter, 16.5–18 mm).

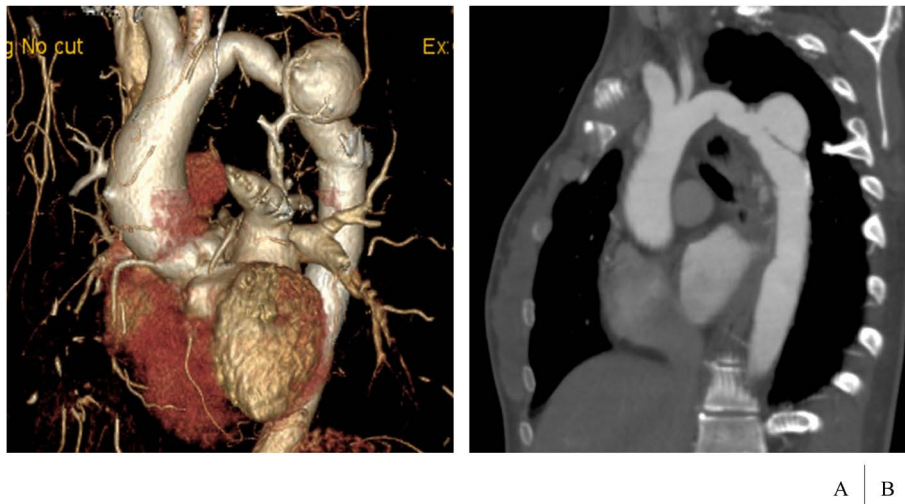


Fig. 1 Preoperative computed tomography scan showing a 42-mm-diameter pseudoaneurysm in the distal aortic arch (A, B).

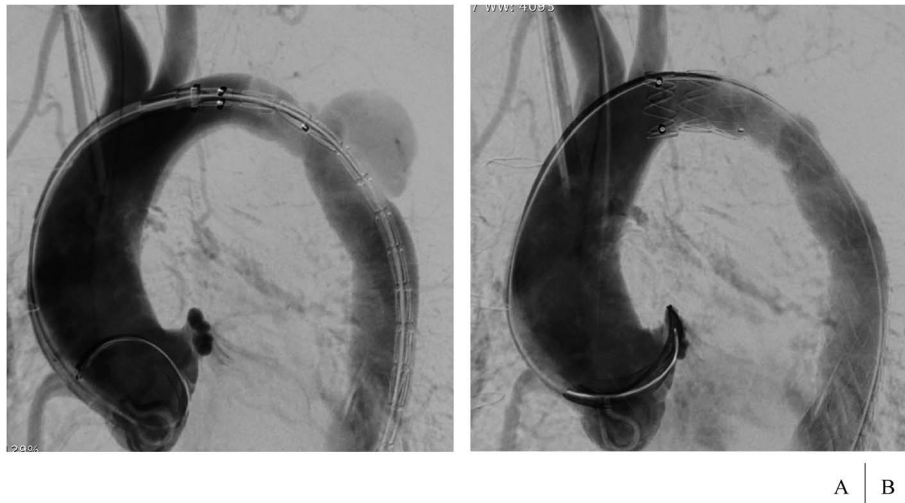


Fig. 2 Angiography showing successful stent graft placement in the distal aortic arch through the descending aorta (A). There was no endoleak into the aneurysm (B).

The surgery was started in the supine position. A 5Fr sheath was inserted from the right brachial artery, and a 4Fr pigtail catheter was placed in the ascending aorta for contrast injection. As the proximal neck was too narrow to insert the regular main body of the stent graft, and the difference in diameter between the proximal neck and the distal neck was marked, we chose an ENDURANT II Leg (Medtronic, Santa Rosa, CA, USA, 16×20×156mm), which was a reversed taper-type leg stent graft for the iliac artery. Informed consent of usage of the device was obtained from the patient and her parents before surgery. We successfully implanted the device using the Lunderquist extra stiff guidewire. Aortic angiography revealed type Ia endoleak, which disappeared after touch-up with balloon (Fig. 2). Initially, there was a discrepancy in the

blood pressure between the upper extremity and the lower extremity (arm: 98/55 mmHg, foot: 73/40 mmHg), but the difference disappeared after performing TEVAR.

The postoperative course was uneventful, and the patient was discharged on postoperative day 7. Postoperative CT scan showed no endoleak, with the proximal diameter extended to 15.6mm and the distal diameter to 19.0mm (Fig. 3). The diameter of pseudoaneurysm measured on CT scan 6 months after surgery decreased from 42mm to 24mm.

Discussion

Recently, the outcomes of surgical treatment for IAA with a ventricular septal defect have improved. One-stage

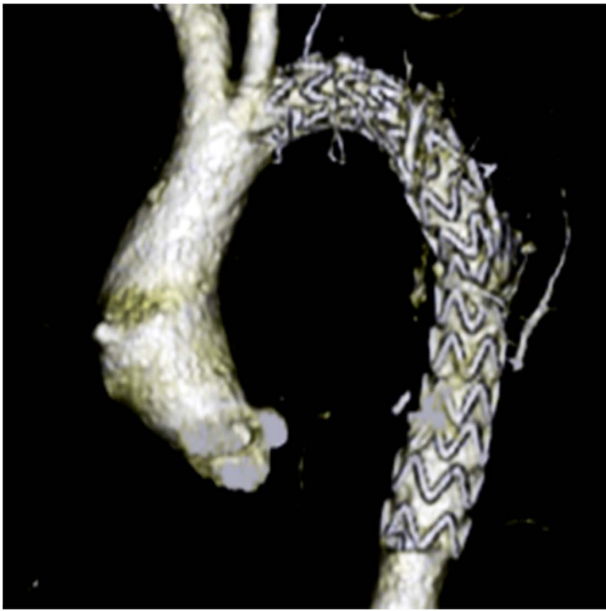


Fig. 3 Postoperative computed tomography scan showing the successful stent graft placement with no migration or endoleak. The aneurysm had already been thrombosed.

repair or two-stage repair is selected depending on the patient's preoperative condition and institutional preference. There are several techniques for reconstructing the aortic arch, such as extended aortic arch anastomosis, the Blalock–Park procedure, the subclavian flap method, and the swing-back technique.^{1–3)} Aortic arch stenosis or aneurysm formation occasionally occurs in the remote postoperative period even if the aortic arch had been repaired with only autologous tissue.

We successfully performed TEVAR for the postoperative anastomotic pseudoaneurysm in our patient who had multiple prior open surgeries. The diameter of the proximal neck was narrow, and there was a difference of 8 mm between the proximal neck diameter and the distal neck diameter. In addition, there was a pressure gradient between the upper extremity and the lower extremity. Lala et al. reported that TEVAR was safely performed in adult patients who had aortic coarctation with excellent short-term outcomes.⁴⁾ Particularly in cases with a large difference in the aortic diameter before and after stenosis, the aortic diameter after TEVAR increased significantly from 11.5 mm to 15.0 mm. It has also been reported that a self-expanding stent graft could expand the aortic constriction to a near-normal diameter.³⁾ In our case, the aortic diameters of both the proximal and distal necks were expanded, as shown by postoperative CT scan, and the pressure gradient between the upper and lower extremities disappeared accordingly. These were unexpected, good results of the stent graft therapy. At this time, the landing zone of the proximal neck was 34-mm long, which should

be sufficient, although the shape was the taper type. Preoperatively, we assumed that type Ia endoleak will develop and therefore decided to insert an additional component, namely, a stent graft whose diameter (22 mm) was larger than that of the origin of the common carotid artery to prevent endoleak.

Numerous problems can occur with the use of a stent graft for the treatment of congenital aortic disease because the patients are usually young. One problem is that young patients often have a narrow access route and their aortic arch is relatively steep, thereby making stent graft therapy difficult. Another problem is that the long-term performance and durability of the stent graft remain unclear. On the other hand, no difference in the mid-term outcomes between TEVAR and open surgery has been reported for an atherosclerotic descending aortic aneurysm,⁵⁾ and continuous careful follow-up is important. If we can confirm that the long-term outcomes of TEVAR are comparable with those of open surgery in the future, stent graft therapy may become the first choice of treatment for young patients who are at a high risk of re-open surgery.

Conclusion

TEVAR facilitated the successful treatment of an aortic anastomotic pseudoaneurysm that developed after IAA repair. Because the long-term outcomes of the use of a stent graft for young people have not yet been fully clarified, careful long-term follow-up should be undertaken.

Acknowledgments

The authors thank Dr. Edward Barroga (<http://orcid.org/0000-0002-8920-2607>) for editing the manuscript.

Disclosure Statement

The authors have nothing to disclose with regard to commercial support.

Author Contributions

Study conception: KH, NK

Data collection: KH

Analysis: KH

Investigation: KH, NK

Writing: KH, NK

Critical review and revision: all authors

Final approval of the article: all authors

Accountability for all aspects of the work: all authors

References

- 1) Hussein A, Iyengar AJ, Jones B, et al. Twenty-three years of single-stage end-to-side anastomosis repair of interrupted aortic arches. *J Thorac Cardiovasc Surg* 2010; **139**: 942-9.
- 2) Naito Y, Harada Y, Uchita S, et al. A novel aortic arch reconstruction method for double-inlet left ventricle with interrupted aortic arch and restrictive bulboventricular foramen. *J Thorac Cardiovasc Surg* 2006; **131**: 475-7.
- 3) Todman SH, Eltayeb O, Ruzmetov M, et al. Outcomes of interrupted aortic arch repair using the carotid artery turn-down procedure. *J Thorac Cardiovasc Surg* 2013; **145**: 176-82.
- 4) Lala S, Scali ST, Feezor RJ, et al. Outcomes of thoracic endovascular aortic repair in adult coarctation patients. *J Vasc Surg* 2018; **67**: 369-81.e2.
- 5) Kamman AV, Jonker FHW, Nauta FJH, et al. A review of follow-up outcomes after elective endovascular repair of degenerative thoracic aortic aneurysms. *Vascular* 2016; **24**: 208-16.