

A Case Series of Liver Abscess Formation after Transcatheter Arterial Chemoembolization for Hepatic Tumors

Wei Sun, Fei Xu, Xiao Li, Chen-Rui Li

Department of Interventional Therapy, National Cancer Center/Cancer Hospital, Chinese Academy of Medical Sciences and Peking Union Medical College, Beijing 100021, China

Abstract

Background: Liver abscess is a serious complication following transcatheter arterial chemoembolization (TACE). Much attention has been paid to this condition as it may interfere with the treatment process and result in a poor prognosis of the patient. This study aimed to analyze the causes of liver abscess, a complication, after TACE for hepatic tumors and to summarize management approaches.

Methods: From June 2012 to June 2014, of 1480 consecutive patients who underwent TACE at our hospital, five patients developed liver abscess after TACE procedures for hepatic tumors. Of the five patients, each receiving conventional TACE, one underwent three sessions, two underwent two sessions, and the remaining two underwent one session of TACE. Demographic and clinical characteristics, together with management approaches and prognosis, were collected through a review of medical records.

Results: These five patients were confirmed to have post-TACE liver abscess through clinical manifestations, laboratory, and imaging tests. After percutaneous drainage and anti-inflammatory treatments, the symptoms present in four patients with liver abscess significantly improved as evidenced by shrinkage or disappearance of the abscess cavity, and the patients recovered completely after sufficient drainage. The remaining patient experienced recurrent symptoms and abdominal abscess, achieved no significant improvement after treatment, and eventually died of severe infection and multiple organ failures.

Conclusions: TACE must be implemented with extreme caution to avoid liver abscess. An effective management relies on an early diagnosis, prompt use of sufficient doses of appropriate antibiotics, and active implementation of abscess incision, drainage, and aspiration.

Key words: Chemoembolization, Therapeutic; Liver Neoplasms; Liver Abscess

INTRODUCTION

Hepatocellular carcinoma (HCC) is the fifth most common cancer worldwide with approximately 500,000 to one million new cases diagnosed annually.^[1-3] The incidence of HCC is 2–3 times higher in developing countries than in the developed countries.^[2] Every year, there are approximately 500,000 to 600,000 deaths from HCC, ranking it the second leading cause of cancer-related deaths.^[1,4]

Transcatheter arterial chemoembolization (TACE) is the intra-arterial injection of emulsified chemotherapeutic agents that mainly include gelatin, iodized oil, and cytotoxic agents.^[2,5] It has already been recognized as the preferred nonsurgical therapeutic option for unresectable primary HCC and liver metastases by means of selectively delivering the chemotherapeutic agents to the targeted tumor area.^[2,5,6] In addition, it can target multiple lesions of HCC in a single treatment session and can be repeatedly applied to the same patient.^[5]

Despite these advantages, complications associated with TACE, including postembolization syndrome (PES), leukocytopenia, impaired hepatic function, biliary necrosis, cholecystitis, and cutaneous injuries, were commonly reported.^[5,6] More specifically, liver abscess, a serious complication following TACE, often prolongs hospital stays and can sometimes be fatal.^[5,6] In the recent years, much attention has been paid to this post-TACE complication because it can interfere with the treatment process and result in a poor prognosis of the patient.

Address for correspondence: Dr. Chen-Rui Li, Department of Interventional Therapy, National Cancer Center/Cancer Hospital, Chinese Academy of Medical Sciences and Peking Union Medical College, Beijing 100021, China
E-Mail: lcr0009@163.com

This is an open access article distributed under the terms of the Creative Commons Attribution-NonCommercial-ShareAlike 3.0 License, which allows others to remix, tweak, and build upon the work non-commercially, as long as the author is credited and the new creations are licensed under the identical terms.

For reprints contact: reprints@medknow.com

© 2017 Chinese Medical Journal | Produced by Wolters Kluwer - Medknow

Received: 08-02-2017 **Edited by:** Yuan-Yuan Ji
How to cite this article: Sun W, Xu F, Li X, Li CR. A Case Series of Liver Abscess Formation after Transcatheter Arterial Chemoembolization for Hepatic Tumors. *Chin Med J* 2017;130:1314-9.

Access this article online

Quick Response Code:



Website:
www.cmj.org

DOI:
10.4103/0366-6999.206345

In this case series, we retrospectively reviewed the medical records of five patients who had developed liver abscess after undergoing TACE in our department in 2012–2014, analyzed the causes of liver abscess, and summarized its management approach.

METHODS

This case series was exempted from Institutional Review Board (IRB) review according to the policy of the IRB of National Cancer Center/Cancer Hospital, Chinese Academy of Medical Sciences and Peking Union Medical College (China).

Over the course of a 2-year period (from June 2012 to June 2014), a total of 1480 patients underwent TACE at our hospital. Of these, five patients developed liver abscess after a total of nine TACE procedures. Informed consent forms were signed by all five patients. The incidence of post-TACE liver abscess was 0.34% (5/1480).

The general characteristics of the five patients are presented in Table 1: all are males with a mean age of 52 (range: 38–65) years. Four had primary HCC and one had liver metastasis, with tumors occurring on the right lobe of the liver for all patients. Three patients had diabetes in addition to hepatic tumors and one was further accompanied with cholecystitis. The patient with liver metastasis had once undergone

pancreaticoduodenectomy (Whipple procedure). Two cases of primary HCC had concomitant portal vein tumor thrombus, of whom one had undergone endoscopic sphincterotomy and stenting. Two cases had Type II biliary abnormalities. All patients received conventional TACE: three sessions for one patient, two sessions for two patients each, and the remaining two had one session of TACE. The five patients underwent chemoembolization using iodized oil (Iodinated Oil Injection; Luyin Pharm Co. Ltd., Yantai, China) and gelfoam particles (Gelatin; Alicon Pharm Sci and TEC Co., Ltd., Hangzhou, China). Among them, three used more than 10 ml of iodized oil; in addition, the lowest dose of gelfoam was 30 mg and two patients received 100 mg of gelfoam [Table 1].

We learned that to determine the number of TACE procedures that should be performed for each individual, we need to consider both the tumor response and each patient's tolerance to the procedure.^[7]

A catheter (TERUMO Co. Ltd., Tokyo, Japan) was briefly inserted under fluoroscopic guidance into the tumor target vessel for injection of chemotherapeutic agents, which were composed of epirubicin hydrochloride (Pfizer Pharm Co. Ltd., Wuxi, China) and raltitrexed (Chia Tai Tianqing Pharm Co., Ltd., Nanjing, China) in four patients and oxaliplatin and raltitrexed (Sanofi Pharm Co. Ltd., Hangzhou, China)

Table 1: General characteristics of patients with liver abscess

Patient number	Diagnosis	Age (years)	Surgical history	Tumor conditions	Number of TACE sessions	Dosage of embolic agents such as iodized oil, together with gelfoam particles (gelatin)	Concomitant diseases	WBC count	Time of onset of high fever	Concomitant symptoms
1	Primary HCC	58	Endoscopic sphincterotomy and stenting	Multiple tumors, the largest was 8.5 cm	2	20 ml + 60 mg	Diabetes	14.57×10^9	1 week after surgery	High fever, chills, abdominal pain, and jaundice, murphy sign (+)
2	Primary HCC	41	No	15.8 cm	2	30 ml + 100 mg	Cholelithiasis	10.23×10^9	No fever	Abdominal pain
3	Primary HCC	38	No	16 cm	3	30 ml + 100 mg	No	9.62×10^9	2 weeks after surgery	High fever, peritonitis, and abdominal pain, murphy sign (+)
4	Primary HCC	65	Liver biopsy (poorly differentiated adenocarcinoma)	Multiple tumors, the largest was 6.2 cm	1	8 ml + 30 mg	No	14.26×10^9	1 week after surgery	High fever, chills, abdominal pain, and jaundice
5	Liver metastasis of bile duct cancer	58	Whipple surgery	2.5 cm	1	6 ml + 30 mg	Diabetes	29.70×10^9	2 days after surgery	Chills, high fever

HCC: Hepatocellular carcinoma; TACE: Transcatheter arterial chemoembolization; WBC: White blood cell.

in the remaining patient. Iodized oil, together with gelfoam particles (gelatin), was additionally used as the embolic agent. None of the five patients received prophylactic antibiotics before TACE treatment, and conventional hepatoprotective treatments were given for symptomatic relief.

RESULTS

After TACE procedures, four patients suffered from high fever ($\geq 39^{\circ}\text{C}$) lasting from 3 days to 2 weeks. This included three cases with chills and one with peritonitis manifestations. Blood or pus culture was positive in three cases, including one with *Enterococcus faecalis* infection and two with co-infection of *E. faecalis* and *Escherichia coli* [Table 2]. Based on laboratory and imaging test results, all the five cases were diagnosed with liver abscess, located on the right lobe of the liver [Figures 1 and 2].

Postoperatively, one patient developed concomitant biloma. Two patients had postoperative cholecystitis manifestations; one was associated with gangrenous cholecystitis (confirmed by surgery and imaging tests) and considered related to gallbladder and bile duct embolization. All the five patients received puncture and drainage supplemented with antibiotics for the treatment of liver abscess [Table 2]. One patient underwent ultrasound-guided puncture and drainage and the other four underwent fluoroscopically guided percutaneous transhepatic external drainage after ultrasound positioning. An 8.5-F external drainage tube (COOK Group Co., Ltd., Bloomington, USA) was placed as low as possible intraoperatively in the abscess cavity. One patient had multilocular abscess in which the puncture needle and catheter were fluoroscopically guided into the largest cavity for maximal drainage. Finally, the drainage fluid was subjected to bacterial culture and drug susceptibility tests.

After the procedure, the drainage tube was kept unobstructed and intermittently rinsed with antibiotics; the patients also received a combination of antibiotics for symptom control. When there was an absence of drainage fluid, imaging tests were used to determine whether it was suitable to withdraw the drainage tube.

Following puncture and drainage, one patient was not febrile after TACE ($\leq 37^{\circ}\text{C}$). The other four patients with fever onset after TACE also returned to normal on the 2nd day after surgery. Clinical symptoms improved significantly after drainage in four patients, the tube was withdrawn after the re-examination results proved that there was improvement, and they were subsequently discharged after recovery. After discharge, one of these patients underwent liver transplantation whereas the other three were followed up regularly. One patient experienced recurrent symptoms and therefore the drainage tube was retained for him. Further, computed tomography (CT) examination revealed the

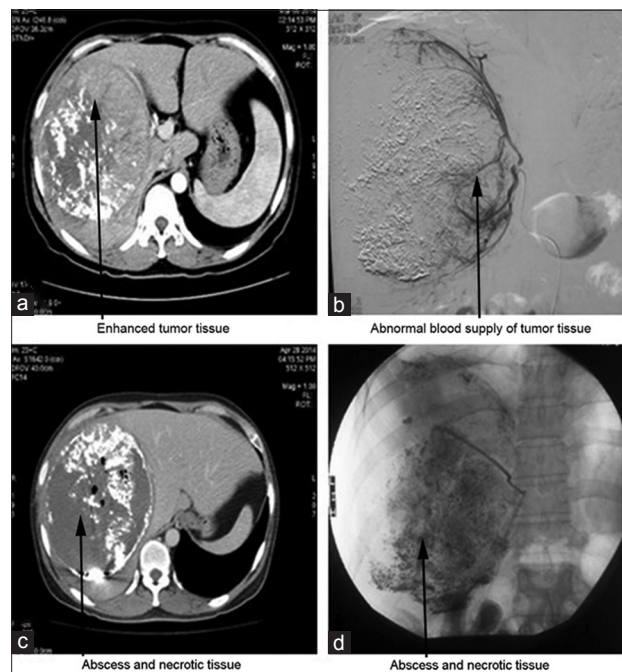


Figure 1: Imaging results of a 41-year-old male with primary HCC. (a) CT image after the first TACE session; (b) DSA image after the second TACE session; (c) CT image after two TACE sessions; (d) X-ray image after percutaneous transhepatic external drainage of liver abscess. HCC: Hepatocellular carcinoma; CT: Computed tomography; TACE: Transcatheter arterial chemoembolization; DSA: Digital subtraction angiography.

Table 2: Management and outcomes of patients with liver abscess

Patient number	Diagnosis	Age (years)	Blood or pus culture	Management	Outcomes
1	Primary HCC	58	<i>E. faecalis</i>	Puncture and drainage + combined use of sensitive antibiotics	Improved and discharged
2	Primary HCC	41	Negative	Puncture and drainage + flushing with antibiotics	Improved and discharged
3	Primary HCC	38	Negative	Puncture and drainage + flushing with antibiotics	Improved and discharged
4	Primary HCC	65	<i>E. coli</i> , <i>E. faecalis</i>	Puncture and drainage + combined use of sensitive antibiotics	Improvement in the early stage, recurrent symptoms, accompanied by severe infection and multiple organ failure
5	Liver metastasis of bile duct cancer	58	<i>E. coli</i> , <i>E. faecalis</i>	Puncture and drainage + flushing with antibiotics + combined use of sensitive antibiotics	Improved and discharged, underwent regular re-examination

HCC: Hepatocellular carcinoma; *E. faecalis*: *Enterococcus faecalis*; *E. coli*: *Escherichia coli*.

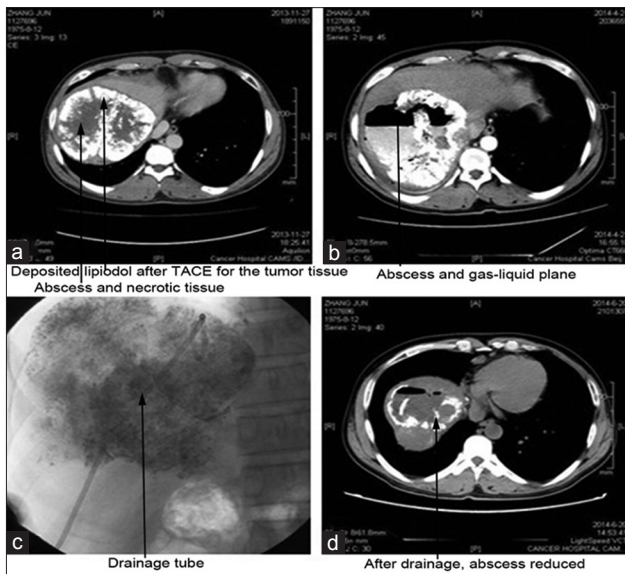


Figure 2: Imaging results of a 38-year-old male with primary HCC. (a) CT image after two TACE sessions; (b) CT image after three TACE sessions; (c) X-ray image after percutaneous transhepatic external drainage of liver abscess; (d) CT image after percutaneous transhepatic external drainage of liver abscess. HCC: Hepatocellular carcinoma; CT: Computed tomography; TACE: Transcatheter arterial chemoembolization.

presence of an abdominal abscess, and despite continuous drainage and antibiotic therapy, the patient still died of severe infection and multiple organ failures after 2 months.

DISCUSSION

We present five cases of liver abscess developed after TACE for hepatic tumors. For unresectable primary and metastatic hepatic tumors, TACE is recognized as the preferred palliative treatment option by health-care practitioners due to its wide indication, good tolerance, and enhanced therapeutic effects at local foci.^[2,5,6,8-11] Postoperative liver abscess is a serious complication with mortality rates ranging from 13.3% to 50%.^[9] During an 8-year study period, Huang *et al.*^[12] found that the incidence of liver abscess after TACE for malignant hepatic tumor was 0.27% in 1374 patients who underwent 2581 TACE procedures in Taiwan, China. A similar incidence rate (0.28%) was observed in 351 Korean patients with liver cancer who received single or multiple TACE sessions.^[13] In this case series, the incidence of post-TACE liver abscess was 0.34%, which is consistent with the rates reported for the Asian population.

The cause of liver abscess after TACE is not well established and is a complex issue. Several mechanisms have been proposed to be attributable to the formation of post-TACE liver abscess: in general, liquefied necrosis forms after tumor tissue embolization, which, combined with chemotherapy-induced liver dysfunction, causes systemic immunity to decline and thereby induces abscess formation.^[14] In this case series, four patients had a large tumor size (>5 cm) located on the right lobe of the liver near

the gallbladder, three patients had concomitant diabetes, one patient had cholecystolithiasis, two patients had Type II biliary abnormalities, and two patients had concomitant portal vein tumor thrombus. The three patients with positive blood or pus culture were all infected with endogenous bacteria; gelfoam particles were applied to all the five cases. In addition, three patients received more than one TACE session, thereby increasing the risks of vasospasm and intimal injury. These, together with compromised immunity of the patients, are regarded as risk factors for the development of post-TACE liver abscess.^[6,7,9,15-17]

One patient underwent endoscopic sphincterotomy and stenting due to primary HCC. Gastrointestinal or biliary tract surgery was one of the most significant risk factors for liver abscess formation (e.g., endoscopic sphincterotomy, biliary-enteric anastomosis, and biliary external drainage).^[6-8,13,15,18,19] In the event of sphincterotomy or loss of function of Oddis sphincter, enteric bacteria could retrograde into the liver; meanwhile, gastrointestinal tract and biliary bacteria can also enter the venous plexus and ascend to the liver through blood flow.^[18,18,19] Since TACE-induced hepatic ischemia and hypoxia would provide a favorable environment for bacterial growth, the biliary tree, which is colonized by enteric bacteria, will predispose the necrotic liver tissue that is susceptible to secondary infection.^[18] In other words, the synergistic effect of biliary duct injury and biliary tree contamination increases the risk of post-TACE liver abscess formation in patients with a history of bilioenteric surgery.^[6] In addition, since the liver is characterized by dual blood supply from both the hepatic artery and portal vein, the formation of portal vein tumor thrombosis after TACE will also aggravate tissue ischemia and hypoxia.^[13] As such, Geschwind *et al.*^[20] conducted an experiment in which patients with a history of biliary reconstructive surgery received either (1) traditional prophylaxis of intravenous cephalexin, or (2) prophylaxis of bowel preparation and tazobactam/piperacillin before TACE. They found that, while four patients (1.5%) in Group 1 developed post-TACE liver abscess, none in Group 2 developed abscess until the end of their follow-up.^[20] As a result, they concluded that the combined use of a broad-spectrum antibiotic regimen and intestinal cleansing in patients with previous biliary reconstructive surgery before TACE might effectively prevent the formation of postoperative liver abscess.^[20] Despite the favorable results, due to the stringent requirements for antibiotics' use in clinical practice, patients in our case series would not receive prophylactic antibiotics unless with a diagnosis of concurrent infection.

In this case series, all the five patients underwent chemoembolization using iodized oil and gelfoam particles (gelatin). Song *et al.*^[7] concluded that the use of gelfoam in addition to Lipiodol would significantly increase the chances of developing liver abscess for patients with portal vein tumor thrombus after TACE on a 90% confidence interval. Consistent findings were also reported by Woo *et al.*,^[16] in

which particulate embolization or Grade 2 oily portogram was identified as a significant risk factor for the development of liver abscess in patients with primary and metastatic liver cancer after TACE. A plausible explanation can be that the semifluid nature of iodized oil, together with the gelatin particulate, would block the drainage routes of the portal vein for hepatic tumors and produce a “subsegmentectomy-like effect,” which is the coexistence of massive tumor destruction and adjacent liver parenchyma atrophy.^[16] For large-sized lesions, there is a trade-off between complete embolization of the tumor and surrounding tissue damage: increasing the dose of embolic agents might cause injury to the vascular endothelial cells, aggravate liver parenchymal damage, and lead to secondary immune dysfunction, which causes bacteria from the gastrointestinal tract and other sources brought by the portal vein blood supply to invade the tumor and increase the chance of abscess formation.

Three out of five patients in this case series had concomitant diabetes. Oshima *et al.*^[17] found that liver cancer patients with concomitant diabetes are highly susceptible to the development of liver abscess following TACE. Hanazaki *et al.*^[21] reported the successful treatment of a case of gas-forming liver abscess after TACE for recurrent primary HCC in a 65-year-old male who had diet-controlled diabetes mellitus for 5 years. Since the organism’s defense mechanism could be weakened by the presence of diabetes, it would result in a hyperglycemia state that is favorable for bacterial growth due to the suppression of phagocytosis, chemotaxis, and cytokine-production activity of leukocytes.^[22] Furthermore, both antibody- and cell-mediated immunity were reduced,^[22] resulting in an increased chance of opportunistic infection which would, alternatively, promote the formation of liver abscess, especially under stress conditions, i.e., after surgical procedures.^[11]

One patient developed concomitant biloma and two patients had postoperative cholecystitis manifestations in our case series. Huang *et al.*^[23] reported the development of intrahepatic biloma after TACE through microspheres in a 44-year-old male diagnosed with primary HCC. In a series of 972 Japanese patients with liver cancer, 35 (3.6%) developed intrahepatic biloma, the incidence rate being significantly higher in patients with metastatic hepatic tumor than those with primary HCC (9.6% vs. 3.3%, $P < 0.05$).^[10] Post-TACE cholangitis was also reported,^[24] and a close association was observed between the areas of TACE and bile duct injuries.^[25]

In contrast to the liver parenchyma, which receives dual blood supply, the main source of blood supply to the biliary system and peribiliary capillary plexus originates from the accompanying branch of the hepatic artery.^[10] As a result, the biliary system, as compared to the hepatocytes, is more susceptible to ischemic injury. TACE can not only block the tumor-feeding artery, but it can also reduce the number of endothelial cells of the peribiliary capillary plexus and can cause secondary chemical and hypoxic-ischemic injury to the biliary system.^[25] This is due to the fact that, when embolic substances remain in the peribiliary capillary plexus, they

will not only reduce local blood supply and subsequently weaken the anti-infective ability of the surrounding liver tissues, but also cause microvascular damage of the peribiliary capillary plexus. As a result, the bile leakage can progress to peripheral bile duct necrosis and eventually form local abscesses and biloma.^[10,23] In addition, conditions such as gallstones, tumor compression, gallbladders that are adjacent to liver lesions with an abnormal blood supply due to undersized and irregular branch of hepatic arteries, surgical-related vasospasm and intimal injury, and conditions associated with extrahepatic bile duct stenosis can all induce intrahepatic bile stasis and cholangitis.^[10] Therefore, special attention, including the avoidance of embolization into the cystic artery, should be given during TACE for patients with lesions close to the gallbladder and vasospasm or stenosis after repeated treatments.^[10,23]

Patients who have undergone TACE and may have had varying degrees of fever, chills, abdominal pain, and other manifestations of PES should be differentiated from liver abscess.^[19] Liver abscess generally has liver enlargement, liver pain, fever and elevated white blood cells, and other signs. CT can show irregular, thick-walled cystic lesions, with abscess in the center, “ring sign,” and abscess within the small bubbles, which are characteristic features of liver abscess. Liver tumor with liver abscess undergoing digital subtraction angiography (DSA) can show the abnormal edge of the blood supply, which is the tumor tissue (DSA is not a means of liver abscess examination, no characteristic features). The duration of fever caused by PES varies, gradually improving and resolving itself within 2 weeks in most patients.^[5] Furthermore, fevers can be caused by tumor necrosis and absorption in which the body temperature mostly does not exceed 38.5°C. In this case series, four patients developed high fevers ($\geq 39^\circ\text{C}$) that ranged from 2 days to 2 weeks after TACE. Three patients’ fevers were accompanied by chills and all values were confirmed by imaging tests with abscess liquefaction and necrosis. The possibility of developing liver abscesses after TACE should be considered for patients experiencing abdominal pain, persistent fever that lasts ≥ 2 weeks (especially fever with a persistent body temperature of over 39°C) and chills, and imaging and laboratory tests that need to be timely performed to avoid a delay in diagnosis.^[5]

In our case series, a variety of antibiotics were administered to patients on an individualized regimen for control of symptoms. For blood or pus culture-positive patients, appropriate antibiotics were added in a timely manner. All the five patients underwent percutaneous transhepatic external drainage after confirmation of liver abscess and intermittent flushing with antibiotics was performed. High-pressure flushing should be avoided due to the fact that it may bring bacteria in the abscess cavity to the bloodstream, which may induce or aggravate infection.

The major limitation of this case series is the small sample size with only five cases being included. Liver abscess is not frequently encountered in clinical practice, so we analyzed

the potential etiologies, diagnosis, treatment, and prognosis of the cases encountered in our institution to deepen our understanding on the prevention and appropriate treatment of this complication.

In conclusion, effective management of liver abscess relies on a clear understanding of its pathogenesis, improvement of the diagnosis, clarification of its imaging characteristics, administration of sufficient doses of sensitive antibiotics in a timely manner, and active abscess cavity puncture aspiration and drainage. TACE must be implemented with extreme caution to avoid liver abscess, especially for high-risk patients such as those with lesions close to the gallbladder, a large tumor size (>5 cm), combined diabetes, portal vein tumor thrombus or bile duct abnormalities, or thorough occlusion of the tumor arterial blood supply.

Acknowledgment

The authors thank Yi-Wen Huang and Dr. Jie Mao for their writing and editing support.

Financial support and sponsorship

Nil.

Conflicts of interest

There are no conflicts of interest.

REFERENCES

1. Carter S, Martin Ii RC. Drug-eluting bead therapy in primary and metastatic disease of the liver. *HPB (Oxford)* 2009;11:541-50. doi: 10.1111/j.1477-2574.2009.00071.x.
2. Nawawi O, Hazman M, Abdullah B, Vijayanathan A, Manikam J, Mahadeva S, *et al.* Transarterial embolisation of hepatocellular carcinoma with doxorubicin-eluting beads: Single centre early experience. *Biomed Imaging Interv J* 2010;6:e7. doi: 10.2349/bij.6.1.e7.
3. Kim HY, Kim CW, Choi JY, Park CH, Lee CD, Yim HW. A decade-old change in the screening rate for hepatocellular carcinoma among a hepatitis B virus-infected population in Korea. *Chin Med J* 2016;129:15-21. doi: 10.4103/0366-6999.172551.
4. Xu XS, Chen W, Miao RC, Zhou YY, Wang ZX, Zhang LQ, *et al.* Survival analysis of hepatocellular carcinoma: A comparison between young patients and aged patients. *Chin Med J* 2015;128:1793-800. doi: 10.4103/0366-6999.159356.
5. Xia J, Ren Z, Ye S, Sharma D, Lin Z, Gan Y, *et al.* Study of severe and rare complications of transarterial chemoembolization (TACE) for liver cancer. *Eur J Radiol* 2006;59:407-12. doi: 10.1016/j.ejrad.2006.03.002.
6. Kim W, Clark TW, Baum RA, Soulen MC. Risk factors for liver abscess formation after hepatic chemoembolization. *J Vasc Interv Radiol* 2001;12:965-8. doi: 10.1016/S1051-0443(07)61577-2.
7. Song SY, Chung JW, Han JK, Lim HG, Koh YH, Park JH, *et al.* Liver abscess after transcatheter oily chemoembolization for hepatic tumors: Incidence, predisposing factors, and clinical outcome. *J Vasc Interv Radiol* 2001;12:313-30. doi: 10.1016/S1051-0443(07)61910-1.
8. Hashimoto T, Mitani T, Nakamura H, Hori S, Kozuka T, Kobayashi Y, *et al.* Fatal septic complication of transcatheter chemoembolization for hepatocellular carcinoma. *Cardiovasc Intervent Radiol* 1993;16:325-7.
9. Li JH, Yao RR, Shen HJ, Zhang L, Xie XY, Chen RX, *et al.* Clostridium perfringens infection after transarterial chemoembolization for large hepatocellular carcinoma. *World J Gastroenterol* 2015;21:4397-401. doi: 10.3748/wjg.v21.i14.4397.
10. Sakamoto I, Iwanaga S, Nagaoki K, Matsuoka Y, Ashizawa K, Uetani M, *et al.* Intrahepatic biloma formation (bile duct necrosis) after transcatheter arterial chemoembolization. *AJR Am J Roentgenol* 2003;181:79-87. doi: 10.2214/ajr.181.1.1810079.
11. Farinati F, De Maria N, Marafin C, Herszényi L, Del Prato S, Rinaldi M, *et al.* Unresectable hepatocellular carcinoma in cirrhosis: Survival, prognostic factors, and unexpected side effects after transcatheter arterial chemoembolization. *Dig Dis Sci* 1996;41:2332-9. doi: 10.1007/BF02100123.
12. Huang SF, Ko CW, Chang CS, Chen GH. Liver abscess formation after transarterial chemoembolization for malignant hepatic tumor. *Hepatogastroenterology* 2003;50:1115-8.
13. Chung JW, Park JH, Han JK, Choi BI, Han MC, Lee HS, *et al.* Hepatic tumors: Predisposing factors for complications of transcatheter oily chemoembolization. *Radiology* 1996;198:33-40. doi: 10.1148/radiology.198.1.8539401.
14. Yang J. Progress of the diagnosis and treatment of liver abscess (in Chinese). *Chin J Pract Surg* 2003;23:693-4.
15. Chen C, Chen PJ, Yang PM, Huang GT, Lai MY, Tsang YM, *et al.* Clinical and microbiological features of liver abscess after transarterial immobilization for hepatocellular carcinoma. *Am J Gastroenterol* 1997;92:2257-9.
16. Woo S, Chung JW, Hur S, Joo SM, Kim HC, Jae HJ, *et al.* Liver abscess after transarterial chemoembolization in patients with bilioenteric anastomosis: Frequency and risk factors. *AJR Am J Roentgenol* 2013;200:1370-7. doi: 10.2214/AJR.12.9630.
17. Oshima S, Tani N, Takaishi K, Hirano M, Makari Y, Hoshi M, *et al.* Clinical evaluation of the risk factors for liver abscess after TACE or RFA (in Japanese). *Gan To Kagaku Ryoho* 2014;41:2113-5.
18. Pua U, Merkle EM. Case report. Spontaneous cholecystocolic fistula and locoregional liver tumour ablation: A cautionary tale. *Br J Radiol* 2011;84:e243-5. doi: 10.1259/bjr/13919678.
19. Halpenny DF, Torreggiani WC. The infectious complications of interventional radiology based procedures in gastroenterology and hepatology. *J Gastrointest Liver Dis* 2011;20:71-5.
20. Geschwind JF, Kaushik S, Ramsey DE, Choti MA, Fishman EK, Kobeiter H. Influence of a new prophylactic antibiotic therapy on the incidence of liver abscesses after chemoembolization treatment of liver tumors. *J Vasc Interv Radiol* 2002;13:1163-6.
21. Hanazaki K, Kajikawa S, Horigome N, Shiohara E, Haba Y, Kuroda T, *et al.* Gas-forming liver abscess after transcatheter arterial embolization for hepatocellular carcinoma: Report of a case. *Jpn J Surg* 1993;23:747-9. doi: 10.1007/BF00311717.
22. Tanaka Y. Immunosuppressive mechanisms in diabetes mellitus (in Japanese). *Nihon Rinsho* 2008;66:2233-7.
23. Huang CK, Chen SC, Shih PM, Chuang WL. Biloma following transcatheter arterial chemoembolization with microspheres: A case report. *Kaohsiung J Med Sci* 2007;23:470-4. doi: 10.1016/S1607-551X(08)70055-X.
24. Okabe K, Beppu T, Komori H, Sano O, Yamanaka T, Haraoka K, *et al.* Postoperative cholangitis of balloon-occluded transarterial chemoembolization (B-TACE) for hepatocellular carcinoma (in Japanese). *Gan To Kagaku Ryoho* 2014;41:2119-21.
25. Kobayashi S, Nakanuma Y, Terada T, Matsui O. Postmortem survey of bile duct necrosis and biloma in hepatocellular carcinoma after transcatheter arterial chemoembolization therapy: Relevance to microvascular damages of peribiliary capillary plexus. *Am J Gastroenterol* 1993;88:1410-5.