

# Osteopathic approach with a patient undergoing cardiac transplantation: the five diaphragms

This article was published in the following Dove Press journal:  
*International Medical Case Reports Journal*

Bruno Bordoni<sup>1</sup>  
Bruno Morabito<sup>2,3</sup>  
Marta Simonelli<sup>4</sup>  
Luigi Nicoletti<sup>5</sup>  
Riccardo Rinaldi<sup>5</sup>  
Filippo Tobbi<sup>6</sup>  
Philippe Caiazza<sup>5</sup>

<sup>1</sup>Foundation Don Carlo Gnocchi IRCCS, Department of Cardiology, Institute of Hospitalization and Care with Scientific Address, Milan 20100, Italy; <sup>2</sup>Foundation Polyclinic University A. Gemelli University Cattolica Del Sacro Cuore, Rome, Italy; <sup>3</sup>Department of Osteopathy, CRESO School, Gorla Minore, Piazza XXV Aprile 421055, Italy; <sup>4</sup>French-Italian School of Osteopathy (SOFI), Pisa, Italy; <sup>5</sup>Department of Osteopathy, Accademia Italiana Terapia Osteopatica Posturale (AITOP), Massa-Carrara, Italy; <sup>6</sup>Poliambulatorio Medico E Odontoiatrico, Busto Arsizio, Varese, Italy

**Abstract:** The case report presents a patient with a possible neuropathic sternal pain associated with a recent heart transplant procedure. The patient could not breathe deeply and move the upper limbs, with a trunk torsion, feeling a sharp pain under and around the left breastbone. A fascial osteopathic approach in the treatment of the pelvic floor, the respiratory diaphragm, the thoracic outlet, the tongue and the tentorium cerebelli allowed the patient to access to a cardiovascular rehabilitation program. In osteopathic medicine, these anatomical parts of the body are called the five diaphragms. To our best knowledge, this is the first case report that uses osteopathic treatment in a patient with sternal pain associated with an undergoing cardiac transplantation. The clinical importance of the case report is added to other osteopathic research with patients undergoing cardiac surgery (coronary artery bypass graft) and with multiple benefits, without side effects. One of the main goals of osteopathic treatment is to provide the patient with well-being, from many clinical points of view, allowing the person to be discharged from the hospital more quickly and/or with less pain.

**Keywords:** diaphragm, osteopathic, fascia, cardiac transplantation, pain, heart, case report

## Introduction

Incidence of chronic heart failure (CHF) is increasing steadily, predominantly due to population aging. Thanks to scientific and medical advances, much progress has been made in treating heart disease, such as the left ventricular assist device (LVAD) implant surgery. Medical advances increase life expectancy for the elderly patients with heart disease, making the heart transplant an essential option.<sup>1</sup> According to the Registry of the International Society for Heart and Lung Transplantation, the 1-year survival rate after a primary heart transplant is about 85%. However, patients can develop postoperative complications that may decrease quality of life or may lead to death: infections, aortic aneurysm, arterial embolism, rejection, cardiac arrest, heart attack, due to technical (related to the transplant procedure) or unknown causes.<sup>2</sup>

Pain is a non-fatal post-transplant complication that can decrease a patient's quality of life (QoL). Pain perception from 6 months to 5 years after transplantation increased, compared to one general population sample; recent data suggest 11% of the patients reported having severe or very severe pain.<sup>3</sup> A wide range of different factors can cause more pain postsurgery, such as socio-demographic factors, psychological status or other concomitant diseases (for example, gastrointestinal or joint disorders).<sup>3</sup>

A possible cause of chronic post-sternotomy pain syndrome is the formation of adhesions in the mediastinum, between the sternum and the retrosternal tissues up to the pericardium.<sup>4</sup> Whilst postsurgical adhesions can help stabilize the

Correspondence: Bruno Bordoni  
Foundation Don Carlo Gnocchi IRCCS,  
Department of Cardiology, Institute of  
Hospitalization and Care with Scientific  
Address, Milan 20100, Italy  
Tel +39 02 349 630 0617  
Email bordonibruno@hotmail.com

pericardium in the mediastinum, they can also cause neuropathic pain. The new adhesions are vascularized and innervated, generating unforeseeable proprioceptive or nociceptive afferents.<sup>4</sup>

It is necessary to find therapeutic strategies that could decrease pain perception, improving the QoL in heart transplant patients and limiting the side effects caused by pain-relieving drugs. In our previous study of patients undergoing sternotomy for cardiac surgery (80 poststernotomy adult inpatients were randomly allocated to either the control group or the experimental group), we used the osteopathic manipulative treatment (OMT) to increase pain threshold and to reduce time course of functional recovery in this patient group, compared to those who were assigned to control group (standardized cardiorespiratory rehabilitation program alone).<sup>5</sup> Osteopathic manual technique was indirect osteopathic approach or fascial unwinding therapy: it is a manual therapy in which a therapist does not induce any movement and not provoke any pain:

The OMT does not induce any movement but allows the underlying tissue to express intrinsic movements, reflecting the physiological sliding of different fascial layers while breathing. Laying on the hands and following fascial vector directions, the application ends when the subcutaneous tissue becomes less rigid and when the movements expressed by the various palpated body segments are broader and similar to those of the (normal) contralateral side of the body.<sup>5</sup>

We adopted the same OMT approach of the trial. The patient was treated 5 consecutive days, for a 15-min session each day. We treated the pelvic floor or the pelvic diaphragm, the respiratory diaphragm, the thoracic outlet or the thoracic diaphragm, the tongue, and the tentorium cerebelli.

The 5 diaphragms describe the fascial and neurological connection of the body segments mentioned. Posteriorly, the thoracolumbar fascial system relates the pelvic floor musculature, the diaphragmatic area (part of the muscular area and the pillars), and the thoracic outlet musculature (trapezius muscle, deep neck muscles).<sup>6,7</sup> The deep musculature of the neck is anatomically, neurologically and embryologically connected to the lingual complex.<sup>8</sup> The suboccipital muscles, which are an integral part of the thoracolumbar fascia, are in direct contact with the tentorium cerebelli through myodural bridges.<sup>6,7</sup> Anteriorly, the fascial system of the neck connects the lingual complex and the

musculature of the thoracic outlet (scalene and subclavian muscles); the fascia of the neck separates at the level of the thoracic outlet to become the endothoracic fascia and the superficial fascia of the thorax. The anterior fascial system of the endothoracic fascia covers the diaphragm muscle and continues as a transversalis fascia, ending as a pelvic fascia covering the pelvic musculature.<sup>6,7</sup>

From a neurological point of view, the tentorium cerebelli innervated by the first roots of the cervical plexus, the vagus nerve and the hypoglossal nerve, as well as the trigeminal nerve; the cranial nerves mentioned involve the motility of the tongue.<sup>8</sup> The phrenic nerve connects to the cited nerves, thanks to the presence of the ansa cervicalis, constituting anastomosis with the stellate ganglion (thoracic outlet).<sup>6,7</sup> The bulbar breath centers regulate the movement of the tongue, diaphragm and pelvic floor musculature during inhalation and exhalation, with a movement of retrusion and protrusion of the tongue, ascent and descent of the diaphragm and pelvic floor, respectively.<sup>6,7</sup>

To our best knowledge, this is the first case report that uses osteopathic treatment in a patient with sternal pain associated with an undergoing cardiac transplantation.

## Case presentation

A patient was admitted to our cardiorespiratory department on January 2019 to start a rehabilitation program. The patient (54 years old, male, white race and retired) with an active lifestyle (daily walks) and no particular dietary alterations, no significant genetic alteration known and without comorbidity. The patient had undergone an artificial heart transplant, HeartMate III LVAD as a bridge to candidacy, 5 years before undergoing a heart transplant. The reasons for this artificial heart are related to continuous heart failure, due to previous inoperable stenoses (stenosis on small caliber coronaries) and a probable previous infant rheumatic disease.

In the months leading up to heart transplant surgery, the patient had been treated with antibiotics to reduce the infection derived from the drive line: *Corynebacterium striatum* and *Staphylococcus aureus*. The patient was also positive by rectal swab for *Acinetobacter baumannii*. The patient underwent a heart transplant in November 2018.

In the postoperative course, cordarone was used for supraventricular tachyarrhythmias that were resolved. The first three biopsies revealed a gradual improvement. The first endomyocardial biopsy (EMB) revealed a moderate grade rejection (2R) treated with methylprednisolone. The second EMB revealed lymphoid aggregates in 2/3 of the

fragments, with mild rejection (1R). The third EMB showed a mild rejection (type 1) on two fragments. The following two EMBs revealed no evidence of rejection. In our department, clinical examinations as the echocardiography showed a small amount of pleural effusion, a normal left ventricular size and a preserved ejection fraction; minimal pericardial effusion. The electrocardiogram signaled a right bundle branch block with a heart rate of 90 beats per minute, a blood pressure level of 135 over 85 (135/85) and an oxygen saturation of 97%. Blood tests reported a low white blood cell count (3.18), a low lymphocyte count (0.74) and a postoperative anemia (hematocrit =29,1 and hemoglobin =9,6), hepatic and renal function gradually improved, gamma glutamyl transferase (30), bilirubin (0.75) and creatinine (1.74). Radiographs showed elevation of the left hemidiaphragm associated to the mild left pleural effusion, partially organized in the posterior basal area, in absence of signs of overload (Figure 1).

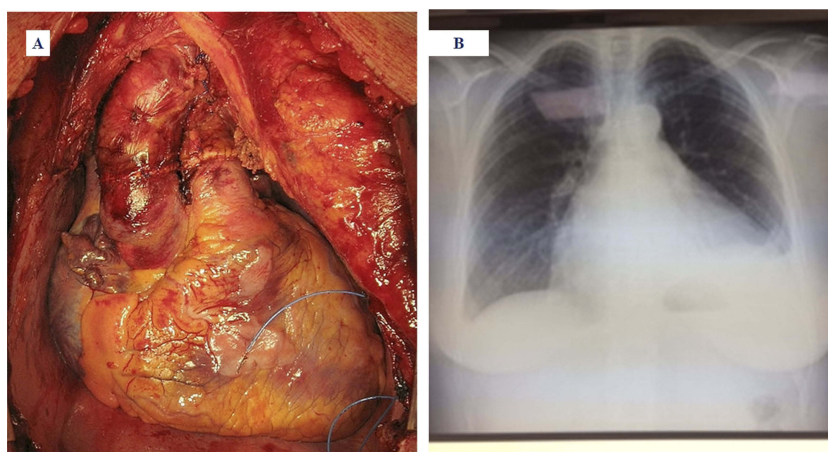
The pharmacological treatment in our department was as follows: Furosemide Teva 25 mg (1 tablet); Augmentin 1 g (3 tablets); 100 mg acetylsalicylic acid (1 tablet); KCL retard 600 mg (2 tablets); magnesium 2,25 g (2 sachets); Myfenax - mycophenolate mofetil 500 mg (2 tablets); Natecal 600 mg +400UI (1 tablet); omeprazole 20 mg (1 tablet); Sandimmun 100 mg (2 tablets); Stilnox 10 mg (1 tablet); Zolof 50 mg (1 tablet).

Laboratory tests showed no glycemc abnormalities or elevated glycate values, as well as no abnormal thyroid function. The patient did not carry out tests such as electromyography, as the motility of the limbs did not present anomalies. Routine examinations, such as X-rays or MRI, did not show any somatic or neurological structural

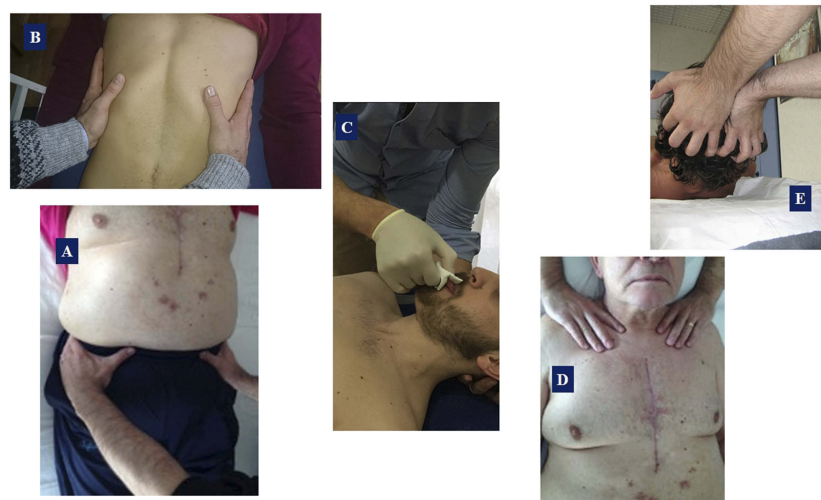anomalies. From the examinations carried out by the psychologist (Coping Orientation for Problem Experiences, Medical Outcomes Study Short-Form 36, Hospital Anxiety and Depression Scale), no behavioral or mood anomalies emerged.

The patient was unable to perform physiotherapy (gymnastics and exercise bike) because he complained of a neuropathic pain in the mediastinum, in an undefined area on the left side of the sternum (by 4th to 6th rib), compounded by breathing, limb movements and trunk rotations. His VAS pain assessment was 8, during movement and with forced breathing. The breastbone was perfectly closed. A cotton pad on the painful sternal area was used to evaluate superficial stimulation discrimination and epicritic sensitivity; a pin for pain assessment was used with slight pressure on the painful area; for the thermal sensitivity we used a test tube with hot water (40–50°C), passing it on the sore skin. The patient had an unaltered sensitivity, in the absence of allodynia, hypoalgesia, hyperalgesia or hypoesthesia. The patient always scored 8 to the numeric rating scale, which means the presence of pain during the evaluations. The patient gave his informed consent for the publication of the pictures and the treatment. The institutional approval was not required and it was not necessary to publish the case report. It was decided to administer ibuprofen 600 mg for 2 tablets a day. After a week, the VAS score fell to 7, but he still could not do physiotherapy.

Considering the positive results of the previous trial and a previous case report on the reduction of pain in patients suffering a sternotomy, we decided to submit the patient to the same number of sessions, that is, an OMT



**Figure 1** The picture shows a heart transplantation (sternotomy) with autologous pericardium (A) and our patient in position for a standard PA (posterior-anterior) chest x-ray (B).



**Figure 2** The figure shows the approach to the pelvic floor anteriorly (A); the approach to the respiratory diaphragm (B); the position for the treatment of the thoracic outlet (C); the position for the treatment of the tongue (D); the position of the operator's fingers for the treatment of the tentorium cerebelli (E).

session for 5 days. Considering that the 5 diaphragms involve the body system in a more global way, it was decided to opt for the latter strategy.

## Osteopathic treatment

The osteopathic treatment involved the pelvic floor or pelvic diaphragm, the diaphragm, the thoracic outlet, the tongue and the tentorium cerebelli. The osteopathic approach was fascial unwinding and the patient on supine position.

For the pelvic floor, the osteopath placed his hands on the iliac crests, with a slight pressure toward the table to find a normal balance of tension between the wings of ilium, assuming they were in the right mechanical connection to sacrum. The technique was considered successful when the wings of ilium had the same tension and thickness, whether during a manual pressure toward the table or assessing the sacroiliac joint.

For the diaphragm, the osteopath placed his hands on the ribcage, in the posterolateral part of the diaphragm. The technique was considered successful when the movement perceived was homogeneous.

For the thoracic outlet, hands were placed to involve the clavicle (index and middle finger) and the first thoracic vertebra (with thumbs); the operator was behind the table, working behind the patient supine. The technique ended when the tissues perceived under the hands showed no anomalous tensions.

For the tongue, using a gauze, the operator grasped the tongue with his fingers and gently pulled toward the ceiling,

just for a few millimeters. He maintained the position until the perceived tension decreased, and the tongue had no preferential vectors.

For the tentorium cerebelli, the osteopath placed the fingers behind the patient's head, following a line between Asterion and the external occipital protuberance (Inion). He maintained the position until he perceived a release of tissue tension. The operator was behind the table.

The techniques have been performed following the sequence described and they have been repeated for 5 days (Figure 2).

The 6th day, the cutaneous evaluations were repeated, without getting worse. The VAS score fell to 3 during limb movements, trunk rotations and breathing exercises. The patient could start the rehabilitation, maintaining anti-inflammatory therapy but reducing the dose to 1 tablet a day.

After a 3-week follow-up, the VAS score remained 3 and he stopped taking painkillers.

No adverse events occurred during and after treatment.

## Discussion

Postoperative sternal pain is a common event and usually is defined as post-sternotomy pain syndrome (PSPS). The exact etiology of PSPS is unknown.<sup>4</sup> Probably, in this specific case and as described in a previous paper, adhesions may have caused the sternal pain. The adhesions formed following thoracic surgery may reduce the capacity of tissues to slide past one another, causing an inflammatory environment and the production of further tissue.<sup>4</sup> The



adhesions cannot be evaluated by X-rays and ultrasound or other clinical tests identify them with great difficulty. Generally, the surgeon notices any formations of adhesions, and consequently, surgery can develop complications.

The adhesions are non-resilient formation of cicatricial tissue that involve different layers; they can be asymptomatic or can create side effects in patients; they create nociceptors, altering the mechanical properties of fascial tissues and altering the mechanotransduction of the surrounding tissues.<sup>9,10</sup>

We have chosen to use a global approach to the patient to get the maximum benefit: fascial techniques can reduce pain, inflammatory cytokines and also reduce nociceptive afferents.<sup>4,5,9</sup>

In this case report, we treated the 5 diaphragms of the osteopathic medicine.<sup>6,7</sup>

Probably in this patient, adhesions involved the pericardium and the respiratory diaphragm, already connected by the fascial area of the diaphragm, in a nonphysiological behavior. A healthy diaphragm stabilizes the spine and allows both lateral bending or torsion of the spine and also limbs movements.<sup>9</sup> Instead, a diaphragm muscle in a nonphysiological behavior, as the presence of adhesions or unilateral elevations, creates a motor incoordination and can cause other disorders: as, for example, cervicalgia, swallowing disorders, thoracic outlet syndrome, functional alterations of the pelvic floor and even chronic pain.<sup>9-11</sup>

In the literature and in the osteopathic field, some authors have worked with patients undergoing cardiac surgery (coronary artery bypass graft, CABG). One study applied osteopathic techniques to patients immediately postintervention (10 patients), with results that highlighted improvements in respiratory (saturation) and hemodynamic parameters.<sup>12</sup> Another study treated 17 patients who underwent CABG with different osteopathic techniques; the experimental group following osteopathy were discharged earlier, compared to the control group patients, with an average of about 0.55 days earlier.<sup>13</sup> Probably, the systemic clinical picture, as in our previous trial, improved more quickly.<sup>5</sup>

We have thus chosen to work on the 5 diaphragms to affect both the fascial system and the neurological aspects, trying to restore motion and provides pain relief. The fascial treatment stimulates the parasympathetic system, decreasing tissue tone; this would allow tissues to slide past one another, creating an optimal mechano-metabolic environment, reducing nociceptive afferents and inflammatory cytokine responses.<sup>4</sup> The parasympathetic nervous

system indirectly stimulates the limbic system through the solitary nucleus, to increase pain threshold.<sup>10</sup>

The limitation of the case report is the absence of higher patient numbers.

Further studies will be needed to better identify the positive motivations that helped the patient.

## Conclusion

The case report presents a patient with chest pain after cardiac transplantation, considerably reduced with a fascial OMT approach. The patient was in our cardiorespiratory department to start a program of cardiovascular rehabilitation, and thanks to the osteopathic approach to the 5 diaphragms, the patient accessed to the cardiovascular rehabilitation program as other patients. To our best knowledge, this is the first case report that uses OMT and the 5 diaphragms for this pathological condition. This case report does not report any adverse event of the patient treated with osteopathy. The clinical importance of the case report is added to other osteopathic research with patients undergoing cardiac surgery (coronary artery bypass graft) and with multiple benefits.

## Disclosure

The authors report no conflicts of interest in this work.

## References

1. Lee SJ, Kim KH, Hong SK, Hankins S. Evaluation of a heart transplant candidate. *Curr Cardiol Rep.* 2017;19(12):133. doi:10.1007/s11886-017-0934-y
2. Lund LH, Edwards LB, Kucheryavaya AY, et al. The registry of the International Society for Heart and Lung Transplantation: thirty-second official adult heart transplantation report—2015; focus theme: early graft failure. *J Heart Lung Transplant.* 2015;34(10):1244–1254. doi:10.1016/j.healun.2015.08.003
3. Tackmann E, Dettmer S. Health-related quality of life in adult heart-transplant recipients – a systematic review. *Herz.* 2018. doi:10.1007/s00059-018-4745-8
4. Bordoni B, Marelli F, Morabito B, Sacconi B, Severino P. Post-sternotomy pain syndrome following cardiac surgery: case report. *J Pain Res.* 2017;10:1163–1169. doi:10.2147/JPR.S129394
5. Racca V, Bordoni B, Castiglioni P, Modica M, Ferratini M. Osteopathic manipulative treatment improves heart surgery outcomes: a randomized controlled trial. *Ann Thorac Surg.* 2017;104(1):145–152. doi:10.1016/j.athoracsur.2016.09.110
6. Bordoni B, Zanier E. Anatomic connections of the diaphragm: influence of respiration on the body system. *J Multidiscip Healthc.* 2013;6:281–291. doi:10.2147/JMDH.S45443
7. Bordoni B, Zanier E. The continuity of the body: hypothesis of treatment of the five diaphragms. *J Altern Complement Med.* 2015;21(4):237–242. doi:10.1089/act.2015.29031.hme
8. Bordoni B, Morabito B, Mitrano R, Simonelli M, Toccafondi A. The anatomical relationships of the tongue with the body system. *Cureus.* 2018;10(12):e3695.

9. Bordoni B, Marelli F. Failed back surgery syndrome: review and new hypotheses. *J Pain Res.* 2016;9:17–22. doi:10.2147/JPR.S96754
10. Bordoni B, Zanier E. Skin, fascias, and scars: symptoms and systemic connections. *J Multidiscip Healthc.* 2013;7:11–24. doi:10.2147/JM.DH.S52870
11. Bordoni B, Marelli F, Morabito B, Sacconi B. Depression, anxiety and chronic pain in patients with chronic obstructive pulmonary disease: the influence of breath. *Monaldi Arch Chest Dis.* 2017;87(1):811. doi:10.4081/monaldi.2017.811
12. O-Yurvati AH, Carnes MS, Clearfield MB, Stoll ST, McConathy WJ. Hemodynamic effects of osteopathic manipulative treatment immediately after coronary artery bypass graft surgery. *J Am Osteopath Assoc.* 2005;105(10):475–481.
13. Wieting JM, Beal C, Roth GL, et al. The effect of osteopathic manipulative treatment on postoperative medical and functional recovery of coronary artery bypass graft patients. *J Am Osteopath Assoc.* 2013;113(5):384–393.

### International Medical Case Reports Journal

Dovepress

### Publish your work in this journal

The International Medical Case Reports Journal is an international, peer-reviewed open-access journal publishing original case reports from all medical specialties. Previously unpublished medical posters are also accepted relating to any area of clinical or preclinical science. Submissions should not normally exceed 2,000 words or 4

published pages including figures, diagrams and references. The manuscript management system is completely online and includes a very quick and fair peer-review system, which is all easy to use. Visit <http://www.dovepress.com/testimonials.php> to read real quotes from published authors.

Submit your manuscript here: <https://www.dovepress.com/international-medical-case-reports-journal-journal>