



## Original Article

# Keblish's lateral surgical approach enhances patellar tilt in valgus knee arthroplasty<sup>☆</sup>



José Roberto Tonelli Filho\*, Marcus Ceregatti Passarelli, João Alberto Salles Brito, Gustavo Constantino Campos, Alessandro Rozim Zorzi, João Batista de Miranda

Universidade Estadual de Campinas (Unicamp), Faculdade de Ciências Médicas, Departamento de Ortopedia e Traumatologia, Campinas, SP, Brazil

## ARTICLE INFO

## Article history:

Received 30 January 2016

Accepted 15 February 2016

Available online 25 October 2016

## Keywords:

Knee

Osteoarthritis

Arthroplasty

Patella

## ABSTRACT

**Objective:** To compare the clinical and radiological outcomes of conventional medial and lateral approaches for total knee replacement in the valgus osteoarthritic knee.

**Methods:** In this randomized controlled trial, 21 patients with valgus knee osteoarthritis were randomized to total knee replacement through medial or lateral approach. The primary outcome was radiographic patellar tilt. Secondary outcomes were visual analog scale of pain, postoperative levels of hemoglobin, and clinical aspect of the operative wound.

**Results:** There were no differences between the groups regarding other clinical variables. Mean lateral tilt of the patella was 3.1 degrees (SD ± 5.3) in the lateral approach group and 18 degrees (SD ± 10.2) in the medial approach group ( $p=0.02$ ). There were no differences regarding the secondary outcomes.

**Conclusion:** Lateral approach provided better patellar tilt following total knee replacement in valgus osteoarthritic knee.

© 2016 Sociedade Brasileira de Ortopedia e Traumatologia. Published by Elsevier Editora Ltda. This is an open access article under the CC BY-NC-ND license (<http://creativecommons.org/licenses/by-nc-nd/4.0/>).

## Acesso lateral de Keblish melhora a inclinação da patela na artroplastia do joelho valgo

## RESUMO

**Objetivo:** Comparar os resultados clínicos e radiológicos da via de acesso convencional com artrotomia medial e da via de acesso lateral na prótese total primária em joelho valgo.

**Métodos:** Neste ensaio clínico prospectivo, 21 pacientes com osteoartrite e deformidade em valgo foram divididos aleatoriamente em dois grupos de acordo com a via de acesso cirúrgico usada: medial ou lateral. O desfecho principal foi a medida radiográfica da inclinação lateral

## Palavras-chave:

Joelho

Osteoartrite

Artroplastia

Patela

<sup>☆</sup> Study conducted at Hospital de Clínicas, Universidade Estadual de Campinas (Unicamp), Campinas, SP, Brazil.

\* Corresponding author.

E-mail: [joserobertotonelli@gmail.com](mailto:joserobertotonelli@gmail.com) (J.R. Tonelli Filho).

<http://dx.doi.org/10.1016/j.rboe.2016.10.010>

2255-4971/© 2016 Sociedade Brasileira de Ortopedia e Traumatologia. Published by Elsevier Editora Ltda. This is an open access article under the CC BY-NC-ND license (<http://creativecommons.org/licenses/by-nc-nd/4.0/>).

da patela. Outros desfechos foram a dor após a cirurgia (escala visual de dor), o sangramento (níveis séricos de hemoglobina) e o aspecto clínico da ferida operatória.

**Resultados:** Não houve diferença entre os grupos em relação a outras variáveis clínicas. A inclinação lateral média da patela no grupo lateral foi 3,1 graus  $\pm$  5,3 DP e no grupo medial foi 18 graus  $\pm$  10,2 DP ( $p=0,02$ ). Os outros desfechos não apresentaram diferenças entre os grupos.

**Conclusão:** A via lateral proveu melhor inclinação lateral da patela pós-operatória nas artroplastias do joelho valgo.

© 2016 Sociedade Brasileira de Ortopedia e Traumatologia. Publicado por Elsevier Editora Ltda. Este é um artigo Open Access sob uma licença CC BY-NC-ND (<http://creativecommons.org/licenses/by-nc-nd/4.0/>).

## Introduction

Approximately 10% of patients undergoing total knee arthroplasty have a valgus deformity, defined as a valgus alignment of the anatomical axes of the femur and tibia in the frontal plane greater than ten degrees.<sup>1</sup> In these cases, the results are considered less satisfactory when compared with patients who have varus knees.<sup>2-5</sup>

The standard access route in total knee arthroplasties is the medial parapatellar arthrotomy.<sup>6,7</sup> The lateral parapatellar approach described by Keblish<sup>2</sup> allows for a better exposure of the lateral and posterolateral structures, which are contracted in valgus deformities and should be released for proper ligament balance; it also has the advantage of including the release of lateral patellar retinaculum, which is necessary in most cases with valgus deformity.<sup>2,8</sup>

Although some authors recommend the use of the lateral access route in cases of fixed valgus deformities of the knee,<sup>8,9</sup> there is no consensus in the literature regarding the best approach for total arthroplasties in valgus knees.<sup>8,10</sup>

This prospective study aimed to compare the results of medial parapatellar access route (classical) and the lateral parapatellar approach (Keblish) in patients with valgus knees, in order to demonstrate the best correction of patellar tilt.

## Material and methods

Detailed explanations of the procedure and research protocol were given to 21 patients with advanced knee osteoarthritis, referred from the basic network of the Brazilian Unified Health System (Sistema Único de Saúde [SUS]) to a university hospital for total arthroplasty surgery. All patients agreed to participate and signed an informed consent form. The study protocol and the informed consent form were approved by the local Research Ethics Committee (CEP; opinion No. 381113 of August 27, 2013).

### Inclusion criteria

- Patients of both genders, between 50 and 75 years, diagnosed with knee osteoarthritis and valgus deformity.
- Indication of total knee arthroplasty due to failure of conservative treatment.
- Having understood, accepted, and signed the consent form.

### Exclusion criteria

- Arthroplasty revision surgery.
- Extra-articular deformities not related to osteoarthritis.
- Previous infection in the knee.
- Severe comorbidity with anesthetic contraindication.
- Inability to understand or sign the consent form.

The study was registered at ClinicalTrials.gov (NCT01965886).

### Allocation

Two groups were created: lateral and medial. A computer program ([www.randomization.com](http://www.randomization.com)) generated a random sequence, divided into blocks of six units, with three indications for each group in each block to avoid the accumulation of a single group at the beginning or at end of the study, as well as the effect of the surgeons' learning curve.

### Blinding

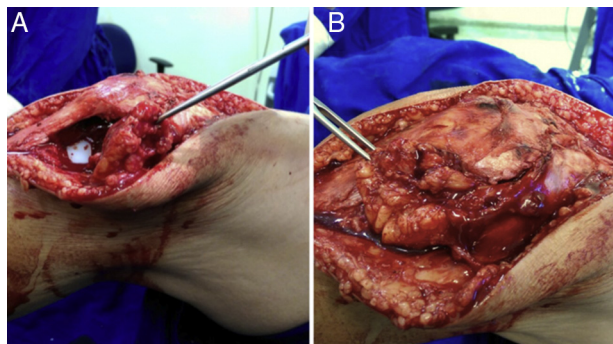
Each of these indications was kept in a box with sealed envelopes in the possession of an operating room nurse who did not participate in the study. In the operating room, after skin incision, the envelope was opened to indicate the group to which the patient had been allocated.

### Interventions

- Lateral group: lateral parapatellar access route and soft tissue ligament balance as described by Keblish,<sup>2</sup> preserving a flap of fat (Fig. 1) for closing the unstressed joint capsule.
- Medial group: conventional medial parapatellar access route and soft tissue ligament balance in the classic sequence.<sup>1</sup>

### Surgical technique

All cases were operated in the same operating room by two board certified knee surgeons (JRTF and MCP) by the Brazilian Society of Orthopedics and Traumatology (Sociedade Brasileira de Ortopedia e Traumatologia [SBOT]), always with supervision of one of the senior surgeons of the service (GCC, ARZ, JBM). The type of anesthesia was defined by the anesthesia team. All patients received infection prophylaxis with



**Fig. 1 – Illustration of the surgical technique using Keblish's access route, demonstrating the Hoffa fat flap needed for closure without tension of the joint capsule. A, the fat flap is attached to the lateral border of the capsule; B, fat is used to cover the defect in the capsule.**

a single intravenous dose of cefazolin 2 g, 30 min before the anesthetic induction. A pneumatic tourniquet on the thigh (300 mmHg) was used in all cases.

The longitudinal incision in the skin was the same in all cases. At that point, the envelope seal was broken and the type of intervention to be performed was revealed, as described in the previous section. The sequence of guides and bone cuts was the same. The prosthesis (Modular III, MDT, Rio Claro, São Paulo, Brazil) and the orthopedic cement (Cemfix, Teknimed, France) were the same in all cases. In some cases, rods or wedges from the prosthesis were necessary. No case required constrained or semi-constrained prosthesis. Whenever possible, the patellar component was used. In all cases, 24-hour suction drain and Robert Jones bandage were used on the first day.

### Rehabilitation

All patients received prophylaxis for thromboembolic events with mechanical (early mobility and elevation of the limb) and pharmacological methods (low molecular weight heparin by subcutaneous injection in a prophylactic dose suitable for the patient's weight) for 15 days.

All patients were hospitalized for three days after surgery, and received training for walking with a walker. Then, outpatient follow-up was performed twice a week in the physiotherapy service of the same hospital in which they were operated, with the same rehabilitation protocol.

### Outcomes

- Visual pain scale (0–100) was applied by a staff member blinded to the allocation of groups in the first three days after surgery, while the patients were in the ward, according to validated technique.<sup>11</sup> For the statistical analysis, the mean of these three measures for each case was used.
- Serum hemoglobin levels were collected on the day before and on the day after the surgery. The difference between these two values was used to determine the reduction in serum hemoglobin and thereby estimate the bleeding.

Patients who received transfusion of red blood cells or other blood products were excluded.

- Appearance of the surgical wound one week after the procedure.
- Functional scales were applied twice a year by examiners blinded to the allocation of groups: the Knee Society Score (KSS),<sup>12</sup> the Western Ontario and McMaster Universities Arthritis Index (WOMAC),<sup>13</sup> and the Kujala Scale<sup>14</sup>; were applied twice a year by examiners blinded to the allocation of groups.
- Alignment of the operated limb in the frontal orthostatic panoramic radiography, bipedal, six months after surgery, through the method of anatomical axes of the femur and tibia in the frontal plane.<sup>15</sup>
- Patellar tilt in the axial radiography six months after surgery, according to the technique previously described<sup>16</sup> (Fig. 2).

### Statistical analysis

This pilot study was conducted to determine the sample size necessary to compare the results of total arthroplasties in knees with valgus deformity via lateral and medial access, with statistical power of 80% and 5% significance level.

The quantitative variables were presented as means and standard deviations (SD). The qualitative variables were presented as absolute frequencies. All significant values were presented as two-tailed. The significance level was set at  $p < 0.05$ .

To determine whether the data followed a standard normal distribution, the Kolmogorov-Smirnov test was used. The means of the quantitative variables were compared by Student's t-test for independent samples, when the parametric conditions were met, or by the Mann-Whitney test, when the variable did not present normal distribution. The frequencies of the qualitative variables were compared by Pearson's chi-squared test or Fisher's exact test.

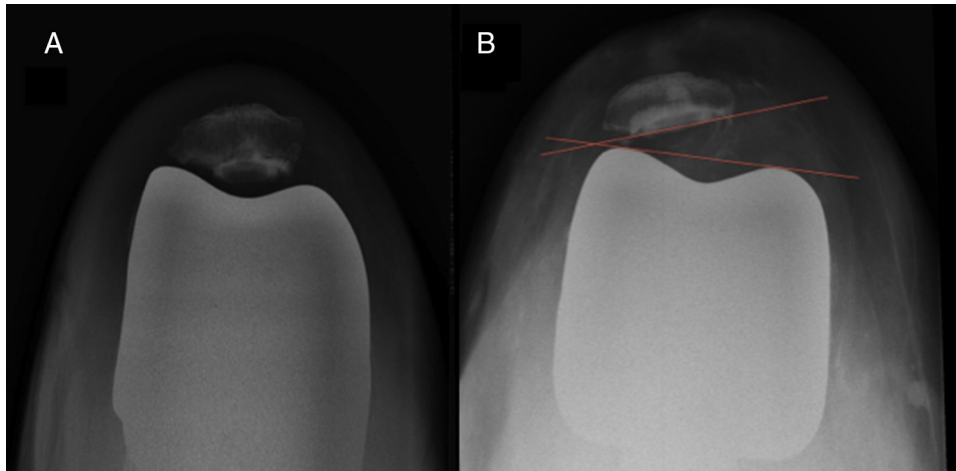
The statistical analyses were performed with IBM SPSS Statistics (Version 22.0. Armonk, NY: IBM Corp.).

### Results

All patients invited agreed to participate and signed the consent form. All patients completed the follow-up (Fig. 3).

The analysis of clinical data of patients in this sample ( $n = 21$ ) demonstrated that the random allocation process was efficient in the creation of two homogeneous groups, with no differences in other variables, such as age, weight, body mass index (BMI), gender, operated side, cause of the deformity, magnitude of the deformity, passive reducibility of the deformity with stress maneuver in varus, surgical time, and Krakow classification for osteoarthritis with valgus deformity (Table 1). The mean valgus deformity before surgery, measured by the intersection of the anatomical axes of the femur and tibia in the frontal plane, was 18.7 degrees  $\pm$  7.2 SD in the lateral group and 25.7 degrees  $\pm$  12.8 SD in the medial group ( $p = 0.197$ ).

The functional assessment with clinical scales before surgery did not differ between groups: the mean WOMAC score in the lateral group was 54.9  $\pm$  12.8 SD and in the medial group, 57.9  $\pm$  15.8 SD ( $p = 0.654$ ); the mean KSS was 29.8  $\pm$  20.3



**Fig. 2 – Illustration of the method used to measure patellar tilt on the radiograph. A: normal tilt; B: increased lateral tilt.**

SD in the lateral group and, in the medial group,  $34.4 \pm 15.3$  SD ( $p=0.605$ ); the mean functional KSS was  $42.5 \pm 18.6$  SD in the lateral group and  $49.6 \pm 19.2$  SD in the medial group ( $p=0.468$ ); the mean Kujala score in the lateral group was  $40.9 \pm 7.5$  SD and in the medial group,  $39.1 \pm 9.7$  SD ( $p=0.557$ ).

A subjective evaluation of the surgical wound one week after surgery showed no difference between groups. In the lateral group, six patients presented wounds as expected; three, better than expected; and one, worse than expected. In the medial group, seven patients presented wounds as expected; two, better than expected; and two, worse than expected ( $p=0.754$ ).

Postoperative pain was lower in the lateral group (Fig. 4), but it was not possible to demonstrate a statistically significant difference ( $p=0.705$ ), as the sample size was insufficient (power = 25%). It would take 32 subjects in each group to find a difference between the means of 10 points.

Bleeding, estimated by the decrease in serum hemoglobin levels, was very similar between groups (Fig. 5).

The most important finding of this study was that the lateral patellar tilt in the lateral access group was lower ( $p=0.02$ ; Fig. 6).

## Discussion

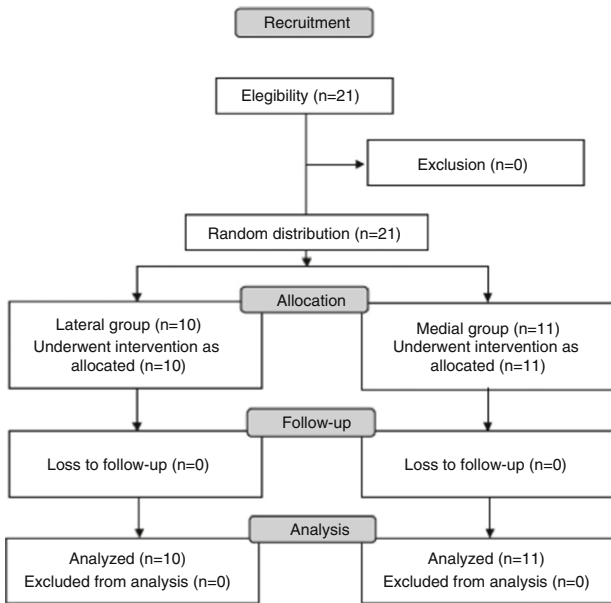
This study compared the medial and lateral access routes to total primary arthroplasty in valgus knees. The main result was the more efficient correction of the axial patellar tilt observed in the group who underwent surgery through Keblish's parapatellar lateral access route. This is the first prospective, randomized clinical trial comparing these techniques that includes the assessment of the postoperative correction of the patellar tilt.

The parapatellar lateral arthrotomy was proposed in 1991 by Keblish<sup>2</sup> as an option to the classic medial parapatellar arthrotomy in cases of osteoarthritis of the knee with valgus deformity. This approach allows for a direct access to the lateral knee structures, which are generally those that are strained and require release.<sup>17</sup> However, the lateral access route is not used by most surgeons, probably due to their unfamiliarity with the procedure, which can lead to technical difficulties and increased surgical time. Another concern is the difficulty of exposure and soft tissue coverage at closing.<sup>18</sup>

**Table 1 – Clinical characteristics of patients undergoing knee arthroplasty with valgus deformity.**

Group		Lateral (n=10)	Medial (n=11)	p
Age (years)		62.9 ± 9.1	62.6 ± 10.6	0.912
Weight (kg)		78.1 ± 12.4	78.1 ± 13.7	1.000
BMI		29 ± 3.9	30.1 ± 3.9	0.552
Surgical time (min)		124.3 ± 19.5	105.5 ± 28.1	0.114
Genre	Male	1	1	0.943
	Female	9	10	
Side	Right	4	8	0.130
	Left	6	3	
Reducibility	Yes	8	7	0.635
	No	2	4	
Krakow classification	1	8	7	0.635
	2	2	4	
Cause	Primary OA	7	6	
	Reumatological	3	5	

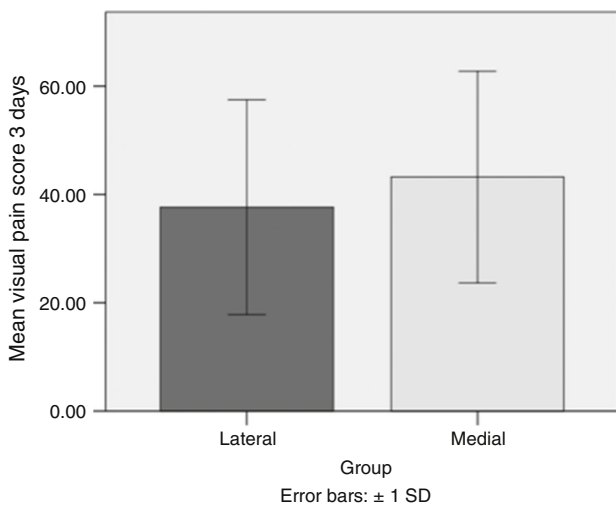
BMI, body mass index.



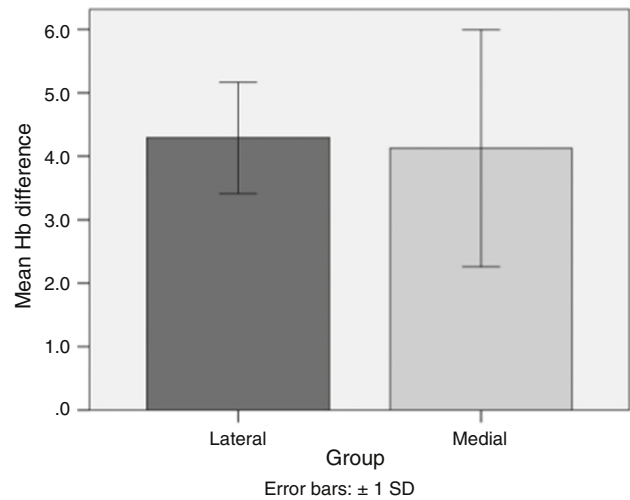
**Fig. 3 – Flow diagram – Consolidated Standards of Reporting Trials (Consort).**

To overcome the difficulty of exposure or even to avoid a catastrophic tearing of the patellar tendon, some authors recommend the routine association of osteotomy of the anterior tibial tuberosity (ATT) to the lateral approach.<sup>2,19</sup> ATT osteotomy, however, can be a factor for increased complications and risk of revision surgery,<sup>10,20</sup> and it was not necessary in the cases operated in the present study.

The literature shows similar results between the two techniques in relation to the post-operative alignment in the coronal plane.<sup>17,21,22</sup> Some studies point to a better postoperative range of motion using the lateral approach.<sup>21,23</sup> Another advantage is the possibility of using common implants (non-constricted), while the knee valgus operated using medial



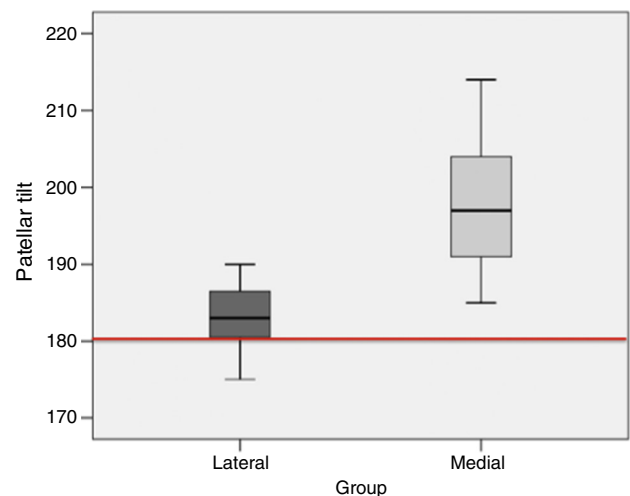
**Fig. 4 – Bar graph comparing the mean visual pain score. Lateral group = 37.66 ± 19.8 SD; medial group = 43.22 ± 19.5 SD; p = 0.705.**



**Fig. 5 – Bar graph comparing the mean blood loss estimated by the difference in hemoglobin serum levels before and after surgery. Lateral group = 4.29 ± 0.88; medial group = 4.13 ± 1.87; p = 0.512.**

access route tends to more often require implants with larger constriction.<sup>22</sup> Furthermore, a major advantage of the lateral approach over the medial is to avoid opening both retinacula of the patella, since many cases of valgus knee require release of the lateral retinaculum to correct the course of the patella. Lateral release after a medial parapatellar approach is not desired, due to the risk of devascularization of the patella and patellar tendon.

Patellofemoral instability is a major cause of pain and functional limitation in the postoperative period of total knee prosthesis implantation, and can even lead to the need for



**Fig. 6 – Box diagram comparing the mean lateral patellar tilt after arthroplasty. Values above 180 degrees indicate a lateral tilt; below 180 degrees, medial tilt. Lateral group = 183.1 ± 5.3 SD; medial group = 198 ± 10.2 SD; p = 0.02.**



revision surgery.<sup>24,25</sup> The lateral approach has been proven to more easily fix patellar tilt in patients with osteoarthritis in valgus, who generally present retraction and even lateral subluxation of the patella. The present study, even with a small number of cases, demonstrated a better correction of the patellar tilt in patients who underwent surgery through the lateral approach. The authors will continue the study to assess whether this difference in patellar tilt will result in a clinical benefit, which will be evaluated by KSS, WOMAC, and Kujala scores.

Although a trend was observed, there was no difference between groups regarding bleeding and pain in the immediate postoperative period, as well as in the comparison between the clinical appearance of the wound in the first days after the procedure. However, the authors believe that there is a type 2 error due to the still insufficient number of patients for these other variables, which will be corrected as the study progresses. In theory, an incision on just the lateral retinaculum should hurt and bleed less. The ease of exposure and lower need for tissue release may also favor a lower trauma to the soft tissue, with better wound aspect.

The present study had some limitations. Firstly, this was a pilot study with a small number of patients. Nonetheless, very interesting results regarding the correction of the patella tilt were observed. Secondly, there is no standard normal value for the angle between the patella and the trochlea of the knee prosthesis. The authors believe that the components must be parallel. Thirdly, this study used radiography to measure the patellar tilt. Despite being a method described in the literature,<sup>11</sup> the authors consider computed tomography to be the ideal method, which will be used in the continuation of the study.

## Conclusion

The lateral patellar tilt was lower in arthroplasties performed using Keblish's lateral access route in knees with valgus deformity. The continuation of this controlled clinical trial, with increasing number of cases and increased follow-up time, will demonstrate whether this finding has any impact on the clinical and functional outcomes of these arthroplasties.

## Conflicts of interest

The authors declare no conflicts of interest.

## REFERENCES

- Ranawat AS, Ranawat CS, Elkus M, Rasquinha VJ, Rossi R, Babhulkar S. Total knee arthroplasty for severe valgus deformity. *J Bone Joint Surg Am.* 2005;87 Suppl. 1:271-84.
- Keblish PA. The lateral approach to the valgus knee. Surgical technique and analysis of 53 cases with over two-year follow-up evaluation. *Clin Orthop Relat Res.* 1991;(271):52-62.
- Krackow KA, Jones MM, Teeny SM, Hungerford DS. Primary total knee arthroplasty in patients with fixed valgus deformity. *Clin Orthop Relat Res.* 1991;(273):9-18.
- Stern SH, Moeckel BH, Insall JN. Total knee arthroplasty in valgus knees. *Clin Orthop Relat Res.* 1991;(273):5-8.
- Elkus M, Ranawat CS, Rasquinha VJ, Babhulkar S, Rossi R, Ranawat AS. Total knee arthroplasty for severe valgus deformity. Five to fourteen-year follow-up. *J Bone Joint Surg Am.* 2004;86(12):2671-6.
- Whiteside LA. Selective ligament release in total knee arthroplasty of the knee in valgus. *Clin Orthop Relat Res.* 1999;(367):130-40.
- Engh GA. The difficult knee: severe varus and valgus. *Clin Orthop Relat Res.* 2003;(416):58-63.
- Satish BR, Ganesan JC, Chandran P, Basanagoudar PL, Balachandar D. Efficacy and mid term results of lateral parapatellar approach without tibial tubercle osteotomy for primary total knee arthroplasty in fixed valgus knees. *J Arthroplasty.* 2013;28(10):1751-6.
- Keblish PA. Alternate surgical approaches in mobile-bearing total knee arthroplasty. *Orthopedics.* 2002;25 2 Suppl.:s257-64.
- Hirschmann MT, Hoffmann M, Krause R, Jenabzadeh RA, Arnold MP, Friederich NF. Anterolateral approach with tibial tubercle osteotomy versus standard medial approach for primary total knee arthroplasty: does it matter? *BMC Musculoskelet Disord.* 2010;11:167.
- Carlsson AM. Assessment of chronic pain. I. Aspects of the reliability and validity of the visual analogue scale. *Pain.* 1983;16(1):87-101.
- Insall JN, Dorr LD, Scott RD, Scott WN. Rationale of the Knee Society clinical rating system. *Clin Orthop Relat Res.* 1989;(248):13-4.
- Fernandes MI [Dissertação] Tradução e validação do questionário de qualidade de vida específico para osteoartrose Womac (Western Ontario McMaster Universities) para a língua portuguesa. São Paulo: Escola Paulista de Medicina, Universidade Federal de São Paulo; 2003.
- Kujala UM, Jaakkola LH, Koskinen SK, Taimela S, Hurme M, Nelimarkka O. Scoring of patellofemoral disorders. *Arthroscopy.* 1993;9(2):159-63.
- Specogna AV, Birmingham TB, Hunt MA, Jones IC, Jenkyn TR, Fowler PJ, et al. Radiographic measures of knee alignment in patients with varus gonarthrosis: effect of weightbearing status and associations with dynamic joint load. *Am J Sports Med.* 2007;35(1):65-70.
- Gomes LS, Bechtold JE, Gustilo RB. Patellar prosthesis positioning in total knee arthroplasty. A roentgenographic study. *Clin Orthop Relat Res.* 1988;(236):72-81.
- Gunst S, Villa V, Magnussen R, Servien E, Lustig S, Neyret P. Equivalent results of medial and lateral parapatellar approach for total knee arthroplasty in mild valgus deformities. *Int Orthop.* 2016;40(5):945-51.
- Fiddian NJ, Blakeway C, Kumar A. Replacement arthroplasty of the valgus knee. A modified lateral capsular approach with repositioning of vastus lateralis. *J Bone Joint Surg Br.* 1998;80(5):859-61.
- Buechel FF. A sequential three-step lateral release for correcting fixed valgus knee deformities during total knee arthroplasty. *Clin Orthop Relat Res.* 1990;(260):170-5.
- Piedade SR, Pinaroli A, Servien E, Neyret P. Tibial tubercle osteotomy in primary total knee arthroplasty: a safe procedure or not? *Knee.* 2008;15(6):439-46.
- Sekiya H, Takatoku K, Takada H, Sugimoto N, Hoshino Y. Lateral approach is advantageous in total knee arthroplasty for valgus deformed knee. *Eur J Orthop Surg Traumatol.* 2014;24(1):111-5.
- Rawal J, Devany AJ, Jeffery JA. Arthroplasty in the valgus knee: comparison and discussion of lateral vs. medial parapatellar approaches and implant selection. *Open Orthop J.* 2015;9:94-7.
- Chalidis BE, Ye K, Sachinis NP, Hawdon G, McMahon S. Lateral parapatellar approach with tibial tubercle osteotomy for the

- treatment of non-correctable valgus knee osteoarthritis: a retrospective clinical study. *Knee*. 2014;21(1):204-8.
24. Malo M, Vince KG. The unstable patella after total knee arthroplasty: etiology, prevention, and management. *J Am Acad Orthop Surg*. 2003;11(5):364-71.
25. Petersen W, Rembitzki IV, Bruggemann GP, Ellermann A, Best R, Koppenburg AG, et al. Anterior knee pain after total knee arthroplasty: a narrative review. *Int Orthop*. 2014;38(2):319-28.