

Laparoscopic nephrectomy in a hemophilia B patient

Slawomir Gajda¹, Tomasz Szopiński², Andrzej B. Szczepanik¹, Roman Sosnowski³, Anna M. Szczepanik⁴

¹Department of Surgery, Institute of Hematology and Transfusion Medicine, Warsaw, Poland

²Department of Urology, Jagiellonian University, Cracow, Poland

³Department of Urooncology, M. Skłodowska-Curie Memorial Cancer Center and Institute of Oncology, Warsaw, Poland

⁴Department of Internal Medicine and Gerontology, Jagiellonian University, Cracow, Poland

Citation: Gajda S, Szopiński T, Szczepanik AB, Sosnowski R, Szczepanik AM. Laparoscopic nephrectomy in a hemophilia B patient. Cent European J Urol. 2016; 69: 271-273.

Article history

Submitted: May 14, 2016

Accepted: Aug. 23, 2016

Published online: Sept. 16, 2016

Corresponding author

Slawomir Gajda
Institute of Hematology
and Transfusion Medicine
Department of Surgery
14, Indiry Gandhi Street
00-776 Warsaw, Poland
phone: +48 505 163 007
slawogajda@gmail.com

Surgery in patients with hemophilia is a serious challenge. It requires a comprehensive approach, as well as careful postoperative monitoring. We present here the first case of a transperitoneal laparoscopic radical nephrectomy (TLRN) for renal cell carcinoma, of the clear-cell type, performed in a hemophilia B patient. The level of factor IX clotting activity before surgery and on postoperative days 1–6 was maintained at 65–130% and at 30–40% on subsequent days until healing of the post-operative wound was achieved. The intraoperative and postoperative courses were uneventful. TLRN can therefore be considered safe and effective for renal cell carcinoma. In hemophilia patients, the TLRN procedure requires proper preparation, as well as adequate substitution therapy for the deficient coagulation factor provided by a multidisciplinary team in a comprehensive center.

Key Words: laparoscopic radical nephrectomy ↔ hemophilia

CASE PRESENTATION

A 73 year-old patient with mild hemophilia B (factor IX clotting activity – 12%) was referred to our department due to a left renal tumor incidentally discovered during ultrasonography performed as follow-up two years after prostate cancer brachytherapy. On admission the patient reported no complaints. No abnormalities were found on physical examination. Blood pressure was 130/70 mmHg, heart rate 80/min and BMI 31. No abnormalities were found during morphological and biochemical investigations. Urine analysis revealed erythrocyturia. Abdominal and pelvic CT scans revealed a multilocal tumor in the lower left kidney pole (57x52x52 mm) with a solid mass of 3.5 cm in diameter (Figure 1). Other abdominal and chest imaging showed no abnormalities. The patient was qualified for left laparoscopic nephrectomy. Twelve hours before surgery, he was transfused with 4200 units of factor IX con-

centrate (Octanine[®], Octapharma AG, Switzerland), with the same dose administered one hour prior to the procedure. Factor IX clotting activity was determined to be at 134% of the normal value. On October 3rd of 2014, the procedure was performed with the patient positioned on his right side. Following urinary catheterization, a Veress needle was introduced close to the umbilicus and an intraperitoneal pressure of 14 mmHg was created. Four ports, two 10 mm and two 5 mm, were then inserted. The descending colon was dissected and the fat renal capsule subsequently cut for access to the left renal artery. The artery was then clipped with polymeric clips (Hem-o-Lok[®] XL (Teleflex, USA) and cut in between. The same was done for the renal vein. The spermatic vessels and ureter were secured with clips and cut. The kidney was excised, placed into a HemoBag[®] (Covidien, USA) and removed through a small incision between the two ports. A plastic drain was placed into the kidney bed and the abdominal wall

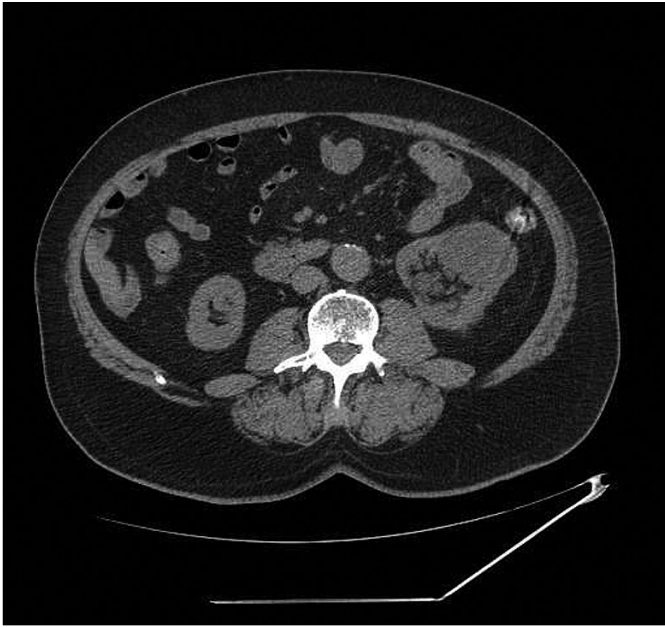


Figure 1. Computed tomography scan revealed a left kidney tumor mass.

was closed with layers of sutures. The surgery time was 170 min. Peritoneal drainage was kept in place for two days with no significant output of blood or serous fluid. Factor IX concentrate transfusions were performed with 3600–6000 units per day. The total amount of administered factor IX was 46800 units. Substitution therapy was continued for 9 days with the level of factor IX clotting activity at 90–130% of the normal value on days 1–3, 65–74% on days 4–6 and 30–40% on days 7–9. The postoperative course was uneventful and the patient was discharged on 10th day after surgery. Histopathological investigation revealed renal carcinoma, clear cell type (G2), limited to the parenchyma, without capsule infiltration or angioinvasion. The patient was followed up for 16-months following the operation. He reported no complains. No abnormalities were revealed in ultrasonography and CT scans.

DISCUSSION

Hemophilia B (Christmas disease) is a congenital bleeding disorder resulting from factor IX deficiency. Hemophilia B patients undergoing surgical procedures are at a high risk of severe bleeding complications unless surgery is performed after adequate correction of the diathesis [1]. Secure hemostasis in hemophilia B patients is achieved with transfusions of factor IX coagulation factor concentrate,

either recombinant or plasma-derived. Desirable preoperative activity is 60–80% of the normal value and should be maintained until complete wound healing, usually through 7–10 days. On days 1–3 the recommended value is 60–80%, on days 4–6 40–60% and 30–40% on days 7–10 [2].

Minimally invasive procedures in patients with hemophilia, apart from well-known benefits such as reduced postoperative pain, fewer complications, better cosmetic effect, shorter hospitalization, quicker convalescence and return to professional activity, also contribute to shorter duration of substitution therapy. The first laparoscopic nephrectomy was performed by Clayman et al. in 1990 [3]. Since then, the procedure has been performed in an increasing number of urologic centers [4, 5]. There are only few reports in the literature of urinary tract operations in patients with congenital coagulation disorders [6, 7]; nonetheless, there have been none of laparoscopic nephrectomy in a hemophilia patient. We present the first case of laparoscopic nephrectomy in a hemophiliac performed with an adrenal-saving, transperitoneal lateral approach using four trocars. No significant complications were observed either postoperatively or in the long-term, which can most likely be attributed to the adequate preparation of the hemophilia patient for surgery, as well as the effective cooperation between urologist and hematologist.

Perioperative and postoperative bleeding episodes are the most frequent complications reported in hemophilia patients. For patients with no coagulation disorders, TLRN intraoperative bleeds are observed at 2.2–2.8%, and are frequently a reason for conversion to an open procedure [5]. There are no significant differences in the reported percentage of all surgical complications, hemorrhage included, between hemophilia patients with adequate substitution of deficient coagulation factor and patients with no coagulation disorders [8, 9]. It is therefore crucial for hemophilia patients to undergo surgery in special reference centers, which provide expert health-care services and are equipped with a modern laboratory for careful daily monitoring of deficient coagulation factor activity [9, 10]. In conclusion, laparoscopic radical nephrectomy in hemophilia patients is a safe and effective procedure for renal carcinoma. Surgery should be performed by an experienced urologist in cooperation with a multidisciplinary team, providing both perioperative and postoperative care, supported by a specialized laboratory.

CONFLICTS OF INTEREST

The authors declare no conflicts of interest.

References

1. Rocino A, Coppola A, Franchini M, et al. Principles of treatment and update of recommendations for the management of haemophilia and congenital bleeding disorders in Italy. *Blood Trans.* 2014; 12: 575-598.
2. Srivastava A, Brewer AK, Mauser-Bunschoten EP, et al. Guidelines for management of haemophilia. *Haemophilia* 2013; 19: e1-47.
3. Clayman RV, Kavoussi LR, Soper NJ, et al. Laparoscopic nephrectomy: initial case report. *J Urol.* 1991; 146: 278-281.
4. Ljungberg B, Bensalah K, Canfield S, et al. EAU guidelines on renal cell carcinoma: 2014 update. *Eur Urol.* 2015; 67: 913-924.
5. Rassweiler J, Fornara P, Weber M, et al. Laparoscopic nephrectomy: the experience of the laparoscopy working group of the German Urologic Association. *J Urol.* 1998; 160: 18-21.
6. Rogenhofer S, Hauser S, Breuer A, et al. Urological surgery in patients with hemorrhagic bleeding disorders hemophilia A, hemophilia B, von Willebrand disease: a retrospective study with matched pair analysis. *World J Urol.* 2013; 31: 703-707.
7. Rusakov VN. Nephrectomy in hemophilia. *Urol Nefrol (Mosk)* 1982; 3: 64-65.
8. Goldman G, Holoborodska Y, Oldenburg J, et al. Perioperative management and outcome of general and abdominal surgery in hemophiliacs. *Am J Surg.* 2010; 199: 702-707.
9. Ligohr P, Bensoukehal S, Matthaei H, et al. Value and risk of laparoscopic surgery in hemophiliacs- experiences from a tertiary referral center for hemorrhagic diatheses. *Langenbecks Arch Surg.* 2014; 399: 609-618.
10. Szczepanik AB, Wislawski S, Windyga J, Huszcza S, Bilski S, Meissner AJ. Strategy for secure hemostasis in hemophilia patients undergoing surgery for malignant neoplasms. *Pol Merkur Lek.* 2009; 27: 375-380. ■