


CASE REPORT

Intracranial angiomatoid fibrous histiocytoma: report of a rare case

How to Cite This Article: Tabibkhouei A, Asgarzadeh L , Sadeghipour A, Vafaei Shahi M. Intracranial angiomatoid fibrous histiocytoma: report of a rare case. Iran J Child Neurol. summer 2022; 16(3): 205-212

Alireza TABIBKHOUEI MD¹,

Leila ASGARZADEH MD²,

Alireza SADEGHIPOUR MD³,

Mohammad VAFAEE SHAHI MD²

1. Department of Neurosurgery,
Iran University of Medical
Sciences, Tehran, Iran

2. Department of Pediatrics, Iran
University of Medical Sciences,
Tehran, Iran

3. Department of Pathology, Iran
University of Medical Sciences,
Tehran, Iran

Corresponding Author

Asgarzadeh L. MD

Department of Pediatrics, Iran
University of Medical Sciences,
Tehran, Iran

Email: dr.l.asgarzadeh@gmail.
com

Received: 22-Aug-2019

Accepted: 30-Sep-2020

published: 16-Jul-2022

Abstract

One rare and low-grade soft tissue tumor with intermediate malignant potential is angiomatoid fibrous histiocytoma (AFH), which occurs mainly in children and adolescents. The tumor naturally tends to local recurrence and recurrent hemorrhage but rarely to remote metastasis. AFH has been reported in different organs; however, there are rare reports of primary intracranial AFH. The diagnosis of AFH may be difficult due to its occurrence at multiple unusual anatomic sites and its spectrum of morphologic patterns; thus, it is especially important to diagnose it correctly because of the small risk of metastasis and death. The lesion is simply confused with a hematoma, soft tissue hemangioma, or malignant fibrous histiocytoma from clinical and radiographical aspects.

We report a case of intracranial AFH in a 5-year-old boy. The tumor is a heterogeneous intra-axial with a size of 78*73mm at the right front temporal. There was also an extra-axial mass measured 8*12mm at the left superior frontal lobe in favor of metastasis. The diagnosis was confirmed using radiographical, immunohistochemical, and molecular tests.

AFH is a rare tumor with a high probability of misdiagnosis. Surgeons must be aware of the presence of AFH and conduct a careful follow-up.

Keywords: Histiocytoma; Malignant Fibrous; Seizures; Brain Neoplasms; pediatrics

DOI: 10.22037/ijcn.v15i4.26805

Introduction

Angiomatoid fibrous histiocytoma (AFH) is a rare tumor with soft tissue and mild malignancy (1). AFH, as a low-grade malignant tumor, is mainly a tumor found in children and adolescents. This tumor is generally found in the hands and feet while it is rarely located in the trunk, head, and neck and usually presents as a slow-growing, painless subcutaneous mass. The deep structures, such as skeletal muscle or periosteum, were involved in only 18% of the cases reported (2). AFH has been widely reported in different organs and rarely occurs in primary intracranial AFH(3). AFH is diagnosed using histopathology and immunohistochemical examinations (4). Nine out of 19 (47%) cases of angiomatoid fibrous histiocytoma reported positive histiocytic marker CD68. The immunopositivity for myoid or myofibroblastic markers has been reported in over 50% of cases (4). Also, 11% of patients have reported local recurrence, while distant metastasis has been reported in 1%; angiomatoid fibrous histiocytoma is recommended to be treated with wide excision. Adjuvant chemotherapy is recommended if the tumor is unresectable or has metastasized (5). We present a five-year-old boy with an intracranial AFH.

Case Report

A 5-year-old boy was admitted to the hospital with a history of focal seizures 7-8 times a day as automatisms and unilateral gaze accompanied by vomiting and nausea. The initial diagnosis was reflux due to normal electroencephalography (EEG). As the symptoms continued, MRI and CT scans were carried out and showed a brain tumor. Brain CT scan showed an isodense lesion with central hypodensity and a specific area of

75 × 80 mm with surrounding vasogenic edema compressing the right lateral ventricle so that it caused the obstruction of the right lateral ventricle and improper drain of the left lateral ventricle. There was also a midline shift (MLS) of 2 cm to the left (Fig. 1).

The MRI scans showed a 78 × 73 mm iso-intense intra-axial mass in the right frontotemporal lobe with enhancement accompanied by surrounding vasogenic edema compressing the right ventricular and causing a midline shift. Also, an extra-axial small mass of 8 × 12 mm was observed in the left frontal lobe in favor of tumor metastasis (Fig. 2).

A craniotomy was performed. The patient was scheduled for urgent surgical decompression and underwent a large frontotemporoparietal craniotomy on the right side. Bones and dura matter were normal. A huge intra-axial highly vascular mass was found, and tumor resection was performed as much as possible. Due to the high vascularization of the mass, only 1/3 of it was removed. The patient received 1700 cc of blood due to the large and highly vascularized mass. We used intraoperative SSEP& MEP, and no more than 30% amplitude loss was detected, and surgery stopped uneventfulneurologically.

Five days later, the patient underwent the second craniotomy, and the entire mass was removed without bone involvement. Despite the difficulty of the operation, it was carried out successfully with no complications. However, the left frontal lobe mass remained (Fig. 4).

The patient received Levebel after surgery and regained the normal conditions so that there was no seizure in the follow-up. The blood test, LP, βHCG, and αFP were all normal.

When the pathology test results were obtained, the patient was discharged after repeating the

Intracranial angiomatoid fibrous histiocytoma: report of a rare case

brain and spine MRIs. The immunohistochemical test was also carried out, and the results were as follows (Fig. 3):

The histology section showed moderately cellular tumor formed by lobules and sheets of neoplastic cells in a richly vascularized stroma containing large-size vessels with numerous branching small vascular channels with a focal staghorn morphology. Scattered multinucleated tumoral cells were seen, and mitosis was infrequent. There were some mononuclear inflammatory cells, including lymphocytes and plasma cells, in the tumoral and non-tumoral tissue boundary. Patchy areas of coagulative necrosis were also seen. Immunostaining for CD68 and chymotrypsin were positive in background histiocytes and some tumoral cells. Tumoral cells were positive for

vimentin and SMA. GFAP, EMA, S100, Desmin, and CD34 were negative in tumoral cells. INI1 showed strong nuclear labeling of tumoral cells. Ki67 was estimated at around 10%.

Intracerebral spindle cell mesenchymal tumor was suggestive of angiomatoid fibrous histiocytoma. In the brain MRI, there was still the left frontal lobe mass. In the spine MRI, a mass of 8*10 mm was observed in the right posterior arch of L3 in favor of metastasis without bone involvement. Regarding the brain and spine MRI scans (Figs. 4 and 5) and the pathology test results, consultation with the oncologist was requested, and accordingly, the whole body bone scan TC99m was advised. There was no need for chemotherapy due to the lack of metastasis focus.

Figure 1. CT scans. (A 5-year-old boy diagnosed with AFH: an isodense lesion with central hypodensity and a specific area of 75 × 80 mm with surrounding vasogenic edema compressing the right lateral ventricle)

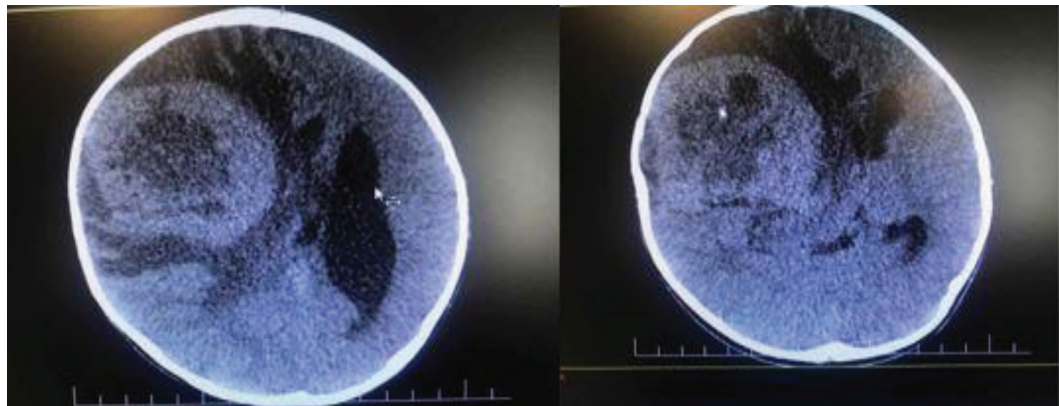
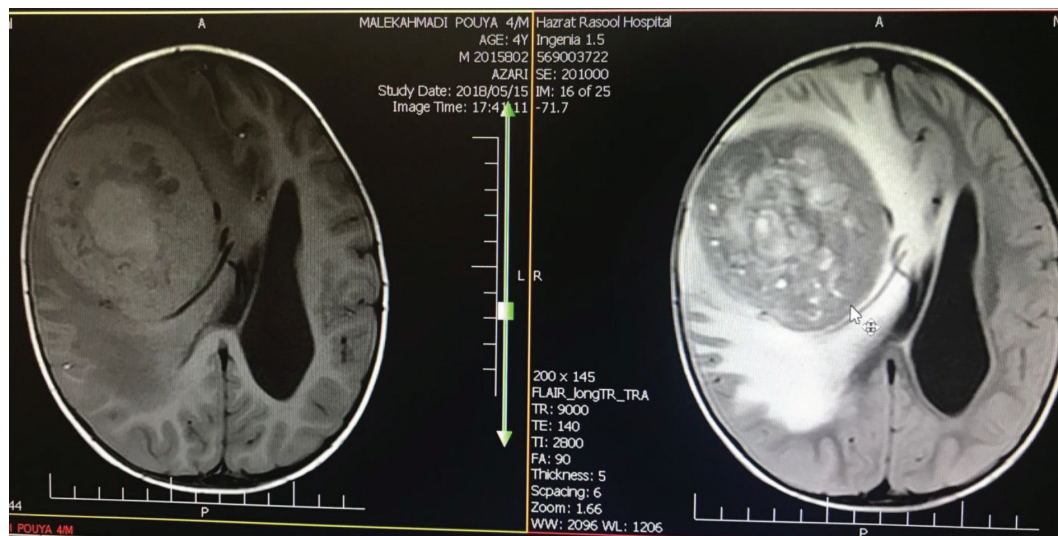


Figure 2. Brain MRI Scans. (A 5-year-old boy diagnosed with AFH: a 78 × 73 mm iso-intense intra-axial mass in the right fronto temporal lobe with enhancement accompanied with surrounding vasogenic edema compressing the right ventricular and causing midline shift. Also, an extra-axial small mass of 8 x 12 mm was observed in the left frontal lobe in favor of tumor metastasis)



Intracranial angiomatoid fibrous histiocytoma: report of a rare case

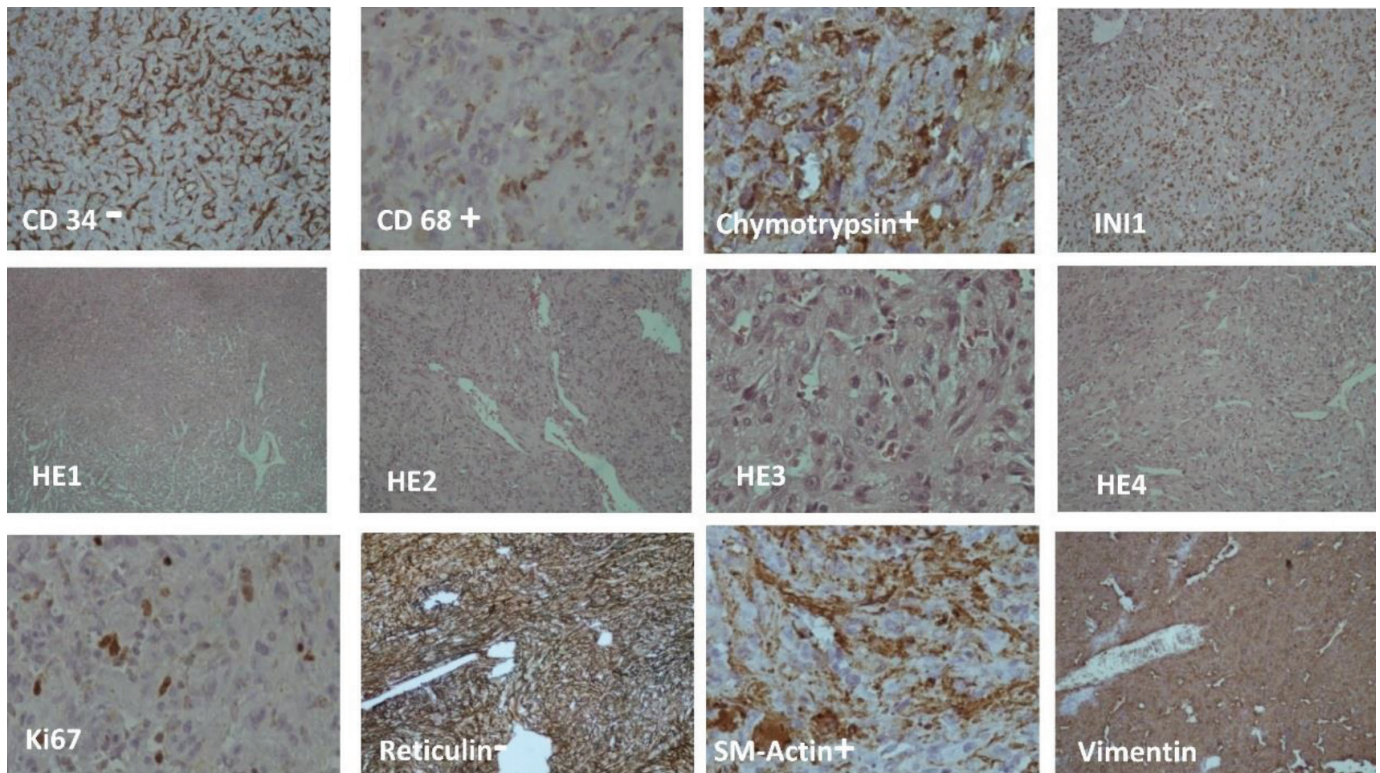


Figure 3. Pathology Pictures (Intracerebral spindle cell mesenchymal tumor suggestive of angiomatoid fibrous histiocytoma).

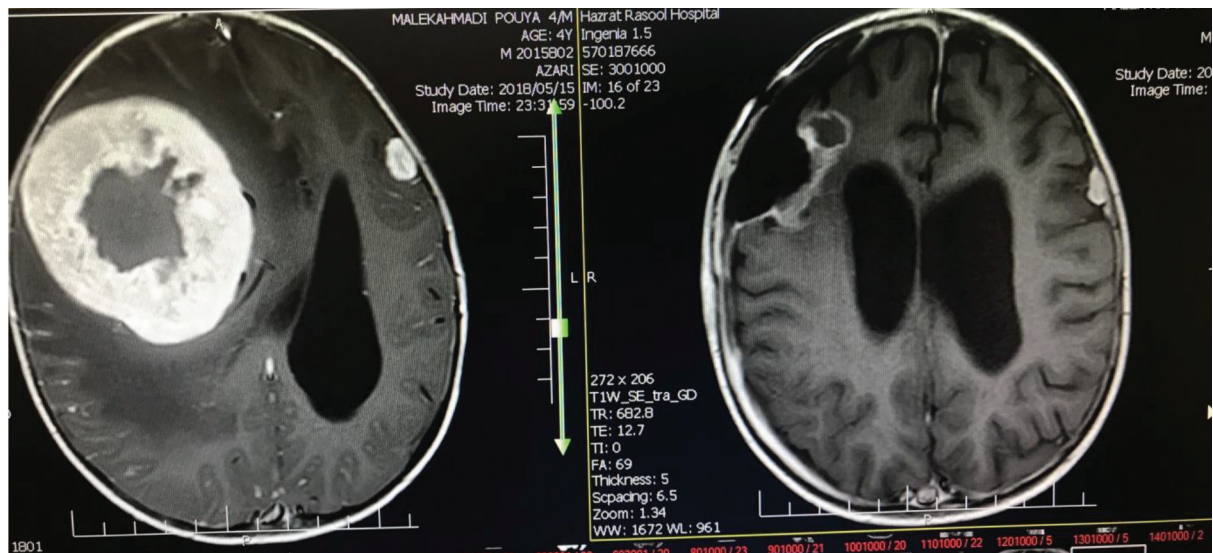


Figure 4. Brain MRI scans before and after craniotomy (**Left:** Before Operation: a 78 × 73 mm iso-intense intra-axial mass in the right fronto temporal lobe with enhancement accompanied with surrounding vasogenic edema compressing the right ventricular and causing midline shift. Also, an extra-axial small mass of 8 x 12 mm was observed in the left frontal lobe in favor of tumor metastasis; **Right:** extra-axial mass measured 8*12mm at left superior frontal lobe evaluation about metastasis)

Intracranial angiomatoid fibrous histiocytoma: report of a rare case

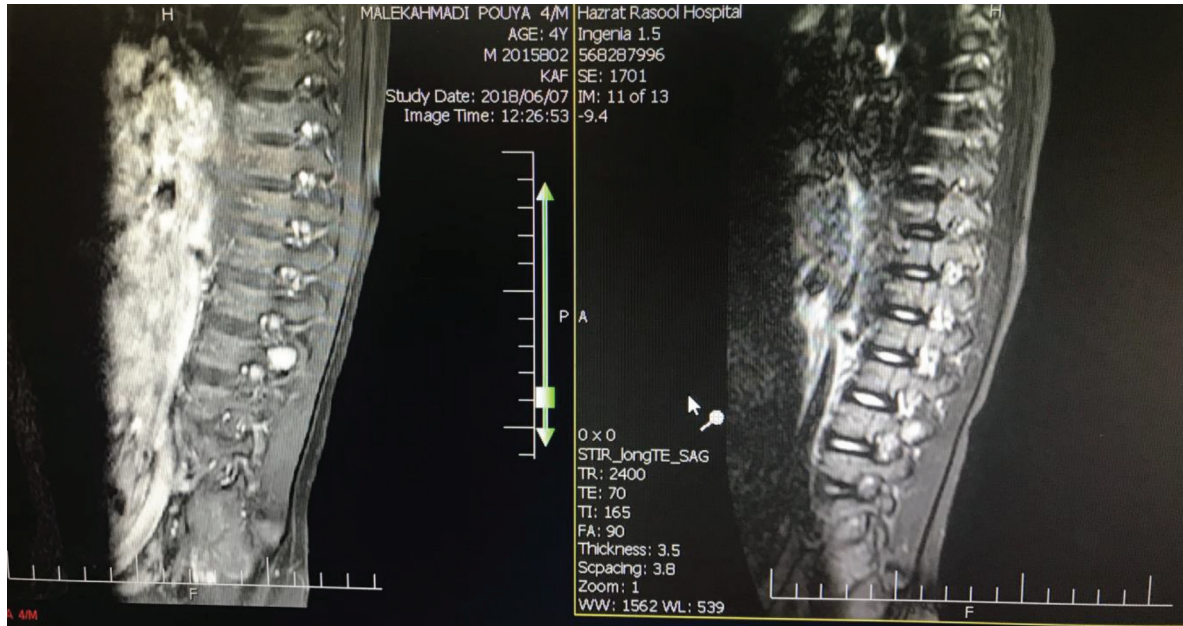


Figure 5. Spine MRI scan (Enhancing intra osseous lesion measured 11*8mm in the right lamina of L3 vertebral is seen)

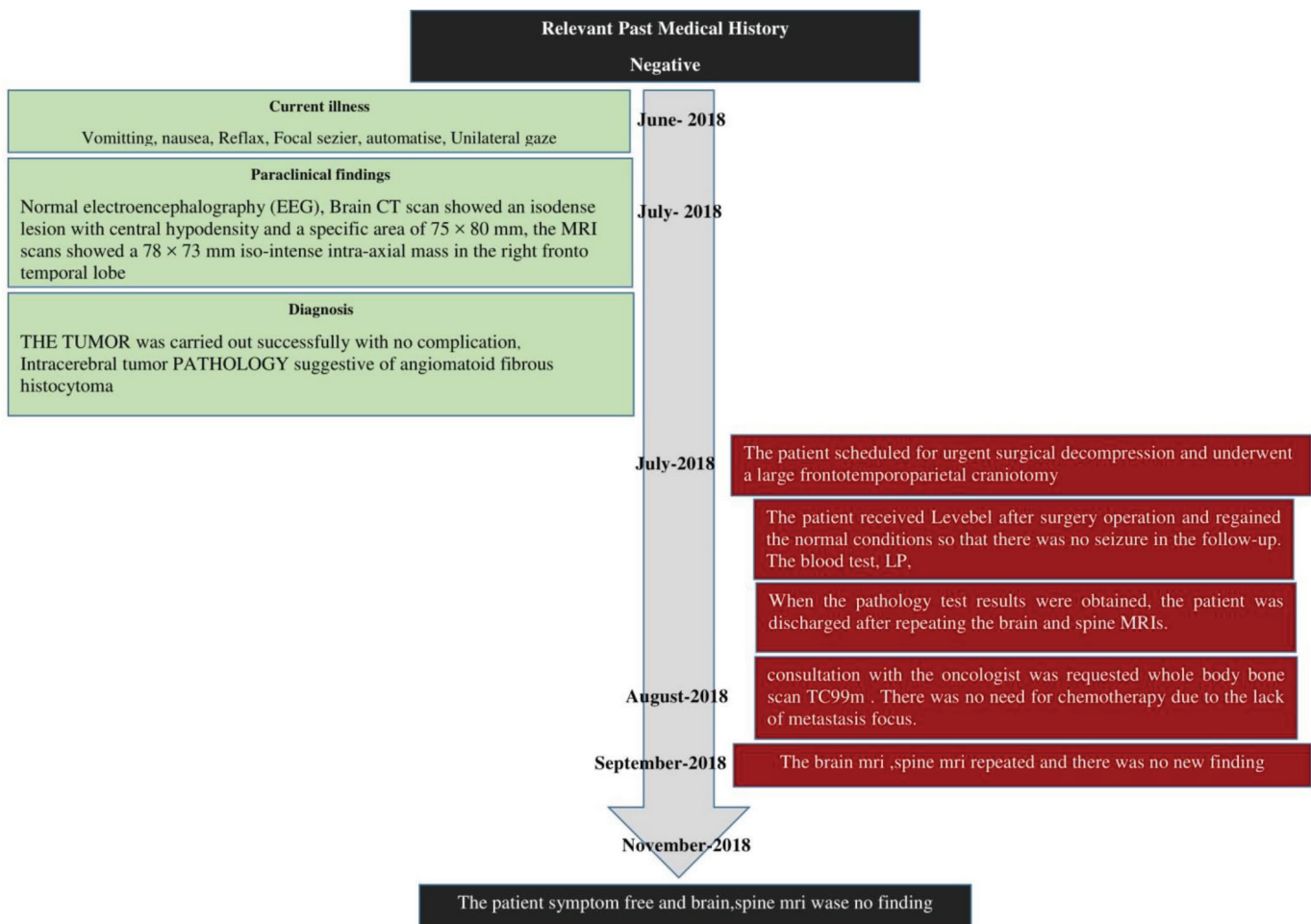


Figure 6. Time line

Discussion

The histogenesis was challenging when Enzinger first described “angiomatoid malignant fibrous histiocytoma” in 1979 (2). Nowadays, the exact differentiation line remains unknown, but its benign microscopic appearance and a favorable prognosis have caused this entity to no longer be regarded as “malignant” (6). According to the WHO classification, AFH rarely metastasizes; it is classified as an intermediate tumor (7). AFH was first described as a variant of malignant fibrous histiocytoma; however, it was finally recognized as a distinct entity when a large case review demonstrated its favorable prognosis (8). A minority of cases showed the symptoms of anemia, weight loss, and fever; however, local manifestations, such as pain or soreness, are extremely uncommon (9). The tumor has angiomatoid-like areas from a microscopic view. The tumor cell is a bland histiocytoid or fibroblast-like, having few mitotic figures. It is also encompassed by condensed lymphoid tissue and thick fibrous pseudocapsule (10). Immunohistochemistry results show that the positivity for epithelial membrane antigen (EMA), desmin, CD68, and CD99 is positivity, whereas that of the S100 protein and cytokeratin is negative. AFH normally incorporates three characteristic translocations that produce the associated fusion genes; the most common translocation is EWSR1-CREB1, derived from t(2;22)(q33;q12), followed by EWSR1-ATF1, from t(12;22)(q13;q12). The least common one is FUS-ATF1 from t(12;16)(q13;p11). EWSR1-CREB1, the widely mentioned gene fusion, has been reported in over 90% of AFHs (11, 12). AFH is usually seen under the skin of the extremities, followed by the trunk, head, and neck. In the meantime, it is rare in splanchnic organs, such as the lung, brain, and mediastinum (11). As

AFH is a middle-grade mesenchymal malignant tumor that relapses locally with a 10% probability and its likelihood of metastasis is 1%, a definitive diagnosis seems vital for appropriate surgical excision (13). From a clinical aspect, it may be similar to a hematoma, hemangioma, or a non-malignant cyst, like in our case (14). The death rate due to the disease among patients with AFH is extremely rare (15). Since it is not proved that add-on care may be helpful in the primary treatment of this tumor, wide ablation and a cautious follow-up are approved (14). It is often misdiagnosed at the first steps. A few cases of AFH recurred locally, and rare cases metastasized (8, 16). An immunohistochemical study showed that 50–60% of cases had coexpression of desmin, epithelial membrane antigen, CD68, and CD99. It is while there was a positive sample for CD21, CD35, clusterin, or S100 (17). Also, 11% of patients have reported local recurrence, and distant metastasis was reported in 1%; angiomatoid fibrous histiocytoma is recommended to be treated with wide excision. The infiltrative margin and deep location of a tumor cause local recurrence. Since performing the wide local excision is difficult, AFH in the head and neck can regularly come back. The surgery with a wide local excision is recommended as the best therapy for AFH. Adjuvant chemotherapy may also be useful if the tumor is unresectable or metastasized (8, 18).

In the present article, we reported a case that was initially misdiagnosed as reflux due to the normal EEG and the lack of AFH symptoms. Despite the manifestations of a malignant tumor, the primary mass was benign and completely removed during the second craniotomy. The symptoms of the patient were also controlled using the medications. Despite the presence of two metastasis masses in

the patient, no chemotherapy was needed.

The teaching point for this rare tumor is that we need radiographical and immunohistochemical tests to diagnose AFH correctly. It should also be noted that the highly vascularized mass does not necessarily indicate tumor malignancy. Furthermore, since the possibility of metastasis to the distant regions is 1%, chemotherapy might not be required despite the metastatic tumor.

Acknowledgement

The authors would like to thank Ali Asghar Clinical Research Development Center (AACRDC), for Assistance. Ethics approval was gathered from the ethics committee at Iran University of medical sciences. The parents prepared the written informed consent to participate.

Authors Contribution

AT Conception and Design and revising critically and neurosurgeon, LA acquisition of data and drafting the manuscript and submit. AS pathologist and Review of manuscript. MV neurologist and Reviewed submitted version of manuscript.

Conflict of interest

Each author listed on the manuscript has seen and approved the submission of this version of the manuscript and takes full responsibility for the manuscript

References

1. Chu Y-N, Chen C-J, Liang C-W, Hsu H-C. An unusual histopathologic feature of angiomatoid fibrous histiocytoma—A case report and molecular study. *Dermatologica Sinica*. 2018.
2. Enzinger FM. Angiomatoid malignant fibrous histiocytoma. A distinct fibrohistiocytic tumor

- of children and young adults simulating a vascular neoplasm. *Cancer*. 1979;44(6):2147-57.
3. Alshareef MA, Almadidy Z, Baker T, Perry A, Welsh CT, Vandergrift III WA. Intracranial angiomatoid fibrous histiocytoma: case report and literature review. *World neurosurgery*. 2016;96:403-9.
4. Sánchez-García I. Angiomatoid fibrous histiocytoma (AFH). *Atlas of genetics and cytogenetics in oncology and haematology*. 2006;10(2):127-30.
5. Huerter ME, Hammad R, Zhou Q, Riker AI. Recurrent angiomatoid fibrous histiocytoma: a case report and review of the literature. *The Ochsner Journal*. 2014;14(3):441-4.
6. Matushansky I, Charytonowicz E, Mills J, Siddiqi S, Hricik T, Cordon-Cardo C. MFH classification: differentiating undifferentiated pleomorphic sarcoma in the 21st century. *Expert review of anticancer therapy*. 2009;9(8):1135-44.
7. Saito K, Kobayashi E, Yoshida A, Araki Y, Kubota D, Tanzawa Y, et al. Angiomatoid fibrous histiocytoma: a series of seven cases including genetically confirmed aggressive cases and a literature review. *BMC musculoskeletal disorders*. 2017;18(1):31.
8. Costa MJ, Weiss SW. Angiomatoid malignant fibrous histiocytoma. A follow-up study of 108 cases with evaluation of possible histologic predictors of outcome. *The American journal of surgical pathology*. 1990;14(12):1126-32.
9. Fanburg-Smith J, Miettinen M. Angiomatoid “malignant” fibrous histiocytoma: a clinicopathologic study of 158 cases and further exploration of the myoid phenotype. *Human pathology*. 1999;30(11):1336-43.

10. Shi H, Li H, Zhen T, Zhang F, Dong Y, Zhang W, et al. Clinicopathological features of angiomatoid fibrous histiocytoma: a series of 21 cases with variant morphology. *International journal of clinical and experimental pathology*. 2015;8(1):772.
11. Kao Y-C, Lan J, Tai H-C, Li C-F, Liu K-W, Tsai J-W, et al. Angiomatoid fibrous histiocytoma: clinicopathological and molecular characterisation with emphasis on variant histomorphology. *Journal of Clinical Pathology*. 2014;67(3):210-5.
12. Chen G, Folpe AL, Colby TV, Sittampalam K, Patey M, Chen M-G, et al. Angiomatoid fibrous histiocytoma: unusual sites and unusual morphology. *Modern Pathology*. 2011;24(12):1560.
13. Li C-S, Chan WP, Chen W-T, Chang C-P, Shih L-S, Chen R-C, et al. MRI of angiomatoid fibrous histiocytoma. *Skeletal radiology*. 2004;33(10):604-8.
14. Billings SD, Folpe AL. Cutaneous and subcutaneous fibrohistiocytic tumors of intermediate malignancy: an update. *The American journal of dermatopathology*. 2004;26(2):141-55.
15. Kim K, Lee J-S, Cho K-J. Angiomatoid fibrous histiocytoma. *Korean J Pathol*. 2006;40:377-80.
16. Davis AM, O'Sullivan B, Turcotte R, Bell R, Catton C, Chabot P, et al. Late radiation morbidity following randomization to preoperative versus postoperative radiotherapy in extremity soft tissue sarcoma. *Radiotherapy and oncology*. 2005;75(1):48-53.
17. García JJ, Folpe AL. The impact of advances in molecular genetic pathology on the classification, diagnosis and treatment of selected soft tissue tumors of the head and neck. *Head and neck pathology*. 2010;4(1):70-6.
18. Asakura S, Tezuka N, Inoue S, Kihara N, Fujino S. Angiomatoid fibrous histiocytoma in mediastinum. *The Annals of thoracic surgery*. 2001;72(1):283-5.

Copyright © 2022 The Authors. Published by Shahid Beheshti University of Medical Sciences.

This work is published as an open access article distributed under the terms of the Creative Commons Attribution 4.0 License

(<http://creativecommons.org/licenses/by-nc/4>). Non-commercial uses of the work are permitted, provided the original work is properly cited.