

The application of texture and color enhancement imaging in transpapillary biliary cannulation

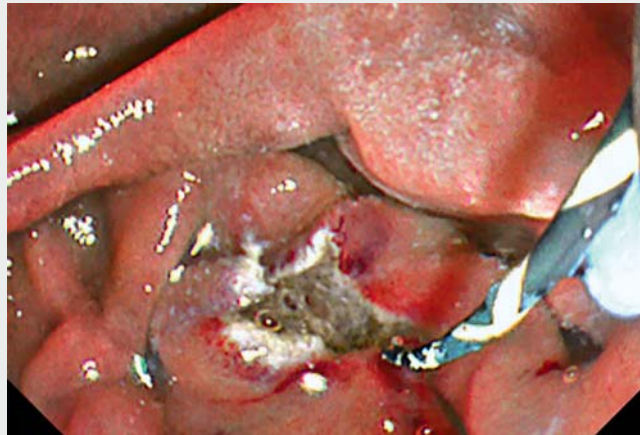

The efficacy of image-enhanced endoscopy (IEE) has been widely reported in the management of gastrointestinal tract lesions [1–3]; however, the efficacy of IEE has not been well discussed in the pancreatobiliary field. Recently, a novel IEE tool called texture and color enhancement imaging (TXI; Olympus, Tokyo, Japan) was launched. TXI has two modes: mode 1, which enhances brightness, texture, and color contrast; and mode 2, which enhances brightness and texture [4]. Herein, we report the usefulness of TXI in biliary cannulation (► **Video 1**).

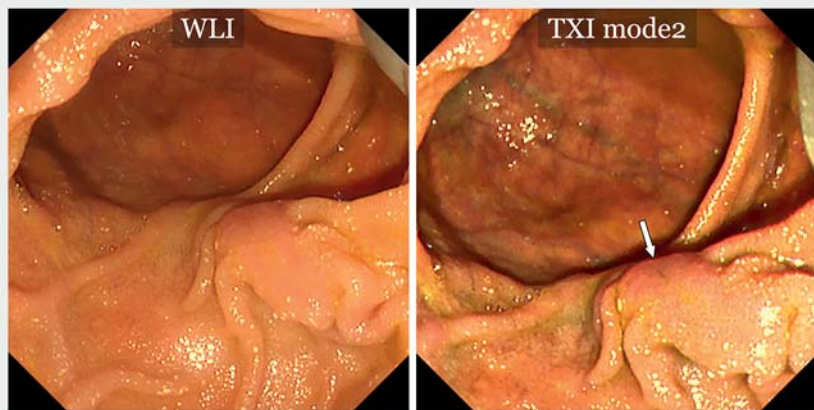
Case 1 was a 79-year-old woman who underwent endoscopic retrograde cholangiopancreatography (ERCP) for cholangitis. The flat-shaped papilla was located in the periampullary diverticula. The orifice of the bile duct was unclear under white-light imaging (WLI); however, TXI mode 2 enhanced the brightness and texture of unevenness on the surface of the papilla, leading to the clear recognition of the orifice (► **Fig. 1**). Finally, biliary cannulation was achieved without pancreatic ductal intervention.

Case 2 was an 81-year-old man with advanced pancreatic cancer who underwent ERCP for a malignant distal biliary obstruction. The scope position was unstable owing to duodenal invasion of the tumor, and use of the transpapillary biliary approach was challenging. Therefore, we performed precutting using a precut needle knife (NeedleCut 3V KD-V441M; Olympus, Tokyo, Japan). Upon observation of the incised surface of the papilla under TXI mode 1, a hole opening on the sphincter muscle suggesting the orifice of the bile duct was well recognized (► **Fig. 2**). Successful biliary cannulation was achieved by the insertion of the ERCP catheter into the hole.

The identification of the papilla orifice is important for transpapillary biliary intervention. Texture and color enhancement imaging amplifies the difference in the structure of the papilla, leading to an



► **Video 1** Texture and color enhancement imaging (TXI) provides enhanced images, because the function amplifies minute visible changes. TXI may help in recognizing the structure around the papilla during biliary cannulation.



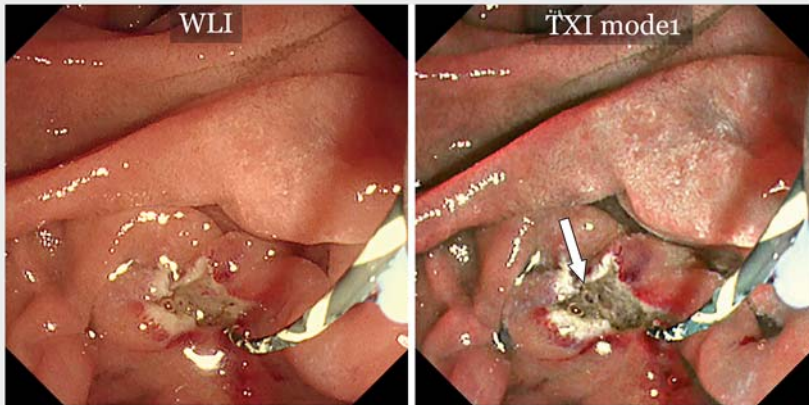
► **Fig. 1** Although the orifice of the bile duct was unclear under white-light imaging (WLI), texture and color enhancement imaging (TXI) mode 2 (texture and brightness enhanced) allowed clear recognition of the orifice.

easier understanding of the papilla orifice. Therefore, TXI can aid in biliary cannulation, especially in cases with an unclear biliary orifice.

Endoscopy_UCTN_Code_TTT_1AR_2AK


Competing interests

Dr. Katanuma received honoraria as a lecture fee from Olympus Co., Tokyo, Japan. The authors have no conflicts of interest to declare.



► **Fig. 2** After precutting, the bile duct orifice was more clearly recognized under TXI mode 1 (texture, brightness, and color enhanced) than with white-light imaging (WLI).

The authors

Haruka Toyonaga , **Toshifumi Kin**, **Tsuyoshi Hayashi**, **Kuniyuki Takahashi**, **Akio Katanuma**
Center for Gastroenterology, Teine Keijinkai Hospital, Hokkaido, Japan

Corresponding author

Haruka Toyonaga, MD
Center for Gastroenterology, Teine-Keijinkai Hospital, 1-40-1-12 Maeda, Teine-ku, Sapporo 006-8555, Japan
Fax: +81-11-685-2967
toyonaga.pc@gmail.com

References

- [1] Sato T. Image-enhanced endoscopy. *Tech Gastrointest Endosc* 2011; 13: 2–7
- [2] Lemmers A, Bucalau AM, Verset L et al. Pristine submucosal visibility using texture and color enhancement imaging during saline-immersion rectal endoscopic submucosal dissection. *Endoscopy* 2021. doi:10.1055/a-1524-1298
- [3] Abe S, Makiguchi ME, Nonaka S et al. Emerging texture and color enhancement imaging in early gastric cancer. *Dig Endosc* 2021. doi:10.1111/den.14182
- [4] Sato T. TXI: Texture and color enhancement imaging for endoscopic image enhancement. *J Healthc Eng* 2021. doi:10.1155/2021/5518948

Bibliography

Endoscopy 2022; 54: E786–E787

DOI 10.1055/a-1806-1913

ISSN 0013-726X

published online 25.4.2022

© 2022. The Author(s).

This is an open access article published by Thieme under the terms of the Creative Commons Attribution-NonDerivative-NonCommercial License, permitting copying and reproduction so long as the original work is given appropriate credit. Contents may not be used for commercial purposes, or adapted, remixed, transformed or built upon. (<https://creativecommons.org/licenses/by-nc-nd/4.0/>)

Georg Thieme Verlag KG, Rüdigerstraße 14, 70469 Stuttgart, Germany



ENDOSCOPY E-VIDEOS

<https://eref.thieme.de/e-videos>



Endoscopy E-Videos is an open access online section, reporting on interesting cases and new techniques in gastroenterological endoscopy. All papers include a high quality video and all contributions are freely accessible online. Processing charges apply (currently EUR 375), discounts and waivers acc. to HINARI are available.

This section has its own submission website at <https://mc.manuscriptcentral.com/e-videos>