

## Successful treatment of HCV/HBV/HDV-coinfection with pegylated interferon and ribavirin

Janine Hartl, Claudia Ott,  
Gabriele Kirchner, Bernd Salzberger,  
Reiner Wiest

Internal Medicine 1, University Hospital  
of Regensburg, Germany

### Abstract

Dual and triple infections with hepatitis virus C (HCV), B (HBV) and D (HDV) frequently lead to severe liver damage. Hereby we describe a 38-year-old Caucasian male coinfecting with HCV (genotype 3a), HBV [positive hepatitis B surface antigen (HbsAg) and antibody to hepatitis B core antigen; negative hepatitis B e antigen (HbeAg) and antibody to hepatitis B e antigen (anti-HBe)] and HDV. Laboratory diagnostics revealed increased liver enzymes and histological examination of the liver showed signs of fibrosis with moderate inflammation. On therapy with pegIFN- $\alpha$ 2b and ribavirin HCV-RNA was undetectable at week 8. After week 24 the antiviral therapy was stopped because of a HBs-seroconversion, the loss of HbeAg and the detection of anti-HBe. Furthermore the HCV-RNA was negative. Six months after successful treatment of the triple-infection, HCV- and HDV-RNA and HbsAg remained negative and the liver enzymes had been completely normalized. In conclusion, pegylated-interferon plus ribavirin may be an effective therapy for HCV, HBV and HDV-coinfected patients.

### Introduction

Worldwide, 400 million people suffer from chronic viral hepatitis B (HBV) and up to 170 million from hepatitis C (HCV).<sup>1</sup> Thereby these infections account largely for the most chronic and end-stage liver diseases. Coinfections are not uncommon: 10% of HBV-infected patients are coinfecting with HCV<sup>2</sup> and 5% of hepatitis B surface antigen (HBsAg)-carriers additionally carry hepatitis D (HDV).<sup>3</sup> Dual or triple infections with these hepatotropic viruses often lead to more severe liver damage and are known to increase the risk for hepatocellular carcinoma (HCC).<sup>4,6</sup> Studies indicated that the antiviral treatment of coinfecting patients still remains a challenge, especially because there does not yet exist a standard-of-care recommendation. After exclusion of contraindications,

the actual standard therapy for HCV-mono-infection consists of a combination of pegylated-interferon alpha (peg-IFN $\alpha$ ) plus ribavirin (RBV).<sup>7</sup> Concerning HBV/HCV-coinfections, a few preliminary studies showed a small response to IFN-monotherapy in these patients,<sup>5,8</sup> but Potthoff *et al.*<sup>9</sup> and Yu *et al.*<sup>10</sup> reported on a high effectiveness of peg-IFN $\alpha$  plus RBV. Much more, they could show similar efficacy in suppressing HCV RNA in coinfection in comparison to HCV monoinfection. No study, however, has yet been presented investigating the efficacy of pegylated peg-IFN $\alpha$  in HBV/HDV/HCV-coinfected individuals.

### Case Report

In August 2009, a 38-year-old Caucasian male presented to our clinic with elevated liver enzymes pre-existing for a minimum of three years. Two months ago, further clinical diagnostics were already performed by his general practitioner. Thereby an HBV/HCV-coinfection was detected. The patient denied intravenous drug abuse, sexual risk factors, blood transfusions and a positive family history for infectious and/or other chronic liver diseases. However we noticed multiple tattoos and the patient admitted moderate alcohol consumption for many years. Physical examination revealed no abnormalities. Laboratory diagnostics verified increased liver enzymes [alanine aminotransferase (ALT) 79 U/L, aspartate aminotransferase (AST) 181 U/L, gamma-GT 223 U/L]; all other remaining routine parameters including RBC, WBC, platelets, inflammation parameters, coagulation and thyroid gland values (TSH, fT3, fT4) were normal. The plasma autoimmune hepatitis antibody panel (ANA, SLA, LKM, SMA) as well as AMA and pANCA were negative, and serum IgG, IgA and IgM levels were not elevated. Microbiological work-up showed antibodies against HCV (anti-HCV) with a high-positive viral load of  $5.2 \times 10^5$  copies/mL (genotype 3a). Furthermore serum hepatitis B surface antigen (HBsAg) was positive, antibody to hepatitis B surface antigen (anti-HBs) was negative, antibody to hepatitis B core antigen (anti-HBc) was positive (anti-HBc-IgM negative), serum HBeAg and anti-HBe were negative. Serum HBV DNA level was low replicative with  $1.0 \times 10^2$  copies/mL, but antibodies against hepatitis delta virus (IgG and IgM) were also positive. At this time no HDV-polymerase chain reaction (PCR) was determined. An infection with HIV and hepatitis A-virus could be excluded. A liver biopsy was performed and histological examination revealed portal and periportal fibrosis and a moderate lobular and portal inflammation (Grading 4, Staging 2; Metavir-Score A2F2). Starting October 2009 the patient was treated

Correspondence: Janine Hartl, Department of Gastroenterology and Hepatology, Department of Internal Medicine I, University Hospital of Regensburg, Franz-Josef-Strauss-Allee 11, 93042 Regensburg, Germany.  
Tel. +49.941.944.7010 - Fax: +49.941.944.7003.  
E-mail: janine.hartl@klinik.uni-regensburg.de

Key words: HCV, HBV, HDV, triple-hepatitis, pegylated interferon, ribavirin.

Contributions: JH, CO, GK, BS, RW, research design; JH, CO, RW, research performing; JH, CO, data analysis; JH, RW, manuscript writing.

Received for publication: 7 November 2011.

Revision received: 26 April 2012.

Accepted for publication: 7 May 2012.

This work is licensed under a Creative Commons Attribution NonCommercial 3.0 License (CC BY-NC 3.0).

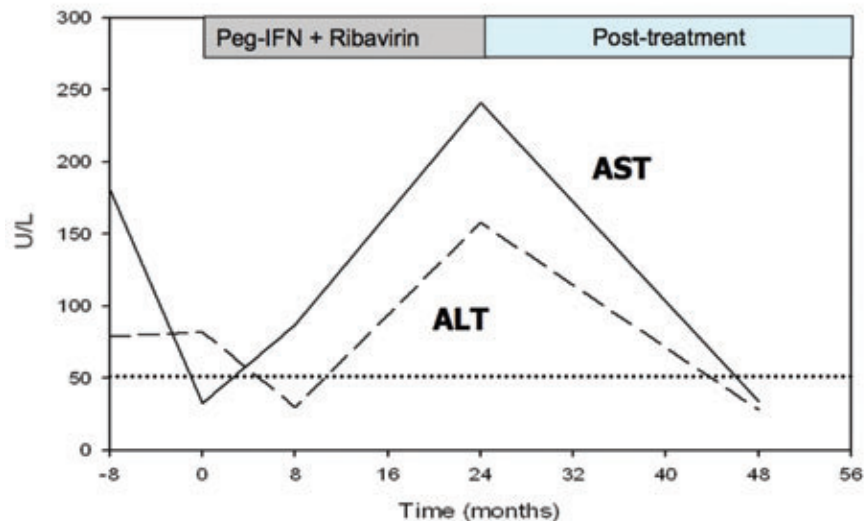
©Copyright J. Hartl *et al.*, 2012  
Licensee PAGEPress, Italy  
*Clinics and Practice* 2012; 2:e64  
doi:10.4081/cp.2012.e64

with a dual-therapy of pegIFN- $\alpha$ 2b 180 $\mu$ g per week and ribavirin 1200 mg per day. After 8 weeks of treatment HCV-RNA was undetectable with reverse transcription-PCR (RT-PCR) and HBs-Ag was positive with 6.7 IU/mL quantitatively. After week 24 HBs- seroconversion was noted evidenced by loss of HBs-Ag and appearance of anti-HBs (101.7 U/L quant.). At the same time, we observed the loss of HBeAg and the detection of anti-HBe. Furthermore a slow elevation of ALT and AST was noticeable over the time. Based on an equally present HCV-RNA-negativity, the dual antiviral therapy was stopped at week 24. Six months after successful treatment of the triple-infection, HCV- and HDV-RNA and HbsAg still remained negative and the liver enzymes had been completely normalized (Figure 1).

### Discussion

Dual and triple infections with hepatotropic viruses (*i.e.* HBV, HDV, HCV) are frequently associated with acute or chronic hepatitis with potential progression to cirrhosis and HCC.<sup>4,6</sup> Thus, an effective antiviral therapy is essential to provide the affected patients with a good prognosis. Unfortunately there do not exist any coherent clinical trials, which could form a basis for a generally valid standard-of-care recommendation. To our knowledge, the presented case is the first showing a sustained recovery from a coinfection with HCV, HBV and HDV

after antiviral treatment with peg-IFN $\alpha$ -2b and ribavirin for 24 weeks. The literature contains multiple studies about different therapeutic approaches for patients with viral coinfections: Villa *et al.*<sup>11</sup> reported on 30 patients with HBV/HCV-coinfection treated with IFN-mono. The results showed that in a proportion of patients IFN could lead to both HBV and HCV viral clearance, especially if higher doses of standard-IFN $\alpha$  were used. On the other hand, Zignego *et al.*<sup>8</sup> concluded that HCV patients with occult hepatitis B had significantly lower biochemical and virological response rates to IFN as compared to those who were HBV DNA negative. Several trials could show synergistic beneficial effects between standard IFN and RBV for the treatment of chronic hepatitis C. Therefore a few study groups investigated the effect of this combination regimen for patients with HBV/HCV-coinfection. In these patients they observed similar sustained virological response (SVR) rates (between 43% and 69%) in comparison to HCV-monoinfection.<sup>12-14</sup> In 2009 Liu *et al.*<sup>15</sup> performed the largest, randomized, controlled prospective study with pegylated interferon and ribavirin for 161 patients with HBV and HCV-coinfection. They could show high HCV-SVR (up to 83%) and good HBV-response rates (HBsAg loss (N=18, 11%) and HBV DNA negativity (N=38, 56%)). However, in agreement with two other previous studies,<sup>9,10</sup> they also showed a high HBV reactivation rate (37%) among the 77 patients with undetectable HBV DNA at baseline. Our presented patient suffered not only from a dual infection with HCV and HBV but also from HDV. Hepatitis D is considered to be the most severe form of viral hepatitis in humans, affects only HBV-infected patients and is often accompanied with fulminant hepatitis and in chronic liver disease with early decompensation.<sup>16,17</sup> Actually, the only approved treatment regimen for hepatitis D is a mono-therapy with peg-IFN.<sup>18-20</sup> Oral antiviral agents (*i.e.* ribavirin, lamivudine) are ineffective.<sup>21-23</sup> Furthermore, the addition of lamivudine or ribavirin to IFN has not improved efficacy, as compared to the use of interferon alone.<sup>24-27</sup> The recently presented Hep-Net-International Delta Hepatitis Intervention Trial (HIDIT)<sup>28</sup> investigated the safety and efficacy of peg-IFN $\alpha$ -2a plus adefovir dipivoxil, as compared to either drug alone, in patients with chronic HDV infection. After 48 weeks of treatment with peg-IFN $\alpha$ -2a (mono or in combination with the oral antiviral drug adefovir dipivoxil) about one quarter of patients had clearance of HDV RNA 24 weeks after the end of treatment. In addition, 7% of the patients had normalized ALT associated with a complete HDV RNA-clearance. However, after treatment with adefovir dipivoxil alone none of the patients had clearance of HDV RNA. Concerning the coincident HBV-infection, the combination of pegin-



HCV - RNA (cop./mL)	5.2x10 <sup>6</sup>	neg	neg	neg
HBV - DNA (cop./mL)	1.0x10 <sup>7</sup>	**	neg	neg
HBs-Ag	pos	pos	neg	neg
anti-HBs	neg	neg	pos	pos
anti-HBc	pos	**	**	**
HBeAg	neg	**	**	**
antiHBe	neg	**	**	pos
anti-HDV-IgG	pos	**	**	**
anti-HDV-IgM	pos	**	**	**
HDV-RNA	**	**	**	neg

**Figure 1.** Biochemical and virological profile of the patient. The horizontal line indicates the upper limit of normal for alanine aminotransferase (ALT) and aspartate aminotransferase (AST). HBV, hepatitis B virus; HCV, hepatitis C virus; HDV hepatitis D virus; HBeAg, hepatitis B e antigen; HBe, antibody to hepatitis B e antigen; anti-HBc antibody to hepatitis B core antigen; HBsAg, hepatitis B surface antigen; anti-HBs, antibody to hepatitis B surface antigen.

terferon alfa-2a and adefovir resulted in a decline in the HBsAg level of at least 1 log<sub>10</sub> IU per milliliter in approximately one third of patients. So far, there are no data available on a complete virological response after treatment with peg-IFN and RBV in triple-infected (HCV/HBV/HDV-coinfected) patients. Zuberi *et al.*<sup>29</sup> reported on 246 patients with HBV, thereof 29 (11.8%) patients with positive anti-HBc IgG, anti-HDV and anti-HCV. After 48 weeks of therapy HBV DNA was cleared in 4 (13.8%) patients with positive HBV DNA (without HCV-RNA). Patients who did present with both, HBV DNA and HCV RNA, HCV was undetectable in 2 (6.9%) while HBV was not cleared in any case. The results of viral antibodies (*i.e.* HbsAg, anti-HBc) unfortunately were not described in this study. Gozlan *et al.*<sup>30</sup> described a patient with a quadruple infection of HIV/HCV/HBV and HDV. Due to an active HCV-infection

(HCV-RNA > 3 × 10<sup>6</sup> IU/mL, Metavir Score A2 F1 and fluctuating liver enzymes) an antiviral therapy of pegIFN and RBV was started. After 6 months of therapy HCV-RNA was still detectable, but the authors could observe HBsAg-clearance, anti-HBs seroconversion and negative serum HBV DNA (HBV viral load 6 months before starting pegIFN/RBV: < 125.000 IU/mL). Surprisingly, HBsAg-clearance came along with an extensive HDV replication (HDV RNA 9.3 × 10<sup>6</sup> copies/mL) resulting in clearance of HDV RNA 6 months later. The authors suggested that the sustained virological response of HBV and HDV under antiviral treatment might be a result of the proper immune response of the patient, which he developed a few months before initiation of pegIFN. This immune response was detected by an increase of aminotransferases and maybe was enhanced by the interferon treat-

ment resulting in HBV clearance. The patient presented here also showed increased liver enzymes before starting antiviral therapy. Thus, we cannot exclude the possibility that our therapeutic success may be an expression of a spontaneous immune response of the patient already at the start of pegIFN and RBV. This effect might be independent of the virological response due to the antiviral therapy but cannot be differentiated. Nonetheless, this has never been described in patients with triple infections of HCV/HBV and HDV. According to previous studies,<sup>30-33</sup> HCV was the dominant virus in our case. Based on the high viral load of the hepatitis C virus and good results in double-infected patients<sup>9,10,15</sup> we initially recommended a combined antiviral therapy with peg-IFN and RBV. Fortunately, after 8 weeks of treatment the HCV RNA was undetectable and after another 16 weeks we achieved a complete seroconversion from HBsAg to Anti-HBs. Six months after the dual antiviral therapy the HDV RNA remained negative and there were no evidences for HBV-reactivation as has been reported in previous studies.<sup>9,10</sup> Because of this surprising result no nucleotide analog reverse transcriptase inhibitor (*i.e.* adefovir) was started. Studies indicate an inverse relationship between HBV and HCV replication and an alternative dominant role of HBV and HCV.<sup>32,34,35</sup> Some authors observed a dominated role of the hepatitis C-virus with suppression of the HBV replication.<sup>35</sup> Others showed that HBV DNA replication inhibits HCV RNA replication among dually infected patients.<sup>36</sup> Furthermore, many of these studies demonstrate that successful clearance of one virus may lead to reactivation of the other.<sup>37</sup> In conclusion, our case report emphasizes that a dual therapy with peg-IFN $\alpha$  plus ribavirin can constitute a successful treatment in HCV/HBV/HDV-coinfected patients, not only with a sustained virological response of HCV-RNA but also with induction of HBsAg seroconversion and clearance of HDV-RNA. Continuous monitoring of the patient's symptoms, the blood count, the transaminases and virological antibodies are essential for a successful treatment of viral hepatitis. Furthermore the optimal treatment duration has to be adapted to every individual patient.

## References

- Koff RS. Risks associated with hepatitis A and hepatitis B in patients with hepatitis C. *J Clin Gastroenterol* 2001;33:20-6.
- Liaw YF. Role of hepatitis C virus in dual and triple hepatitis virus infection. *Hepatology* 1995;22:1101-8.
- Hadziyannis SJ. Review: hepatitis delta. *J Gastroenterol Hepatol* 1997;12:289-98.
- Benvegno L, Fattovich G, Noventa F, et al. Concurrent hepatitis B and C virus infection and risk of hepatocellular carcinoma in cirrhosis. *Cancer* 1994;74:2442-8.
- Chiaromonte M, Stroffolini T, Vian A, et al. Rate of incidence of hepatocellular carcinoma in patients with compensated viral cirrhosis. *Cancer* 1999;85:2132-7.
- Weltman MD, Brotodihardjo A, Crewe EB, et al. Coinfection with hepatitis B and C or B, C and delta viruses results in severe chronic liver disease and responds poorly to interferon-alpha treatment. *J Vir Hep* 1995;2:39-45.
- Ghany MG, Strader DB, Thomas DL, Seeff LB (AASLD). Diagnosis, management, and treatment of hepatitis C: an update. *Hepatology* 2009;49:1335-74.
- Zignego AL, Fontana R, Puliti S, et al. Relevance of inapparent coinfection by hepatitis B virus in alpha interferon-treated patients with hepatitis C virus chronic hepatitis. *J Med Virol* 1997;51:313-8.
- Potthoff A, Wedemeyer H, Boecher WO, et al. The HEPNET B/C co-infection trial: a prospective multicenter study to investigate the efficacy of pegylated interferon Alfa-2b and ribavirin in patients with HBV/HCV co-infection. *J Hepatol* 2008;49: 688-94.
- Yu JW, Sun LJ, Zhao YH, et al. Analysis of the efficacy of treatment with peginterferon alpha-2a and ribavirin in patients coinfecting with hepatitis B virus and hepatitis C virus. *Liver Int* 2009;29:1485-93.
- Villa E, Grottola A, Buttafoco P, et al. High doses of alpha-interferon are required in chronic hepatitis due to coinfection with hepatitis B virus and hepatitis C virus: long term results of a prospective randomized trial. *Am J Gastroenterol* 2001;96: 2973-7.
- Chuang WL, Dai CY, Chang WY, et al. Viral interaction and responses in chronic hepatitis C and B coinfecting patients with interferon-alpha plus ribavirin combination therapy. *Antivir Ther* 2005;10:125-33.
- Hung CH, Lee CM, Lu SN, et al. Combination therapy with interferon-alpha and ribavirin in patients with dual hepatitis B and hepatitis C virus infection. *J Gastroenterol Hepatol* 2005;20:727-32.
- Liu CJ, Chen PJ, Lai MY, et al. Ribavirin and interferon is effective for hepatitis C virus clearance in hepatitis B and C dually infected patients. *Hepatology* 2003;37:568-76.
- Liu CJ, Chuang WL, Lee CM, et al. Peginterferon alfa-2a plus ribavirin for the treatment of dual chronic infection with hepatitis B and C viruses. *Gastroenterology* 2009;136:496-504 e3.
- Fattovich G, Giustina G, Christensen E, et al. Influence of hepatitis delta virus infection on morbidity and mortality in compensated cirrhosis type B. The European Concerted Action on Viral Hepatitis (Eurohep). *Gut* 2000;46:420-6.
- Calle Serrano B, Heidrich B, Jaroszewicz J, et al. Long-term outcome of hepatitis delta: A 14-year single center experience. *Hepatology* 2009;50:737A.
- Erhardt A, Gerlich W, Starke C, et al. Treatment of chronic hepatitis delta with pegylated interferon-alpha2b. *Liver Int* 2006;26:805-10.
- Castelnuovo C, Le Gal F, Ripault MP, et al. Efficacy of peginterferon alpha-2b in chronic hepatitis delta: relevance of quantitative RT-PCR for follow-up. *Hepatology* 2006;44:728-35.
- Niro GA, Ciancio A, Gaeta GB, et al. Pegylated interferon alpha-2b as monotherapy or in combination with ribavirin in chronic hepatitis delta. *Hepatology* 2006;44: 713-20.
- Garripoli A, Di Marco V, Cozzolongo R, et al. Ribavirin treatment for chronic hepatitis D: a pilot study. *Liver* 1994;14:154-7.
- Yurdaydin C, Bozkaya H, Gürel S, et al. Famciclovir treatment of chronic delta hepatitis. *J Hepatol* 2002;37:266-71.
- Niro GA, Ciancio A, Tillman HL, et al. Lamivudine therapy in chronic delta hepatitis: a multicentre randomized-controlled pilot study. *Aliment Pharmacol Ther* 2005;22:227-32.
- Yurdaydin C, Bozkaya H, Onder FO, et al. Treatment of chronic delta hepatitis with lamivudine vs lamivudine + interferon vs interferon. *J Viral Hepat* 2008;15:314-21.
- Gunsar F, Akarca US, Ersoz G, et al. Two-year interferon therapy with or without ribavirin in chronic delta hepatitis. *Antivir Ther* 2005;10:721-6.
- Wolters LM, van Nunen AB, Honkoop P, et al. Lamivudine-high dose interferon combination therapy for chronic hepatitis B patients co-infected with the hepatitis D virus. *J Viral Hepat* 2000;7:428-34.
- Kaymakoglu S, Karaca C, Demir K, et al. Alpha interferon and ribavirin combination therapy of chronic hepatitis D. *Antimicrob Agents Chemother* 2005;49: 1135-8.
- Wedemeyer H, Yurdaydin C, Dalekos GN, et al. Peginterferon plus adefovir versus either drug alone for hepatitis delta. *N Engl J Med* 2011;364:322-31.
- Zuberi BF, Afsar S, Quraishy MS. Triple hepatitis: frequency and treatment outcome of co/super-infection of hepatitis C and D among patients of hepatitis B. *J Coll Phys Surg Pak* 2008;18:404-7.
- Gozlan J, Lacombe K, Gault E, et al. Complete cure of HBV-HDV co-infection after 24 weeks of combination therapy with pegylated interferon and ribavirin in

- a patient co-infected with HBV/HCV/HDV/HIV. *J Hepatol* 2009;50:432-4.
31. Jardi R, Rodriguez F, Buti M, et al. Role of hepatitis B, C, and D viruses in dual and triple infection: influence of viral genotypes and hepatitis B precore and basal core promoter mutations on viral replicative interference. *Hepatology* 2001;34:404-10.
  32. Crespo J, Lozano JL, Carte B, et al. Viral replication in patients with concomitant hepatitis B and C virus infections. *Eur J Clin Microbiol Infect Dis* 1997;16:445-51.
  33. Pontisso P, Gerotto M, Ruvoletto MG, et al. Hepatitis C genotypes in patients with dual hepatitis B and C virus infection. *J Med Virol* 1996;48:157-60.
  34. Alberti A, Pontisso P, Chemello L, et al. The interaction between hepatitis B virus and hepatitis C virus in acute and chronic liver disease. *J Hepatol* 1995;22:S38-41.
  35. Pontisso P, Ruvoletto MG, Fattovich G, et al. Clinical and virological profiles in patients with multiple hepatitis virus infections. *Gastroenterology* 1993;105:1529-33.
  36. Zarski JP, Bohn B, Bastie A, et al. Characteristics of patients with dual infection by hepatitis B and C viruses. *J Hepatol* 1998;28:27-33.
  37. Chu CJ, Lee SD. Hepatitis B virus/hepatitis C virus coinfection: epidemiology, clinical features, viral interactions and treatment. *J Gastroenterol Hepatol* 2008;23:512-20.