



Case Series

Would Marjolin see it coming? Two unusual cases of squamous cell carcinoma

Yeela Ben Naftali^{a,*}, Ori Samuel Duek^a, Ram Kalus^a, Marc Berns^a, Yaniv Zohar^b, Yehuda Ullmann^a

^a Department of Plastic & Reconstructive Surgery, Rambam Health Care Campus, Haifa, Israel

^b Department of Pathology, Rambam Health Care Campus, Haifa, Israel

ARTICLE INFO

Article history:

Received 14 March 2018

Received in revised form 14 July 2018

Accepted 29 July 2018

Available online 8 August 2018

Keywords:

Squamous cell carcinoma

Marjolin's ulcer

Abscess

Young patients

ABSTRACT

INTRODUCTION: Cutaneous squamous cell carcinoma (SCC) is a common skin cancer, second in incidence only to basal cell carcinoma (BCC). The incidence of SCC increases significantly with age; thus, it is rarely diagnosed in young patients. In this paper, we present two cases of young patients who presented clinically with purulent lesions that were later diagnosed as large primary SCCs.

MATERIALS AND METHODS: A review of the medical records of two patients who were admitted to the department of plastic surgery with a final clinical diagnosis of cutaneous SCC was conducted. Information of the review included history, physical examination, laboratory tests, imaging studies and histology. A literature review was also conducted and discussed.

RESULTS: Two female patients under the age of 45 presented with large, purulent lesions that were initially clinically suggestive of an infectious etiology. The lesions were surgically treated by incision and drainage without sending tissue samples to pathology. Biopsies of the lesions were performed to obtain a tissue diagnosis due to recurrence approximately one year after the initial treatment. Histological evaluation revealed well differentiated squamous cell carcinomas. Surgical intervention with wide excision with adjuvant chemotherapy was recommended based on biopsy and CT scan results.

DISCUSSION: Aggressive behavior of SCC in young patients is uncommon. The patients in this report were diagnosed only one year after the first sign of the lesion. One patient was first diagnosed with an abscess, and the other with necrotizing fasciitis. The delayed diagnosis of SCC in these two patients is a potential contributing factor to the aggressiveness of the tumors. Therefore, it is imperative to perform skin biopsies of chronic or persistent purulent lesions to rule out malignancies including Marjolin's ulcer.

CONCLUSION: Aggressive SCC should be suspected in cases of persistent and relapsing purulent lesions in all patients.

© 2018 The Authors. Published by Elsevier Ltd on behalf of IJS Publishing Group Ltd. This is an open access article under the CC BY-NC-ND license (<http://creativecommons.org/licenses/by-nc-nd/4.0/>).

1. Introduction

Cutaneous squamous cell carcinoma (SCC) is the second most common skin malignancy after basal cell carcinoma (BCC) and can present with a wide variety of clinical manifestations [1,2]. It accounts for approximately 20% of all nonmelanoma skin cancers in the United States [1–4]. The incidence of SCC increases with age and is 5–10 times higher for those 75 years of age or older [5,6]. There are numerous environmental and genetic risk factors that contribute to the development of SCC, which include UV light, radiation, immunosuppression, chronic inflammation, smoking, HPV

infection, drugs, family history, inherited disorders such as xeroderma pigmentosum and others [1,2,7–10].

SCC is most commonly seen in fair-skinned individuals in locations that are frequently exposed to the sun [11]. A thorough and complete physical examination, including lymph nodes, is necessary to detect potential lesions, and the final diagnosis is made by histopathologic analysis of skin biopsy specimens [1,11,12]. Treatment of SCC involves surgical excision, with radiation and systemic therapy in case of a regional or metastatic disease. The patient specific treatment plan is based on a risk assessment for local recurrence and metastasis [13–16]. Regional lymph node involvement and metastases are rare and associated with increased mortality [17–21]. Although the five-year cure rate is greater than 90%, all patients require long term oncologic follow up even after successful treatment.

* Corresponding author.

E-mail address: yeelab@gmail.com (Y. Ben Naftali).

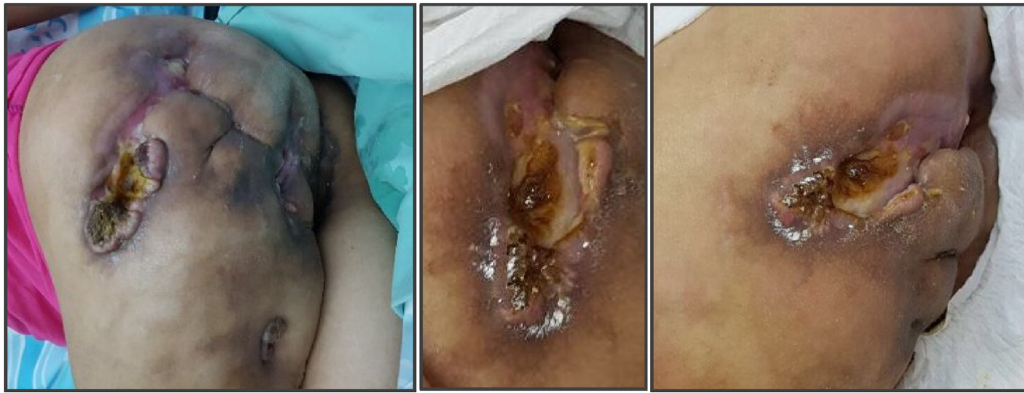

Fig. 1. The gluteal area showing extensive tumor formation with ulcerative surface.

Marjolin's ulcer refers to a rare but highly aggressive ulcerating SCC, which presents as a non-healing wound or painless ulcer [22]. It is associated with chronic inflammatory states, such as venous ulcers, lupus vulgaris, vaccination scars, snake bite scars, pressure sores, osteomyelitis zones and radiotherapy areas. The majority of purulent Marjolin's ulcer lesions described in the literature are pilonidal abscesses [11,22–24].

Here we discuss two cases of rare Marjolin's ulcer in northern Israel.

2. Case reports

2.1. Case 1

A thirty-two-year-old female presenting with a left-sided gluteal abscess was hospitalized in the general surgery department. Her medical history included spina bifida (meningocele) with resultant paraplegia and urinary retention requiring self-catheterization. During the hospitalization, she underwent debridement of the involved gluteal skin and received intravenous antibiotics. However, a biopsy of the affected gluteal tissue was not taken, hence a histopathologic analysis was not performed. The patient was offered a diverting colostomy to keep the abscessed area clean to facilitate healing, however, this intervention was declined. On the second post-operative day, the patient became septic despite receiving intravenous antibiotics. A subsequent CT scan revealed multiple abscesses, which were then incised and drained in the operating room. The patient was discharged following an uneventful postoperative course.

Eight months later, the patient was admitted to our hospital and diagnosed with necrotizing fasciitis in the same left-sided gluteal region. She refused any definitive surgical treatment but agreed to a biopsy, which revealed a well-differentiated squamous cell carcinoma (see Fig. 1). An initial CT scan showed multiple bur-

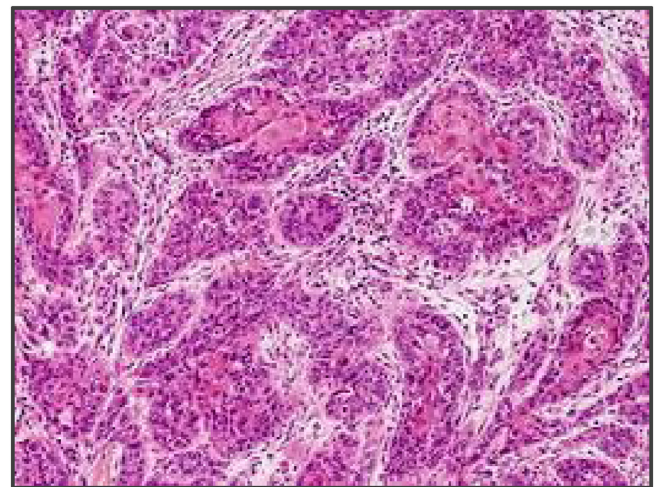


Fig. 3. Histological biopsies confirmed the diagnosis of a well differentiated squamous cell carcinoma.

rows and enlarged lymph nodes (see Fig. 2a–c). Additional CT scans of the thorax and abdomen demonstrated no evidence of distant metastases. Repeat biopsies of the lesion were performed, and the diagnosis of a well differentiated squamous cell carcinoma was confirmed (see Fig. 3).

A multidisciplinary team including plastic surgeons, orthopedic oncologic surgeons, general surgeons and medical oncologists advised her to undergo extensive surgical intervention including hemipelvectomy, abdominoperineal resection (APR) and colostomy. The patient refused any surgical intervention. She was then referred for chemotherapy and began treatment with a regimen of cis-platinum, 5-fluorouracil (5FU), and Erbitux (cetuximab). This chemotherapy was unsuccessful, and the patient passed away

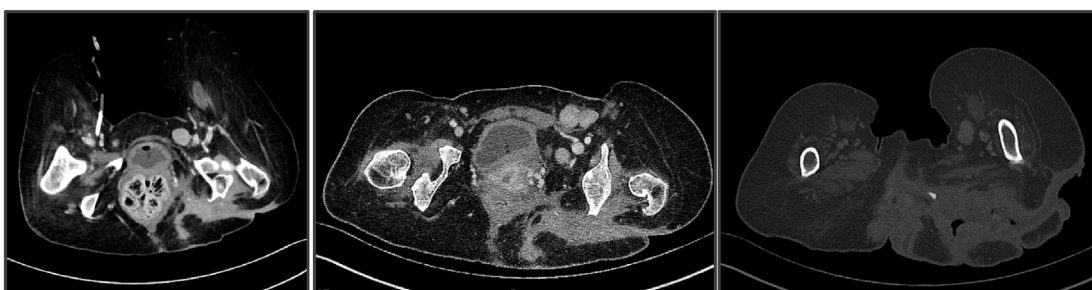


Fig. 2. a–c: CT scan showed multiple burrows and enlarged lymph nodes.

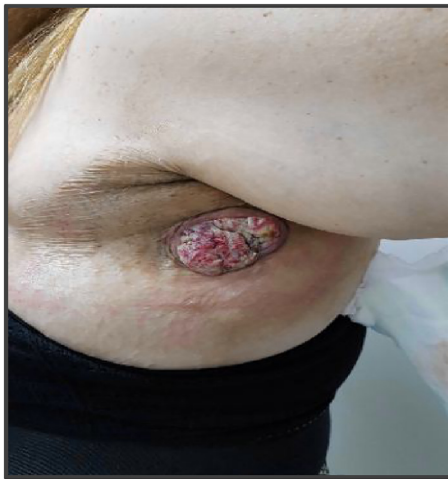

Fig. 4. Left axillary area showing an extensive SCC tumor with ulceration.

within a few months. The extensive spread and aggressive behavior of the lesion was highly suspicious for Marjolin's ulcer arising from a chronic pressure sore.

2.2. Case 2

A forty-two-year-old female with a history of morbid obesity and hypertension, status post bariatric surgery (laparoscopic adjustable gastric banding and sleeve gastrectomy) resulting in a significant weight loss, presented in July 2016 with what was initially diagnosed as an infected epidermal inclusion cyst in the axilla. The patient's family history was significant for breast cancer and melanoma. She was initially treated at an outpatient clinic by a general surgeon who performed an incision and drainage.

One year later, the lesion reappeared, and the clinical signs were highly suspicious for malignancy (see Fig. 4). A biopsy of the lesion was performed, and the histopathologic results confirmed our suspicion of a well-differentiated squamous cell carcinoma. A subsequent CT scan revealed focal calcification within the large primary lesion and an additional axillary mass (3.9 cm) with a necrotic lymph node; there was no additional lymphadenopathy (see Fig. 5 a and b). Four other cysts (7.2 cm) in the anterior thorax wall were also observed.

The patient underwent a wide excision of the lesions under general anesthesia. The histological results showed moderately differentiated SCC with involved margins (see Fig. 6). Soon after receiving these results, the patient underwent a second surgery, which included a wide excision and additional dissection of nine lymph nodes. The pathology results showed SCC with free margins and lymph nodes without metastasis. The patient is currently being

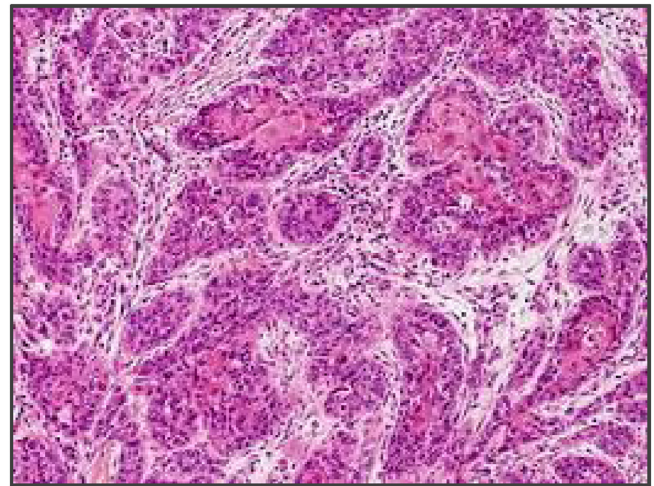


Fig. 6. The histological results showed moderately differentiated SCC with involved margins.

monitored regularly at our clinic and has been referred to oncology for radiation treatment.

3. Discussion

SCC is a common cutaneous malignancy that is rarely aggressive unlike the presentations in these two cases. One explanation of the aggressive nature of the SCC in our cases might be related to their delayed diagnoses. In addition, the presentation of Marjolin's ulcer in unusually young patients may further explain the tumors' aggressive behavior. Although it is very uncommon for this aggressive tumor to appear at an early age [1–4], our cases demonstrate the importance of having a wide differential diagnosis and high level of suspicion for malignancy when treating a chronic wound. The probable chronic irritation and inflammation, combined with the toxin and co-carcinogen theories, may shed light on the evolution of these rapidly evolving ulcerated carcinomas [11,24].

There is a paucity of literature describing Marjolin's ulcer cases in the setting of pressure sores of spina bifida patients or epidermal inclusion cysts [11,20,24,25]. Hence, the natural history of the ulcerated tumors presented in these two cases remains a mystery. However, the aggressive nature of this disease emphasizes the need for early tissue biopsy of purulent lesions that present in the setting of chronic or non-healing wounds.

There are numerous Treatment options for low risk SCC tumors [26,27] including surgical excision, cryotherapy, electrosurgery, topical treatment, radiation and photodynamic therapy. The risk of recurrence and metastasis is important for determining the appropriate treatment [13–23]. Marjolin's ulcer falls into the category of

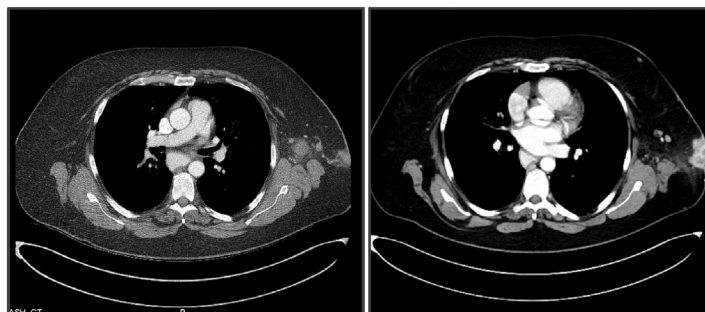


Fig. 5. a and b: The CT scan revealed focal calcification within the large lesion, an additional axillary mass (3.9 cm) with a necrotic lymph node and no additional lymphadenopathy. Four other cysts (7.2 cm) in the anterior thorax wall were also observed.

high risk tumors. In these cases, surgery is still the cornerstone of treatment with adjuvant chemotherapy and radiation if necessary. Although the prognosis is excellent for low risk tumors, high risk lesions are associated with increased mortality and require lifelong monitoring, such as the two cases presented here [17–24].

The work presented in this paper meets the PROCESS criteria [28].

4. Conclusion

These two cases of highly aggressive SCC in relatively young patients demonstrate the importance of having an increased suspicion of malignancy when evaluating non-healing wounds with or without infection, even in non-sun-exposed locations. Thus, we recommend having a low threshold to perform biopsies in this setting in order to ensure the correct diagnosis is made to facilitate early intervention.

Ethical approval

Ethical approval has been exempted by our institution.

Funding

None.

Conflict of interest statement

None.

Guarantor

Dr. Yeela.

Consent

For one patient, we have written informed consent was obtained from the patient for publication of this case report and accompanying images. A copy of the written consent is available for review by the Editor-in-Chief of this journal on request.

For the other patient we could not get signed consent, so head of the medical team-hospital takes responsibility that exhaustive attempts have been made to contact the family and that the paper has been sufficiently anonymised not to cause harm to the patient or their family.- uploaded sign document.

Author contribution

Dr. Yeela – study concept or design, data collection, data analysis or interpretation, writing the paper.

Research registration number

researchregistry3876.

References

- [1] Epidemiology and Risk Factors for Cutaneous Squamous Cell Carcinoma, 2018 <http://www.uptodate.com>.

- [2] American Cancer Society, Cancer Facts and Figures, 2003 (Accessed on 01 April 2004) www.cancer.org/docroot/STT/stt_0_2003.asp?sitearea=STT&level=1.
- [3] D.L. Miller, M.A. Weinstock, Nonmelanoma skin cancer in the United States: incidence, *J. Am. Acad. Dermatol.* 30 (1994) 774.
- [4] M. Alam, D. Ratner, Cutaneous squamous-cell carcinoma, *N. Engl. J. Med.* 344 (2001) 975.
- [5] M.R. Karagas, E.R. Greenberg, S.K. Spencer, et al., Increase in incidence rates of basal cell and squamous cell skin cancer in New Hampshire, USA. New Hampshire Skin Cancer Study Group, *Int. J. Cancer* 81 (1999) 555.
- [6] D.T. Gray, V.J. Suman, W.P. Su, et al., Trends in the population-based incidence of squamous cell carcinoma of the skin first diagnosed between 1984 and 1992, *Arch. Dermatol.* 133 (1997) 735.
- [7] D.E. Brash, J.A. Rudolph, J.A. Simon, et al., A role for sunlight in skin cancer: UV-induced p53 mutations in squamous cell carcinoma, *Proc. Natl. Acad. Sci. U. S. A.* 88 (1991) 10124.
- [8] K.Y. Tsai, H. Tsao, The genetics of skin cancer, *Am. J. Med. Genet. C Semin. Med. Genet.* 131C (2004) 82.
- [9] P.P. Vitaliano, F. Urbach, The relative importance of risk factors in nonmelanoma carcinoma, *Arch. Dermatol.* 116 (1980) 454.
- [10] R.P. Gallagher, G.B. Hill, C.D. Bajdik, et al., Sunlight exposure, pigmentation factors, and risk of nonmelanocytic skin cancer. II. Squamous cell carcinoma, *Arch. Dermatol.* 131 (1995) 164.
- [11] Clinical Features and Diagnosis of Cutaneous Squamous Cell Carcinoma (SCC), 2018 <http://www.uptodate.com>.
- [12] Part II head and neck, in: M.B. Amid (Ed.), *AJCC Cancer Staging Manual*, 8th ed., Springer, New York, 2017, p. 53.
- [13] Ad Hoc Task Force, S.M. Connolly, D.R. Baker, et al., AAD/ACMS/ASDSA/ASMS 2012 appropriate use criteria for Mohs micrographic surgery: a report of the American academy of dermatology, american college of mohs surgery, american society for dermatologic surgery association, and the american society for mohs surgery, *J. Am. Acad. Dermatol.* 67 (2012) 531.
- [14] L. Lansbury, F. Bath-Hextall, W. Perkins, et al., Interventions for non-metastatic squamous cell carcinoma of the skin: systematic review and pooled analysis of observational studies, *BMJ* 347 (2013) f6153.
- [15] L. Lansbury, J. Leonardi-Bee, W. Perkins, et al., Interventions for non-metastatic squamous cell carcinoma of the skin, *Cochrane Database Syst. Rev.* (2010), CD007869.
- [16] D.G. Brodland, J.A. Zitelli, Surgical margins for excision of primary cutaneous squamous cell carcinoma, *J. Am. Acad. Dermatol.* 27 (1992) 241.
- [17] D.E. Rowe, R.J. Carroll, C.L. Day Jr., Prognostic factors for local recurrence, metastasis, and survival rates in squamous cell carcinoma of the skin, ear, and lip. Implications for treatment modality selection, *J. Am. Acad. Dermatol.* 26 (1992) 976.
- [18] R.E. Kwa, K. Campana, R.L. Moy, Biology of cutaneous squamous cell carcinoma, *J. Am. Acad. Dermatol.* 26 (1992) 1.
- [19] D.H. Kraus, J.F. Carew, L.B. Harrison, Regional lymph node metastasis from cutaneous squamous cell carcinoma, *Arch. Otolaryngol. Head Neck Surg.* 124 (1998) 582.
- [20] N. Michalopoulos, K. Sपालιδις, S. Laskou, E. Triantafyllou, G. Raptou, I. Kesisisoglou, Squamous cell carcinoma arising from chronic sacrococcygeal pilonidal disease: a case report, *World J. Surg. Oncol.* 15 (1) (2017) 65.
- [21] Treatment and Prognosis of Cutaneous Squamous Cell Carcinoma, 2018 <http://www.uptodate.com>.
- [22] M.A. Kerr-Valentic, K. Samimi, B.H. Rohlen, J.P. Agarwal, W.B. Rockwell, Marjolin's ulcer: modern analysis of an ancient problem, *Plast. Reconstr. Surg.* 123 (2009) 184–191.
- [23] N.G. Fairbairn, S.A. Hamilton, Management of Marjolin's ulcer in a chronic pressure sore secondary to paraplegia: a radical surgical solution, *Int. Wound J.* 8 (5) (2011) 533–536.
- [24] P.M. Nthumba, Marjolin's ulcers: theories, prognostic factors and their peculiarities in spina bifida patients, *World J. Surg. Oncol.* 8 (2010) 108–110.
- [25] Tadashi Terada, Squamous cell carcinoma originated from an epidermal cyst, *Int. J. Clin. Exp. Pathol.* 5 (5) (2012) 479–481.
- [26] NCCN Guidelines™ and Clinical Resources, 2018 (Accessed on 22 June 2013) http://www.nccn.org/professionals/physician_gls/pdf/nmsc.pdf.
- [27] S. Farasat, S.S. Yu, V.A. Neel, et al., A new American Joint Committee on Cancer staging system for cutaneous squamous cell carcinoma: creation and rationale for inclusion of tumor (T) characteristics, *J. Am. Acad. Dermatol.* 64 (2011) 1051.
- [28] R.A. Agha, A.J. Fowler, S. Rammohan, I. Barai, D.P. Orgill, PROCESS Group, The PROCESS Statement: preferred reporting of case series in surgery, *Int. J. Surg.* 36 (Pt A) (2016) 319–323.

Open Access

This article is published Open Access at sciendo.com. It is distributed under the IJSCR Supplemental terms and conditions, which permits unrestricted non commercial use, distribution, and reproduction in any medium, provided the original authors and source are credited.