

## Case Report

## Open Access

Ali Riza Cenk Celebi\*, Ayse Ebru Kilavuzoglu, Ugur Emrah Altiparmak, Cemile Banu Cosar, Abdullah Ozkiris

# Retinal tear: an unusual complication of ocular toxoplasmosis

DOI: 10.1515/med-2015-0094

received September 22, 2015; accepted October 18, 2015

**Abstract:** Purpose: It is aimed to report on a 16-year-old patient with acquired ocular toxoplasmosis complicated by a retinal tear.

Methods: Retrospective medical chart review

Results: A 16-year-old Caucasian female presented with vision loss in her right eye. In addition to a white active lesion between the fovea and the optic nerve head, marked vitreous opacification was noted. She was diagnosed with ocular toxoplasmosis. The patient was treated with oral azithromycin, clindamycin, and trimethoprim-sulfamethoxazole. One month later, retinochoroiditis resolved and vitreous cleared. Three months after onset, patient presented with floaters in the right eye and a retinal tear was located at the temporal region of the retina. Prophylactic argon laser treatment that encircled the retinal tear was performed. No other abnormalities were noted during 6 months of follow-up.

Conclusions: Retinal tear associated with ocular toxoplasmosis is rare; however, a retinal tear can occur due to vitreoretinal traction following post-inflammatory structural alteration of the vitreous. Retinal tears may be seen during the healing phase, when the inflammation turns into tightening of vitreous substance. Careful retinal examination in cases of ocular toxoplasmosis is warranted, especially in patients with severe vitreous inflammation.

**Keywords:** Ocular toxoplasmosis, retinal tear, argon laser photocoagulation, vitreoretinal traction, vitreous inflammation

\*Corresponding author: Ali Riza Cenk Celebi, Acibadem University School of Medicine Department of Ophthalmology Turgut Ozal Boulevard, No:16 Pbx: 34303 Kucukcekmece, Istanbul, Turkey, Tel: 90 212 404 40 84 Fax: 90 212 404 48 39, E-mail: cenk.celebi@acibadem.edu.tr, arcenkcelebi@gmail.com

Ayşe Ebru Kilavuzoglu, Ugur Emrah Altiparmak, Cemile Banu Cosar, Abdullah Ozkiris, Acibadem University School of Medicine Department of Ophthalmology Istanbul/Turkey

## 1 Introduction

*Toxoplasma gondii* infection is well known and occurs worldwide; toxoplasmic retinochoroiditis is the most common form of posterior uveitis caused by *T. gondii* in otherwise healthy individuals [1]. Toxoplasmic retinochoroiditis accounted for 7.2% of all cases of uveitis in a referral center in Turkey [2]. Classically, toxoplasmic retinochoroiditis appears as a focus of inner retinitis adjacent to an old chorioretinal scar, and is accompanied by vitritis. Active ocular toxoplasmosis, also caused by *T. gondii*, is characterized by focal necrotizing retinochoroiditis, which in 90 percent of cases is unilateral [2]. During the healing process the acute lesions resolves, leaving a chorioretinal scar with well-defined hyperpigmented borders and central chorioretinal atrophy [3]. Nonetheless, considerable variation in the clinical features of ocular toxoplasmosis led some to consider if atypical cases represent different forms of the disease [4]. Vitreoretinal complications of toxoplasmic retinochoroiditis include retinal tear, exudative and/or rhegmatogenous retinal detachment, vitreous hemorrhage, epiretinal membrane, and choroidal neovascularization [5]. Herein we report on a patient with acquired ocular toxoplasmosis complicated by a retinal tear. To the best of our knowledge, the presented case is the youngest with acquired ocular toxoplasmosis complicated by a retinal tear.

## 2 Case presentation

A 16-year-old Caucasian female presented to our department with sudden vision loss in her right eye. Systemic evaluation was negative for any systemic illnesses. She was not on any systemic medications nor had a family history of eye illnesses. Visual acuity was count-fingers at 50 cm in the right eye and 20/20 with -1.75 diopter spherical correction in the left eye. There was +2 aqueous cells in the anterior chamber and +2 anterior vitreous cells in

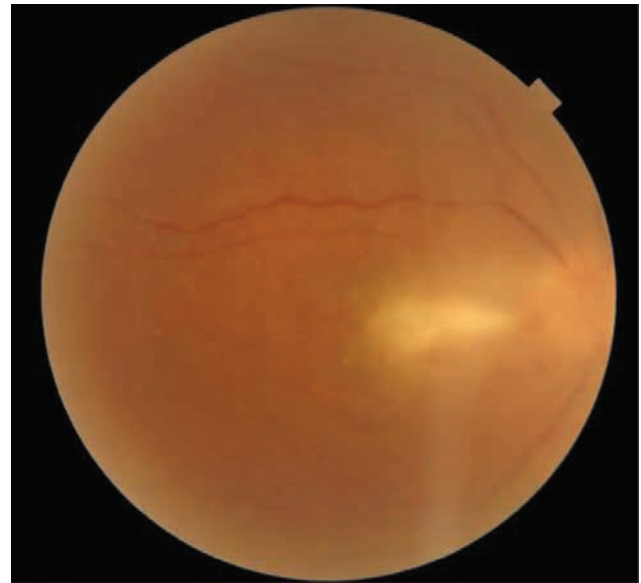
the right eye. Corneal endothelial mutton-fat keratic precipitates were also noted in the right eye. Slit-lamp examination of the left eye was unremarkable. Intraocular pressure was 14 mmHg in both eyes.

Dilated funduscopy examination revealed a diffuse, elevated white-yellow lesion in the right retina with 1.5 times the diameter of the optic disc in size that was located half a disc diameter temporal to the optic nerve head. Focal condensation of inflammatory cells in the vitreous was observed overlying an area of active chorioretinitis (Figure 1). Chest x-ray, complete blood count, and serum biochemistry, including angiotensin-converting enzyme, were within normal limits. Purified protein derivative of tuberculin was negative. Titers for *Toxoplasma gondii* -specific IgM (3.1 IU/mL) and IgG (4.3 IU/mL) were elevated. The patient was consulted to the pulmonology department due to suspicion of tuberculosis and sarcoidosis, both of which were ruled out. Based on the serological findings and clinical presentation, the ocular toxoplasmosis was diagnosed.

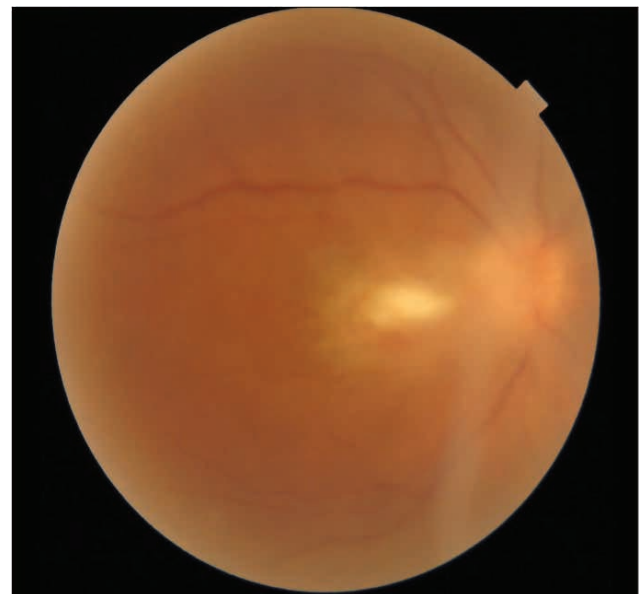
The patient was put on oral clindamycin 300 mg q.i.d, azithromycin 500 mg q.d, and trimethoprim-sulfamethoxazole 800/160 mg q.d, and for the right eye only topical anti-inflammatory treatment with prednisolone acetate ophthalmic every two hours and tropicamide ophthalmic t.i.d. After 1 week of treatment, the patient's visual acuity in the right eye increased to 20/160. Dilated funduscopy examination of the right eye showed a decrease in vitreous haze (Figure 2). After 1 month of treatment visual acuity in the right eye was 20/60 and dilated funduscopy examination of the right eye showed a decrease in the size of the macular infiltrate (Figure 3).

After 3 months of treatment, the patient presented with complaints of flashing lights and floaters in her right eye. Dilated funduscopy examination showed a horseshoe retinal tear at the 9 o'clock position. The retinal tear was treated with Argon laser photocoagulation immediately (Figure 4). At the 6-month follow-up visual acuity in the right eye was 20/40 and slit-lamp examination findings were within normal limits. Additionally, dilated funduscopy examination of the right eye showed fibrotic tissue at the toxoplasmic retinochoroiditis spot, and active vitreous inflammation was not noted. Furthermore, the horseshoe retinal tear was well circumscribed with laser scars (Figure 5).

The research related to human use has been complied with all the relevant national regulations, institutional policies and in accordance the tenets of the Helsinki Declaration.



**Figure 1.** The patient's funduscopy examination at initial presentation showed dense vitreous inflammation with yellow-white macular infiltrate.

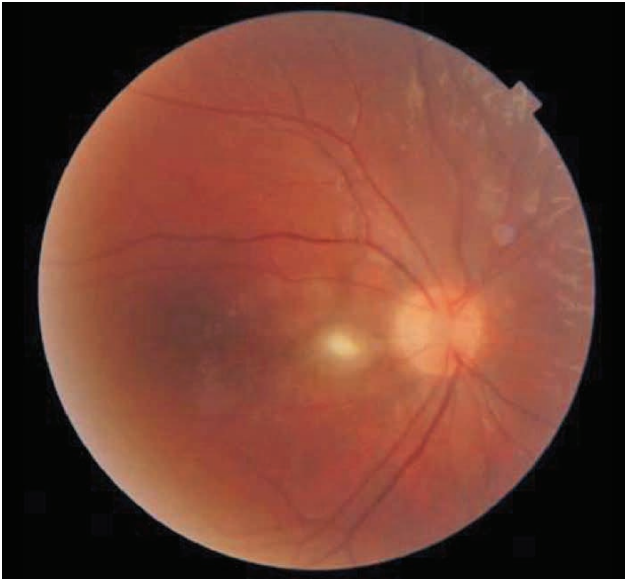


**Figure 2.** After 1 week of treatment, funduscopy showed a decrease in vitreous inflammation.

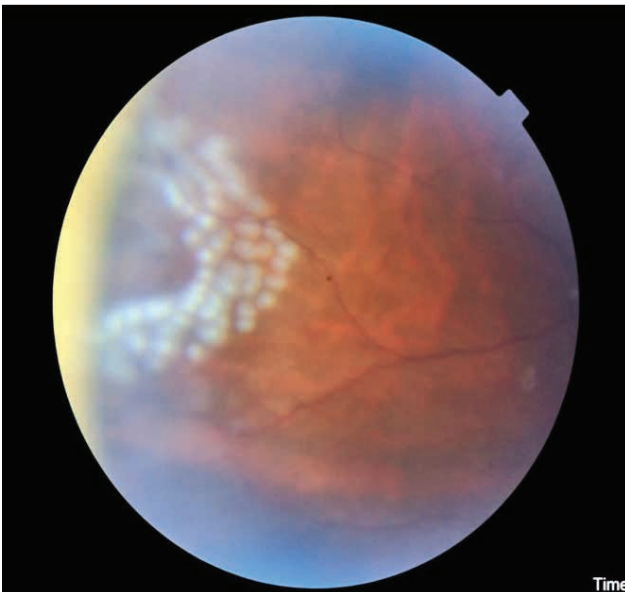
Patient's written consent was obtained regarding the fundus images that were used in this manuscript.

### 3 Discussion

The hallmark of the ocular toxoplasmosis includes focal necrotizing retinochoroiditis that results in a characteristic adjacent or nearby retinochoroidal atrophic scar.

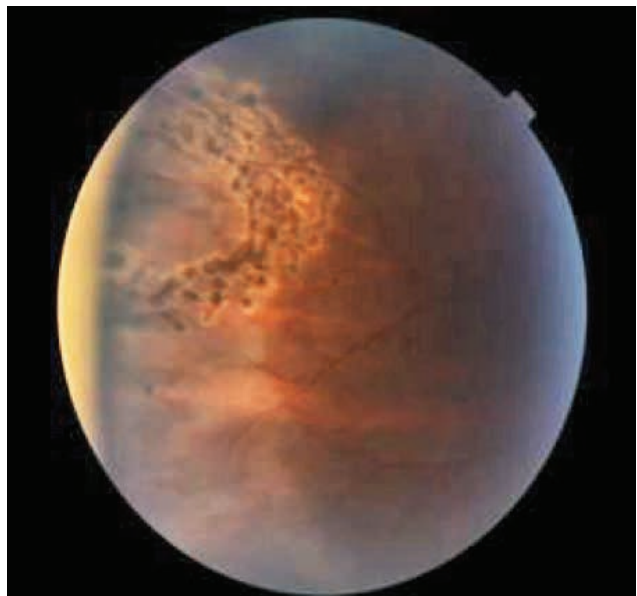
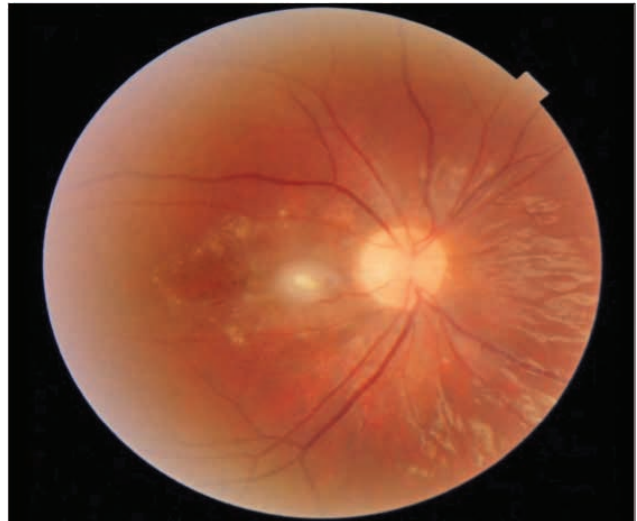

**Figure 3.** After 1 month of treatment funduscopy examination showed a marked decrease in vitreous inflammation and a decrease in the size of the macular infiltrate.



**Figure 4.** Dilated funduscopy examination showed a new horseshoe retinal tear that was circumscribed with Argon laser photocoagulation.

However, a variety of less common, “atypical” presentations may occur; punctate outer retinal toxoplasmosis, retinal vasculitis, retinal vascular occlusions, rhegmatogenous and serous retinal detachments, unilateral pigmentary retinopathy mimicking retinitis pigmentosa, neuroretinitis and other forms of optic neuropathy, and scleritis [6]. The presented case had ocular toxoplasmosis complicated by a retinal tear. The precise frequency of retinal tears in patients with ocular toxoplasmosis is unknown, though toxoplasmic retinochoroiditis cases with retinal



**Figure 5.** At the 6-month follow-up dilated funduscopy examination showed no vitreous inflammation and that the horseshoe retinal tear was circumscribed by old pigmented Argon laser photocoagulation scars.

tear have been reported. A study that included 150 consecutive patients with toxoplasmic retinochoroiditis reported that 5% of patients had retinal tears [7]. The same study showed that attacks of active ocular toxoplasmosis preceded retinal tears were characterized by severe intraocular inflammation. The occurrence of retinal tears in patients with uveitis may be related to early posterior vitreous detachment caused by the intraocular inflammatory process [8]. Bodanowitz et al. [9] reported that retinal tear in patients with retinitis is associated with toxoplasmosis and that retinal tear is a rare complication of toxoplasmic retinochoroiditis. It was proposed that a retinal tear could occur due to vitreoretinal traction following structural alteration of the vitreous.

It is noteworthy that in over 90 percent of acquired cases, attacks of active ocular toxoplasmosis characterized by severe intraocular inflammation preceded retinal tear. Vitritis in patients with ocular toxoplasmosis, varying in severity, is quite common and can even be an initial finding before the development of retinitis. As the area of retinochoroiditis increases there is a tendency for the severity of vitritis to increase [10]. Dense vitreous inflammation in cases of ocular toxoplasmosis and retinal tear was observed, and profuse inflammation of the vitreous tissue was reported to be the cause of retinal tears [9]. Lafaut *et al.* [11] reported that proliferative protrusion of the sensory retinal layer and a secondary scar caused by ocular toxoplasmosis cause retinal tear in patients with active ocular toxoplasmosis due to severe intraocular inflammation.

The use of corticosteroids for ocular toxoplasmosis remains controversial; these drugs are primarily used to alleviate severe inflammation and, as such, might play a role in the development of vitreoretinal traction and pre-retinal membranes [12]. An earlier study reported that 4 patients with ocular toxoplasmosis and retinal tear used systemic corticosteroids together with anti-parasitic agents before the onset of ocular toxoplasmosis. The researchers posited that corticosteroid monotherapy might induce extremely severe inflammation resulting in fulminant ocular disease; therefore it is not recommended [13].

Visual prognosis of retinal detachment due to retinal tear as a complication of ocular toxoplasmosis was reported to be very poor, as legal blindness occurs in 56% of cases [14]. It was also reported that patients with an attached retinal tear retained their visual potential, which might be because the retinal tears were diagnosed during ophthalmological examinations performed for an active attack of ocular toxoplasmosis, resulting in early treatment [15]. It was posited that laser treatment of asymptomatic attached retinal tears in an eye with recurrent intraocular inflammation is justified. First, there is the additional risk of vitreous traction and secondly the visual prognosis after surgical repair for retinal detachment in ocular toxoplasmosis was poor [12]. Extra-macular and macular localization of retinitis were not associated with an increase in the risk of retinal detachment, although extra-macular lesions were associated with more severe vitreous inflammation [10].

Tugal-Tutkun *et al.* [16] reported that there was not a gender predilection and that 86.2% of patients diagnosed as ocular toxoplasmosis were aged <35 years. Numerous studies have shown that the severity of ocular toxoplasmosis increases with age [17, 18]. The presented case was aged 16 years at the time of diagnosis and to the best of

our knowledge is the youngest case of ocular toxoplasmosis complicated by retinal tear. The presented patient had a macular lesion. Macular or juxtapapillary involvement with active lesions was reported to be significantly more common in previously uninvolved eyes than in eyes with preexisting scars. The rich blood supply of the macular region of the choroid may explain the predilection for this area if dissemination to the eye from other sites is presumed to occur in patients with primary ocular toxoplasmosis [16].

## 4 Conclusion

Retinal tear associated with ocular toxoplasmosis is rare; however, a retinal tear can occur due to vitreoretinal traction following post-inflammatory structural alteration of the vitreous. Retinal tears may be seen during the healing phase, when the inflammation turns into tightening of vitreous substance. As such, we recommend careful retinal examination in patients with ocular toxoplasmosis, especially patients with severe intraocular vitreous inflammation. In cases of toxoplasmic retinochoroiditis diagnostic attention should not be limited to evaluation of the optical transparency of the vitreous; the vitreous structure should also be assessed and, if changes are noted, funduscopy should be repeated in order to find any retinal tears in a timely fashion.

**Conflict of interest statement:** Authors state no conflict of interest

## References

- [1] McCannel C.A., Holland G.N., Helm C.J., Cornell P.J., Winston J.V., Rimmer T.G., Causes of uveitis in the general practice of ophthalmology. *UCLA Community-Based Uveitis Study Group*, *Am. J. Ophthalmol.*, 1996, 121, 35-46
- [2] Sengun A., Karadağ R., Karakurt A., Sarıcaoğlu M.S., Abdik O., Hasiripi H., Causes of uveitis in a referral hospital in Ankara, Turkey, *Ocul. Immunol. Inflamm.*, 2005, 13, 45-50
- [3] Holland G.N., O'Connor G.R., Belfort R. Jr., Remington J.S., Toxoplasmosis. In: Pepose J.S., Holland G.N., Wilhelmus K.R. eds., *Ocular Infection & immunity*, 1st edn., Mosby, St Louis, MO, pp 1183-1223
- [4] Klaren V., Kijlstra A., Toxoplasmosis, an overview with emphasis on ocular involvement., *Ocul. Immunol. Inflamm.*, 2002, 10, 1-26
- [5] Adan A., Giralt J., Alvarez G., Alforja S., Burés-Jeslstrup A., Casaroli-Marano R.P., Corcostegui B., Pars plana vitrectomy

- for vitreoretinal complications of ocular toxoplasmosis, *Eur. J. Ophthalmol.*, 2009, 19, 1039-1043
- [6] Perrotta S., Nobili B., Grassia C., Sebastiani A., Parmeggiani F., Costagliola C., Bilateral neuroretinitis in a 6-year-old boy with acquired toxoplasmosis, *Arch. Ophthalmol.*, 2003, 121, 1493-1496
- [7] Bosch-Driessen L.H., Karimi S., Stilma J.S., Rothova A., Retinal detachment in ocular toxoplasmosis, *Ophthalmology*, 2000, 107, 36-40
- [8] Lucena Dda R., Ribeiro J.A., Lucena Dda R., de Lucena A.L., Jorge R. [Retinal tears in toxoplasmic retinochoroiditis: case series], *Arq. Bras. Oftalmol.* 2009, 72, 829-831
- [9] Bodanowitz S., Hesse L., Schroeder B. [Retinal tear in retinochoroiditis toxoplasmodica], *Klin. Monbl. Augenheilkd.* 1996, 208, 130-131
- [10] Dodds E.M., Holland G.N., Stanford M.R., Yu F., Siu W.O., Shah K.H., Ten Dam-van Loon N., Muccioli C., Hovakimyan A., Barisani-Asenbauer T.; International Ocular Toxoplasmosis Research Group, Intraocular inflammation associated with ocular toxoplasmosis: relationships at initial examination. *Am. J. Ophthalmol.* 2008, 146, 856-865
- [11] Lafaut B.A., Meire F.M., Leys A.M., Dralands G., De Laey J.J., Vasoproliferative retinal tumors associated with peripheral chorioretinal scars in presumed congenital toxoplasmosis, *Graefes. Arch. Clin. Exp. Ophthalmol.* 1999, 237, 1033-1038
- [12] Kianersi F., Naderi Beni A., Ghanbari H., Fazel F., Ocular toxoplasmosis and retinal detachment: five case reports. *Eur. Rev. Med. Pharmacol. Sci.* 2012, 16, 84-89
- [13] Bosch-Driessen E.H., Rothova A., Sense and nonsense of corticosteroid administration in the treatment of ocular toxoplasmosis, *Br. J. Ophthalmol.* 1998, 82, 858-860
- [14] Bosch-Driessen L.E., Berendschot T.T., Ongkosuwito J.V., Rothova A., Ocular toxoplasmosis: clinical features and prognosis of 154 patients, *Ophthalmology* 2002, 109, 869-878
- [15] Desmettre T., Labalette P., Fortier B., Mordon S., Constantinides G., Laser photocoagulation around the foci of toxoplasmic retinochoroiditis: a descriptive statistical analysis of 35 patients with long-term follow-up, *Ophthalmologica* 1996, 210, 90-94
- [16] Tugal-Tutkun I., Corum I., Otük B., Urgancıoğlu M., Active ocular toxoplasmosis in Turkish patients: a report on 109 cases, *Int. Ophthalmol.* 2005, 26, 221-228
- [17] Fardeau C., Romand S., Rao N.A., Cassoux N., Bettembourg O., Thulliez P., Lehoang P., Diagnosis of toxoplasmic retinochoroiditis with atypical clinical features. *Am. J. Ophthalmol.* 2002, 134, 196-203
- [18] Johnson M.W., Greven G.M., Jaffe G.J., Sudhalkar H., Vine A.K., Atypical, severe toxoplasmic retinochoroiditis in elderly patients, *Ophthalmology* 1997, 104, 48-57