

# Docetaxel, oxaliplatin, 5FU, and trastuzumab as first-line therapy in patients with human epidermal receptor 2-positive advanced gastric or gastroesophageal junction cancer

## Preliminary results of a phase II study

Giandomenico Roviello, MD<sup>a,\*</sup>, Roberto Petrioli, MD<sup>b</sup>, Valerio Nardone, MD<sup>c</sup>, Pietro Rosellini, MD<sup>b</sup>, Andrea Giovanni Multari, MD<sup>d</sup>, Raffaele Conca, MD<sup>a</sup>, Michele Aieta, MD<sup>a</sup>

### Abstract

The aim of this study is to report first preliminary results of patients enrolled in a phase II study that will investigate the activity and safety of docetaxel, oxaliplatin, and 5-fluorouracil (DOF) in combination with trastuzumab in human epidermal receptor-2 (HER-2) positive patients with advanced gastric or gastroesophageal junction (GEJ) cancer.

Treatment consisted of docetaxel 70 mg/m<sup>2</sup> combined with oxaliplatin 130 mg/m<sup>2</sup> on day 1, and continuous infusion 5-fluorouracil mg/m<sup>2</sup> days 1–5 plus trastuzumab at the standard dose on day 1, every 3 weeks for a maximum of 8 cycles.

Fifteen patients were enrolled. The overall response rate was 60%. The median progression-free survival was 9.2 months (95% confidence interval [CI], 4.4–10.1 months) and the median overall survival was 19.4 months (95% CI, 8.9–21.1 months). Grade 3 neutropenia was observed in 3 patients (20%).

The DOF plus trastuzumab seems active in HER-2 positive advanced gastric or GEJ cancer, final results of the phase II study are awaited.

**Abbreviations:** CR = complete response, DCR = disease-control rate, DOF = docetaxel/oxaliplatin/5-FU, EOF = epirubicin/oxaliplatin/5-fluorouracil, GEJ = gastroesophageal junction, HER2 = human epidermal receptor 2, NCI = National Cancer Institute, OS = overall survival, PD = progressive disease, PFS = progression free survival, PR = partial response, SD = stable disease.

**Keywords:** docetaxel, fluorouracil, gastric cancer, human epidermal receptor-2, oxaliplatin, trastuzumab

## 1. Introduction

Gastric or gastroesophageal junction (GEJ) cancer is considered one of the most important cause of death related to cancer in

Editor: Qinhong Zhang.

No author has actual or potential conflicts of interest, including any financial, personal, or other relationships with other people or organizations within 3 years of beginning the submitted work that could influence, or be perceived to influence, their work.

Supplemental Digital Content is available for this article.

<sup>a</sup> Division of Medical Oncology, Department of Onco-Hematology, Scientific Institute for Research, Hospitalisation and Health Care-Referral Cancer Center of Basilicata, Referral Cancer Center of Basilicata, Vulture (PZ), <sup>b</sup> Medical Oncology Unit, Department of Medicine, Surgery and Neurosciences, <sup>c</sup> Radiotherapy Unit, Department of Medicine, Surgery and Neurosciences, University of Siena, Siena, <sup>d</sup> Unit of Medical Oncology, Department of Oncology, Ospedale San Donato, Arezzo, Italy.

\* Correspondence: Giandomenico Roviello, Division of Medical Oncology, Department of Onco-Hematology, Scientific Institute for Research, Hospitalisation and Health Care-Referral Cancer Center of Basilicata, via Padre Pio 1, 85028 Rionero, Vulture (PZ), Italy, Italy (e-mail: giandomenicoroviello@hotmail.it).

Copyright © 2018 the Author(s). Published by Wolters Kluwer Health, Inc. This is an open access article distributed under the terms of the Creative Commons Attribution-Non Commercial License 4.0 (CCBY-NC), where it is permissible to download, share, remix, transform, and buildup the work provided it is properly cited. The work cannot be used commercially without permission from the journal.

Medicine (2018) 97:20(e10745)

Received: 5 June 2017 / Accepted: 24 April 2018

<http://dx.doi.org/10.1097/MD.00000000000010745>

Europe.<sup>[1]</sup> Surgical resection is the standard for long-term curative results,<sup>[2,3]</sup> unfortunately only one-third of patients are ideal candidates to radical surgery while for patients with locally advanced or metastatic disease at diagnosis, systemic chemotherapy with a platinum compound and a fluoropyrimidine is considered the standard of treatment.<sup>[4]</sup> However, several studies have proposed a triplet drug combinations with the addition of taxane or anthracycline<sup>[5]</sup> and recently a meta-analysis has suggested similar activity of docetaxel and epirubicin-based chemotherapeutic regimens.<sup>[5]</sup> In this context, we previously reported that a sequential treatment with a triplet combination of epirubicin/oxaliplatin/5-fluorouracil (EOF) and docetaxel/oxaliplatin/5-FU (DOF) is active against metastatic gastroesophageal cancer.<sup>[6]</sup>

Trastuzumab is a humanized recombinant monoclonal antibody that selectively binds to the extracellular domain of human epidermal receptor 2 (HER2).<sup>[7]</sup> The trastuzumab for gastric cancer (ToGA) trial evaluated the combination of trastuzumab with a cisplatin/fluoropyrimidine chemotherapy doublet in patients with previously untreated advanced HER2-positive gastroesophageal cancer<sup>[8]</sup> showing a survival benefit. However, little data are available on efficacy and toxicity of a triplet taxane-based regimen chemotherapy for HER2-positive gastroesophageal tumors. Therefore, we investigated the feasibility and preliminary efficacy of DOF chemotherapy in combination with trastuzumab as first line in patients with gastroesophageal cancer, hereby we report the results of first 15 patients with a brief overview of literature.

**Table 1****Characteristics of patients and response to treatment.**

Patient	Age	Sex	ECOG	Tumor location	Gastric cancer type	Primary tumor resected	No. of sites of disease	Previous adjuvant chemotherapy	HER2 status
1	62	M	0	Stomach	Mixed	Yes	1	No	3+
2	64	M	0	Stomach	Intestinal	No	3	No	3+
3	68	M	1	Gastroesophageal junction	Intestinal	No	2	No	3+
4	74	F	1	Stomach	Intestinal	Yes	2	Yes	3+
5	45	M	0	Stomach	Intestinal	No	1	No	3+
6	60	M	1	Gastroesophageal junction	Intestinal	No	4	No	3+
7	69	F	0	Stomach	Diffuse	No	3	No	3+
8	53	F	0	Stomach	Intestinal	No	1	No	3+
9	48	M	0	Stomach	Mixed	No	6	No	3+
10	63	M	0	Stomach	Intestinal	Yes	2	No	3+
11	65	F	0	Stomach	Intestinal	No	2	No	3+
12	38	M	0	Stomach	Intestinal	No	1	No	2+
13	71	M	1	Gastroesophageal junction	Diffuse	Yes	4	Yes	3+
14	44	F	1	Stomach	Mixed	No	3	No	2+
15	54	M	0	Stomach	Intestinal	No	1	No	3+

HER2 = human epidermal receptor 2.

## 2. Methodology

The complete methodology is reported in supplementary data, <http://links.lww.com/MD/C247>, we briefly describe here for convenience. The study enrolled patients with histologically proven advanced adenocarcinoma of the stomach or GEJ HER2-positive tumors who had not previously received chemotherapy for advanced disease. The other eligibility criteria included age >18 years, Eastern Cooperative Oncology Group performance status of 0 to 1, bidimensionally measurable disease, a life expectancy of at least 6 months, adequate hematological and biochemical parameters, baseline left ventricular ejection fraction  $\geq 50\%$ . Patients with operable metastatic disease were excluded from the study, as were those with severe cardiac dysfunction, chronic diarrhea, or uncontrolled sites of infection. This study was approved by the local ethical and scientific committee, and all of the patients gave their written informed consent.

The pretreatment evaluation, performed within 2 weeks before study entry. During treatment, physical examination and blood test were mandatory before each course, and left ventricular ejection fraction was assessed every 3 month. Treatment response was evaluated every 4 3-weekly cycles or sooner if clinically indicated. Tumor response was assessed using the RECIST 1.1 criteria.<sup>[9]</sup>

Treatment consisted of intravenous (i.v.) docetaxel 70 mg/m<sup>2</sup> combined with 6-hour i.v. I-OHP 130 mg/m<sup>2</sup> on day 1, and c.i. 5FU 750 mg/m<sup>2</sup> days 1–5 (DOF regimen) plus trastuzumab intravenously as a 90-min infusion at doses of 8 mg/kg (loading dose in first cycle) and 6 mg/kg (maintenance doses) on day 1, every 3 weeks. This schedule was repeated until disease progression, development of unacceptable toxicity, or patient withdrawal of consent. After the completion of 8 cycles, the patients who achieved complete or partial response or stable disease continued the maintenance treatment with c.i. 5FU 750 mg/m<sup>2</sup> days 1–5 every 3 weeks and trastuzumab 6 mg/kg until progressive disease or unacceptable toxicity.

Toxicity was assessed using the common toxicity criteria of the National Cancer Institute (NCI), version 3.0. Treatment was

delayed if, on the planned day of treatment, the neutrophil count was  $<1,500/\text{mm}^3$ , the platelet count was  $<100,000/\text{mm}^3$ , or the patient had persistent diarrhea or stomatitis  $>$ grade 1. Any patient who required more than 2 weeks for recovery from adverse reactions was excluded from the study. In the event of grade 4 hematologic or any other severe ( $\geq$ grade 3) organ toxicity in individual patients, the doses of chemotherapy drugs were reduced by 25% for subsequent courses.

## 3. Statistical considerations

The primary end-point was 6-months disease-control rate (DCR). It was calculated that a total of 43 patients would have to be recruited. Progression free survival (PFS) was calculated as the time from the first chemotherapy infusion to disease progression or death. Secondary end points included: safety and overall survival (OS), measured from the date of start of treatment to the date of death. Kaplan–Meier method was used to determine PFS and OS. Statistical analyses were conducted by STATA IC 2012 software (StataCorp LLC, College Station, TX).

## 4. Results

From October 2011 to May 2017, a total of 15 patients were enrolled in the study. Baseline characteristics of the patients are presented in Table 1. The median age was 62 years (range, 45–74). All patients had a performance status of 0 or 1, and 66.7% had multiple metastatic sites.

Primary tumor was gastric in 12 patients and GEJ in 3 patients. Two patients had received prior chemotherapy.

All patients received at least 1 treatment cycle and were evaluable for response and toxicity. The median number of cycles was 9 (range, 1–28).

A documented complete response (CR) was observed in 2 (13.3%) patients and partial response (PR) in 7 patients (46.7%), with an overall response rate of 60% (95% CI, 32–84%). Four patients (26.7%) had stable disease (SD), and 2 (13.3%) progressive disease (PD) (Table 2).

**Table 2****Best response to treatment of enrolled patients.**

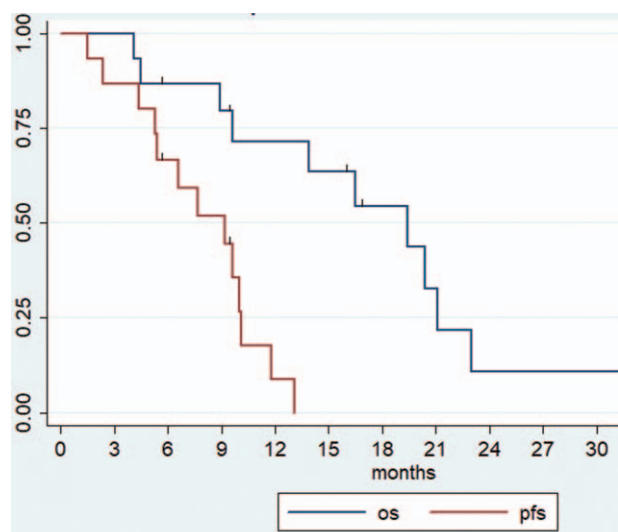
Patient	Best response to treatment by RECIST criteria	PFS, (mo)	OS, (mo)	Status
1	PR	9.6	20.4	Dead
2	SD	5.3	16.5	Dead
3	PR	11.8	23	Dead
4	CR	13.1	34.4	Dead
5	PR	10.1	21.1	Dead
6	PR	5.4	9.6	Dead
7	SD	10	19.4	Dead
8	PR	7.7	13.9	Dead
9	PD	1.5	4.5	Dead
10	CR	9.4	9.4	Alive without progression
11	SD	4.4	8.9	Dead
12	PR	5.6	5.6	Alive without progression
13	PD	2.4	4.1	Dead
14	PR	9.2	16.8	Alive
15	SD	6.6	15.9	Alive

CR = complete response, OS = overall survival, PFS = progression free survival, PR = partial response, SD = stable disease.

The median PFS of the patients was 9.2 months (95% CI, 4.4–10.1 months): 9 patients (60%) were progression-free after about 6 months from the onset of chemotherapy (Fig. 1). After the completion of 8 cycles of DOF, 8 patients started maintenance therapy. No patient was lost to follow-up. A total of 9 patients received a further treatment line at documentation of progressive disease (mainly ramucirumab-based therapy).

At a median follow-up time of 15.9 months, 11 patients were deceased: the median OS was 19.4 months (95% CI, 8.9–21.1 months) (Fig. 1).

Toxicity during DOF plus trastuzumab was acceptable and easily manageable with adequate supportive care (Table 1 supplementary data, <http://links.lww.com/MD/C247>). One patient interrupted DOF treatment after 3 cycles for toxicity-unrelated reasons. Three of 15 patients experienced at least 1 episode of grade 3 neutropenia without neutropenic fever.



**Figure 1.** Kaplan–Mayer curve of progression free survival and overall survival.

Among non-hematologic toxicities, grade 4 was not observed: grade 3 nausea/vomiting, diarrhea, and stomatitis was reported in 2, 1, and 1 patient, respectively. A total of 11 DOF cycles were delayed for at least 1 week because of toxicity, and dose reductions were required in 3 patients.

No patient had an infusion reaction to trastuzumab and no moderate to severe cardiotoxicity was observed, a cardiac event consisting of a grade 1 atrial fibrillation was reported in 1 patient.

## 5. Discussion

The ToGA study demonstrated that trastuzumab in combination with cisplatin plus capecitabine or fluorouracil was superior to cisplatin plus capecitabine or fluorouracil alone<sup>[8]</sup> in term of tumor response, PFS and OS in patients with HER2-positive advanced gastric cancer. Based on this data, trastuzumab was approved in combination with chemotherapy as first line of treatment in patients with metastatic HER2-overexpressing gastric or GEJ adenocarcinoma. From this landmark trial, other studies evaluated the efficacy of different chemotherapeutic agents in HER-2 positive gastric or EGJ cancer. In 2011, a small multicenter phase II trial evaluated the activity and safety of trastuzumab in combination with cisplatin in patients with advanced non-resectable HER2-positive gastric or GEJ adenocarcinoma.<sup>[10]</sup> Although with the limitation of a small sample size, cisplatin and trastuzumab achieved a response rate in 32% of patients with a disease control in 64%. Median time to progression was 5.1 months, while data on OS were not reported. Another Japanese phase II study evaluated the efficacy and safety of S-1 plus cisplatin plus trastuzumab in HER2-positive advanced gastric cancer.<sup>[11]</sup> The authors enrolled a total of 54 patients and the response rate was 68%, and the disease control rate was 94%. Median OS, PFS, and time to treatment failure were 16.0, 7.8, and 5.7 months, respectively. Finally, TRIO-013/LOGiC was a multicenter, double-blind, randomized phase III study that randomized capecitabine and L-HOP plus lapatinib 1.250 mg or placebo in patients with previously untreated HER2-amplified advanced gastroesophageal adenocarcinoma.<sup>[12]</sup> Unfortunately, the addition of lapatinib to chemotherapy failed to increase survival. Other studies that investigated trastuzumab in combination with chemotherapy in HER2-positive advanced gastric cancer are summarized in Table 3.<sup>[13–21]</sup>

Albeit with the limitations of a small sample size (only 15 patients from a preliminary analysis), the current study indicates the feasibility and efficacy of a first-line treatment with a DOF regimen plus trastuzumab with 9.2 months of median PFS and 19.4 months of median OS. These results compare well with the best ones reported in this disease for the HER2-positive gastric or GEJ cancer (Table 3). However, our results must be interpreted with caution because of we excluded patients with performance status >1 that were enrolled in the ToGA and LoGic trials (Table 2 supplementary data, <http://links.lww.com/MD/C247>). As known, these patients had a very poor outcome and survival. In addition, a preplanned exploratory analysis of the ToGA trial suggested that a strongest expression of HER2 (IHC 3+) is able to predict the survival of patients treated with trastuzumab with an improvement in OS of >5 months for patients with IHC 3+ compared with patients with IHC 2+ and fluorescent in situ hybridization (FISH) positive. In our study, we must report that only 2 patients had IHC 2+ and subsequent FISH positive as definition of HER2-positivity. However, the nature of our results of the current study (preliminary data from a small sample size) is a limitation which should be considered for a correct their

**Table 3****Main outcomes in patients with HER-2 positive gastric cancer treated with chemotherapy and trastuzumab.**

Study	Phase	Treatment	Number	Response rate (%)	PFS (mo)	OS (mo)	Reference
ToGA	III	CX/CF	131*	35	6.7	17.9*	8
Grávalos et al	II	C	22	32	5.1	NR	10
HERBIS-1	II	S+C	54	68	7.8	16.0	11
Yi et al	Retrospective	CX or CF	168	50.6	10.2	18.5	13
Namikawa et al	Retrospective	CX	15	46.7	NR	22.9	14
CGOG1001	II	CAPOX	51	66.6	9.2	19.5	15
Kataoka et al	II	CS-1	22	41.2	7.5	15.3	16
Chua et al	II	CS-1	30	59.3	7.4	14.6	17
Mitsui et al	II	DCS	16	93.8	NR	NR	18
Soularue et al	Retrospective	mFOLFOX6 or XELOX	34	41	9	17.3	19
Ryu et al	II	XELOX	55	67	9.8	21	20
Miura et al	II	SC	44	61	5.9	16.5	21
Current study preliminary data	II	DOF+T	15	60	9.2	19.4	–

C = cisplatin, CAPOX = capecitabine+oxaliplatin, D = docetaxel, DOF = docetaxel+oxaliplatin+5-FU, F = 5-FU, FISH = fluorescent in situ hybridization, HER2 = human epidermal receptor 2, mFOLFOX = modified oxaliplatin/5-FU/leucovorin, OS = overall survival, PFS = progression-free survival, S = S-1, T = trastuzumab, X = capecitabine, XELOX = oxaliplatin+capecitabine.

\* FISH positive/HER-2 3+ subgroup.

interpretation and thus, caution should be exercised before drawing firm conclusions.

In order to improve the efficacy of trastuzumab and chemotherapy in HER2 advanced metastatic gastric cancer, different approach or combinations have been tested. In 2016, Li et al<sup>[22]</sup> reported the results of a phase II study which aims to analyze the benefit and risk associated with continuing trastuzumab treatments after first line progression, in addition, a multicenter, single-arm, phase II study had combined bevacizumab and trastuzumab with docetaxel, oxaliplatin, and capecitabine as first-line treatment of advanced HER2-positive gastric cancer.<sup>[23]</sup> However, although a certain efficacy has been observed, these approaches should be validated in larger randomized phase III studies. Finally, Pertuzumab, a new humanized anti-HER2 antibody, almost tested in breast cancer in combination with trastuzumab, has shown to achieve partial response in the 86% of HER2-positive advanced gastric cancer when combined with capecitabine and cisplatin chemotherapy.<sup>[24]</sup> Based on these results, the JACOB phase III study (a study of pertuzumab in combination with trastuzumab and chemotherapy in patients with HER2-positive metastatic gastric cancer; NCT01774786) has been conducted and recently completed. The results of the JACOB study are awaited to define the role of pertuzumab in HER2-positive metastatic gastric cancer.

In summary, the conventional triple drug regimen DOF in combination with trastuzumab seems a feasible and encouraging option in HER2-positive advanced gastric or GEJ cancer. The final results of the phase II study are awaited to confirm these conclusions.

### Author contributions

**Conceptualization:** Giandomenico Roviello, Roberto Petrioli, Michele Aieta.

**Data curation:** Pietro Rosellini, Roberto Petrioli, Andrea Giovanni Multari.

**Formal analysis:** Giandomenico Roviello, Roberto Petrioli.

**Investigation:** Raffaele Conca.

**Methodology:** Raffaele Conca.

**Resources:** Pietro Rosellini.

**Validation:** Raffaele Conca.

**Writing – original draft:** Giandomenico Roviello, Roberto Petrioli, Michele Aieta.

**Writing – review & editing:** Valerio Nardone, Michele Aieta.

### References

- De Manzoni G, Marrelli D, Baiocchi GL, et al. The Italian Research Group for Gastric Cancer (GIRCG) guidelines for gastric cancer staging and treatment: 2015. *Gastric Cancer* 2017;20:20–30.
- Marano L, Polom K, Patrii A, et al. Surgical management of advanced gastric cancer: an evolving issue. *Eur J Surg Oncol* 2016;42:18–27.
- Marrelli D, Polom K, Pascale V, et al. Strong prognostic value of microsatellite instability in intestinal type non-cardia gastric cancer. *Ann Surg Oncol* 2016;23:943–50.
- Lordick F, Allum W, Carneiro F, et al. Unmet needs and challenges in gastric cancer: the way forward. *Cancer Treat Rev* 2014;40:692–700.
- Petrioli R, Roviello G, Zanotti L, et al. Epirubicin-based compared with docetaxel-based chemotherapy for advanced gastric carcinoma: a systematic review and meta-analysis. *Crit Rev Oncol Hematol* 2016; 102:82–8.
- Petrioli R, Francini E, Roviello F, et al. Sequential treatment with epirubicin, oxaliplatin and 5FU (EOF) followed by docetaxel, oxaliplatin and 5FU (DOF) in patients with advanced gastric or gastroesophageal cancer: a single-institution experience. *Cancer Chemother Pharmacol* 2015;75:941–7.
- Roviello G, Polom K, Petrioli R, et al. Monoclonal antibodies-based treatment in gastric cancer: current status and future perspectives. *Tumour Biol* 2016;37:127–40.
- Bang YJ, Van Cutsem E, Feyereislova A, et al. Trastuzumab in combination with chemotherapy versus chemotherapy alone for treatment of HER2-positive advanced gastric or gastro-oesophageal junction cancer (ToGA): a phase 3, open-label, randomised controlled trial. *Lancet* 2010;376:687–97.
- Eisenhauer EA, Therasse P, Bogaerts J, et al. New response evaluation criteria in solid tumours: revised RECIST guideline (version 1.1). *Eur J Cancer* 2009;45:228–47.
- Grávalos C, Gómez-Martín C, Rivera F, et al. Phase II study of trastuzumab and cisplatin as first-line therapy in patients with HER2-positive advanced gastric or gastroesophageal junction cancer. *Clin Transl Oncol* 2011;13:179–84.
- Kurokawa Y, Sugimoto N, Miwa H, et al. Phase II study of trastuzumab in combination with S-1 plus cisplatin in HER2-positive gastric cancer (HERBIS-1). *Br J Cancer* 2014;110:1163–8.
- Hecht JR, Bang Y-J, Qin SK, et al. Lapatinib in combination with capecitabine plus oxaliplatin in human epidermal growth factor receptor 2-positive advanced or metastatic gastric, esophageal, or gastroesophageal adenocarcinoma: TRIO-013/LOGiC - a randomized phase III trial. *J Clin Oncol* 2016;34:443–51.
- Yi JH, Kang JH, Hwang IG, et al. A retrospective analysis for patients with HER2-positive gastric cancer Who were treated with Trastuzumab-

- based Chemotherapy: in the perspectives of ethnicity and histology. *Cancer Res Treat* 2016;48:553–60.
- [14] Namikawa T, Munekage E, Munekage M, et al. Evaluation of a trastuzumab-containing treatment regimen for patients with unresectable advanced or recurrent gastric cancer. *Mol Clin Oncol* 2016;5:74–8.
- [15] Gong J, Liu T, Fan Q, et al. Optimal regimen of trastuzumab in combination with oxaliplatin/capecitabine in first-line treatment of HER2-positive advanced gastric cancer (CGOG1001): a multicenter, phase II trial. *BMC Cancer* 2016;16:68.
- [16] Kataoka H, Mori Y, Shimura T, et al. A phase II prospective study of the trastuzumab combined with 5-weekly S-1 and CDDP therapy for HER2-positive advanced gastric cancer. *Cancer Chemother Pharmacol* 2016;77:957–62.
- [17] Chua C, Tan IB, Yamada Y, et al. Phase II study of trastuzumab in combination with S-1 and cisplatin in the first-line treatment of human epidermal growth factor receptor HER2-positive advanced gastric cancer. *Cancer Chemother Pharmacol* 2015;76:397–408.
- [18] Mitsui Y, Sato Y, Miyamoto H, et al. Trastuzumab in combination with docetaxel/cisplatin/S-1 (DCS) for patients with HER2-positive metastatic gastric cancer: feasibility and preliminary efficacy. *Cancer Chemother Pharmacol* 2015;76:375–82.
- [19] Soularue É, Cohen R, Tournigand C, et al. Efficacy and safety of trastuzumab in combination with oxaliplatin and fluorouracil-based chemotherapy for patients with HER2-positive metastatic gastric and gastro-oesophageal junction adenocarcinoma patients: a retrospective study. *Bull Cancer* 2015;102:324–31.
- [20] Ryu MH, Yoo C, Kim JG, et al. Multicenter phase II study of trastuzumab in combination with capecitabine and oxaliplatin for advanced gastric cancer. *Eur J Cancer* 2015;51:482–8.
- [21] Miura Y, Sukawa Y, Hironaka S, et al. Five-weekly S-1 plus cisplatin therapy combined with trastuzumab therapy in HER2-positive gastric cancer: a phase II trial and biomarker study (WJOG7212G). *Gastric Cancer* 2018;21:84–95.
- [22] Li Q, Jiang H, Li H, et al. Efficacy of trastuzumab beyond progression in HER2 positive advanced gastric cancer: a multicenter prospective observational cohort study. *Oncotarget* 2016;7:50656–65.
- [23] Meulendijks D, Beerepoot LV, Boot H, et al. Trastuzumab and bevacizumab combined with docetaxel, oxaliplatin and capecitabine as first-line treatment of advanced HER2-positive gastric cancer: a multicenter phase II study. *Invest New Drugs* 2016;34:119–28.
- [24] Kang YK, Rha SY, Tassone P, et al. A phase IIa dose-finding and safety study of first-line pertuzumab in combination with trastuzumab, capecitabine and cisplatin in patients with HER2-positive advanced gastric cancer. *Br J Cancer* 2014;111:660–6.