

[ CASE REPORT ]

## Atrial Fibrillation-triggered Ventricular Fibrillation in a Patient with Early Repolarization Syndrome

Masaki Takahashi, Hidekazu Kondo, Keisuke Yonezu, Tetsuji Shinohara, Mikiko Nakagawa and Naohiko Takahashi

### Abstract:

A 54-year-old man with early repolarization syndrome (ERS) implanted with an implantable cardioverter-defibrillator (ICD) developed persistent atrial fibrillation (AF) three years after the implantation. Similarly, the remote monitoring system began frequently detecting ventricular fibrillation (VF) and polymorphic ventricular tachycardia (PVT). Longer RR intervals were repeatedly observed just before the initiation of PVT/VF. Catheter ablation for AF successfully diminished both the PVT and VF events.

**Key words:** idiopathic ventricular fibrillation, atrial fibrillation, catheter ablation, early repolarization syndrome

(Intern Med 61: 1973-1976, 2022)

(DOI: 10.2169/internalmedicine.8716-21)

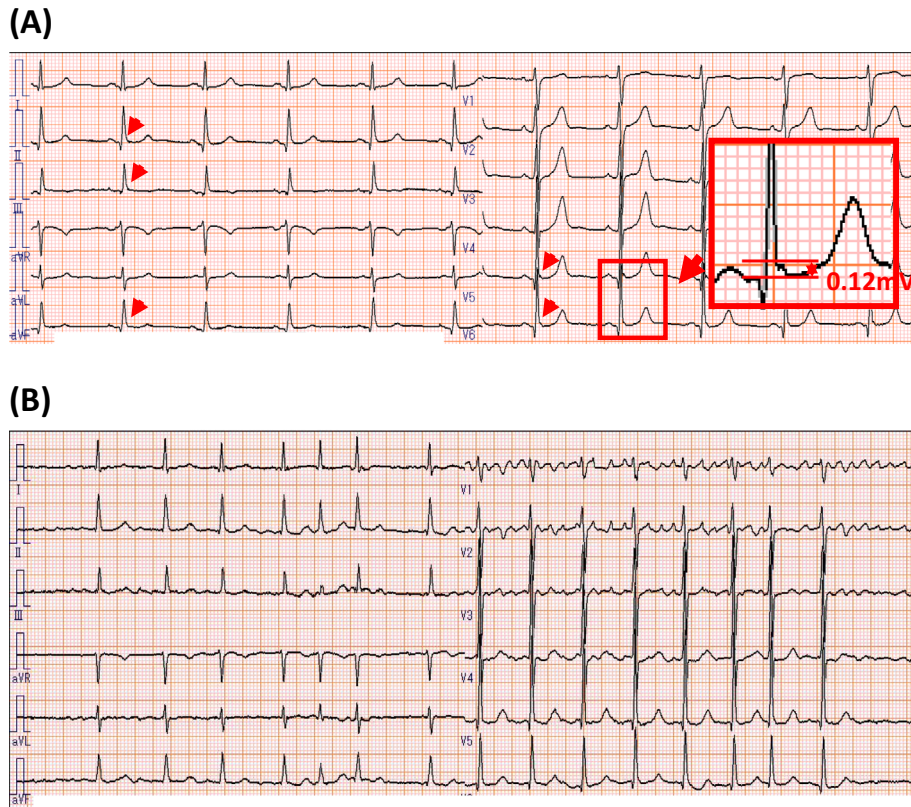
### Introduction

Early repolarization syndrome (ERS) is known to be a clinical syndrome causing ventricular fibrillation (VF) and sudden cardiac death in young and middle-aged adults. ERS is characterized with inferior/lateral early repolarization (ER) on electrocardiograms (ECG) and no obvious structural heart disease (1). Electrophysiologically, ERS are observed as notches or slurs in the terminal position of the QRS complex in either inferior or inferolateral leads. Controversy remains regarding the atrial fibrillation (AF) prevalence in patients with ERS or healthy subjects with an ER pattern ECG (2-6). Furthermore, the question as to whether AF enhances the VF in patients with ERS remains unclear. We herein report a patient with ERS who suffered from frequent implantable cardioverter defibrillator (ICD) appropriate shock due to VF, following new-onset of persistent AF. The restoration of sinus rhythm by catheter ablation for AF can therefore successfully eliminate ICD shocks due to VF.

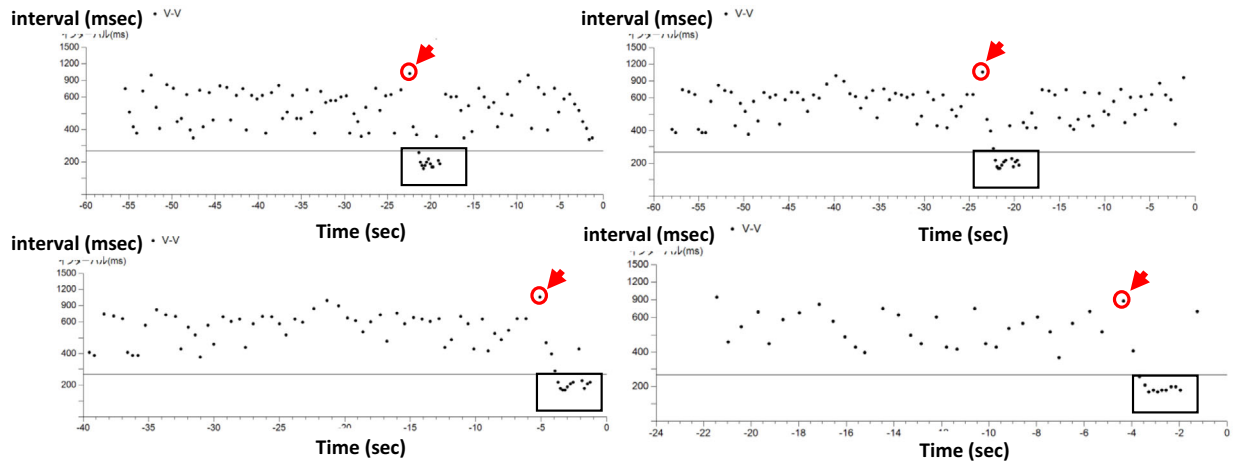
### Case Report

A 54-year-old man without a family history of sudden death or a history of syncope, who survived from cardiac ar-

rest due to VF, was admitted to our hospital. The patient was successfully converted to sinus rhythm by utilizing an automated external defibrillator. At admission, his ECG showed a sinus rhythm with an inferolateral ER pattern (Fig. 1A). His QT interval was within the normal range. The cardiac evaluation including cardiac catheterization, echocardiography, myocardial magnetic resonance imaging, and myocardial scintigraphy demonstrated no obvious structural heart disease. Genetic screening tests were negative. According to these findings, he was diagnosed to have ERS. He was implanted with a transvenous single-chamber ICD for secondary prevention purposes. After the implantation, no further ventricular tachyarrhythmic events were observed for three years. However, during the same observation period, short-lasting supraventricular tachyarrhythmic episodes which were suspected of indicating paroxysmal AF were documented through a remote monitoring system. Thereafter, supraventricular tachyarrhythmic episodes such as atrial tachycardia (AT) or AF were persistently recorded. Twelve-lead ECG documented AF (Fig. 1B) at an outpatient clinic. Therefore, we diagnosed the patient to have persistent AF. With this as a trigger, the remote monitoring system started to frequently detect ventricular tachyarrhythmic events presenting as non-sustained polymorphic ventricular tachycardia (PVT) (tachycardia cycle lengths of less than 180 ms). Inter-



**Figure 1.** (A) A twelve-lead electrocardiogram recorded during sinus rhythm. (B) A twelve-lead electrocardiogram recorded during atrial fibrillation.



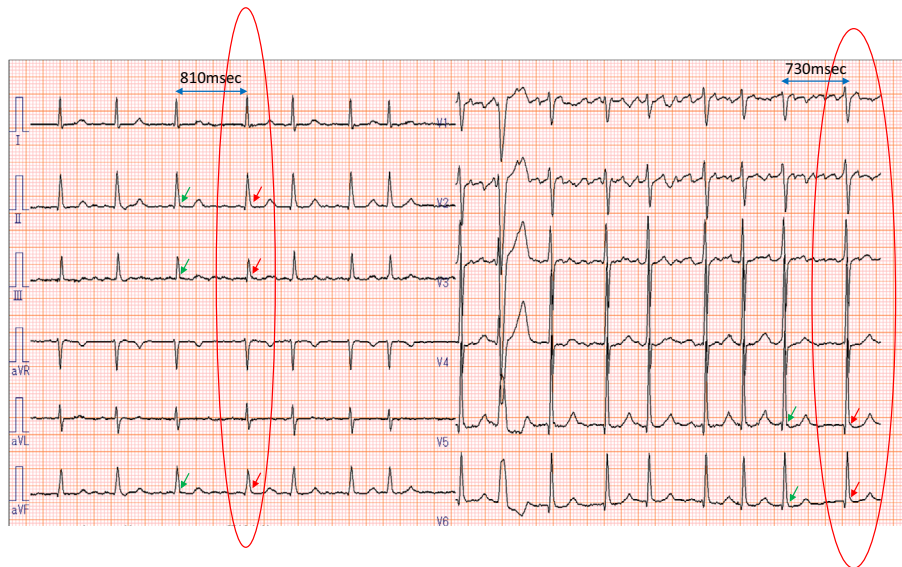
**Figure 2.** Reproducible R-R prolongation immediately before initiation of non-sustained polymorphic ventricular tachycardia.

estingly, the plots of RR intervals toward the onset of VF revealed that longer RR intervals reproducibly preceded the initiation of non-sustained PVT (Fig. 2). Twelve-lead ECG also showed that J waves were augmented when the RR intervals were prolonged (Fig. 3). Sixty days after the start of persistent AF, an appropriate ICD shock was delivered due to VF (Fig. 4). Appropriate ICD shocks were delivered to the patient two times due to VF for 1 month. We considered that RR irregularity due to AF is associated with an enhanced the vulnerability to PVT/VF. After obtaining in-

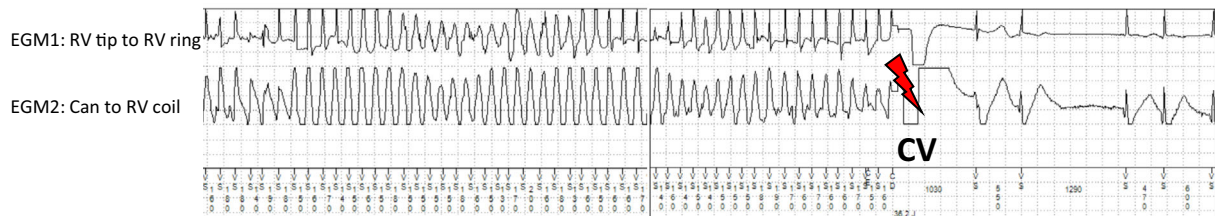
formed consent, we performed pulmonary vein antrum isolation by radiofrequency catheter ablation (RFCA). During the 12-month period after RFCA, the sinus rhythm has been maintained with no recurrence of AF. In addition, the ventricular tachyarrhythmic events completely disappeared.

## Discussion

To the best of our knowledge, the present case is the first one showing the unfavourable effects of AF which may



**Figure 3.** J wave augmentation just after the prolongation of the R-R intervals in the infero-lateral leads.



**Figure 4.** Appropriate shock (36J) to ventricular fibrillation recorded on an intra-cardiac electrocardiogram.

sometimes trigger VF in patients with ERS. As shown in Fig. 2, RR prolongations reproducibly preceded the initiation of non-sustained PVT. This phenomena appears to be consistent with the “short-long-short” pattern as an initiating mode of Torsade de Pointes in patients with congenital long QT syndrome (7). Nam et al. also demonstrated that VF episodes were more commonly initiated by premature ventricular contraction (PVC) with a short-long-short sequence in ERS patients (72.4%) vs. Brugada syndrome patients (15.1%) (8). Unfortunately, we could not obtain the ECG recordings corresponding the initiation of non-sustained PVT in Fig. 2. However, each RR interval immediately after the RR prolongation were remarkably shorter, thus suggesting this beat might indicate short-coupled PVC which initiates non-sustained PVT. Abrupt RR prolongation could increase the transient outward potassium current ( $I_{to}$ ) in the epicardial myocardium and thereby augment the J wave, thus leading to the intramural dispersion of effective refractory period and a susceptibility to develop VF (9, 10).

Although it has been established that the patients with Brugada syndrome are susceptible to AF, the association between AF and ER still remains controversial (2-6). A recent study suggested that ER was associated with lone AF (2). RFCA has also been reported to effectively maintain the si-

nus rhythm in Brugada syndrome patients with AF in several reports (11, 12), however, the efficacy of RFCA for AF to maintain the sinus rhythm in patients with ERS has not yet been investigated. Further study will therefore be needed to validate the efficacy of RFCA for AF in patients with ERS.

**The authors state that they have no Conflict of Interest (COI).**

## References

- Haïssaguerre M, Derval N, Sacher F, et al. Sudden cardiac arrest associated with early repolarization. *N Engl J Med* **358**: 2016-2023, 2008.
- Hasegawa Y, Watanabe H, Ikami Y, et al. Early repolarization and risk of lone atrial fibrillation. *J Cardiovasc Electrophysiol* **30**: 565-568, 2019.
- Matoshvili Z, Petriashvili S, Archvadze A, et al. Early repolarization as a risk factor of atrial fibrillation. *Georgian Med News* **229**: 59-61, 2014.
- Watanabe H, Nogami A, Ohkubo K, et al. Clinical characteristics and risk of arrhythmia recurrences in patients with idiopathic ventricular fibrillation associated with early repolarization. *Int J Cardiol* **159**: 238-240, 2012.
- McNair PW, Benenson DM, Ip JE, et al. Prevalence of early repolarization pattern in patients with lone atrial fibrillation. *J Electro-*

- cardiol **50**: 545-550, 2017.
6. Junttila MJ, Tikkanen JT, Kenttä T, et al. Early repolarization as a predictor of arrhythmic and nonarrhythmic cardiac events in middle-aged subjects. *Heart Rhythm* **11**: 1701-1706, 2014.
  7. Noda T, Shimizu W, Satomi K, et al. Classification and mechanism of Torsade de Pointes initiation in patients with congenital long QT syndrome. *Eur Heart J* **25**: 2149-2154, 2004.
  8. Nam GB, Ko KH, Kim J, et al. Mode of onset of ventricular fibrillation in patients with early repolarization pattern vs. Brugada syndrome. *Eur Heart J* **31**: 330-339, 2010.
  9. Aizawa Y, Sato M, Kitazawa H, et al. Tachycardia-dependent augmentation of “notched J wave” in a general patient population without ventricular fibrillation or cardiac arrest: not a repolarization but a depolarization abnormality? *Heart Rhythm* **12**: 376-383, 2015.
  10. Aizawa Y, Takatsuki S, Nishiyama T, et al. Tachycardia-induced J-wave changes in patients with and without idiopathic ventricular fibrillation. *Circ Arrhythm Electrophysiol* **10**: e005214, 2017.
  11. Kitamura T, Fukamizu S, Kawamura I, et al. Long-term efficacy of catheter ablation for paroxysmal atrial fibrillation in patients with Brugada syndrome and an implantable cardioverter-defibrillator to prevent inappropriate shock therapy. *Heart Rhythm* **13**: 1455-1459, 2016.
  12. Rodríguez-Mañero M, Kreidieh B, Valderrábano M, et al. Ablation of atrial fibrillation in patients with Brugada syndrome: a systematic review of the literature. *J Arrhythm* **35**: 18-24, 2018.

The Internal Medicine is an Open Access journal distributed under the Creative Commons Attribution-NonCommercial-NoDerivatives 4.0 International License. To view the details of this license, please visit (<https://creativecommons.org/licenses/by-nc-nd/4.0/>).

---

© 2022 The Japanese Society of Internal Medicine  
*Intern Med* 61: 1973-1976, 2022