

Clinical and Dermoscopic Features of Follicular Becker's Nevus: A Rare Variant

Sir,

Becker's nevus is a cutaneous hamartoma, typified by the presence of macular pigmentation, hypertrichosis, and smooth muscle proliferation. Herein, we report a rare follicular variant of Becker's nevus.

An 18-year-old man presented with asymptomatic lesions over the right chest and supraclavicular area for a year and a half, gradually progressive in nature. There were no lesions elsewhere. There was no history of seizures, developmental delay, or any neurological complaints.

On examination, there was unilateral involvement of the right upper chest and supraclavicular area in the form of numerous, well-defined, folliculocentric macules tending to coalesce at one side [Figure 1a and b]. There was no evidence of scaling, and scratch sign was negative. There was presence of terminal hair in the patch located at the centre of each hyperpigmented macule. There was no evidence of thickening or nodularity over the lesion. There was no limb or breast hypoplasia or asymmetry.

Dermoscopy (DermLite DL200 Hybrid M; polarized mode) showed a well-defined network-like pigmentation. There was immediate perifollicular hypopigmentation, visible dermoscopically. Surrounding this, there were well-defined areas of darker pigment network. These corresponded clinically to the folliculocentric macules [Figures 2 and 3].

Histopathology demonstrated hyperpigmentation of the basal layer with regular elongation of rete ridges. There was acanthosis present. This hyperpigmentation corresponds clinically to the hyperpigmented macules. There was no evidence of dermal smooth muscle

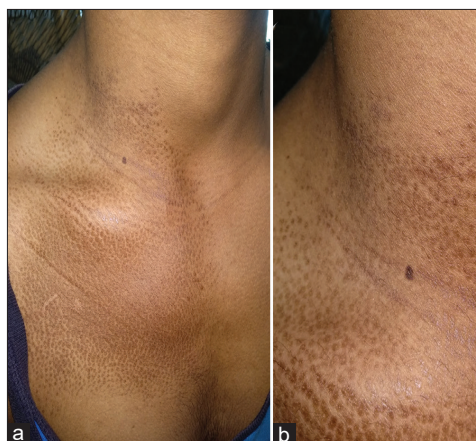

Figure 1: (a and b) Numerous, hyperpigmented, folliculocentric macules seen over the right side of the chest, extending onto the neck as well as the shoulder. They tend to be coalescing towards the center

proliferation. Thus, a final diagnosis of follicular Becker's nevus was made. The patient was counselled about the nature and course of the condition and advised treatment with Q-switched NDYAG laser. However, because of the lack of facilities in the government institute where he presented and him not being able to afford private treatment, the patient did not opt for this.

Becker's nevus is a cutaneous hamartoma, presenting as a unilateral patch of hyperpigmentation, with hypertrichosis and smooth muscle proliferation. The exact etiology of Becker's nevus is unknown. Beta-actin (ACTB) mutations amplify Hedgehog signaling leading to interference with the development of hair follicles and arrector pili muscles. This explains lesions being perifollicular, to begin with.^[1]

Androgens play a role in this condition as seen by peri-pubertal development, hypertrichosis, acneiform lesions in the involved area, and hypertrichosis, with an increase in androgen receptors in the involved skin noted.^[2]

**Harshal Ranglani,
Subrata Malakar¹**

*Consultant Dermatologist, Cure and Care Polyclinic, Thane,
¹Consultant Dermatologist,
Rita Skin Foundation, Kolkata,
Maharashtra, India*

Address for correspondence:

*Dr. Harshal Ranglani,
Cure and Care Polyclinic,
Vartak Nagar, Thane,
Maharashtra, India.
E-mail: harshalranglani@gmail.
com*

Access this article online

Website: www.idoj.in

DOI: 10.4103/idoj.IDOJ_877_20

Quick Response Code:



How to cite this article: Ranglani H, Malakar S. Clinical and dermoscopic features of follicular Becker's nevus: A rare variant. *Indian Dermatol Online J* 2021;12:750-1.

Received: 11-Dec-2020. **Revised:** 09-Feb-2021.

Accepted: 19-Mar-2021. **Published:** 21-Aug-2021.

This is an open access journal, and articles are distributed under the terms of the Creative Commons Attribution-NonCommercial-ShareAlike 4.0 License, which allows others to remix, tweak, and build upon the work non-commercially, as long as appropriate credit is given and the new creations are licensed under the identical terms.

For reprints contact: WKHLRPMedknow_reprints@wolterskluwer.com

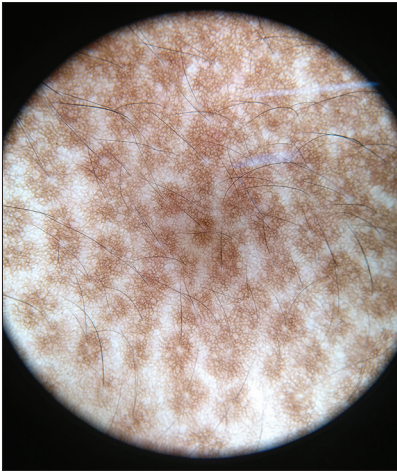


Figure 2: Dermoscopy (Dermlite DL200 Hybrid M; polarized mode) showed islands of well-defined network-like pigmentation. Interspersed between these islands were areas of normal skin with a normal skin pigment network

Several morphological variants of Becker's nevus reported include the presence of only pigmentation (Becker's melanosis), giant Becker's nevus, blaschkoid Becker's nevus, bilateral involvement, and presence of multiple lesions. Becker's nevus syndrome is an association of Becker's nevus with unilateral breast hypoplasia and muscle, skin, and/or skeletal abnormalities.^[3]

There is a case series on follicular Becker's nevus by Y Manchanda *et al.*,^[4] describing predominantly follicular involvement. It is suggested that the presence of folliculocentric macules at the periphery of evolved lesions, and the center of early lesions points to an etiopathological role of the follicular epithelium. In contrast to the dermoscopy of classical Becker's nevus in which a continuous sheet of pigmentation is seen, islands of pigmentation are seen in the case of follicular Becker's nevus. On dermoscopy of classical Becker's, the well-defined pigment network is present in a continuous sheet, with uniform thickness and color of lines throughout the lesion. In follicular Becker's, the pigmentation is patchy – occurring in circles around each follicle. Interspersed between these circles are areas of normal pigment network i.e., normal skin.

It can often pose a diagnostic conundrum, being misdiagnosed as pityriasis versicolor. It is important to note that early and evolving lesions of Becker's nevus can present with only predominantly follicular lesions. The lack of scaling and unilateral location along with the dermoscopic findings can help differentiate the two.

A variety of lasers have been used alone or in combination to treat the hyperpigmentation and hypertrichosis of




Figure 3: Dermoscopy (Dermlite DL200 Hybrid M; polarized mode) showing immediate perifollicular hypopigmentation, surrounding which there is a hyperpigmented area around each individual follicle. This corresponds clinically to hyperpigmented macules, thus, representing the follicular variant

Becker's nevus, with wavelengths ranging from 504 to 10,600 nm.^[5]

Declaration of patient consent

The authors certify that they have obtained all appropriate patient consent forms. In the form the patient(s) has/have given his/her/their consent for his/her/their images and other clinical information to be reported in the journal. The patients understand that their names and initials will not be published and due efforts will be made to conceal their identity, but anonymity cannot be guaranteed.

Financial support and sponsorship

Nil.

Conflicts of interest

There are no conflicts of interest.

References

1. Happle R. Becker's nevus and lethal beta-actin mutations. *J Invest Dermatol* 2017;137:1619-21.
2. Sheng P, Cheng YL, Cai CC, Wu YY, Shi G, Zhou Y, *et al.* Overexpression of androgen, oestrogen and progesterone receptors in skin lesions of Becker's naevus. *Acta Derm Venereol* 2018;98:867-72.
3. Dasegowda SB, Basavaraj G, Nischal K, Swaroop M, Umashankar N, Swamy SS. Becker's nevus syndrome. *Indian J Dermatol* 2014;59:421.
4. Manchanda Y, Khaitan BK, Ramam M, Das S, Al-Mutairi N. Follicular Becker's nevus: A new clinical variant. *Indian J Dermatol* 2020;65:130-2.
5. Zhong Y, Yang B, Huang L, Elias PM, Man MQ. Lasers for Becker's nevus. *Lasers Med Sci* 2019;34:1071-9.