

A Simple, 10-minute Procedure for Transforaminal Injection under Ultrasonic Guidance to Effect Cervical Selective Nerve Root Block

Mikinobu TAKEUCHI,^{1,2} Mitsuhiro KAMIYA,^{1,3} Norimitsu WAKAO,^{1,3} Koji OSUKA,² Muneyoshi YASUDA,² Toshiaki TERASAWA,⁴ Takahisa YAMADA,² and Masakazu TAKAYASU^{1,2}

Departments of ¹Spine Center, ²Neurological Surgery, and ³Orthopedic Surgery, Aichi Medical University Hospital, Nagakute, Aichi;

⁴Department of General Surgery, Shirayama Surgical Clinic, Kasugai, Aichi

Abstract

The aim is to provide a detailed procedure of a simple and 10-minute cervical nerve root block (CNRB) under ultrasonic guidance, and to report the clinical outcomes, disorders, and complications. Records of patients who had undergone CNRB, were reviewed under ultrasonic guidance at the hospital from 2010 through 2012. The procedure is described in detail. Arm and shoulder pain was evaluated by use of the visual analogue scale (VAS). Forty-three patients agreed to undergo CNRB under ultrasonic guidance. Nerve roots from C5 to C8 were affected in 41, and these nerve roots were readily distinguished. Two of the 43 participants did not receive injections because impediments in visualizing the affected nerve root. Of the 41 who received injections, radicular pain immediately disappeared in 39, who continued to feel pain relief 1 month later. However, pain recurred in 15 patients (38%), of whom 11 underwent cervical spine surgery. The rest of 24 patients felt sustained pain relief longer than 3 months after the injection, significantly. Although one patient had recurrent radicular pain 10 months later, the pain could be controlled by medication. At the final follow-up periods, 17.2 (10–24 months), the median VAS score of the patients, 23 (0 to 71 mm), was significantly improvement ($P = 0.001$) in comparison to before injection 88 (range; 56–100). No complications occurred. The cervical nerve root block under ultrasonic guidance simply, safely, and efficaciously decreased radicular pain for 17.2 months in 62% patients with intolerable radicular pain.

Key words: selective cervical nerve root block, transforaminal injection, ultrasonic guidance, clinical outcome

Introduction

The North American Spine Society (NASS) Evidence-Based Clinical Guideline on the Diagnosis and Treatment of Cervical Radiculopathy from Degenerative Disorders¹⁾ indicated that transforaminal epidural steroid injections to effect cervical selective nerve root block may be considered when patients suffering from painful cervical radiculopathy resulting from degenerative disorders have not benefited from conservative therapy. Rathmell et al.²⁾ described this procedure under the real-time fluoroscopic guidance in 2004, and Cyteval et al.³⁾ described the procedure under computed tomographic guidance.

More recently, Lin et al.⁴⁾ reported that 11 (60%) of 19 patients experienced pain relief sustained 16 weeks after transforaminal epidural steroid injections under fluoroscopic guidance, and Kim et al.⁵⁾ reported that mean pain relief in 19 patients was sustained through 16 weeks of follow-up after injection under multislice computed tomography (CT) under fluoroscopic guidance.

Narouze et al.⁶⁾ fluoroscopically confirmed that needles injected under ultrasonic guidance were properly targeted in 8 of 10 patients, whereas the other 2 patients had critical vessels in the posterior aspect of the foramen. In both these cases, the vessels existed in the pathway of a needle correctly positioned under ultrasonic guidance. They concluded that transforaminal epidural steroid injection under ultrasonic guidance is feasible. Yamauchi et al.⁷⁾

reported that radicular pain score in 12 patients significantly decreased from 65 (range, 46 to 80) before injection to 25 (range, 3 to 31) at 24 hours and 40 (range, 28 to 66) at 30 days after injection under ultrasound guidance. Moreover some authors considered various advantages of ultrasonic guidance compared with fluoroscopic guidance, such as better targeting of the nerve root, avoiding abnormally situated blood vessels, and absence of radiation exposure.⁶⁻⁸⁾ However, there has been no report on clinical outcome more than one year.

Here we provide detail about the procedure under ultrasonic guidance accompanied by a narrated video, and report on clinical outcomes, their disorders and complications, due to transforaminal epidural injections, after one year.

Materials and Methods

Patients who had undergone transforaminal injection under ultrasonic guidance to effect cervical selective nerve root block at Aichi Medical University Hospital from 2010 through 2012 were retrospectively analyzed. The injection was considered when the patient had shown no improvement after 2 months of conservative therapy. If the effect of the injection was not sufficiently sustained for longer than 2 weeks, then the injection was repeated once or twice. Patients with cervical myelopathy or any cancer, including a benign intradural tumor, motor palsy without sensory disturbance were excluded as candidates for the injection.

Records were reviewed for patient sex, age, and duration of presenting symptoms. The cervical level responsible for pain was determined from reviewing magnetic resonance imaging (MRI) and CT scans for evidence of disc herniations or osteophytes compressing a cervical nerve root. Arm and shoulder pain before the first injection and 1 month after the final injection was evaluated by use of the visual analogue scale (VAS),⁹⁾ in which the patient indicated the extent of pain on a 100-mm long horizontal labeled "no pain" (0 mm) at one end and "very severe pain" (100 mm) at the other end.

Results are expressed as the mean (SD). The Friedman test was used for the evaluation of VAS before and after the root block on the table presenting results. Statistical data were processed using SPSS software (version 16; SPSS, Chicago, Illinois, USA). P value was set at < 0.05.

I. Study approval, informed consent, and funding

The study was approved by the institutional review board of the Aichi Medical University Hospital, and study subjects provided informed consent. This study

did not receive any benefits from a commercial entity related directly or indirectly to the subject of this manuscript. The authors do not have any conflicts of interest related to the materials or methods used or the findings of this study.

II. Procedure

This outpatient procedure was done without specific patient preparations. Patients, who were not sedated, were placed lying down on the opposite side as the radicular pain occurred onto an examining table (Fig. 1A). The head and neck were set on a folded towel and bent slightly to the side opposite to the side of the radicular pain to facilitate visualizing the targeted foramen.

Standing behind the patient, the surgeon (M.K.) set an alcohol-wiped S- HFL38/13-6 MHz linear probe (for carotid artery, Fig. 1B) attached to an S-nerve ultrasound machine (SonoSite, Inc., Tokyo), with the setting in normal mode, perpendicularly to the neck (Fig. 1A). The surgeon determined the location of and the trajectory to the nerve root in two steps. In the first step, the surgeon obtained an axial ultrasound image of common or internal

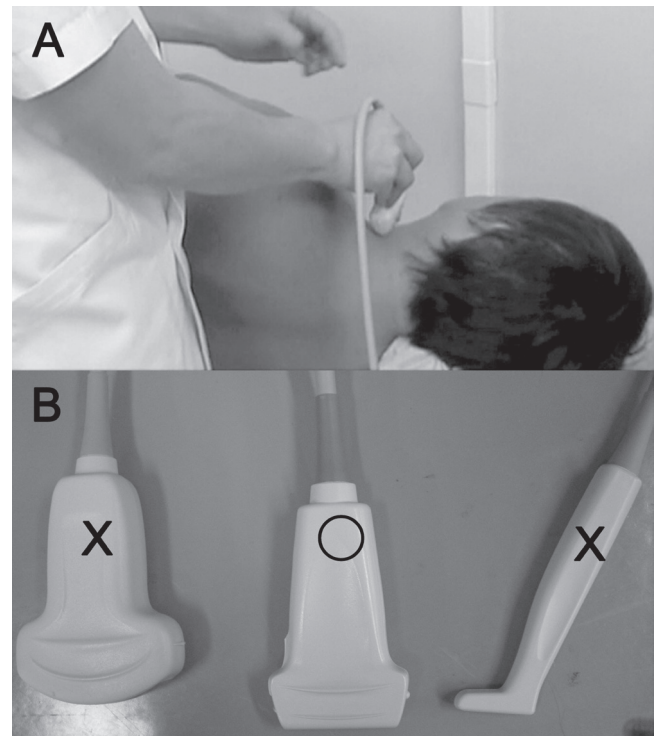


Fig. 1 A: Position of the surgeon and the patient during selective nerve root block under the ultrasound. The probe was set perpendicularly to the neck. B: X denotes not to use the probes for the abdominal ultrasound or echocardiography and O denotes that probe for the carotid artery (*center*) was used.

carotid artery on the same side (left or right) where the injection was to be administered. In the second step, by moving the probe posteriorly, the surgeon identified the C5 to C7 nerve roots in an axial image by the shapes of the transverse processes. The C5 and C6 transverse processes have obvious anterior and posterior tubercles (Fig. 2A, B), whereas the C7 transverse process has a rudimentary anterior tubercle and a prominent posterior tubercle^{6,10} (Fig. 2C, D). Thus, the C7 vertebral level is a key landmark,¹¹ which the surgeon located by moving the probe slightly caudally.

The vertebral artery at C7 vertebral level is also a landmark, where the C7 nerve root appears in between the vertebral artery and the posterior tubercle (Fig. 2C). The surgeon changed the ultrasound setting to power Doppler mode to visualize blood flowing through the vertebral artery at the C7 vertebral level. Then the ultrasound setting was returned to normal mode because power Doppler mode worsens image resolution, and the probe was moved to the cranial side to locate and inject the C5 or C6 nerve root, or to the caudal side to locate and inject the C8 nerve root. Then, with ultrasound again set in power Doppler mode, the surgeon determined if a blood vessel was abnormally situated around the targeted nerve root so as to avoid an intravascular injection. If a blood vessel was abnormally situated,

the surgeon discontinued the procedure instead of continuing to insert the needle.

The skin was wiped with an alcohol antiseptic, and under ultrasonic guidance with the ultrasound setting in normal mode, the surgeon gently inserted a 70-mm 22-gauge needle (TERUMO, Co., Tokyo) toward the nerve root located at the inside of the posterior tubercle. When the tip of the needle slightly struck the targeted nerve root with the needle angle between 30 degrees and 45 degrees, the surgeon verified that the patient felt radiating pain at the affected area (Fig. 2E). After confirming that blood or cerebrospinal fluid had not aspirate into the syringe, the surgeon slowly injected 2 mL of a mixture of 1.5 mL of 1% lidocaine and 0.5 mL (2 mg) of injectable betamethasone sodium phosphate. Finally, the needle was removed and light pressure was applied to the injection site for 2 minutes. (See the video: <http://youtu.be/KdQvDfq23C8>)

The entire procedure took about 10 minutes. The patient remained on bed, under rest, for 30 minutes.

Results

Review of records revealed that 43 patients agreed to undergo transforaminal steroid injections under ultrasonic guidance at Aichi Medical University Hospital from 2010 through 2012 (Table 1). Of

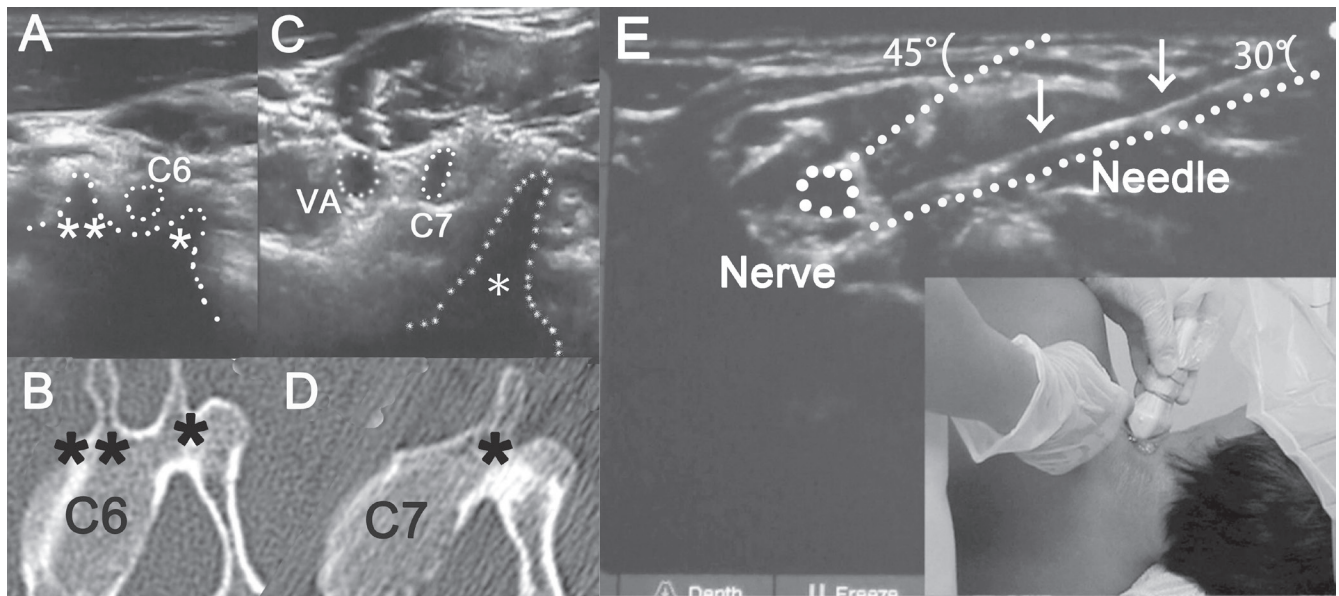


Fig. 2 A: Axial ultrasound image showing the C6 nerve root (C6) in between the posterior and anterior tubercles. B: Computed tomographic scan at level C6 showing between the posterior (*) and anterior tubercles (**) from the same angle as ultrasound imaging in A. C: Axial ultrasound image showing the C7 nerve root in between the vertebral artery (VA) and the posterior tubercle (*). D: Computed tomographic scan at C7 level showing the posterior (*) tubercle from the same angle to ultrasound imaging in C. E: Axial ultrasound image showing the 22-G needle was inserted toward the C6 nerve root. Two dotted lines indicating the needle angle between 30 degree and 45 degree.

Table 1 Patient demographics (n = 43), injection for cervical nerve root, and the success rate of injection

Characteristic	Number
Age y (median; range)	49 (39–62)
Sex (M/F)	24/19
Duration of symptoms, months (range)	3–26
Post-injection follow-up period, months (range)	17.2 (10–24)
Injection for cervical nerve root	Fail/Success (n) Success rate
C5	0/3 100%
C6	0/19 100%
C7	1 [¶] /18 94.4%
C8	1 [§] /3 66.7%
Total	2/43 95.3%

[¶]Patient had undergone anterior cervical discectomy and fusion with a titanium cage few years previously. The inability to visualize the C7 nerve root by ultrasound was an artifact of the presence of the titanium cage or surgical scar. [§]An injection at the C8 nerve root was not done because the patient was fat with a short neck, and the C8 nerve root was adjacent to the subclavian artery. F: female, M: male.

these, 41 received 76 injections. Nineteen participants received a second injection when pain relief was not sustained beyond 2 weeks, and 8 patients received a third injection. Two patients did not receive any injection.

Of the 41 who received injections, radicular pain immediately disappeared in 39. Before the injection, the median VAS score for these 39 patients was 88 (56 to 100) mm. One month after the injection, all 39 continued to feel pain relief, when the median VAS score was 28 (10 to 78) mm (P = 0.001 compared to before injection).

After 1 month, VAS scores were obtained in 39 patients, pain recurred in 15, of whom 11 underwent cervical spine surgery. The other four declined to undergo surgery, electing instead to take medication for pain. At 3 months the median VAS score of the 24 patients (62%), 36 (0–83 mm), was statistically significant (P = 0.001) from the score before injection. They felt sustained pain relief longer than 3 months after the injection. Although one patient had recurrent radicular pain 10 months later, some administrations satisfied him. At the final follow-up periods, 17.2 (10–24 months), the median VAS score of the patients, 23 (0–71 mm), was significantly improved (P = 0.001) in comparison to before injection (Table 2).

In the 11 patients who underwent cervical spine surgery, at final follow-up, the median VAS score 13 (0 to 27 mm) was significantly improved (P =

Table 2 VAS scores before and after injection

VAS			
Before injection	After 1 month	After 3 months	Final period
88	28*	36*	23*
(56–100)	(10–78)	(0–83)	(0–71)

*: VAS score significantly decreased in comparison to before injection (P = 0.001, Friedman test). VAS: visual analogue scale.

0.001) compared to the initial VAS score.

When two patients did not experience immediate pain relief after injection for C7 nerve root, we suspected that pain was not caused by cervical radiculopathy. They were diagnosed as cerebrospinal fluid hypovolemia in one patient and thoracic outlet syndrome in the other patient in other departments.

A needle smaller than 22 gauge was too narrow for detecting the needle’s direction and angle. Technical complications such as vertebral perforation, vessel injury, cerebrospinal fluid leak, or spinal cord injury did not occur.

Discussion

We found that transforaminal injection under ultrasonic guidance to effect cervical selective nerve root block statistically significantly and safely decreased radicular pain for 17 month after injection. Although the pain recurrence was observed in 15 patients (38%) between 1 month and 3 months and 11 patients underwent the cervical surgery, 24 (62%) of the 39 patients felt sustained pain relief longer than 17 months. Consequently, patients obtained sufficient pain relief within 10 minutes after injection, an important consideration for patients in severe pain who might have to wait few weeks for surgery. We conclude that transforaminal injection under ultrasonic guidance is worthwhile for patients who have not had effective drug treatment or physical therapy.

Although Ma et al.¹²⁾ reported minor complications in 14 (2%) and no catastrophic complications in 844 patients who received 1,036 fluoroscopically guided transforaminal epidural steroid injections. Furman et al.¹³⁾ reported vertebral artery injury, and Baker et al.¹⁴⁾ reported spinal cord injury upon cervical transforaminal epidural steroid injections. In contrast, transforaminal epidural steroid injections for selective cervical nerve block under ultrasonic guidance facilitated identifying critical vessels at unexpected locations relative to the intervertebral foramen and vertebral artery.⁶⁾ Similarly, Jee et al.⁸⁾

stated that ultrasonic guidance may facilitate identifying critical vessels at unexpected locations relative to the intervertebral foramen and avoiding injury to such vessels. Our study did not find any complications. Therefore, transforaminal epidural injections under ultrasonic guidance are safer than injections under fluoroscopic guidance. We confirm three important permissions to avoid some severe complications. First, the linear probe for the carotid artery should be used. Second, we must identify the specific C7 level. If you were able to find it, you would have better abandon the cervical nerve root block under the ultrasound. Third, the 70-mm 22 G needle should be used.

Use of ultrasonic guidance can avoid radiation exposure under fluoroscopic guidance to the patient, especially if injections are repeated, and to the surgeon. We are unaware of a report detailing radiation exposure during transforaminal epidural steroid injections under fluoroscopic guidance to effect cervical nerve root block. However, Kumar and Gowda¹⁵⁾ reported a mean duration of 28 seconds of radiation exposure for cervical foraminal selective nerve block under fluoroscopic guidance, and Kim et al.¹⁶⁾ computed an effective radiation dose for an average lumbar epidural steroid injection of 0.93 mSv during fluoroscopic exposure of 41 seconds. Therefore, given an average duration of fluoroscopic exposure of 28 seconds, we guessed that the effective radiation dose was about 0.64 mSv for a typical transforaminal cervical injection under fluoroscopic guidance.

Done under CT guidance, transforaminal cervical injections incur less radioactive exposure than when done under fluoroscopic guidance. Shepherd et al.¹⁷⁾ reported an estimated mean radiation exposure during CT-guided cervical spine injections of 1.1 mSv, with minimum effective dose of only 0.17 mSv. Miller et al.¹⁸⁾ reported a mean radiation exposure of 0.51 mSv. Even though radiation exposure under CT guidance is less than that under fluoroscopic guidance, radiation exposure still occurs. The radiation-sensitive thyroid gland is nearby the C6 or 7 nerve roots, and the effective dose for a neck CT presented is 3 mSv.¹⁹⁾ Thus, if the transforaminal cervical injections under CT guidance were done 6 times in the same patient, the effective radiation will reach 3 mSv, the same as a neck CT.

We could not complete injection under ultrasonic guidance in two of the 26 patients because the nerve root could not be detected. One of these two patients had a titanium cage inserted from previous surgery, which interfered with visualizing the C7 nerve root under ultrasonic guidance. The other patient was fat with a short neck, and the C8 nerve root was

adjacent to the subclavian artery. Martinoli et al.¹⁰⁾ were able to visualize nerve roots from C4 to C7 under ultrasonic guidance in all 20 healthy subjects they examined. However, they could visualize the C8 nerve root in only 16. They also reported that the C8 nerve root, which is at the cervicothoracic junction, is too caudad and deep, especially in subjects with thick, short necks, and therefore it was difficult to find. Nakagawa et al.¹¹⁾ discussed the possibility that it might be difficult to identify the C8 nerve root because of the deep depth of its location. Thus, injections under ultrasonic guidance might not be successfully completed in fat patients with short neck.

Although transforaminal cervical epidural steroid injections under ultrasonic guidance benefited patients who had suffered from severe radicular pain unresponsive to conservative treatment, the use of ultrasound is not popular among spine surgeons or neurosurgeons. Accordingly, we included a detailed procedure. We are unaware of any other presentations of the transforaminal cervical epidural injections under ultrasonic guidance with clinical outcome in more than 1 year. Finally, we persistently considered that the indication of this procedure was a part of conservative therapies to avoid the cervical spine surgery for the cervical radiculopathy.

In conclusions, if use of this simple, safe, and efficacious procedure becomes widespread, patients with intolerable radicular pain would benefit. Furthermore, injecting these injections under ultrasonic guidance would allay concerns about targeting the responsible level causing the radicular pain, such as distinguishing between the C6 and C7 levels. Therefore, we believe that it is essential for surgeons and other physicians to learn well about this procedure before suggesting to patients.

Acknowledgments

The authors contracted Michael S. Altus, PhD, ELS, of Intensive Care Communications, Inc., Baltimore, MD, USA, to edit their initial manuscript. They thank Dr. Altus for his excellent services. The authors maintained complete control over the direction and content of the manuscript.

Conflicts of Interest Disclosure

This study did not receive any benefits from a commercial entity related directly or indirectly to the subject of this manuscript. The authors do not have any conflicts of interest related to the materials or methods used or the findings of this study.

References

- 1) Bono CM, Ghiselli G, Gilbert TJ, Kreiner DS, Reitman C, Summers JT, Baisden JL, Easa J, Fernand R, Lamer T, Matz PG, Mazanec DJ, Resnick DK, Shaffer WO, Sharma AK, Timmons RB, Toton JF; North American Spine Society: An evidence-based clinical guideline for the diagnosis and treatment of cervical radiculopathy from degenerative disorders. *Spine J* 11: 64–72, 2011
- 2) Rathmell JP, Aprill C, Bogduk N: Cervical transforaminal injection of steroids. *Anesthesiology* 100: 1595–1600, 2004
- 3) Cyteval C, Thomas E, Decoux E, Sarrabere MP, Cottin A, Blotman F, Taourel P: Cervical radiculopathy: open study on percutaneous periradicular foraminal steroid infiltration performed under CT control in 30 patients. *AJNR Am J Neuroradiol* 25: 441–445, 2004
- 4) Lin EL, Lieu V, Halevi L, Shamie AN, Wang JC: Cervical epidural steroid injections for symptomatic disc herniations. *J Spinal Disord Tech* 19: 183–186, 2006
- 5) Kim H, Lee SH, Kim MH: Multislice CT fluoroscopy-assisted cervical transforaminal injection of steroids: technical note. *J Spinal Disord Tech* 20: 456–461, 2007
- 6) Narouze SN, Vydyanathan A, Kapural L, Sessler DI, Mekhail N: Ultrasound-guided cervical selective nerve root block: a fluoroscopy-controlled feasibility study. *Reg Anesth Pain Med* 34: 343–348, 2009
- 7) Yamauchi M, Suzuki D, Niiya T, Honma H, Tachibana N, Watanabe A, Fujimiya M, Yamakage M: Ultrasound-guided cervical nerve root block: spread of solution and clinical effect. *Pain Med* 12: 1190–1195, 2011
- 8) Jee H, Lee JH, Kim J, Park KD, Lee WY, Park Y: Ultrasound-guided selective nerve root block versus fluoroscopy-guided transforaminal block for the treatment of radicular pain in the lower cervical spine: a randomized, blinded, controlled study. *Skeletal Radiol* 42: 69–78, 2013
- 9) Huskisson EC: Measurement of pain. *Lancet* 2: 1127–1131, 1974
- 10) Martinoli C, Bianchi S, Santacroce E, Pugliese F, Graif M, Derchi LE: Brachial plexus sonography: a technique for assessing the root level. *AJR Am J Roentgenol* 179: 699–702, 2002
- 11) Nakagawa M, Shinbori H, Ohseto K: [Ultrasound-guided and fluoroscopy-assisted selective cervical nerve root blocks]. *Masui* 58: 1506–1511, 2009 (Japanese)
- 12) Ma DJ, Gilula LA, Riew KD: Complications of fluoroscopically guided extraforaminal cervical nerve blocks. An analysis of 1,036 injections. *J Bone Joint Surg Am* 87: 1025–1030, 2005
- 13) Furman MB, Giovanniello MT, O'Brien EM: Incidence of intravascular penetration in transforaminal cervical epidural steroid injections. *Spine (Phila Pa 1976)* 28: 21–25, 2003
- 14) Baker R, Dreyfuss P, Mercer S, Bogduk N: Cervical transforaminal injection of corticosteroids into a radicular artery: a possible mechanism for spinal cord injury. *Pain* 103: 211–215, 2003
- 15) Kumar N, Gowda V: Cervical foraminal selective nerve root block: a 'two-needle technique' with results. *Eur Spine J* 17: 576–584, 2008
- 16) Kim S, Toncheva G, Anderson-Evans C, Huh BK, Gray L, Yoshizumi T: Kerma area product method for effective dose estimation during lumbar epidural steroid injection procedures: phantom study. *AJR Am J Roentgenol* 192: 1726–1730, 2009
- 17) Shepherd TM, Hess CP, Chin CT, Gould R, Dillon WP: Reducing patient radiation dose during CT-guided procedures: demonstration in spinal injections for pain. *AJNR Am J Neuroradiol* 32: 1776–1782, 2011
- 18) Miller TS, Fruauff K, Farinhas J, Pasquale D, Romano C, Schoenfeld AH, Brook A: Lateral decubitus positioning for cervical nerve root block using CT image guidance minimizes effective radiation dose and procedural time. *AJNR Am J Neuroradiol* 34: 23–28, 2013
- 19) Mettler FA, Huda W, Yoshizumi TT, Mahesh M: Effective doses in radiology and diagnostic nuclear medicine: a catalog. *Radiology* 248: 254–263, 2008

Address reprint requests to: Mikinobu Takeuchi, MD, PhD, Department of Neurological Surgery, Aichi Medical University, Karimata 1-1 Yazako, Nagakute, Aichi 480-1195, Japan.
e-mail: take7106@aichi-med-u.ac.jp