

Two cases of septic shock with different outcomes caused by non-O1/non-O139 *Vibrio cholerae* isolates

Journal of International Medical Research

48(6) 1–6

© The Author(s) 2020

Article reuse guidelines:

sagepub.com/journals-permissions

DOI: 10.1177/0300060520933459

journals.sagepub.com/home/imr

Jie Chen^{1,*}, Jian Huang^{1,*} , Meirong Huang²,
Zehui Chen¹, Anlin Chen¹, Jianru Yang¹,
Tao Zhang¹ and Xun Min¹

Abstract

In recent decades, increasing numbers of human infections have been linked to non-O1/non-O139 *Vibrio cholerae*. Septicemia resulting from non-O1/non-O139 *V. cholerae* infection is rare but has high mortality. The pathogenesis of non-O1/non-O139 *V. cholerae* septicemia is poorly understood. Here, we report two sporadic cases of septicemia following non-O1/non-O139 *V. cholerae* infection from an inland area of China. Patient 1 died rapidly within 24 hours, while patient 2 gradually recovered from septic shock. To explore the reasons for these divergent outcomes, we compared the two cases, tested the antibiotic sensitivity of the two isolates, and investigated their virulence genes and sequence types.

Keywords

Non-O1/non-O139 *Vibrio cholerae*, septicemia, septic shock, isolate analysis, antibiotic sensitivity, virulence genes

Date received: 6 January 2020; accepted: 20 May 2020

Introduction

Vibrio cholerae is a Gram-negative bacillus present in aquatic environments. Based on differences in the O antigen on the bacterial cell surface, *V. cholerae* can be divided into more than 200 serogroups.¹ The O1 and O139 serogroups are associated with epidemic and pandemic cholera,² while

¹Department of Laboratory Medicine, Affiliated Hospital of Zunyi Medical University, Zunyi, Guizhou, China

²Department of Blood Transfusion, Affiliated Hospital of Zunyi Medical University, Zunyi, Guizhou, China

*These authors contributed equally to this work.

Corresponding author:

Xun Min, Department of Laboratory Medicine, Affiliated Hospital of Zunyi Medical University, No. 149 Dalian Road, Zunyi, Guizhou 563003, China.

Email: zmchj2001@163.com



non-O1/non-O139 *V. cholerae* strains can cause sporadic local cholera-like diarrhea and extraintestinal infection. The clinical significance of non-O1/non-O139 serogroups has long been neglected. However, in recent decades, more human infections associated with these species have been reported. Gastroenteritis is the most common disease caused by non-O1/non-O139 *V. cholerae*, and the pathogen is isolated from approximately 1.2% of patients with diarrhea in China.³ In addition, there have been reports of extraintestinal infection in recent years, including bacteremia, skin and soft tissue infections, pneumonia, urinary tract infection, meningitis, endophthalmitis and empyema.⁴⁻⁶ Bacteremia resulting from non O1/non-O139 *V. cholerae* infection is a very serious complication with a mortality rate of more than 25%.⁷ Non-O1/non-O139 *V. cholerae* strains are highly heterogeneous with considerable serological diversity and variation in virulence. Our understanding of clinical and therapeutic aspects remains incomplete.⁸ In the absence of clinical trials, a summary of case reports can provide therapeutic history and experience. In this study, we report two sporadic cases of septicemia caused by non-O1/non-O139 *V. cholerae* in Guizhou Province, an inland area of China. Both cases developed septic shock. While case 1 died rapidly within 24 hours of symptom onset, case 2 was discharged in good clinical condition after 12 days of treatment. We also investigated the virulence genes and the genetic relatedness of the isolates. Because of the rarity of such cases and their potential lethality, our report serves as a reminder for clinicians to be aware of this pathogen.

Case report

Case 1

A 36-year-old male suffered from sudden left abdominal pain, vomiting and

intermittent diarrhea after consuming jelly in a local farm town for lunch. His stools were yellow and watery with no mucus and blood. Four hours later, he was admitted to a local county hospital. On admission, he was febrile with a temperature of 39.5°C, blood pressure of 118/62 mmHg, pulse of 108 beats/minute and respiratory rate of 44 breaths/minute. Physical examination revealed abdominal tenderness mainly localized to the mid-upper quadrant. Emergency examination by abdominal computed tomography (CT) revealed cholecystitis and ascites. Based on the patient's vital signs and the results of auxiliary examination, acute cholecystitis was suspected. Antibiotics and gastrointestinal decompression treatment were administered.

The patient was transferred to our hospital (Affiliated Hospital of Zunyi Medical University) 5 hours later because his condition had gradually worsened. He had a history of high blood pressure and alcohol consumption. On examination, he was febrile with a temperature of 38.7°C, pulse of 158 beats/minute, respiratory rate of 44 breaths/minute, blood pressure of 158/109 mmHg while receiving vasopressors, and oxygen saturation of 95% while receiving oxygen at 4 L/minute. A physical examination revealed obvious abdominal distension and abdominal bullae. His abdominal pain presented as diffuse tenderness with rebound tenderness and muscle guarding. His extremities were cold. Liver function tests revealed total bilirubin levels of 30.06 µmol/L, alkaline phosphatase levels of 94 U/L, aspartate transaminase levels of 184 U/L, alanine transaminase levels of 37 U/L and albumin levels of 16.5 g/L. Renal function tests showed creatinine levels of 242 µmol/L and uric acid levels of 503 µmol/L. His coagulation profiles included a prothrombin time of 22 s and a partial thromboplastin time of 54 s. Serological tests revealed no evidence of infection with hepatitis A virus, hepatitis B virus or

hepatitis C virus. A complete blood count revealed 4.05×10^9 white blood cells/L, 3.34×10^{12} red blood cells/L, and 21×10^9 platelets/L. Chest CT showed small exudative lesions in the lower lobes of both lungs, minor bilateral pleural effusion, and a minor pneumatosis in the right neck tissue. Abdominal CT revealed cholecystitis and ascites. Diagnostic paracentesis showed yellow, cloudy ascites containing 8200 leucocytes/mm³ (90% neutrophils and 10% lymphocytes). The Rivalta test was positive.

The patient was admitted to the intensive care unit immediately and diagnosed with septic shock. Vasoactive drugs were administered to maintain blood pressure. Gastrointestinal decompression, fluid replenishment with electrolyte supplementation, anti-inflammatory drugs and other therapies were used to protect vital organ functions and counteract shock. In addition, an empiric combination of meropenem and levofloxacin was administered intravenously. Unfortunately, his condition deteriorated rapidly within the next few hours. Abdominal inspection showed that abdominal tension was extremely high. Abdominal distension was obvious, abdominal bullae were present, the local umbilical skin was red and hard, blister formation was apparent, and intestinal sounds disappeared. The patient's blood pressure was maintained at 90/50 mmHg using high doses of vasoactive drugs. Analysis of arterial blood showed metabolic acidosis and lactic acidosis (pH 7.30, pCO₂ 19.4 mmHg, pO₂ 81 mmHg, lactate > 8 mmol/L, and O₂ saturation 94% with supplemental oxygen). He eventually died from multiple organ failure less than 24 hours from symptom onset. His blood culture showed bacterial growth after 12 hours of incubation. The bacterium was identified as *V. cholerae* by matrix-assisted laser desorption ionization time-of-flight (MALDI-TOF) using a VITEK MS instrument (bioMérieux, Craponne, France). The

isolate was classified as non-O1/non-O139 because of the absence of agglutination in the presence of either O1 or O139 antisera.

Case 2

A 31-year-old male had been experiencing abdominal distension for 8 days and was admitted to our hospital on May 15, 2017. He had a 6-year history of hepatitis B virus infection but was not treated. On admission, examinations revealed stable vital signs. Serological tests were positive for hepatitis B virus, but negative for hepatitis A virus, hepatitis C virus and human immunodeficiency virus. Liver function tests showed total bilirubin levels of 64.9 μmol/L, aspartate transaminase levels of 304 U/L, alanine transaminase levels of 119 U/L and prealbumin levels of 18 mg/L. An abdominal ultrasound revealed splenomegaly. He was diagnosed with hepatitis B cirrhosis. He was treated with entecavir (0.5 mg once a day, orally) and magnesium isoglycyrrhizinate (100 mg once a day, intravenously).

On the fourth day, the patient suddenly developed chills and fever with nausea and vomiting. His body temperature was 38.5°C, then rose to 40.5°C. A systemic infection was suspected. Blood was collected immediately for culture and empiric treatment with cefotaxime was initiated. Four hours later, the patient still had a fever, a pulse of 106 beats/minute, a respiratory rate of 22 breaths/minute, blood pressure of 80/40 mmHg and oxygen saturation of 96%. His septic shock was treated with a booster and fluid replacement and antibiotic therapy was changed to imipenem. Blood cultures revealed microbial growth after 12 hours of incubation. Gram staining demonstrated the presence of Gram-negative rods. Further identification was performed using the VITEK2 system according to the manufacturer's instructions. The organism was identified

as *V. cholerae* and was classified as non-O1/non-O139 because of the absence of agglutination in the presence of either O1 or O139 antisera.

After 3 days of imipenem treatment, the patient gradually recovered from septic shock. Based on de-escalation therapy, antibiotic treatment was switched to piperacillin-tazobactam based on the results of susceptibility testing. The patient was discharged in an asymptomatic state 9 days later.

Isolate analysis

The isolates from both cases were identified as *V. cholerae* by MALDI-TOF. We tested their susceptibility using standard disk diffusion on Muller Hinton agar plates according to Clinical and Laboratory Standards Institute (CLSI) document M45-A2. Both strains were sensitive to piperacillin, cefotaxime, imipenem, meropenem, amikacin, tetracycline, diprofloxacin, and chloramphenicol. Only isolate 1 was resistant to trimethoprim-sulfamethoxazole. PCR assays were used to detect the presence of virulence genes according to previous reports.⁹ Both isolates carried the *hap*, *hlyA*, *lolB*, *ompW*, *prtV*, *rtxC* and *toxR* genes, and neither isolate carried the *ctxA*, *tcpI*, *ompU*, *stnF*, and *zot* genes. We amplified seven genes to conduct multilocus sequence typing (MLST) and assess the relatedness and genetic heterogeneity of the isolates.¹⁰ Isolate 1 was a new sequence type (ST985), while isolate 2 was classified as ST558 (<http://pubmlst.org/vcholerae/>). goeBURST analysis was used to assess the relationships between the two STs and other STs in the database. ST985 formed clonal complex 6 (CC6) with four other sequence types (ST8, ST88, ST384 and ST777). Furthermore, a large clonal complex (CC0) comprised ST558 and 27 other STs (Figure 1).

Discussion

Here we reported two cases of non-O1/non-O139 *V. cholerae* septicemia. Patient 1 had consumed raw food which may have been contaminated by non-O1/non-O139 *V. cholerae*. However, we were unable to determine the exact source because of a lack of microbiological confirmation. Patient 2's source of infection was unclear. Previous reports of non-O1/non-O139 *V. cholerae* infection have primarily originated from coastal areas.¹¹ To our knowledge, this is the first report of this type from Guizhou Province, China. These two cases serve as a reminder to clinicians in inland areas to be aware of this pathogen. Patient 1 had a history of alcohol consumption but no history of severe liver disease. Patient 2 was diagnosed with cirrhosis, which is the main risk factor for non-O1/non-O139 *V. cholerae* bacteremia. Antibiotics are critically important for the treatment of non-O1/non-O139 *V. cholerae* bacteremia. Sensitivity testing showed that both isolates were susceptible to most antibiotics. We administered timely anti-infection and anti-shock therapies to both patients. However, the outcomes of infection were vastly different in the two patients. We assessed potential causes of these different outcomes arising from virulence factors associated with the isolates.

The clinical manifestations of infections caused by non-O1/non-O139 *V. cholerae* are diverse. Most patients have mild symptoms, and only a small number of patients become seriously ill.¹² Patient 1 presented with watery diarrhea and bullae of the abdominal skin; the latter is significantly associated with in-hospital mortality.¹³ The formation of bullae is more commonly associated with *Vibrio vulnificus* infection. However, a few reports have shown that bullae formation occurs in *V. cholerae* infections. Endotoxin production following *Vibrio* infection leads to cell lysis and vascular permeability changes, eventually

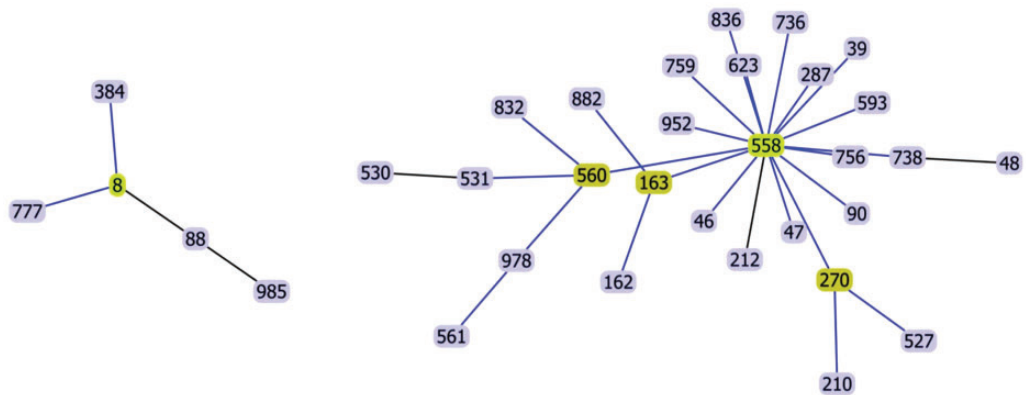


Figure 1. goeBURST analysis of CC6 (left) and CC0 (right) at the level of single-locus variants (SLVs). ST8 and ST558 were predicted to be the founders of CC6 and CC0, respectively. The inferred founders of CCs are outlined in light green and subgroup founders in dark green. Blue lines were inferred using tiebreak rule (numbers of SLVs), and black lines represent links where no tie occurred.

causing skin necrosis and formation of bullae.¹² Although non-O1/non-O139 *V. cholerae* usually does not produce cholera toxin or express the toxin coregulated pilus, reports have suggested that this bacterium may carry other types of virulence genes that play important roles in their pathogenicity. We used PCR to assess the presence of virulence genes in these two isolates. There were no differences in the common virulence genes carried by the two isolates. Differences in other unknown virulence genes may have been present; this possibility remains to be further investigated.

To investigate the genetic variation and relatedness of the two isolates, we performed MLST analysis. We found that isolate 1 represented a novel sequence type (ST985). We used goeBURST analysis to investigate the relationships between these two isolates and other isolates present in the non-O1/non-O139 *V. cholerae* MLST database. Isolates 1 (ST985), ST8, ST88, ST384 and ST777 constituted a clonal complex (CC6). ST88 was isolated in India and China,¹⁴ suggesting that this clonal complex has a wide geographical distribution. Isolate 2 (ST558) and the other 27 sequence

types constituted a large clonal complex (CC0). ST558 was the predicted founder of this clonal complex. According to the MLST database, most of the strains within this clonal complex were isolated in China. Thus, it is necessary to monitor the prevalence of members of this clonal complex in China.

CARE guidelines

This manuscript was prepared following the CARE guidelines.

Declaration of conflicting interest

The authors declare that there is no conflict of interest.

Ethics and consent statements

This study was approved by the Ethics Committee of the Affiliated Hospital of Zunyi Medical University (NO.KLL-2020-002). Each patient gave written informed consent for publication.

Funding

This research was supported by the Science and Technology Program of Zunyi (Zunshikeheshezi

[2019]91) and the National Natural Science Foundation of China (No. 31800130).

ORCID iD

Jian Huang  <https://orcid.org/0000-0002-7118-2177>

References

- Harris JB, LaRocque RC, Qadri F, et al. Cholera. *Lancet* 2012; 379: 2466–2476.
- Laviad-Shitrit S, Sharaby Y, Izhaki I, et al. Antimicrobial susceptibility of environmental non-O1/non-O139 *Vibrio cholerae* isolates. *Front Microbiol* 2018; 9: 1726.
- Luo Y, Ye J, Jin D, et al. Molecular analysis of non-O1/non-O139 *Vibrio cholerae* isolated from hospitalised patients in China. *BMC Microbiol* 2013; 13: 52.
- Yang CC, Lee BJ, Yang SS, et al. A case of non-O1 and non-O139 *Vibrio cholerae* septicemia with endophthalmitis in a cirrhotic patient. *Jpn J Infect Dis* 2008; 61: 475–476.
- Hao Y, Wang Y, Bi Z, et al. A case of non-O1/non-O139 *Vibrio cholerae* septicemia and meningitis in a neonate. *Int J Infect Dis* 2015; 35: 117–119.
- Maraki S, Christidou A, Anastasaki M, et al. Non-O1, non-O139 *Vibrio cholerae* bacteremic skin and soft tissue infections. *Infectious Diseases (London, England)* 2016; 48: 171–176.
- Deshayes S, Daurel C, Cattoir V, et al. Non-O1, non-O139 *Vibrio cholerae* bacteraemia: case report and literature review. *Springerplus* 2015; 4: 575.
- Huang J, Chen Y, Chen J, et al. Exploration of the effects of a degS mutant on the growth of *Vibrio cholerae* and the global regulatory function of degS by RNA sequencing. *PeerJ* 2019; 7: e7959.
- Ceccarelli D, Chen A, Hasan NA, et al. Non-O1/non-O139 *Vibrio cholerae* carrying multiple virulence factors and *V. cholerae* O1 in the Chesapeake Bay, Maryland. *Appl Environ Microbiol* 2015; 81: 1909–1918.
- Jiang F, Bi R, Deng L, et al. Virulence-associated genes and molecular characteristics of non-O1/non-O139 *Vibrio cholerae* isolated from hepatitis B cirrhosis patients in China. *Int J Infect Dis* 2018; 74: 117–122.
- Dobrović K, Rudman F, Ottaviani D, et al. A rare case of necrotizing fasciitis caused by *Vibrio cholerae* O8 in an immunocompetent patient. *Wien Klin Wochenschr* 2016; 128: 728–730.
- Newman C, Shepherd M, Woodard MD, et al. Fatal septicemia and bullae caused by non-O1 *Vibrio cholerae*. *J Am Acad Dermatol* 1993; 29: 909–912.
- Chen YT, Tang HJ, Chao CM, et al. Clinical manifestations of non-O1 *Vibrio cholerae* infections. *PLoS One* 2015; 10: e0116904.
- Aydanian A, Tang L, Chen Y, et al. Genetic relatedness of selected clinical and environmental non-O1/O139 *Vibrio cholerae*. *Int J Infect Dis* 2015; 37: 152–158.