

Role of Saline Infusion Sonohysterography in Infertility Evaluation

Vinita Singh, Byasdev Mishra, Snehil Sinha, Sarita Agrawal, Pushpawati Thakur

Department of Obstetrics and Gynaecology, AIIMS, Raipur, Chhattisgarh, India

ABSTRACT

Introduction: Etiology of infertility is multifactorial, and fallopian tube abnormality being one of the most important causes accounts for up to 40% of female subfertility if not less and is further increasing. Saline infusion sonohysterography (SIS) procedure is gaining popularity and is being widely practiced and accepted as a screening tool in assessing tubal patency in infertile patients attending infertility clinic and has become popular as a routine test for the evaluation of the uterine cavity in the investigation of infertility and abnormal uterine bleeding. **Objective:** To compare the results of SIS with that of hysterosalpingography in infertility evaluation and to observe the role of SIS to find out endometrial pathology and tubal patency in infertility patients. **Materials and Methods:** A retrospective, observational study was done on the basis of record maintained in the ultrasound register and case record sheets of all infertile women who underwent infertility treatment and fulfilled the inclusion criteria from June 2015 to August 2016. **Results:** SIS had sensitivity of 91%, specificity of 76% positive predictive value (PPV) of 95%, negative predictive value (NPV) of 66%, and accuracy of 89% of SIS in evaluating tubal patency. Further, SIS showed sensitivity of 83.3%, specificity of 60%, PPV of 75%, NPV of 75%, and accuracy of 72% in detecting pelvic pathology. **Conclusion:** In a low-resource country like India where patients are also less educated, SIS can prove to be a useful tool in initial workup of infertility patients with better compliance, low cost, and better results in a single visit.

KEYWORDS: Hysterosalpingography, intrauterine pathology, saline infusion sonography, tubal patency

INTRODUCTION

Problem of infertility (subfertility) is increasing day by day in a country like India. According to the reports of the World Health Organization,^[1] around 10% of women are facing problems of infertility globally. Etiology of infertility is multifactorial, and fallopian tube abnormality being one of the most important causes accounts for up to 40% of female subfertility if not less and is further increasing.^[2,3] Hence, screening for tubal occlusion is one of the first important steps in fertility assessment of the investigation of subfertile couples. Till date, hysterosalpingography (HSG) is the preferred choice of investigation followed by laparoscopy with chromotubation.^[4] HSG is a contrast-enhanced fluoroscopic radiological study which has been a standard test in the workup of infertile females. It not

only gives information about tubal patency and contour but also helps to assess the uterine cavity giving information for its size, shape, contour, and filling defect, suggestive of polyp, septa, adhesions, fibroids, etc. It has its own drawbacks and limitations like iodinated contrast and X-rays are being used and is also painful and uncomfortable for the patients. Laparoscopy with chromopertubation is largely accepted as the gold standard for diagnosing tubal occlusion but is usually preferred for the assessment or treatment of other associated pelvic pathology. It is an invasive procedure

Address for correspondence: Dr. Vinita Singh,
Department of Obstetrics and Gynaecology, AIIMS, Raipur,
Chhattisgarh, India.
E-mail: ddvinitasingh@gmail.com

This is an open access journal, and articles are distributed under the terms of the Creative Commons Attribution-NonCommercial-ShareAlike 4.0 License, which allows others to remix, tweak, and build upon the work non-commercially, as long as appropriate credit is given and the new creations are licensed under the identical terms.

For reprints contact: reprints@medknow.com

How to cite this article: Singh V, Mishra B, Sinha S, Agrawal S, Thakur P. Role of saline infusion sonohysterography in infertility evaluation. J Hum Reprod Sci 2018;11:236-41.

Access this article online

Quick Response Code:



Website:
www.jhrsonline.org

DOI:
10.4103/jhrs.JHRS_47_18

also needing anesthesia, thus adding to the cost and side effects.

Saline infusion sonohysterography (SIS), also known as sonohysterography or hysterosonography procedure, is gaining popularity and is being widely practiced and accepted as a screening tool in assessing tubal patency in infertile patients attending infertility clinic^[5] and has become popular as a routine test for the evaluation of the uterine cavity in the investigation of infertility and abnormal uterine bleeding.^[6-9] SIS can be done with B mode ultrasound (US) and Doppler. SIS refers to a procedure in which fluid is instilled into the uterine cavity transcervically through a catheter to provide enhanced endometrial visualization during transvaginal US examination.^[10,11] There are many studies that suggest application of SIS in evaluating uterine defects in patients with recurrent pregnancy loss as well as in those undergoing *in vitro* fertilization (IVF). SIS can demonstrate a patent tube; however, if blocked, the site of block is difficult to elicit. SIS aids in improved sonographic detection of endometrial pathologies, such as polyps, hyperplasia, leiomyomas, and sometimes adhesions. In addition, it can help in avoiding invasive diagnostic procedures in some patients as well as can optimize the preoperative evaluation process for those women who require therapeutic intervention. It is a well-tolerated technique, could be easily and rapidly performed at minimal cost, and has virtually lower risk of adverse effects and severe complications. The American College of Obstetricians and Gynecologists in conjunction with the American College of Radiology and the American Institute of Ultrasound in Medicine have developed a technology assessment document for saline infusion sonohysterography.^[12,13] The current study was done to observe the role of SIS to find out endometrial pathology and tubal patency in infertility patients and to compare the results of SIS with that of HSG in infertility evaluation.

Primary objective

The primary objective was to compare the results of SIS with that of HSG in infertility evaluation.

Secondary Objective

The secondary objective was to observe the role of SIS to find out endometrial pathology in infertility patients.

Study methodology

A retrospective observational study was done on the basis of record maintained in US register and case record sheets of all infertile women who underwent infertility treatment and fulfilled the inclusion criteria from June 2015 to August 2016 at our gynecology outpatient department. After revising the test validity

parameters of HSG in comparison to SIS from the literature at $\alpha = 0.05$ and a study power of 80%, a total sample size of minimum 90 participants was calculated after adding a 10% for possible drop out cases during the study. Initial workup of detailed clinical history to identify possible predisposing factors leading to infertility and the duration of symptoms was obtained from all the patients. According to standard treatment protocol, all patients had undergone detailed general examination as well as pelvic examination. Routine laboratory investigations such as screening patients for anemia and blood grouping Rh typing, 75 g 2-h glucose tolerance test, rapid plasma reagin, spouse's semen analysis, serum thyroid-stimulating hormone, prolactin, and human immunodeficiency virus test (on opt-out basis) were done before undergoing SIS. SIS was performed on the 7th or 8th day of the menstrual cycle. They were first subjected to baseline transvaginal sonography (TVS) and then sonosalpingography. Their outcome of diagnosing tubal patency was subsequently analyzed to compare the results of SIS with HSG done by an independent observer in the evaluation of uterine cavity and tubal patency. The primary outcome of the study was to test parameters of saline infusion sonography (SIS) and HSG in terms of sensitivity, specificity, positive predictive value (PPV), and negative predictive value (NPV).

Procedure for saline infusion sonohysterography

Procedures were done after obtaining valid informed consent. Premedication with ibuprofen 500 or hyoscine 10 mg was given ½ h before the procedure. Emergency cart was kept ready for any vasovagal attack. A bimanual examination was performed, Cusco's self-retaining speculum inserted, antiseptic cleaning of the cervix and vagina was performed, and a Foleys catheter of size-8 was introduced into the external os with the help of artery forceps, which was kept intracervically. In patulous os, it was kept above internal os, 2–3 ml of normal saline was pushed to inflate the bulb. Around 20 ml normal saline was kept ready with a 20 ml syringe. After removing stellate of catheter, normal saline was slowly pushed into catheter. Maximum 50 ml of normal saline was instilled. Once adequate distension of uterine cavity achieved, a sagittal sweep from cornua to cornua followed by an axial sweep from fundus to external cervical os was performed with a transvaginal probe. The cavity was evaluated for the presence of any abnormality. Subsequently, each tube was visualized separately for the presence of fimbrial turbulence (waterfall sign) which was taken as a sign of tubal patency. The presence of fluid in pouch of Douglas after SIS was also taken as a sign of tubal patency.

Parameters studied

- Endometrial thickness
- Length of endometrial cavity
- Contour of endometrial cavity
- Any detectable mass with its dimension
- Filling defect inside cavity
- Myometrial thickness
- Dimension of uterus
- Any congenital anomaly of uterus noticed coincidentally
- Tubal passage of fluid and air bubble (indicator of tubal patency)
- Fluid collection in pouch of Douglas.

Inclusion criteria

- All cases of primary infertility
- All cases of secondary infertility
- Previous history of recurrent spontaneous abortion.

Exclusion criteria

- Suspected case of genital tuberculosis
- Pelvic infection
- Active vaginal bleeding
- Suspected pregnancy
- Genital malignancy.

Type of study

This was a retrospective observational study.

The study was conducted at the Department of Obstetrics and Gynecology, AIIMS Raipur.

RESULTS

Table 1 highlights the demographic characteristics of patients, and there were more cases of primary infertility (73.4%) than secondary infertility (26.6%). Approximately 84% of the patients fall between age group of 23 and 32 years.

Table 2 shows that SIS was superior to HSG in picking up pelvic organ pathology and definitely had an added advantage of detecting adnexal pathology which HSG lacked.

All the patients who showed pathology or any abnormality were subjected for diagnostic hysteroscopy. Hence, from Table 3, it is evident that SIS is superior to HSG in picking up pelvic organ pathology which was confirmed by diagnostic hysteroscopy [Figures 1-5].

Table 4 shows that SIS detected 15 tubes with bilateral block, of which HSG showed only 10 tubes with bilateral occlusion and laparoscopy agreed to only eight occluded tubes [Figures 6-7]. Hence, concordance is 53.3% in SIS and 66.7% in HSG.

Table 5 summarizes the findings of the current study showing sensitivity of 91%, specificity of 76%, PPV of 95%, NPV of 66%, and accuracy of 89% of SIS in evaluating tubal patency. Furthermore, SIS showed sensitivity of 83.3%, specificity of 60%, PPV of 75%, NPV of 75%, and accuracy of 72% in detecting pelvic pathology.

DISCUSSION

Infertility is constantly growing in developing countries like India. India being a low-resource country, patients cannot always afford multiple visits and we need to set a management protocol in which maximum abnormalities and pathologies could be detected in a single visit. Baseline sonography is needed to be done in all infertile patients to look for antral follicular count, ovaries, pathology in the uterus, adnexa, and uterine cavity and also to check for tubal patency. Saline infusion sonography is the single most investigation which when done on day 8–9 can reveal maximum information in an average time span of 10–15 min. Baseline TVS would detect any uterine pathologies such as fibroid, ovarian mass, and polyp and also give idea of growing follicle and its size and any fluid in pouch of Douglas. In a the meta-analyses by Seshadri *et al.*,^[14] SIS was declared as having a high degree of diagnostic accuracy in the detection of all types of intrauterine abnormalities with a sensitivity and specificity of 88 and 94%,

Table 1: Demographic characteristic

	Frequency (%)
Type of infertility	
Primary	58 (73.4)
Secondary	21 (26.6)
Age distribution of participants	
18-22	6 (07.5)
23-27	34 (43.03)
28-32	32 (40.05)
33-37	7 (08.86)

Table 2: Pelvic organs abnormalities

Pathology	HSG (n=79), frequency (%)	SIS (n=79), frequency (%)
Normal pelvic organs	74 (93.6)	65 (82.2)
Endometrial hyperplasia	0	1 (1.27)
Submucous fibroid	0	1 (1.27)
Endometrial polyp	0	3 (3.79)
Ovarian cyst/to mass	0	5 (6.32)
Hydrosalpinx	1 (1.27)	1 (1.27)
Synechiae	1 (1.27)	1 (1.27)
Congenital	3 (3.79)	2 (2.53)

HSF=Hysterosalpingography, SIS=Saline infusion sonohysterography

Table 3: Uterine and adnexal pathology

Pathology	LAP/HYS (<i>n</i> =20), frequency (%)	HSG (<i>n</i> =20), frequency (%)	SIS (<i>n</i> =20), frequency (%)
Endometrial hyperplasia	1 (5)	0	1 (5)
Submucous fibroid	1 (5)	0	1 (5)
Endometrial polyp	2 (10)	0	3 (15)
Ovarian cyst/to mass	3 (15)	0	5 (25)
Hydrosalpinx	3 (15)	1 (5)	1 (5)
Synechiae	1 (5)	1 (5)	1 (5)
Congenital	1 (5)	3 (15)	2 (10)

LAP/HYS=Laparoscopy, HSG=Hysterosalpingography, SIS=Saline infusion sonohysterography

Table 4: Tubal patency on saline infusion sonohysterography versus hysterosalpingography

SIS (<i>n</i> =79)	HSG		
	B/P	B/B	U/B
B/P (59)	56	2	1
B/B (15)	10	3	2
U/B (4)	0	1	3
Inconclusive (1)	1	0	0

B/P=Bilateral patency, B/B=Bilateral block, U/B=Unilateral block, HSG=Hysterosalpingography, SIS=Saline infusion sonohysterography

respectively. SIS is quite efficient in analyzing various endometrial pathologies such as endometrial polyps, submucous myomas, intrauterine adhesions, septas, and many other congenital uterine anomalies. Hence, any patient suspected of having an endometrial pathology on conventional transvaginal scan, SIS must be done before advising hysteroscopy especially as there are few studies depicting comparable accuracy in detecting these pathologies. With advancement in US imaging, SIS and hysterosalpingo-contrast sonography are replacing HSG for the evaluation of the uterine cavity and fallopian tubal patency in many centers worldwide.^[5,14]

Our study compared the performance of SIS in diagnosing tubal patency in comparison to HSG keeping HSG as the gold standard. In addition, all those patients in whom tubal block was suspected or any pelvic pathology detected underwent diagnostic hysteroscopy with laparoscopy along with chromopertubation. The test performance parameters of SIS in terms of accuracy in detecting tubal patency were comparable to HSG being approximately 90%. SIS was much superior to HSG in detecting pelvic pathology in terms of sensitivity, specificity, PPV, NPV, and accuracy. In our study, SIS detected 15 tubes with bilateral block of which HSG showed only 10 tubes with bilateral occlusion and laparoscopy agreed to only eight occluded tubes. Hence, concordance is 53.3% in SIS and 66.7% in HSG. These results are inferior to previous studies, which have yielded concordance values between 83 and 86%.^[15-17]

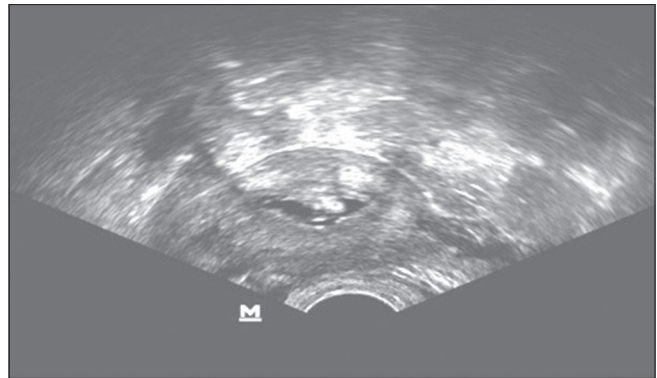


Figure 1: Endometrial polyp on saline infusion sonography

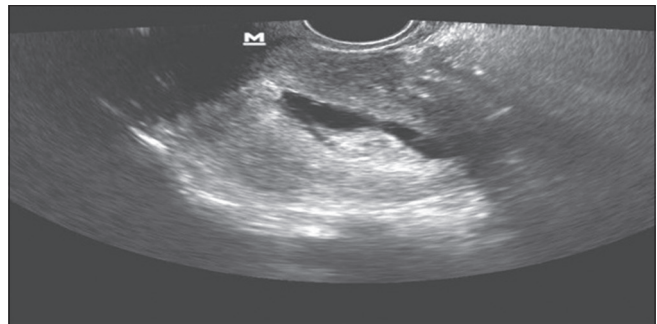


Figure 2: Sessile endometrial polyp

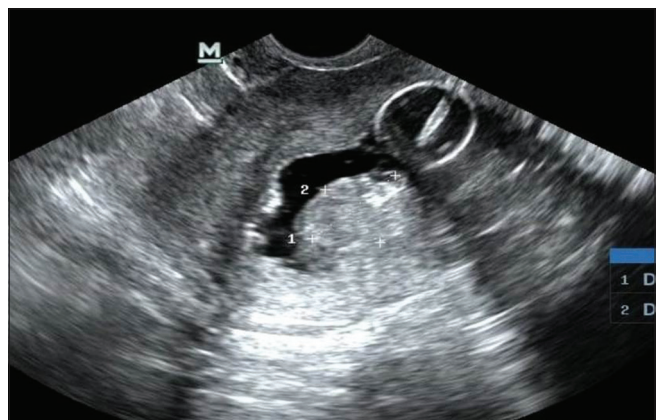

Figure 3: Submucous fibroid

The test results of our study showed sensitivity of 91%, specificity of 76%, PPV of 95%, NPV of 66%,

and accuracy of 89% of SIS in evaluating tubal patency. Furthermore, SIS showed sensitivity of 83.3%, specificity of 60%, PPV of 75%, NPV of 75%, and accuracy of 72% in detecting pelvic pathology. Similar study by Pujar *et al.*^[18] showed slightly better results of SIS in assessing tubal patency and detecting pelvic pathology. We found that SIS was very accurate in detecting tubal patency both by seeing turbulence of fluid flowing in the tubes and also by collection of fluid in pouch of Douglas, but we had difficulty in detecting side-specific tubal patency as probably the turbulence was altered in the tubes with block. It was obvious from our study that SIS had more sensitivity but less specificity than hysteroscopy or HSG in the diagnosis of uterine cavity pathology. Hysteroscopy definitely gives most accurate results in the diagnosis of endometrial pathology when compared with SIS, but SIS can very

well be incorporated as a screening tool of all infertile patients with more advantages than disadvantages. According to one study, HSG cannot be considered a reliable and accurate method for the diagnosis of tubal patency.^[19]

There is a study which also complies with our results and shows that SIS is a highly sensitive and specific investigative modality and is comparable to the gold standard tool hysteroscopy in the diagnosis of intrauterine pathology and can be utilized as screening tool for subfertile patients before taking them for IVF treatment.^[14] Another study declared that routine SIS was only beneficial in patients with any suspicious findings on TVS (including extracavitary lesions) than in those with normal TVS.^[20]

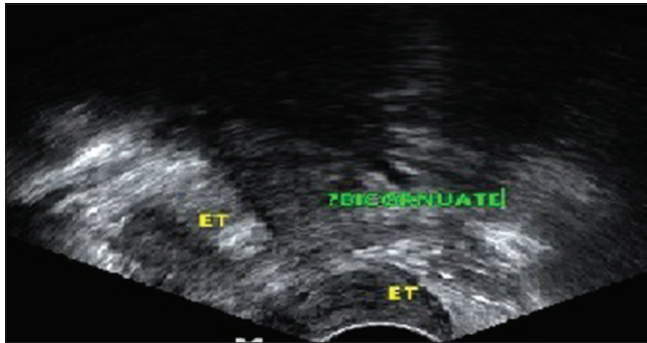

Figure 4: Bicornuate uterus with two endometrial lining

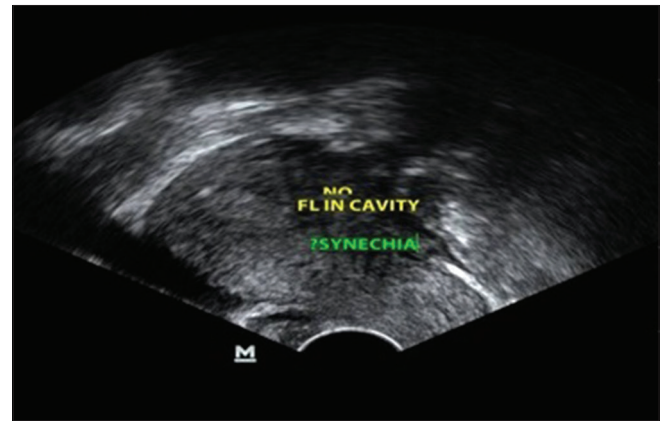


Figure 5: Synechiae

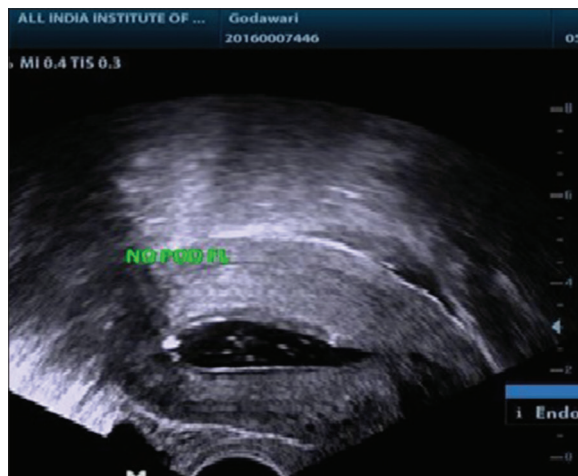


Figure 6: Blocked tubes on saline infusion sonography

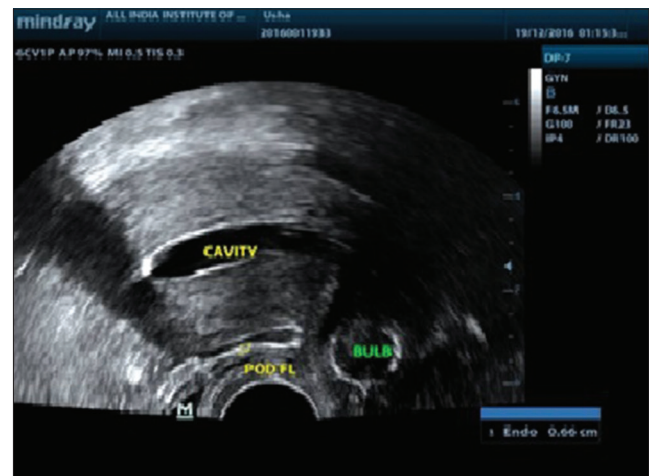

Figure 7: Bilateral patent tubes on SIS

Table 5: Results of diagnostic test

Method	Sensitivity (%)	Specificity (%)	PPV (%)	NPV (%)	Accuracy (%)
SIS (tubal patency)	91.0	76.0	95.0	66.0	89.0
SIS (pelvic organ pathology)	83.3	60.0	71.4	75.0	72.0
HSG (pelvic organ pathology)	30.0	80.0	60.0	53.3	55.0

HSG=Hysterosalpingography, SIS=Saline infusion sonohysterography, PPV=Positive predictive value, NPV=Negative predictive value

CONCLUSION

Saline infusion sonography is becoming a popular diagnostic tool for the evaluation of tubal patency and uterine pathology (both intracavitary and extracavitary) in patients with infertility. In a low-resource country like India, SIS can prove to be a useful tool in initial workup of infertility patients with better compliance, low cost, and better results in a single visit. SIS should be the investigation of choice, and HSG and laparoscopic chromopertubation should only be reserved for those patients with doubtful diagnosis in saline infusion sonography or with long duration unexplained infertility.

Acknowledgments

We would like to acknowledge the women who agreed to participate in this study.

Financial support and sponsorship

Nil.

Conflicts of interest

There are no conflicts of interest.

REFERENCES

- World Health Organization. Sexual and Reproductive Health. Available from: <http://www.who.int/reproductivehealth/topics/infertility/perspective/en/index.html>. [Last accessed on 2018 Jul 23].
- Kupesic S, Kurjak A. Interventional ultrasound in human reproduction. In: Kupesic S, De Ziegler D, editors. *Ultrasound and Infertility*. New York, NY: Parthenon Publishing; 2000. p. 253-63.
- Patil M. Assessing tubal damage. *J Hum Reprod Sci*, 2009;2:2- 11.
- National Institute for Health and Clinical Excellence: Fertility: Assessment and treatment for People with Fertility Problems. Nice Clinical Guideline 156; 2013. Available from: <http://www.guidance.nice.org.uk/cg156>. [Last accessed on 2018 Jul 23].
- Saunders RD, Shwayder JM, Nakajima ST. Current methods of tubal patency assessment. *Fertil Steril* 2011;95:2171-9.
- American College of Obstetricians and Gynecologists. ACOG technology assessment in obstetrics and gynecology No 5: Sonohysterography. *Obstet Gynecol* 2008;112:1467-9.
- American Institute of Ultrasound in Medicine, American College of Radiology, American College of Obstetricians and Gynecologists, Society of Radiologists in Ultrasound. AIUM practice guideline for the performance of sonohysterography. *J Ultrasound Med* 2012;31:165-72.
- Goldstein SR. Modern evaluation of the endometrium. *Obstet Gynecol* 2010;116:168-76.
- Tur-Kaspa I, Gal M, Hartman M, Hartman J, Hartman A. A prospective evaluation of uterine abnormalities by saline infusion sonohysterography in 1,009 women with infertility or abnormal uterine bleeding. *Fertil Steril* 2006;86:1731-5.
- Parsons AK, Lense JJ. Sonohysterography for endometrial abnormalities: Preliminary results. *J Clin Ultrasound* 1993;21:87-95.
- Syrop CH, Sahakian V. Transvaginal sonographic detection of endometrial polyps with fluid contrast augmentation. *Obstet Gynecol* 1992;79:1041-3.
- Hajishafiha M, Zobairi T, Zanjani VR, Ghasemi-Rad M, Yekta Z, Mladkova N. Diagnostic value of sonohysterography in the determination of fallopian tube patency as an initial step of routine infertility assessment. *J Ultrasound Med* 2009;28:1671-7.
- Malek-Mellouli M, Gharbi H, Reziga H. The value of sonohysterography in the diagnosis of tubal patency among infertile patients. *Tunis Med* 2013;91:387-90.
- Seshadri S, El-Toukhy T, Douiri A, Jayaprakasan K, Khalaf Y. Diagnostic accuracy of saline infusion sonography in the evaluation of uterine cavity abnormalities prior to assisted reproductive techniques: A systematic review and meta-analysis. *Hum Reprod Update* 2015;21:262-74.
- Campbell S, Bourne TH, Tan SL, Collins WP. Hysterosalpingo contrast sonography (HyCoSy) and its future role within the investigation of infertility in Europe. *Ultrasound Obstet Gynecol* 1994;4:245-53.
- Hamilton JA, Larson AJ, Lower AM, Hasnain S, Grudzinskas JG. Evaluation of the performance of hysterosalpingo contrast sonography in 500 consecutive, unselected, infertile women. *Hum Reprod* 1998;13:1519-26.
- Schlieff R, Deichert U. Hysterosalpingo-contrast sonography of the uterus and fallopian tubes: Results of a clinical trial of a new contrast medium in 120 patients. *Radiology* 1991;178:213-5.
- Pujar Y, Sherigar B, Patted S, Desai BR, Dhumale H. Comparative evaluation of saline infusion sonohysterography and hysterolaparoscopy for diagnosis of uterine cavity abnormalities and tubal patency in infertility: A one year cross-sectional study. *South Asian Fed Obstet Gynecol* 2010;2:133-5.
- Bonilla-Musoles F, Simón C, Serra V, Sampaio M, Pellicer A. An assessment of hysterosalpingosonography (HSSG) as a diagnostic tool for uterine cavity defects and tubal patency. *J Clin Ultrasound* 1992;20:175-81.
- Almog B, Shalom-Paz E, Shehata F, Ata B, Levin D, Holzer H, *et al.* Saline instillation sonohysterography test after normal baseline transvaginal sonography results in infertility patients. Is it justified? *Gynecol Endocrinol* 2011;27:286-9.