

# Total Endoprosthesis Versus Lundborg's Resection Arthroplasty for the Treatment of Trapeziometacarpal Joint Osteoarthritis

Holger Erne, MD\*  
 Claudia Scheiber, MD†  
 Daniel Schmauss, MD, PhD\*‡  
 Steffen Loew, MD§  
 Michael Cerny, MD\*  
 Denis Ehrh, MD¶  
 Verena Schmauss, MS\*  
 Hans-Guenter Machens, MD\*  
 Philipp Muhl, MD†

**Background:** There exist various operative approaches for the treatment of trapeziometacarpal joint osteoarthritis. The aim of this study was to compare the results of Lundborg's resection arthroplasty (RA) with implantation of a total endoprosthesis.

**Patients and Methods:** In this 2-center study, we retrospectively analyzed 71 patients with symptomatic osteoarthritis of the carpometacarpal I joint stage III according to the Eaton-Littler classification. Thirty-two patients underwent a Lundborg's RA group, and 39 patients received a total endoprosthesis of the carpometacarpal I joint (TEP group). We evaluated operative time, DASH score, postoperative time until resolution of symptoms, pain level, pinch force, and satisfaction with the treatment.

**Results:** Both groups had a similar mean length of follow-up of 42 months (TEP group) and 36 months (RA group). The final DASH score was significantly better in the TEP-group (10.1 versus 21.5 in the RA group;  $P \leq 0.05$ ). Also, the time interval from surgery till absence of any pain (1.5 versus 5.9 months) and the time of inability to work (6 versus 21 weeks) were significantly shorter for the TEP group compared with the RA group ( $P \leq 0.05$ ). The pinch force, pain intensity, and the satisfaction with the treatment were comparable ( $P > 0.05$ ). The duration of the operation was significantly shorter in the RA group (31 min versus 65 min in the TEP group;  $P \leq 0.05$ ).

**Conclusion:** Both techniques resulted in improved function of the operated hand and a clear reduction of symptoms. However, the implantation of a total endoprosthesis seems to have advantages, given a significantly better DASH score and a significantly shorter time until resolution of symptoms. (*Plast Reconstr Surg Glob Open* 2018;6:e1737; doi: 10.1097/GOX.0000000000001737; Published online 4 April 2018.)

From the \*Klinik und Poliklinik für Plastische Chirurgie und Handchirurgie, Klinikum rechts der Isar, Technische Universität München, München, Germany; †Klinik für Hand-, Fuß- und Mikrochirurgie, Elmshorn, Germany; ‡Division of Plastic, Reconstructive and Aesthetic Surgery, Ospedale Regionale di Lugano, Ente Ospedaliero Cantonale, Lugano, Switzerland; §Praxis für Handchirurgie und Unfallchirurgie, Bad Mergentheim, Germany; and ¶Klinik für Handchirurgie, Plastische und Ästhetische Chirurgie, Klinikum der Universität München, München, Germany. Received for publication December 10, 2017; accepted February 7, 2018.

Institutional review board approval: Not applicable because this is a retrospective study.

Statement of Conformity: This study was conducted in accordance with the Declaration of Helsinki.

Copyright © 2018 The Authors. Published by Wolters Kluwer Health, Inc. on behalf of The American Society of Plastic Surgeons. This is an open-access article distributed under the terms of the Creative Commons Attribution-Non Commercial-No Derivatives License 4.0 (CCBY-NC-ND), where it is permissible to download and share the work provided it is properly cited. The work cannot be changed in any way or used commercially without permission from the journal.

DOI: 10.1097/GOX.0000000000001737

## INTRODUCTION

Osteoarthritis of the carpometacarpal (CMC) I joint is a frequent pathology. The severity of arthritis is classified according to Eaton and Littler, and in advanced stages, the operative treatment is considered the first choice in symptomatic patients. The resection arthroplasty (RA) with or without interposition of a tendon is the most frequently performed operation for this indication worldwide.<sup>1-3</sup> An alternative, which is rarely performed, is the arthrodesis of the CMC joint.<sup>4</sup> New approaches use the interposition of silicone implants or synthetic spacers to avoid grinding of the CMC I joint and preserve the trapezium bone. However, their use is still controversially discussed, because they seem to be associated with foreign body reactions that potentially lead to synovitis.<sup>5,6</sup>

Today, the RA, although first described in 1991 and modified later on by various hand surgeons, is still considered the gold standard for treatment of CMC I joint

**Disclosure:** The authors have no financial interest to declare in relation to the content of this article. The Article Processing Charge was paid for by the authors.

arthritis.<sup>1,2</sup> Nevertheless, this technique is very ablative and invasive due to the complete removal of the trapezium with or without interposition of a tendon, usually the abductor pollicis longus (APL) tendon. This ablation negatively affects the biomechanical stability of the thumb, and a frequently seen side effect of the intervention is the proximalization of the first metacarpal bone, which might lead to impingement symptoms. Further, the period of time until completion of the healing process and pain-free movements is relatively long.<sup>7-10</sup> Besides that, patients frequently report having problems with the pinch grip, which is especially a problem for patients who are dependent on the ability to perform precision work. As a consequence, it seems logical to look for nonablative operative approaches for the treatment of CMC I osteoarthritis.


One of these less-invasive approaches, which is less commonly used, is the replacement of the CMC I joint through a total endoprosthesis.<sup>11-16</sup> This technique preserves the length of the thumb and prevents proximalization of the first metacarpal bone. Further, the possibility to convert to a conventional RA later on is preserved using this approach.

Due to a lack of data in the literature, we performed a 2-center study to compare the replacement of the CMC I joint using a total endoprosthesis to the well-established Lundborg's RA. Main endpoints were the time from operation until completion of the healing process, the usability of the hand, the pain level, and the remaining pinch force after surgery.

## PATIENTS AND METHODS

In the period from 2010 to 2016, 71 patients suffering from symptomatic and advanced CMC osteoarthritis of the thumb stages III, as classified by Eaton and Littler, were surgically treated in 2 centers.<sup>17</sup> In center 1, 39 patients underwent replacement of the CMC I joint through a total endoprosthesis (Ivory Memometal, Stryker Corporate, Kalamazoo, Mich.; total endoprosthesis group: TEP group). Figure 1 demonstrates the components of the endoprosthesis used. In center 2, 32 patients were treated with a conventional RA after Lundborg (RA group: RA group).<sup>2</sup>

The patients were operated by 5 experienced hand surgeons (center 1, n = 3; center 2, n = 2). In all patients, an additional arthritis of the scapho-trapezio-trapezoidal joint was excluded. The postoperative follow-up was performed in the particular center where the respective patient underwent the operation.



**Fig. 1.** The 3 components of the endoprosthesis used for the study (Ivory Memometal, Stryker Corporate, Kalamazoo, Mich.).

The preoperative parameters and patient data were retrospectively collected from patient files.

Preoperative parameters and demographic data were comparable between both groups (Table 1). The time from symptom onset to operation, the preoperative pain in rest, evaluated by the visual analog scale (VAS) were similar in both groups. None of the 71 patients had undergone previous operative treatment. No patient had prior cortisone injections, 6 patients (3 in each group) suffered from insulin-dependent diabetes, and 4 patients (2 in each group) were pharmacologically treated for osteoporosis.

## Operative Technique

All patients were operated using a pneumatic tourniquet and loupe magnification glasses.

### Resection Group

Longitudinal curved incision is made over the basal thumb joint. The superficial radial nerve is dissected carefully and preserved. Exposure of the trapezium, which is freed from its periosteum and split into 4 pieces using an osteotome and completely resected using a Luer. The flexor carpi radialis tendon becomes visible after the removal of the trapezium. After splitting of the first extensor tendon sheath, the APL tendon is partially transected proximally for 5 cm and left distally pedicled. This pedicle is then woven around the flexor carpi radialis tendon and sutured to itself under tension to create a sling. Rinsing of the wound with ringer solution and closure of the joint capsule and the skin.

### Prosthesis Group

Dorsal skin incision is made over the first metacarpal bone to the trapezium. Identification and preservation of the superficial radial nerve and the radial artery.

Dissection between the tendons of the APL muscle and the extensor pollicis brevis muscle and identification of the joint capsule. Incision of the joint capsule and exposure of the first metacarpal bone. At the base of the first metacarpal bone, a slice of 3 mm bone is removed parallel to the joint area using the oscillating saw. The medullary cavity is opened, and the size of the shaft is measured. Insertion of a testing shaft. At the trapezium the distal joint area is resected sparingly using the oscillating saw. Implantation of test components. After determination of the definite size, implantation of the prosthesis is performed in pressfit-technique without using cement (Figs. 1, 2).

In both groups, a cast was applied at the end of the operation, which is wrapped around the radial lower arm and wrist, and the basal joint of the thumb in palmar abduction, but sparing the interphalangeal joint of the thumb and the proximal joints of the fingers to allow movement.

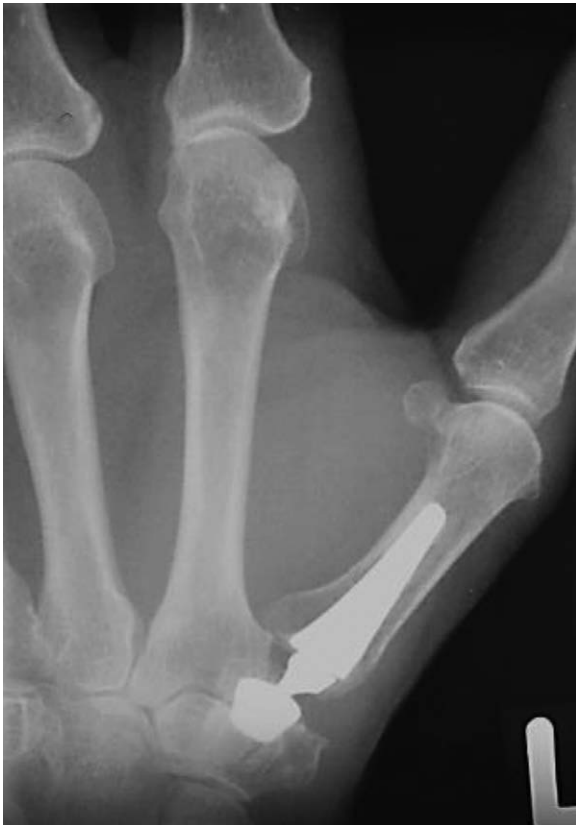
## Postoperative Care

In both groups, the patients were discharged at postoperative days 2-3. The cast was replaced by a thumb spica splint after 2 weeks, which was then worn for 4 weeks. The patients did not receive any physiotherapy.

**Table 1. Patient Demographics and Preoperative Data**

	Age (Mean in Years)	Male/Female (n)	Patients in Employment (%)	Dominant Hand Affected (n)	Duration of Symptoms (mo)
TEP group	56.2	9/30	27 (69)	19 (49)	30
RA group	54.3	7/25	20 (65)	17 (53)	23
<i>P</i>	> 0.05	> 0.05	> 0.05	> 0.05	> 0.05

All data are presented as mean.



**Fig. 2.** x-Ray of a 53-year-old woman after implantation of the endoprosthesis used for the study (Ivory Memometal, Stryker Corporate).

#### Time Intervals for Postoperative Control

All patients from both groups were invited for a follow-up examination after 12 and 18 months, 2, 3, 4, 5, and 6 years. All patients had at least 1 follow-up after 12 months. All examinations were performed by 1 surgeon per center. The follow-up protocol contained the following parameters:

- DASH score
- Time interval from surgery until resolution of symptoms/pain postoperatively
- Period of inability in employed patients
- Pinch strength using the Pinch-Dynamometer (Pinch-Gauges-Dynamometer, Modell-Nr: PG-30, B+L Engineering, Tustin, Calif.)
- Level of pain according to the VAS
- Satisfaction with the treatment using a score from 0 to 10 (0 was determined as “not satisfied at all”, and 10 as “very satisfied”)
- Sensory evaluation.

The incision to suture time was evaluated by studying patient records.

We used the parameters of the most current follow-up visit of the individual patient for the study.

#### Statistical Tests

The results of the evaluated parameters are shown as mean. The statistical comparison between both groups was done utilizing an unpaired *t* test. A result was considered statistically significant in case of  $P \leq 0.05$ .

## RESULTS

Table 2 demonstrates the results of both groups. The mean follow-up period of the TEP group was 42 months (range, 12–72 months), which is comparable with the mean of 36 months for the RA group (range, 21–65 months;  $P > 0.05$ ). The final DASH score was significantly better in the TEP group with a mean of 10.1 compared with 21.5 for the RA group ( $P \leq 0.05$ ). Also, the time interval from surgery till the absence of any pain was significantly shorter for the TEP group with a mean of 1.5 months (range, 1.0–2.5) months compared with 5.9 months for the RA group (range, 1.2–6.9 months;  $P \leq 0.05$ ).

Further, the time of disability was significantly shorter in the TEP group with a mean of 6 (range, 2–10) weeks compared with the RA group with 21 weeks (range, 12–72;  $P \leq 0.05$ ).

The pinch strength was comparable for both groups with a mean of 1.0 bar (range, 0.8–1.3 bar) in the TEP group and 0.8 bar (range, 0.6–0.9) in the RA group ( $P > 0.05$ ). In both groups, the pain intensity according to the VAS at follow-up was comparably low, [TEP group, mean 0.5 (range, 0–3); RA group, 1.0 (range, 0–7)].

Both patient collectives showed a high rate of satisfaction with the result of the operation, which was comparable [TEP group, mean 9.5 (range, 7–10); RA group, mean 8.5 (range, 6–10);  $P > 0.05$ ].

The duration of the operation was significantly shorter in the RA group with a mean of 31 (range, 13–67) minutes compared with the TEP group with a mean of 65 (range, 36–115) minutes ( $P \leq 0.05$ ).

#### Complications

Two patients of the TEP group had to undergo revision surgery due to a broken proximal component on the day of initial surgery and 3 weeks postoperatively, respectively. A third patient had a significant loosening of the implant after 1.5 years. In all 3 patients, a conversion to Lundborg's RA was performed. In another patient of the TEP group, the superficial radial nerve was injured during the operation.

**Table 2. Follow-up Results**

	Follow-up Period (mo)	Dash Score (Points)	Time from Surgery to Absence of Any Pain (mo)	Time of Inability to Work (wk)	Pinch Strength (bar)	Present Pain Level in VAS (1–10)	Patient Satisfaction with the Treatment (1–10)	Operation Time (min)
TEP group	42 (12–72)	10.1 (7.5–32)	1.5 (1.0–2.5)	6 (2–10)	1.0 (0.8–1.3)	0.5 (0–3)	9.5 (7–10)	65 (36–115)
RA group	36 (21–65)	21.5 (14–59)	5.9 (1.2–6.9)	21 (12–72)	0.8 (0.6–0.9)	1.0 (0–7)	8.5 (6–10)	31 (13–67)
<i>P</i>	> 0.05	≤ 0.05	≤ 0.05	≤ 0.05	> 0.05	> 0.05	> 0.05	≤ 0.05

All results are presented as mean (range).

One patient in the RA-group had a diminished sensibility in the innervation area of the superficial radial nerve. However, we did not find signs for a neuroma.

### DISCUSSION

The RA with additional suspension and interposition of a tendon is still the gold standard operative procedure for advanced osteoarthritis of the CMC I joint, which mostly affects women in their 40s or older.<sup>7</sup> The idea of Lundborg’s RA is to relieve any grinding between the 2 neighboring bones, and to fix the thumb ray distally with a tendinous construction to create as little proximalization as possible. Further, the tendon serves as a buffer and interposition graft.<sup>5,6,8,17,18</sup> Nevertheless, the benefit of an additional interposition of a tendon compared with trapeziectomy alone is still under discussion.<sup>19,20</sup>

RA with and without interposition of a tendon generally achieves a high grade of patient satisfaction. However, those approaches are quite invasive and ablative and change the anatomy of the wrist irreversibly.<sup>21</sup> This usually results in a loss of strength of the thumb and a long recovery time of several months, which might be a disadvantage of this well-established technique, especially for younger patients and their professional life. As a consequence, it is important to evaluate new less invasive and nonablative techniques preserving the trapezium.<sup>22</sup>

Total endoprosthesis of large joints, for example, the hip or knee joints, is performed with great success since many years. However, the commercially available total endoprostheses for the thumb CMC joint have been rarely used in the past, most probably due to preoccupation for early loosening.<sup>14</sup>

Nevertheless, the total endoprosthesis of the CMC joint of the thumb is less invasive and ablative when compared with the RA. Since our centers are experienced in both techniques and there are no comparable studies available in the literature, we performed a study comparing the standard RA according to Lundborg with the implantation of a total endoprosthesis.

To the best of our knowledge, the presented study is the first that compares mid-term follow-up results of the total endoprosthesis of the CMC I joint with the RA by Lundborg.

Both collectives were comparable regarding their advanced stage of the osteoarthritis, their demography, and the follow-up period.

Overall, the surgical results of the RA by Lundborg were comparable with the results found in the literature.<sup>1,3,10,23,24</sup> The number of studies in the literature on

total endoprosthesis of the CMC I joint is small and the results inhomogeneous.<sup>11–16</sup> Some authors report a high rate of loosening others a smaller rate, which is comparable with our collective.

We were able to demonstrate that postoperative hand function according to the DASH score was significantly better in the TEP group, which might be due to the missing proximalization and the preserved biomechanical stability of the thumb. Further, the time interval from surgery to complete resolution of pain was significantly longer in the RA group compared with the TEP group, which could possibly be explained, given that the approach is more invasive. Consequently, the time of disability was significantly longer in the RA group, which might especially be a problem for younger patients.

The pinch force and pain intensity were comparable in our collectives. However, we have the impression that our patients undergoing TEP have fewer problems with pinch precision work compared with patients undergoing RA. The reason therefore might be, once again, the preserved biomechanical stability of the thumb. Nevertheless, we do not yet have scientific data to prove this hypothesis.

On the other hand, the operation time in the TEP group was significantly longer when compared with the RA group, which seems comprehensible, because the total endoprosthesis is a much more complex procedure.

Another fact that should not be concealed is the much higher material costs for implantation of a total endoprosthesis of 1,200–1,400 U.S. dollars.

There is a learning curve for both procedures, but especially the correct positioning of the proximal component requires some experience.

The complication rate in the TEP group was higher compared with the RA group. Three patients (8% of the collective) had to undergo revision surgery due to loosening. Nevertheless, 2 of the 3 cases were operated early in our series, and therefore the reason for the complication might be the early stage of the learning curve. Several active craftsmen in the TEP group had no signs for loosening of the implant after 42 months and more.

The conversion from prosthesis to a conventional RA is always possible. The patients who had the implant removed and were converted to a Lundborg arthroplasty had postoperative results that were comparable with patients receiving a Lundborg arthroplasty primarily.

One limitation of our study might be the relatively short time of follow-up for implant-based treatment. However, we provide data that demonstrate a good mid-term outcome.

Another limitation might be the fact that the study is retrospective, not randomized, and was performed by different surgeons at different centers.

Further, the recall bias might have affected the parameters, time until the absence of pain and time of disability.

## CONCLUSIONS

In mid-term follow-up, both operative approaches for advanced osteoarthritis of the trapeziometacarpal joint are associated with high patient satisfaction. The implantation of a total endoprosthesis seems to be associated with a better function of the hand and shorter time until resolution of symptoms and reentry into employment compared with the gold standard Lundborg's RA. On the other hand, the implantation of a total endoprosthesis is more cost-intensive due to higher material costs and a longer operation time.

Holger Erne, MD

Klinik und Poliklinik für Plastische Chirurgie  
und Handchirurgie  
Klinikum rechts der Isar, Technische Universität München  
Ismaningerstrasse 22  
D-81675 München, Germany  
E-mail: Holger.Erne@mri.tum.de

## REFERENCES

1. Wulle. Abductor pollicis longus-repair in treating basal thumb joint arthrosis. Article in German. *Handchir Mikrochir Plast Chir.* 1993;25:250–255.
2. Sigfusson R, Lundborg G. Abductor pollicis longus tendon arthroplasty for treatment of arthrosis in the first carpometacarpal joint. *Scand J Plast Reconstr Surg Hand Surg.* 1991;25:73–77.
3. Mentzel M, Ebinger T, Heckmann E, et al. [Results of basal joint arthrosis treatment—comparison of Epping ligament reconstruction with trapeziectomy alone]. *Handchir Mikrochir Plast Chir.* 2001;33:176–180.
4. Klimo GF, Verma RB, Baratz ME. The treatment of trapeziometacarpal arthritis with arthrodesis. *Hand Clin.* 2001;17:261–270.
5. Pellegrini VD Jr, Burton RI. Surgical management of basal joint arthritis of the thumb. Part I. Long-term results of silicone implant arthroplasty. *J Hand Surg Am.* 1986;11:309–324.
6. Ehrl D, Erne H. Poor outcomes from use of the Artelon® biodegradable implant for the treatment of thumb carpo-metacarpal joint and scapho-trapezio-trapezoid osteoarthritis: a short report and brief review of literature. *J Hand Surg Eur Vol.* 2015;40:1009–1012.
7. Ehrl D, Erne HC, Broer PN, et al. Outcomes of denervation, joint lavage and capsular imbrication for painful thumb carpometacarpal joint osteoarthritis. *J Hand Surg Eur Vol.* 2016;41:904–909.
8. Epping W, Noack G. [Surgical treatment of the saddle joint arthrosis]. *Handchir Mikrochir Plast Chir.* 1983;15:168–176.
9. Ehrl D, Erne HC, Broer PN, et al. Painful thumb carpometacarpal joint osteoarthritis: results of a novel treatment approach. *J Plast Reconstr Aesthet Surg.* 2016;69:972–976.
10. Burton RI, Pellegrini VD Jr. Surgical management of basal joint arthritis of the thumb. Part II. Ligament reconstruction with tendon interposition arthroplasty. *J Hand Surg Am.* 1986;11:324–332.
11. Dehl M, Chelli M, Lippmann S, et al. Results of 115 Rubis II reverse thumb carpometacarpal joint prostheses with a mean follow-up of 10 years. *J Hand Surg Eur Vol.* 2017;42:592–598.
12. Kollig E, Weber W, Bieler D, et al. Failure of an uncemented thumb carpometacarpal joint ceramic prosthesis. *J Hand Surg Eur Vol.* 2017;1:1753193416688427.
13. Kollig E, Bieler D, Franke A. [Replacement of the thumb carpometacarpal joint: current importance of endoprosthetics for operative treatment of rhizarthrosis]. *Unfallchirurg.* 2016;119:1007–1014.
14. Badia A. Total joint arthroplasty for the arthritic thumb carpometacarpal joint. *Am J Orthop (Belle Mead NJ).* 2008;37:4–7.
15. De Smet L, Sioen W, Spaepen D, et al. Total joint arthroplasty for osteoarthritis of the thumb basal joint. *Acta Orthop Belg.* 2004;70:19–24.
16. Kaszap B, Daecke W, Jung M. High frequency failure of the Moje thumb carpometacarpal joint arthroplasty. *J Hand Surg Eur Vol.* 2012;37:610–616.
17. Eaton RG, Lane LB, Littler JW, et al. Ligament reconstruction for the painful thumb carpometacarpal joint: a long-term assessment. *J Hand Surg Am.* 1984;9:692–699.
18. Kaarela O, Raatikainen T. Abductor pollicis longus tendon interposition arthroplasty for carpometacarpal osteoarthritis of the thumb. *J Hand Surg Am.* 1999;24:469–475.
19. Aliu O, Davis MM, DeMonner S, et al. The influence of evidence in the surgical treatment of thumb basilar joint arthritis. *Plast Reconstr Surg.* 2013;131:816–828.
20. Mahmoudi E, Yuan F, Lark ME, et al. Medicare spending and evidence-based approach in surgical treatment of thumb carpometacarpal joint arthritis: 2001 to 2010. *Plast Reconstr Surg.* 2016;137:980e–989e.
21. Herold C, Fleischer O, Allert S. [Autologous fat injection for treatment of carpometacarpal joint osteoarthritis of the thumb—a promising alternative]. *Handchir Mikrochir Plast Chir.* 2014;46:108–112.
22. Erne H, Cerny M, Ehrl, et al. Autologous fat injection vs. Lundborg's resection arthroplasty for the treatment of trapeziometacarpal joint osteoarthritis. *Plast Reconstr Surg.* 2018 Jan;141(1):119–124.
23. Zajonc H, Grill B, Simunovic F, et al. [Comparison of the results of Lundborg's and Sirotakova's resection-suspension arthroplasty for the treatment of trapeziometacarpal joint osteoarthritis]. *Handchir Mikrochir Plast Chir.* 2016;48:161–167.
24. Esenwein P, Hoigne D, Zdravkovic V, et al. [Resection, interposition and suspension arthroplasty for treatment of basal joint arthritis of the thumb: a randomized and prospective comparison of techniques using the abductor pollicis longus- and the flexor carpi radialis tendon]. *Handchir Mikrochir Plast Chir.* 2011;43:289–294.